

laser



international magazine of laser dentistry

2 2017



case report

Diode-laser assisted vital pulp therapy

case report

Treatment of black hairy tongue

industry

Laser in soft tissue treatment



Fotona
choose perfection

The universe at your fingertips.

● LightWalker

The highest technology dental laser system

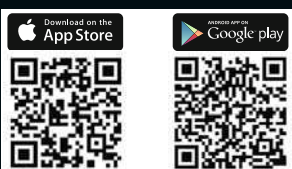
Supreme clinical results:


- TwinLight® Perio Treatments
- TwinLight® Endo Treatments
- No-sutures soft-tissue surgery
- Patient-friendly conservative dentistry
- Pre-sets for over 40 applications

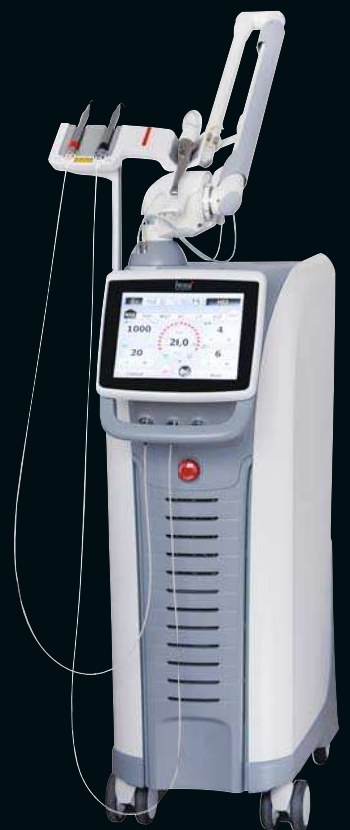Unmatched simplicity of use:

- Balanced and weightless OPTOflex® arm
- Nd:YAG handpiece detection system
- Quantum Square Pulse technology for fast minimally invasive treatments
- X-Runner™ - the first digitally controlled Er:YAG dental laser handpiece

Journey into a new dental experience with speed, precision and great results.
Visit www.fotona.com today!



 Fotona App



88897/25



Prof. Dr Norbert Gutknecht

Sense & sensibility

Dear colleagues,

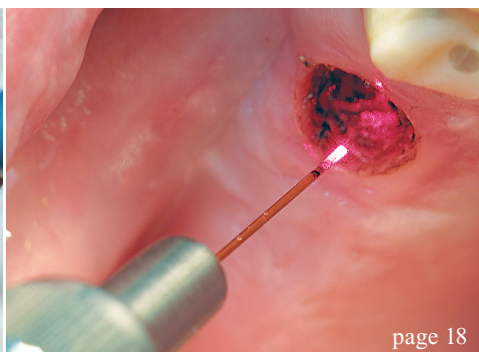
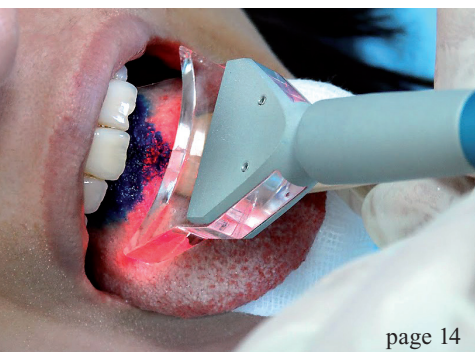When I walked the exhibition grounds of the IDS two and a half months ago, two aspects of the world's largest dental exhibition were especially touching to me. Firstly, the number of participants and exhibitors has increased significantly over the years. And secondly, innovations and digital technologies have gained more presence in dentistry. While originally a merely mechanical type of work, the profession of the dentist has turned into handling a command centre surrounded by various technologies, including the latest laser devices. If you thought that you would find hardly more than four or five laser manufacturers at the IDS only a few years ago, a look into this year's list of exhibitors will have shown otherwise. Not only were there more than 40 laser exhibitors and manufacturers present at the IDS 2017, but the technical development of the laser devices was impressive.

The devices' performance and efficiency, the increasing variability of the laser applicators and the above-mentioned further development of the software presented by many manufacturers demands a higher level of insight in these technologies from the users when treating patients. The laser industry's response to a yet palpable knowledge deficit in this regard covers elaborate treatment animations and extensive default settings for special therapies. A sensible balance of high-tech laser and extensive insights into its appropriate handling will make laser-assisted therapies in dentistry even more effective in the future.

Yours,

A handwritten signature in black ink, appearing to read 'N. Gutknecht'. The signature is fluid and cursive, with a large initial 'N'.

Prof. Dr Norbert Gutknecht



editorial

- 03 Sense & sensibility
Prof. Dr Norbert Gutknecht

case report

- 06 Dual-wavelength laser application
Dr Imneet Madan
- 10 Diode-laser assisted vital pulp therapy
Dr Masoud Shabani *et al.*
- 14 Treatment of black hairy tongue
Prof. Georgi T. Tomov *et al.*

industry

- 18 Laser in soft tissue treatment
Hans-Joachim Koort
- 22 Laser-assisted herpes labialis therapy
Dr Darius Moghtader
- 26 Sealer placement in lateral/accessory canals
Dr He-Kyong Kang & Dr John Palanci

practice management

- 30 Successful communication in your daily practice
Dr Anna Maria Yiannikos
- 32 Marketing dentistry in a global economy
Chris Barrow

events

- 35 This year's IDS sets new record in attendees
- 36 4th International SGOLA Congress
Timo Krause
- 38 Bringing laser to sunlight

news


- 41 manufacturer news
- 42 news international

DGL

- 45 Effizienz & Innovation
Prof. Dr. Norbert Gutknecht
- 46 Laserzahnheilkunde – Was geht und was nicht
- 48 news germany

about the publisher

- 50 imprint



Cover image courtesy of Biolase Technology Inc.
www.biolase.com
Original Background: © Samarets/Shutterstock.com



22 & 23 SEPTEMBER

WFLD-ED 2017
THESSALONIKI
GREECE BRINGING LASER
TO SUNLIGHT



© YK/Shutterstock



6TH EUROPEAN DIVISION CONGRESS OF THE WORLD FEDERATION FOR LASER DENTISTRY

Aachen Dental Laser Center – AALZ
Pauwelsstraße 17 · 52074 Aachen · Germany
Tel.: +49 241 4757130 · info@aalz.de

AALZ
World Academy for
Laser Education in Dentistry

αααααα
Official Media Partner

Dual-wavelength laser application

Dental-fistula in a **primary** anterior tooth

Author: Dr Imneet Madan, UAE

Primary teeth play a vital role in setting the healthy pathway towards permanent dentition. The treatment modalities for primary teeth should therefore be in best favour of preserving these teeth until they exfoliate naturally. Chronic dental caries in primary teeth are the most common cause of premature extractions. The best mode of management is to prevent the onset, nevertheless, when the decay does occur and reach the stage where there is chronic infection leading to periapical areas, laser therapy can be used effectively to save the tooth.

The current case report emphasises on the successful effect of laser in the treatment of fistula in primary upper anterior tooth in a four-year-old female. Laser-assisted endodontic treatment resulted in success and this helped to retain the anterior primary tooth until the permanent tooth will eventually replace it at the age of six to seven years. The child is under periodic follow-up and has had no clinical or radiographic signs of reinfection since the last two years.

Introduction

Primary teeth functions extend far beyond enhancing the smile of the child. They act as the natural space maintainers that can be the best guide in the eruption of permanent teeth in accurate alignment. Primary teeth contribute to the development of jaws, maintain the speech of the child and avoid the development of any parafunctional habits such as tongue thrusting.¹

Considering these vital functions of the primary teeth, it is important that under any given conditions, it should be prioritised to save them and avoid premature extraction. One of the most common reasons for the primary teeth to undergo extraction

is chronic untreated dental caries. Chronic dental carious lesions lead to necrosed pulpal changes and treatment for this is very complex in primary teeth.² Both anatomical and physiological nature of primary teeth does not allow complete elimination of root canal infection. There has been no reported endodontic concept for the treatment of primary teeth so far.³

The microbiology of endodontic infections is complicated. *Enterococcus faecalis* has been reported in high prevalence in primary root canal infections.⁴ However, lasers, by virtue of their deeper permeability help in sterilising the affected and infected canals leading to better success rates with compromised teeth.

Case report

A four-year-old female child reported to the dental clinic after referral from their general practitioner. The child came in with her mom in January, 2015 after a traumatic fall on the upper front teeth a few weeks back. No antibiotics were taken. The upper front tooth had been mobile ever since the fall. The mom took the child to her dentist and they were then referred to consult for an opinion other than extraction.

On intraoral examination

Tooth number 61 presented with grade II mobility and a periapical fistula. An intraoral periapical X-ray showed widening of the periodontal ligament in the periapical area. There were no signs of tenderness to percussion, although the child was in discomfort due to infection and swelling in the gum (Fig. 1).

Discussion prior to the treatment

Based on radiographic and clinical examination, two options of the treatment were given as follows:

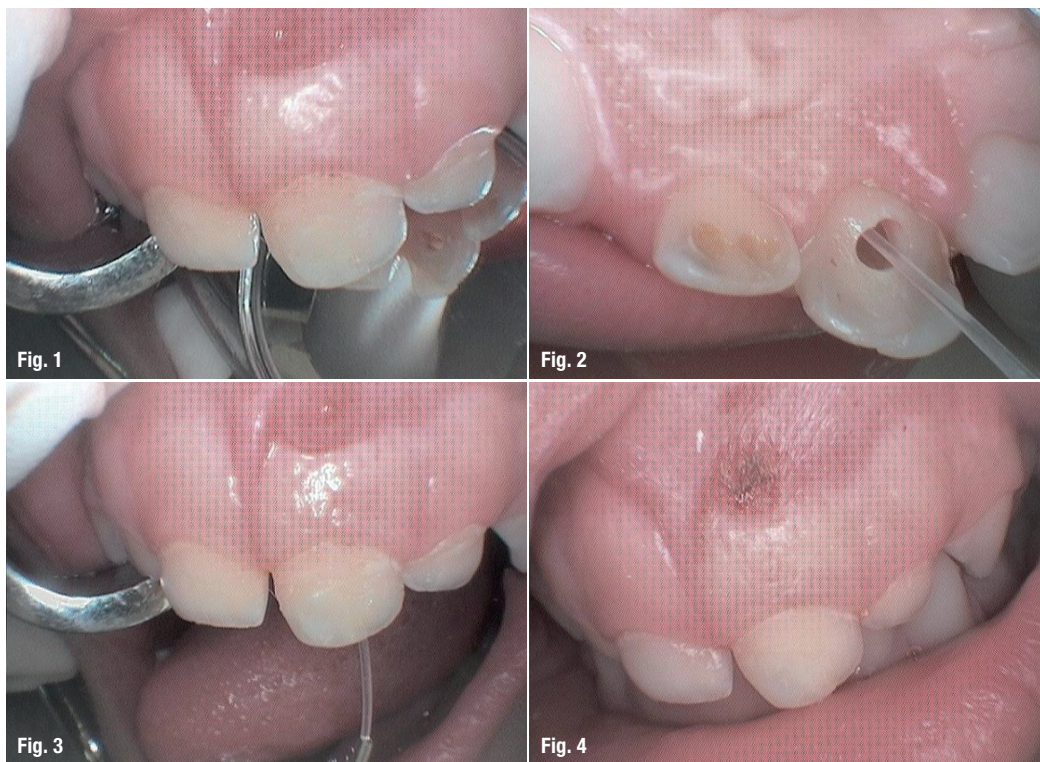


Fig. 1: Primary upper anterior tooth 61 with fistula.

Fig. 2 & 3: Zinc oxide eugenol obturation was done followed by GC Fuji IX base fill and composite fill on top.

Fig. 4: Primary upper anterior teeth after treatment.

Option 1: Extraction followed by fixed space maintainer.

Option 2: Root canal treatment with uncertain prognosis.

Cotton role: Tooth pillow

Irrigation of canals: Wash the sugar bugs

Obturation: Putting cream in the tooth

Filling: Close the hole

The child's mom was informed that after the endodontic treatment of tooth #61, the tooth will be observed for three months and an X-ray will be repeated in order to check the healing of the periapical region. In case that the tooth does not take the treatment successfully and there is a recurrence of the infection, an extraction followed by space maintainer should be planned. The mom understood both of the options and decided to go with option two.

Certain behaviour modelling tools of neuro-linguistic programming were used in order to get the child's attention and cooperation. Since the child was able to listen and agree in the best manner; the steps for next visit were informed. She was very fond of Barbie princess stories, so we agreed on telling the princess stories and watching the same in the next visit. The child then left the surgery with a small reward as a positive reinforcement of good behaviour and good listening.

Dental behaviour

The child was young, thereby, apprehensive and fearful towards the dental treatment. The Dental Behaviour Management was as following: It was suggested to use the conscious sedation with nitrous oxide. On the first visit, no treatment was performed. The child was acquainted with the dental chair, basic dental tools, water, air syringe, nasal mask and laser.

Before leaving, the "Next Time Behaviour" message was given and reinforced with small stickers. This was done to serve as a reminder for the child to be brave next time as well.

Nitrous oxide sedation

Nitrous oxide is a friendly gas that helps to relax the receptors in the way that the child acts more receptive to the instructions during the dental procedure. It does have an analgesic or anxiolytic effect that causes temporary depression of the central nervous system with very little effect on the respiratory system. It gets absorbed rapidly but stays relatively insoluble into any tissues in the body. At the end of the procedure, 100 per cent oxygen is used to flush out nitrous oxide. There is minimal impairment of any reflexes, thus cough reflex is protected.⁵

Euphemisms involved in the treatment were explained as follows:

Nasal Mask: Happy air

Laser: Popping light

Dental caries: Sugar bugs

Dental cavity: Hole

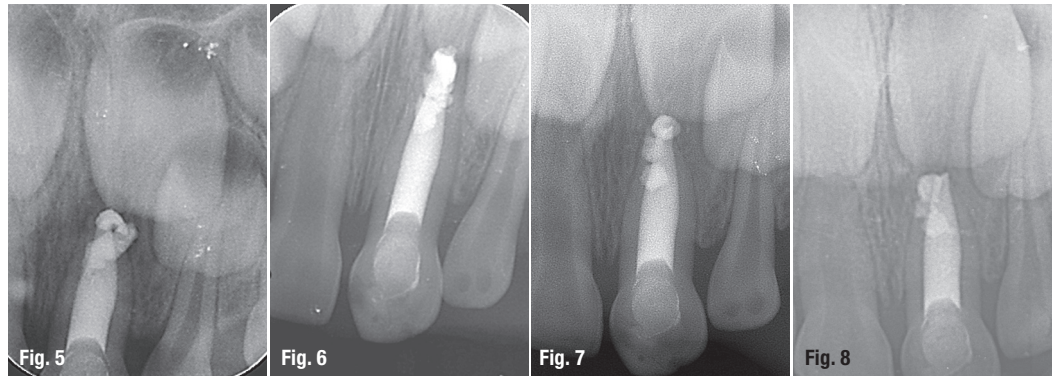
Water: Washing the sugar bugs

Fig. 5: X-ray of the primary upper anterior teeth after treatment.

Fig. 6: X-ray, follow-up after four months.

Fig. 7: X-ray, follow-up after nine months.

Fig. 8: X-ray, follow-up after eighteen months.



Informed consent

Due to the nature of pathology, uncertain prognosis for the treatment was suggested. The child's mom understood that in case of failure of treatment, retreatment is not recommended. The tooth would be extracted in such a scenario. Cost estimates for both options were given. The mom chose the treatment plan with laser under conscious sedation. Written consents for the agreed treatment, nitrous oxide sedation and costs were taken.

Procedure

As the child was seated in the chair, basic neuro-linguistic programming techniques were used to get her attention to follow the instructions of deep breathing. One of the introductory techniques is to ask the child to "imagine". As she began to imagine her own creations such as clouds, butterflies, flower garden, she was guided into deep breathing. Further continuation of stories and metaphors helped to place the mask.

Nitrous oxide was slowly increased to 50 per cent and then finally settled at 55 per cent. During this euphoric state, the child chose to watch a movie on the overhead screen. She was allowed to relax in this state for five minutes before the procedure was started. After that, an erbium laser access from the palatal surface was done with following settings: Er,Cr:YSGG 2,780 nm, MX7 tip, 3.75 W, 25 Hz, 80 water, Air 60. Rotary instruments, TCM prep, were used to enlarge the canals until ISO #35. Intermittent irrigation with saline and chlorhexidine was done. The erbium laser was used for initial sterilisation of the canals with following settings: Er,Cr:YSGG 2,780 nm, RFT2, 1.25 W, 50 Hz, Air 34, Water 24. Paper points were then used to dry the canals. A diode laser 940 nm, 1.5W, continuous wave, 2 mm/sec, 4-5 turns in circular motion was used. An interim temporary filling was placed in order to allow the fistula to heal before the final obturation.

After three days, the tooth was reintervened. The temporary fill was removed and the canals were re-irrigated with saline and chlorhexidine. Both erbium and diode laser were used to sterilise the radicular and

periapical area. Since the canals had no bleeding and were completely dry, zinc oxide eugenol obturation was done followed by GC Fuji IX base fill and the composite fill on the top (Figs. 2-5).

After four months, the child presented with no clinical signs or symptoms. An intraoral periapical X-ray showed no abnormal changes (Fig. 6). The child was able to eat, chew and there had been no recurrence of infection since the completion of treatment.

The follow-up after nine and eighteen months shows no clinical or radiographic changes (Figs. 7 & 8). The child has been completely asymptomatic and the tooth showed normal signs of physiological resorption (Fig. 9).

Discussion

Primary teeth act as the natural blue print for the eruption of permanent teeth. They facilitate vital functions:

- Act as a natural space maintainers for the teeth.
- Support proper chewing and digestion of the food.
- Help in normal development of speech.
- Add to self-esteem and confidence of the child.

Early loss of primary teeth can interrupt a proper development of the speech. It can also lead to tongue interposition and development of parafunctional oral habits. Keeping the above functions in mind, it is ideal not to decide to savage the primary tooth until it is time for the new permanent teeth to erupt.

The microbiology of fistula

The microbiology of fistula has been reported to be quite complex. Even though, the details of the same are scarce. The deep areas of periapical region and around do not provide oxygen to feed the bacteria; hence, it is mainly the anaerobic population that dwells here quite well. These bacteria can result in pain, swelling, tenderness and exudation of pus.

A high prevalence of *Enterococcus* species and *P. gingivalis* has been observed in the necrotic pulp of

2 to 5 years old. Since *E. faecalis* is very resistant to antimicrobials, this makes the endodontic treatment of primary teeth a bit more challenging.⁴ *P. gingivalis* has been found to affect about 27 per cent of primary teeth.^{6,7} *P. nigrescens*, *P. intermedia* and *P. endodontalis* also contribute to the infectious process of the pulp.³ Other bacteria that are found to contribute as well are *Fusobacterium nucleatum*.⁸ Bacterial associations such as Porphyromonas/Prevotella species and *P. gingivalis*/Enterococcus species had been found in primary teeth as per few studies done on the microbiology of the deciduous teeth with periapical abscess and fistula.⁹ Spirochaetes such as *Treponema denticola* are also profound.⁷ *Enterococcus faecalis*, *P. gingivalis* and *F. nucleatum* were found in extensive numbers especially in the fistula related to primary teeth.³ It is the complex nature of the primary root canal microbiology that renders the conventional treatment supported only with antimicrobial not 100 per cent successful.

Complex microbiology that demands laser

There are predominantly two factors that complicate the success of primary teeth root canals:

1. Anatomical root configuration
2. Complex resident bacterial flora¹⁰

The presence of lateral canals and a predominant number of canal openings in the apical delta is a specific anatomical variation of baby teeth. Blind ending canals called Diverticles pass through the root dentin.¹⁰ Additionally, dentinal tubules run through the entire dentine in complex manner and store the bacteria at the depth of up to 1,000 μm .^{11,12} At this depth, the microbes are able to sustain against the body's own defences and conventional pulpectomy procedures.^{11,12}

The conventional irrigants used in pulpectomy can penetrate to the depth of about 100 μm .¹³ Lasers of different wavelengths have been used in the root canals and have shown the depth of penetration between 500 μm to less than 1,000 μm .¹⁰ Laser light

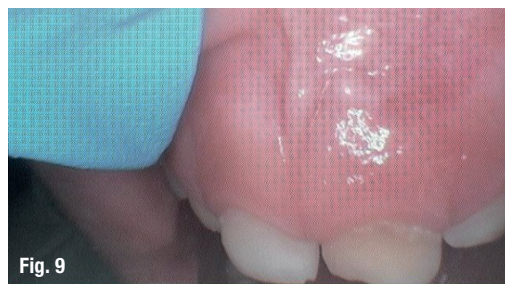

Fig. 9: The child has been completely asymptomatic and tooth showed normal signs of physiological resorption.

causes permanent destruction of the microbial cell membrane and thereby stops their further growth.¹⁰

Conclusion

Primary tooth endodontics has gained utmost importance in the past few decades, where parents come seeking root canal treatments for the chronically affected primary teeth. Those who are not aware of the same are educated about the importance of baby teeth at the first appointment. Parents feel more assured when a successful alternative to extraction is given.

Even if teeth are in grossly decayed shapes, laser-assisted endodontics proves successful in the lasting success of the treatment until the tooth exfoliates on its own.

contact

Dr Imneet Madan

Specialist Pediatric Dentist
MSc Lasers Dentistry (Germany)
MDS Pediatric Dentistry
MBA (Hospital Management)
Children's Dental Center, Dubai
Villa 1020 Al Wasl Road, Umm Suqeim 1
Dubai, United Arab Emirates
Tel.: +971 506823462
imneet.madan@yahoo.com
www.drmmichaels.com

Author details



Kurz & bündig

Das Milchzahngebiss setzt die Grundlage für die bleibenden Zähne. Daher sollte bei einer Behandlung die Bewahrung der Milchzähne im Vordergrund stehen, solange, bis diese von alleine ausfallen. Die beste Behandlungsstrategie ist Prävention. Sollte es doch einmal zu einem vorzeitigen Verfall und einer chronischen Infektion kommen, die bis in den periapikalen Bereich vordringt, kann eine Lasertherapie effektiv sein und zur Rettung des Zahns beitragen. Im Fallbericht schildert die Autorin den erfolgreichen Einsatz des Lasers bei der Behandlung einer Fistel im oberen Frontzahn einer vier Jahre alten Patientin. Die laserunterstützte, endodontische Behandlung führte zum Erfolg und trug dazu dabei, den Oberkieferfrontzahn im Milchzahngebiss bis zum Zahnwechsel im Alter von sechs bis sieben Jahren zu bewahren. Das Kind kommt zu regelmäßigen Kontrollterminen in die Praxis und zeigt seit zwei Jahren keine klinischen oder radiologischen Anzeichen einer erneuten Infektion.

Literature

