



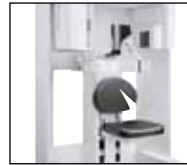AAID heads to Vegas
Figure out how to stack the deck in your favor

▶Page 10



Win a trip to New York!
Find out how you can enter the Dental Tribune Awards

▶Page 17



The new i-CAT Precise
Learn what sets this new technology apart from others

▶Page 23

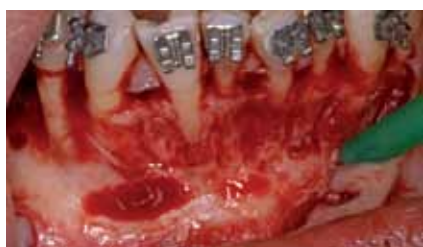

Fig. 1: A very resorbed ridge in the edentulous area is evident together with bone dehiscence on teeth #31, #42 and #44. A regeneration with xenogeneic bone of bovine origine (Endobone, BIOMET 3i) and a resorbable membrane (Osseoguard, BIOMET 3i) was performed. (Photos/Provided by Dr. Federico Brugnam)

Surgically accelerated orthodontics in implant treatment

By Federico Brugnam, DDS, and Alfonso Caiazzo, DDS

Abstract

Multidisciplinary treatment requires excellent communication and coordination among clinicians in a variety of fields. Although this can be difficult to achieve at first, interdisciplinary collaboration usually results in efficient treatment that patients appreciate and benefit from.

→ [page 2](#)

AAOMS in Philly



Philadelphia is the site of the AAOMS 93rd Annual Meeting, Scientific Sessions and Exhibition, which takes place Sept. 12-17 at the Pennsylvania Convention Center. (Photo/www.sxc.hu)

Annual meeting takes place Sept. 12-17 in Pennsylvania

The AAOMS 93rd Annual Meeting, Scientific Sessions and Exhibition will take place Sept. 12-17 at the Pennsylvania Convention Center, located at the Philadelphia Marriott.

The meeting will include a variety of features such as Anesthesia Update, Maxillofacial Oncology Program, Symposia, Surgical Mini-Lectures and Clinics, Professional Allied Staff Courses, Practice Management Clinics, Lunch and Learn Sessions, Poster and Abstract Sessions, Corporate Forum Sessions, and Faculty and Resident Programs.

Speakers will include Daniel R Cullum, DDS; Michael D. Turner, DDS, MD; Joshua Lubek, DDS, MD; Joshua Lubek, DDS, MD; Daniel Buchbinder, DMD, MD; Thomas R. Flynn, DMD; Anthony Sclar, DMD; Steven M. Sullivan, DDS; Bach T. Le, DDS, MD; Paul Tiwana, DDS, MD; and many more.

For more information, see www.aaoms.org/annual_meeting/2011.

Validating the oral-systemic health connection

By Barry L. Musikant, DDS

How does one go about becoming familiar with an avenue of health improvement that we have in the past paid little or no attention to, at least on a professional level, yet has major impact on our patient's oral health? I am

referring to the nutritional status of our patients (and ourselves) and the implications it has on our general health. The central question is whether or not there is adequate validity in the quantification of our nutritional status as a measure of our health to apply it to our patients. Secondly, but of obvious clinical importance, is whether or not the technology exists that would allow us to make quantitative measurements.

In terms of answering the first question, one of the first studies that caught my attention was Munoz et al in a paper titled, "Effects of a Nutritional Supplement on Periodontal Status," published in the May 2001 issue of *Compendium*.¹ Researchers at Loma Linda University studied the impact of an antioxidant-rich oral supplement on 63 patients ranging in age from 20 to 70 years and diagnosed with gingivitis and Type II periodontal disease during a 60-day double-blind trial.

The participants were random-

ly assigned to two groups — the experimental group, which took two tablets each day of the proprietary blend of antioxidants, and the control group, which took a similar-looking placebo.

Results of the study showed significant improvement in the clinical parameters and measurements of gingival inflammation, bleeding on probing, pocket depth and attachment levels.

"At the 60-day evaluation point, all subjects receiving the experimental treatment had significant reduction in the gingival index, pocket depth and bleeding index." Treatment with this proprietary nutraceutical appeared to offer patients a noninvasive, systemic, adjunctive protocol to potentiate in-office therapies.

In a second double-blind study also conducted at Loma Linda, pocket depth measurements were made within three groups of patients. The groups consisted of those who were

→ [page 7](#)

PRSR STD
U.S. Postage
PAID
San Antonio, TX
PERMIT #1396

Dental Tribune America
116 West 25th St., Ste. 500
New York, NY 10011

← **IT** page 1

When appropriately coordinated, the job of each specialist can facilitate the work of the other team members. For example, orthodontists can be of considerable assistance in periodontal and prosthetic treatment. Dental alignment of the arches can facilitate periodontist's and prosthodontist's objectives. This is done, for example, by aligning the natural dentition, making possible a path of insertion for a prosthesis, or establishing a physiological alveolar crestal topography to facilitate periodontal surgery.

Orthodontic tooth movement can then be of substantial benefit for the patient. Many adults seeking routine restorative dentistry have misaligned teeth, which compromises either the final restorative outcome or the ability to clean the natural dentition.

Orthodontic appliances have become smaller, less noticeable and easier to maintain during therapy. Invisible or lingual appliances further improve the rate of acceptance by adult patients. Many adults can now have their teeth aligned to improve their chewing function and their smiles with reduced esthetic effect during therapy.

In addition, implants have become a major part of the treatment plan for adults with missing teeth. If adjacent teeth have drifted into the edentulous area, orthodontics may be beneficial for providing adequate space for implant placement and restoration.

One of the major problems in acceptance of orthodontic treatment by adults is the length of treatment. For this reason, periodontists and oral surgeons may be helpful to the orthodontist, as they can facilitate the orthodontist's work and thereby reduce treatment time. Endosseous implants can be used to enhance anchorage and increase movement control of orthodontically moved teeth.

Furthermore, the alveolar architecture can be reshaped with periodontally accelerated osteogenic orthodontic augmentation (PAOO) surgery to produce the regional acceleratory phenomenon (RAP),^{1,2} which results in a vast increase in osteoblast and osteoclast activity.

The biological result of this is osteopenia (decrease of bone mineralization without loss of volume). The clinical result is softer bone, which may allow faster movement of teeth.^{3,4} In multidisciplinary treatment of adult patients, malocclusion may be associated with tooth loss, bone resorption and a consequent

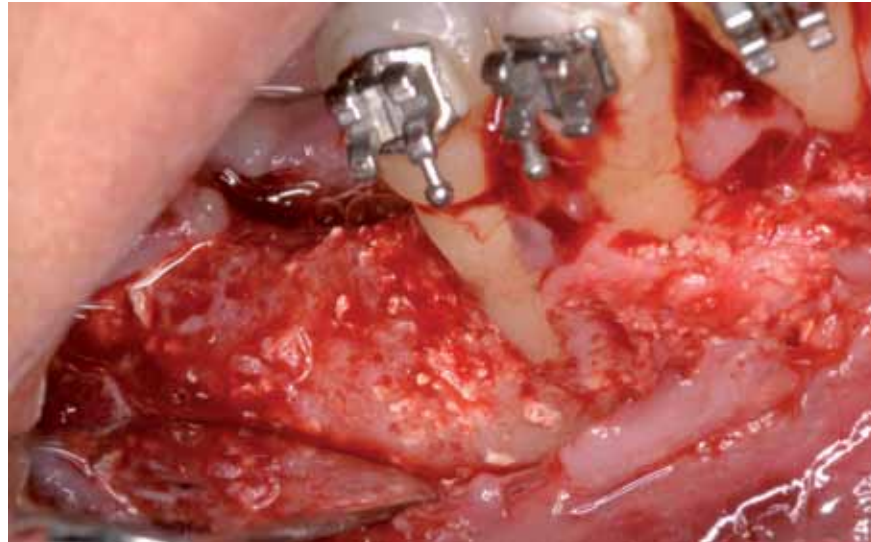


Fig. 2: Six months after surgery, one osteointegrated implant (BIOMET 3i) in the augmented area is placed. A regeneration of the bony fenestration on tooth #42 was also evident, while the control #44 remained unchanged.

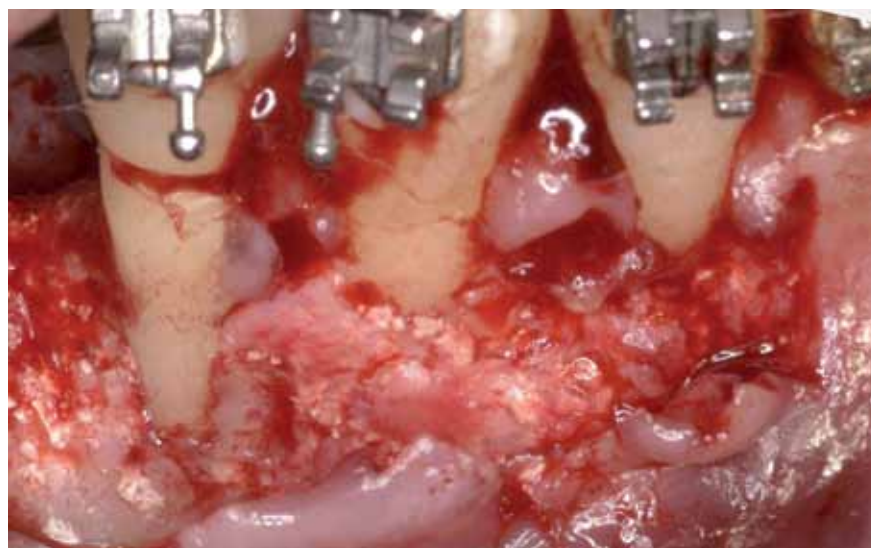


Fig. 3: Appropriate implant placement requires orthodontic movement.

need for implants and/or periodontal treatment and bone augmentation. In these cases especially, efficient interdisciplinary collaboration may result in a great benefit for the patients.⁵⁻¹²

Periodontally accelerated orthodontic movement, as described by Wilcko, appears particularly feasible in those multidisciplinary cases for which treatment planning requires orthodontic movement and oral or periodontal surgery. In these cases, corticotomy can be combined with wisdom tooth extraction and/or a regenerative technique, such as guided bone regeneration (GBR), in order to avoid multiple surgeries.

Recently some orthodontic therapies, especially the so-called low-friction therapies, have demonstrated clinically and radiographically that it is possible to expand dental arches without interfering with periodontal health, by augmenting the alveolar bones.

Melsen et al.¹⁵ confirmed what

was previously suggested, that the tooth will move with the bone and not in bone, especially when light orthodontic forces are applied. Dehiscence and fenestration, which are difficult to diagnose preoperatively, may represent a limitation of this technique. Because the tooth will move with the periodontium, in cases in which the periodontium is not present, we might create recession and attachment loss.¹⁴ A recent study on modern American skulls found that a dehiscence was present in 40.4 percent of the skulls, and a fenestration was present in 61.6 percent of skulls.¹⁵

If this data is translated in clinical treatment, it may mean that potentially at least 50 percent of orthodontic patients undergoing expanding movement could be at risk of gingival recession and periodontal damage. It would be advisable, then, to introduce routine 3-D X-rays into

→ **IT** page 4

IMPLANT TRIBUNE

The World's Newspaper of Implantology - U.S. Edition

Publisher & Chairman

Torsten Oemus
t.oemus@dental-tribune.com

Chief Operating Officer

Eric Seid
e.seid@dental-tribune.com

Group Editor & Designer

Robin Goodman
r.goodman@dental-tribune.com

Editor in Chief

Sascha A. Jovanovic, DDS, MS
sascha@jovanoviconline.com

Managing Editor/Designer

Implant, Endo & CAD/CAM Tribunes
Sierra Rendon
s.rendon@dental-tribune.com

Managing Editor/Designer

Ortho Tribune & Show Dailies
Kristine Colker
k.colker@dental-tribune.com

Online Editor

Fred Michmershuizen
f.michmershuizen@dental-tribune.com

Account Manager

Humberto Estrada
h.estrada@dental-tribune.com

Marketing Manager

Anna Wlodarczyk
a.wlodarczyk@dental-tribune.com

Marketing & Sales Assistant

Lorrie Young
l.young@dental-tribune.com

C.E. Manager

Julia Wehkamp
j.wehkamp@dental-tribune.com

International C.E. Sales Manager

Christiane Ferret
c.ferret@dtstudyclub.com

Dental Tribune America, LLC
116 W. 23rd St., Suite #500
New York, NY 10011
Phone: (212) 244-7181, Fax: (212) 244-7185

Published by Dental Tribune America

© 2011 Dental Tribune America.
All rights reserved.

Dental Tribune makes every effort to report clinical information and manufacturer's product news accurately, but cannot assume responsibility for the validity of product claims, or for typographical errors. The publishers also do not assume responsibility for product names or claims, or statements made by advertisers. Opinions expressed by authors are their own and may not reflect those of Dental Tribune International.

Editorial Advisory Board

Dr. Sascha Jovanovic, Editor in Chief

Dr. Bernard Touati

Dr. Jack T. Krauser

Dr. Andre Saadoun

Dr. Gary Henkel

Dr. Doug Deporter

Dr. Michael Norton

Dr. Ken Serota

Dr. Axel Zoellner

Dr. Glen Liddelou

Dr. Marius Steigmann

**Tell us
what
you
think!**

Do you have general comments or criticism you would like to share? Is there a particular topic you would like to see more articles about? Let us know by e-mailing us at feedback@dental-tribune.com. If you would like to make any change to your subscription (name, address or to opt out) please send us an e-mail at database@dental-tribune.com and be sure to include which publication you are referring to. Also, please note that subscription changes can take up to 6 weeks to process.

IT Corrections

Implant Tribune strives to maintain the utmost accuracy in its news and clinical reports. If you find a factual error or content that requires clarification, please report the details to Managing Editor Sierra Rendon at s.rendon@dental-tribune.com.



infinite possibilities

coming your way from ACE

For more information, visit us at the AAOMS meeting.

Philadelphia • 9.15.2011 • Booth #418



ACE Surgical Supply Co., Inc. • 1.800.441.3100 • acesurgical.com

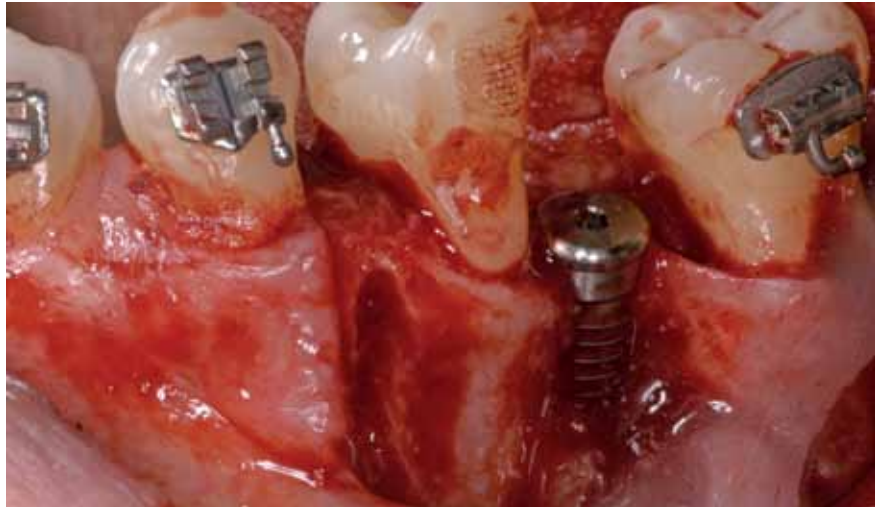


Fig. 4: At the time of implant placement, a corticotomy is performed to accelerate the orthodontic movement and facilitate the implant restoration. Regeneration with a first layer of autologous graft collected during site preparation, covered with xenograft and a resorbable membrane (Endobone and Osseoguard, BIOMET 3i), was performed simultaneously.

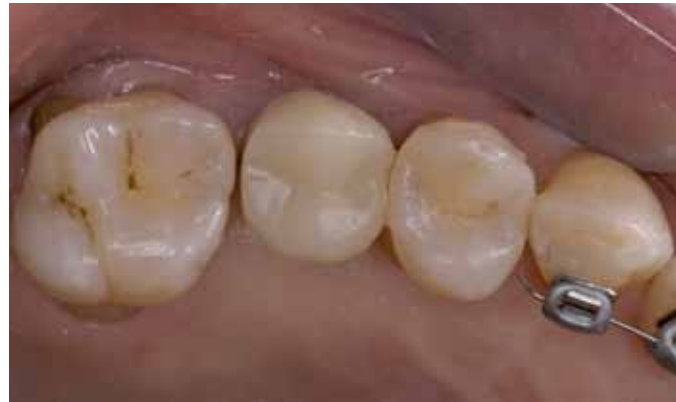

Fig. 5: Provisional restoration in place.

← **ii** page 2

the preoperative work-up (i.e., cone beam).

The cone-beam examination, with a reduced dose of radiation compared with the fan beam (CT scan) and better definition,¹⁶ could be used

routinely in those patients with a thin, scalloped periodontium, where the risk of post-operative recessions is higher. The PAOO technique has been found not only to be predictable in solving dehiscence and fenestration above the roots,¹⁷ but also to produce a noticeable change in the cephalometric analysis of points A and B.¹⁷ With the PAOO technique, the patient needs to be seen routinely for changing the wires, as the teeth movements are much faster than in regular orthodontic treatment. The use of segmental corticotomy (applied only to the teeth that have to move more than the others) can dramatically change the relationship amongst groups of teeth.¹⁸

This has to be kept in mind because it may require changes in distributing the anchorage by the orthodontist. The teeth in the area of surgery will be moving much faster than the other teeth.

Conclusions

When the treatment plan requires orthodontic movement and oral or periodontal surgery, corticotomy can be combined with a wisdom tooth extraction and/or a regenerative technique, such as GBR, in order to avoid multiple surgeries and to optimize the final outcome for the patient.

Another indication is for instances in which the risk of creating root dehiscence in patients with thin periodontium is very high even with slow orthodontic movement and light forces applied. Root recession can be present even without clinical manifestation of gingival recession. An efficient multidisciplinary approach to a complex case may result in a faster and better treatment. The PAOO technique can be used for faster dental movement, to treat and prevent periodontal problems and to regenerate ridge defects, allowing implant placement. **ii**

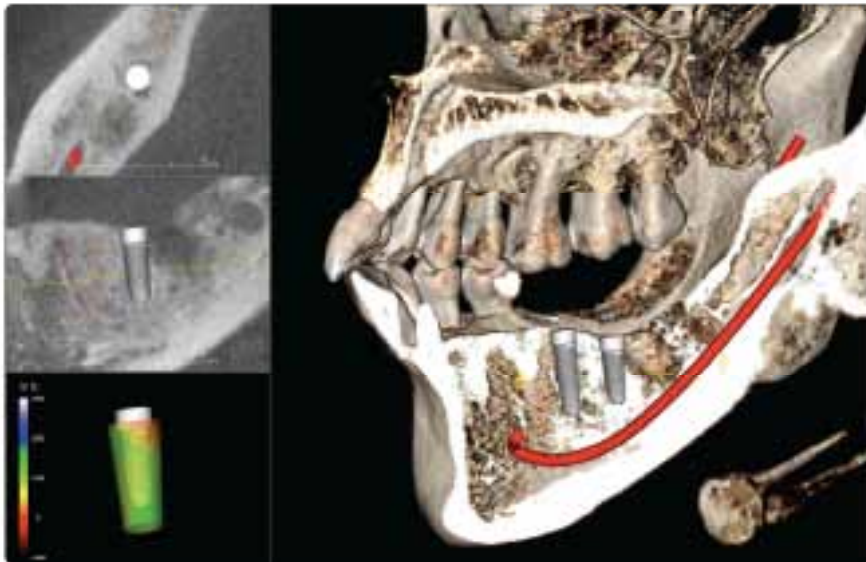
Editorial note: A list of references is available from the publisher.

AD

Implant Planning in 20 Seconds

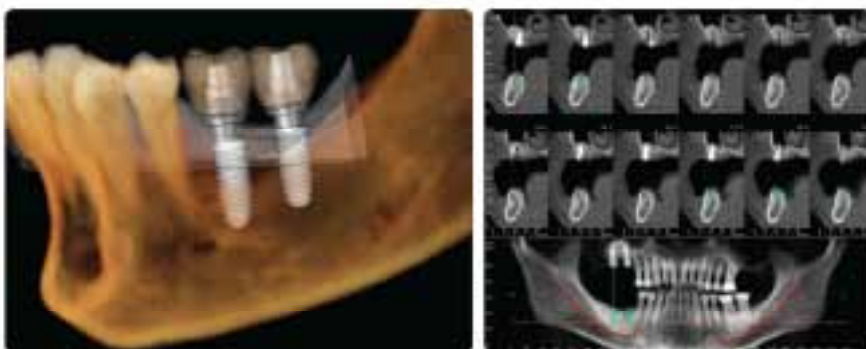Visit us at the
AAOMS Annual Meeting
Booth #1054

with **Invivo5**



High quality 3D Implant planning system from CA, USA.

- Extremely fast and easy
- High quality and accurate visualizations
- No conversion, pre-processing, or preparation
- Software developed from Silicon Valley, California
- Surgical Guide made from California
- Expert support provided from California



Find out why so many doctors choose Invivo5. Call for a demonstration today!



www.anatimage.com Tel. 408-885-1474 Fax 408-295-9786 111 N. Market St. #800 San Jose, CA 95113

Anatimage

ii Contact

Federico Brugnamì, DDS
Piazza dei prati degli Strozzi 21
00195 Roma, Italy
Tel.: +39 06 39730191
Fax: +39 06 39730195
fbrugnamì@gmail.com

Alfonso Caiazzo, DDS
Private practice, Salerno, Italy

Adapting with nature

OsseoSpeed™ TX Profile – anatomically designed implants for sloped ridges

Imagine being able to achieve 360° bone preservation around the implant, also in cases with sloped ridges. Now you can.

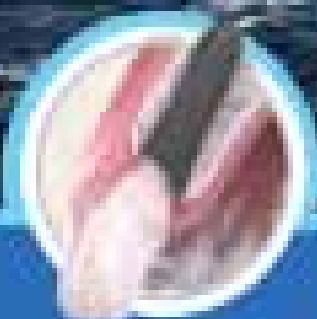With OsseoSpeed™ TX Profile – a uniquely shaped, patented implant, specifically designed for sloped ridge situations – you no longer have to choose between buccal and lingual recipient bone preservation and aesthetics, you can have it all – 360° around the implant.

As with all Astra Tech implants, OsseoSpeed™ TX Profile is based on the documented key features and benefits of the Astra Tech BioManagement Complex™. Used in combination with patient-specific Adaptic™ Abutments, you and your patient can look forward to long-term function and pleasure.

For more information, please visit www.astratechdental.com



Visit us at booth #920 at the AAOHNS annual meeting to learn more.



 **ASTRATECH
DENTAL**
EST. 1988

ASTRA
ASTRATECH

 A company of the
Astellera Group

800.537.5281 • www.astratechdental.com

ICOI Seoul

ICOI World Congress XXVIII

6-9 October, 2011 | Coex, Seoul, Korea

- Congress Co-Chair_ Dong-Seok Sohn(Korea), Carl E. Misch(USA)
- ICDI President_ Hom-Lay Wang(USA)
- ICDI Korea President_ Chang-Yeon Shin
- Program Chair_ Su-Gwan Kim(Korea)
- ICDI Co-Chair_ Kenneth W.M. Judy(USA), Carl E. Misch(USA)

Invited Speakers

- | | | |
|-----------------------------|--------------------------------|--------------------------------------|
| + Carl Misch (USA) | + Kyong-An Joe (Korea) | + Shih-Chang Twong (Taiwan) |
| + Chen Zhuofan (China) | + Kyo-Sung Cho (Korea) | + Shota Makoto (Japan) |
| + Douglas Deporter (Canada) | + Marius Steigmann (Germany) | + Stephen Chu (USA) |
| + Erika Benavides (USA) | + Maurice Salama (USA) | + Tae-ju Ch (Korea) |
| + Giulio Rasperini (Italy) | + Mitsuhiro Tsukibashi (Japan) | + Trikol Mekaywongnanonth (Thailand) |
| + Hom-Lay Wang (USA) | + Mohammad Ketabi (Iran) | + Tulio Valcanalis (Brazil) |
| + Hyun Jun Jeon (Korea) | + Myron Nevins (USA) | + William Giannobile (USA) |
| + Jim Yuan Lai (Canada) | + Myung-Jin Kim (Korea) | + Yoshiharu Hayashi (Japan) |
| + Keith Doonan (Australia) | + Pablo Galindo-Moreno (Spain) | |
| + Runkiko Teranishi (Japan) | + Scott Carr (USA) | |



← **IT** page 1

limited to the nutritional supplements, those who had scaling and root planning and those who had local antibiotics added to their scaling and root planning procedures. At 30 days, the pocket depth and gingival index were measured for the three groups with those receiving the nutritional supplements without any further treatment showing a significantly reduced pocket depth compared to the two other groups.

Double-blind studies represent the highest form of proof in evidence-based research and the conclusions must include the following:

1. The proper nutritional supplements improve the health status of the periodontium.
2. The improvement must be systemic in nature since no local remedies were applied and where they were applied in the two other groups the results were not as successful.
3. Given the systemic improvement in what we traditionally treat as a local problem, we have to assume that the local manifestation of a compromised periodontium is at least in part caused by systemic conditions.
4. We must consider the probability that many diseases are at least partially exacerbated if not caused by a lack of proper nutrition.

In addition to the two studies presented here, there are literally hundreds of other studies showing the effect of nutritional status on health as it relates to macular degeneration, diabetes, cancer, heart disease, lung disease as well as the general state of aging.²

While much of this is known, there is little compliance among the general population to take the necessary blood tests to determine one's nutritional status. One can know what the proper thing is to do, but for a large segment of the population, avoiding needles will trump the common sense of drawing blood. And, as a result, we remain uninformed.

Today, however, technology allows the nutritional status of a patient to be determined non-invasively in less than 90 seconds using a blue laser light directed at the skin in the hand. This technology, called Raman spectroscopy, led to the development of the biophotonic scanner that accurately measures the carotenoids in the skin.

Carotenoids have been shown to be a measure of nutritional health from a plethora of studies.³ Carotenoids are an accurate reflection of a patient's overall antioxidant status, and antioxidants have, in turn, been shown to be the protectors of our organs on both the cellular and DNA level.

Basically, our degenerative aging process is thought to result from an accumulation of damage done to our DNA and cells by the continuous attacks of free radicals (reactive oxygen species). They are called



Fig. 1: Biophotonic scanner. (Photos/ Provided by Dr. Barry L. Musikant)

free radicals because they are missing an electron in their outer shell and will attack any other atom or molecule to get one, damaging (oxidizing) it in the process. Antioxidants, as the name suggests, pre-

vents this oxidation by contributing electrons to these free radicals, neutralizing their destructive behavior in the process. Now, life is a balance. We do produce many of our own antioxidants, but not all. Some must come from exogenous sources such as fruits and vegetables.

Many of these antioxidants come from the various highly colored fruits we eat, such as carrots, red and yellow peppers, and the greater their concentration in our blood, the more protection they offer both as antioxidants in their own right, but also as protectors of the endogenous antioxidants we produce ourselves.

To sum up, at this point we have strong correlation between one's nutritional status and the level of carotenoids in our skin as measured by the biophotonic scanner. We

also now have a tool that we can use to determine whether or not the supplements we may be taking are effective. How many of us have taken one nutritional supplement after another without a clue to their effectiveness and then we just switch to another supplement that garners attention in the news or simply drop what we had been taking?

I will tell you from personal experience that one can be quite cavalier about one's nutritional status until you take the scanner test and get a low score. Knowing the correlation between low antioxidant levels and the increased propensity for degenerative diseases to express themselves, it is logical that most of us would want to change that status as

→ **IT** page 9

AD

Treat small spaces with confidence






Image courtesy of Michael Reppig, DDS Image courtesy of Gary Shapiro, DDS

Introducing the Laser-Lok® 3.0 implant

Laser-Lok 3.0 is the first 3mm implant that incorporates Laser-Lok technology to create a biologic seal and maintain crestal bone on the implant collar*. Designed specifically for limited spaces in the esthetic zone, the Laser-Lok 3.0 comes with a broad array of prosthetic options making it the perfect choice for high profile cases.

- Two-piece 3mm design offers restorative flexibility in narrow spaces
- Implant design is more than 20% stronger than competitor implant²
- 3mm threadform shown to be effective when immediately loaded³
- Laser-Lok microchannels create a physical connective tissue attachment (unlike Sharpey fibers)⁴

For more information, contact BioHorizons
Customer Care: 888.246.8338 or
shop online at www.biohorizons.com



BIOHORIZONS®

SCIENCE • INNOVATION • SERVICE

1. Radiographic Analysis of Crestal Bone Levels on Laser-Lok Collar Dental Implants. CA Shapiro, G Leiby, PA Weyers, DM Rice, IPRO, Vol 30, No 2, 2010.
 2. Implant strength & fatigue testing done in accordance with ISO standard 7461.
 3. Initial clinical efficacy of 3-mm implants immediately placed into function in conditions of limited spacing. Teddy WS, Offord S, Hagh S, Apaza-Vikson R, Szucs RC, Int J Oral Maxillofac Implants. 2008 Mar-Apr;23(1):201-209.
 4. Human Histologic Evidence of a Connective Tissue Attachment to a Dental Implant. W Boyles, JG Hines, M Carrozzini, E Boyapati, DM Rice, International Journal of Periodontics & Restorative Dentistry, Vol. 20, No. 2, 2000.

©BIOHORIZONS INC 2010

Academy of Osseointegration

27th Annual Meeting


Technology to Practice



Phoenix

March 1-3, 2012

Phoenix Convention Center



← **IT** page 7

rapidly as possible, especially after we have passed the stage where we still think we are immortal. It is unlikely that most of us have the discipline to instantaneously make a major change in diet and life style. More likely to produce the sought-after results is the use of supplements as recommended by the nutritional company that developed the scanner to aid us in attaining a better nutritional status, one that can be measured periodically by the same biophotonic scanner that told us of our deficiencies.

That is exactly the route I have taken, and during the past three months, my nutritional score has tripled. I am still not where I want to be, but I am on a road that shows continuous progress. Of equal importance, the biophotonic scanner is a motivator for maintaining good nutritional status. I have also noticed that over time, at least with me, it is a tool that produces behavioral modifications. I find myself eating more fruit and vegetables, less fried food and consuming far less sugar. So far, each time I have been scanned, my scores have gone up.

We all wear several hats in the course of our lives. One hat I wear in addition to being an endodontist is a producer of innovative dental products, particularly in the field of endodontics. However, I cannot help but see the advantages to any dental practice that would incorporate the biophotonic scanner as an initial means of determining the nutritional status of their patients. If you see a patient who displays periodontal disease⁴ and that patient correlates with a low nutritional score, both you and the patient will gain from a regimen of supplements that research has clearly shown to

A	50,000 to 100,000+ =	Optimal
B	40,000 to 49,000 =	Good
C	30,000 to 39,000 =	Moderate
D	20,000 to 29,000 =	Weak
F	10,000 to 19,000+ =	Poor

Fig. 2: Scores from the biophotonic scanner. An optimal reading begins at 40,000.

improve these conditions even without local therapy being initiated.

As an added motivator, research has clearly shown that damage to the same gene can adversely effect one's periodontal state as well as one's cardiac health. With the knowledge that free radicals damage the genes

comprising our DNA, we may be doing much more for the patient than we realize. We are certainly doing no harm.

Data has shown that our patients are far more likely to visit us than a physician. It has also been stated that more than 90 percent of the dis-

eases that affect us display oral signs and symptoms.⁵⁻⁷ We can take advantage of the technological advances that now allow us to determine our patients' level of antioxidants to make recommendations to them for an improvement of their nutritional status and to monitor them for the improvements that are sure to come.

There is so much more to this story, but if this short article stirs some interest in you, please contact Victoria Reina at vreina@edsdental.com for more information and, if so desired, a biophotonic scan for yourself. That's where it started for me, and I want to extend these benefits to as many people as possible. I hope every dentist who reads this article sees the great possibilities for doing good, both for your patients and yourself. **IT**

AD

IT About the author



Dr. Barry Lee Musikant is a member of the American Dental Association, American Association of Endodontists, Academy of General Dentistry, The Dental Society of N.Y., First District Dental Society, Academy of Oral Medicine, Alpha Omega Dental Fraternity and the American Society of Dental Aesthetics. He is also a fellow of the American College of Dentistry (FACD). As a partner in the largest endodontic practice in Manhattan, Musikant's 35-plus years of practice experience have established him as one of the top authorities in endodontics.

One implant system for all your needs.

One implant body, three connections.

Treatment simplicity with one drill protocol.

Most widely used implant system in the world.¹

PREVIEW

With platform shift and conical connection
Launch in fall 2011

It's called NobelReplace. Whether you are a new or experienced implant user, this original tapered implant mimicking the shape of a natural tooth offers you a safe and reliable solution for every indication. The color-coded surgical and prosthetic components and the standardized step-by-step drill protocol ensure ease-of-use and predictable outcomes. Depending on indication and your personal preference, choose between the internal tri-channel connection with or without platform shifting for unrivalled tactile feel and the strong sealed conical connection with built-in platform shifting. After 45 years as a dental innovator we have the experience to bring you future-proof and reliable technologies for effective patient treatment. **Their smile, your skill, our solutions.**

Call 800 322 5001 or visit nobelbiocare.com/nobelreplace

Nobel Biocare USA, LLC, 20715 San Ranch Parkway, Yorba Linda, CA 92682 Phone 714.282.4400 Toll free 800.983.8100 Tech. support 888.735.7451 Fax 714.282.9422
 Nobel Biocare Canada, Inc. 8133 Leslie Street, Unit 100, Richmond Hill, ON L4B 4N1 Phone 905.762.3800 Toll free 800.608.8284 Fax 905.762.4343
 © Nobel Biocare Services AG, 2011. All rights reserved. Nobel Biocare, the Nobel Biocare logo and all other trademarks are, if nothing else is stated or is evident from the context in a certain case, trademarks of Nobel Biocare, Döckumet. Some products may not be regulatory cleared/registered for sale in all markets. Please contact the local Nobel Biocare sales office for current product information and availability.
 1 Source: IMB Research Group, 2 Dental Product Shopper voted NobelReplace Tapered Best Product 2011, www.dentalproductshopper.com/nobelreplace