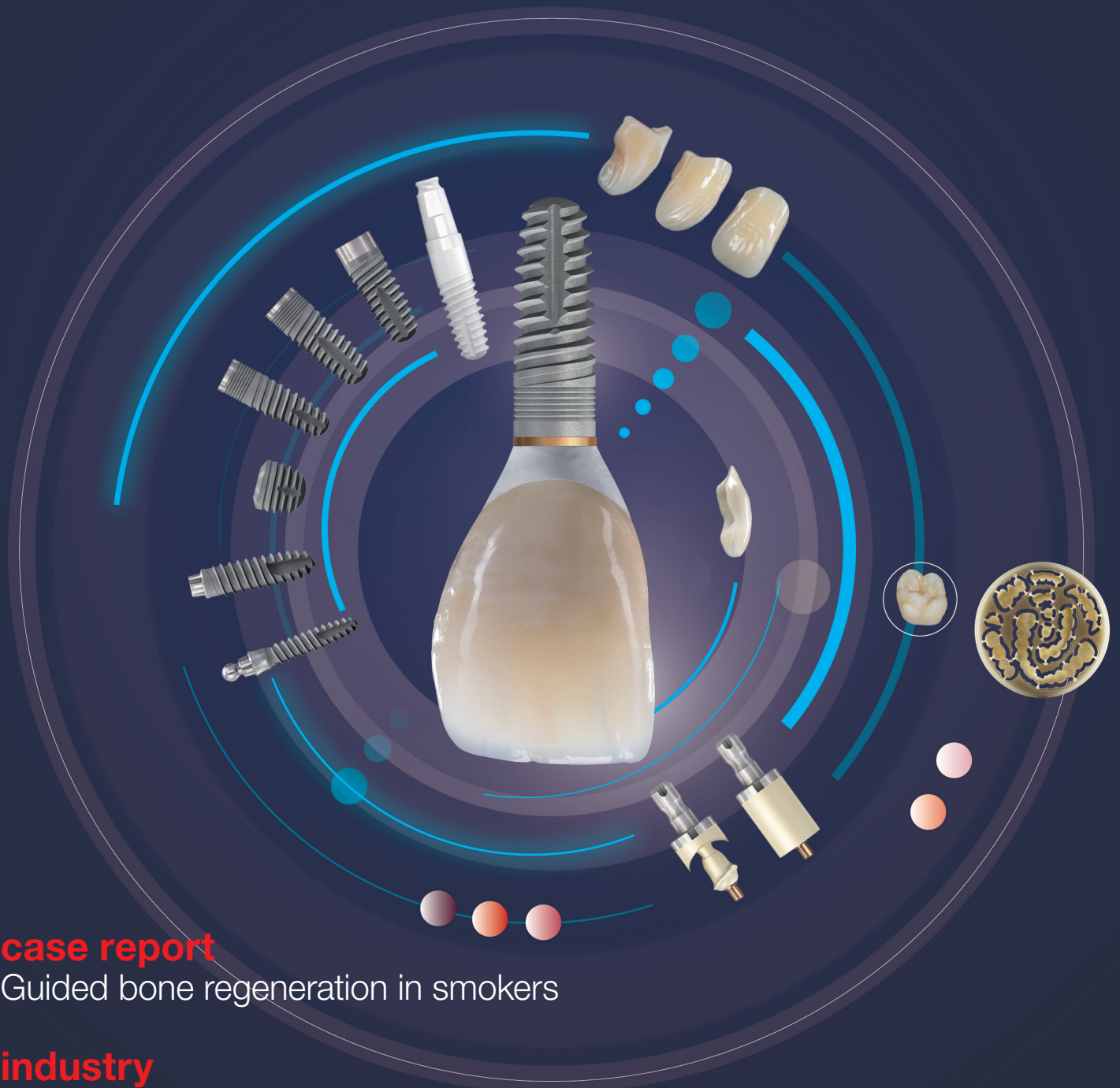


implants

international magazine of oral implantology



case report

Guided bone regeneration in smokers

industry

Dynamic navigation by innovative registration

events

Academy of Osseointegration Annual Meeting 2018

There's no shortcut to excellence.
You need to pass through Berlin.



Focus on implant dentistry— International Congress on Ankylos 2018

It's no coincidence that Ankylos is renowned for high performance and long-lasting esthetic results. Together with you, we've been on a long journey to develop and refine Ankylos. For 33 years to be exact.

And we are not stopping now. In fact, we would like you to join us in Berlin for a look at what we have accomplished so far and how we can take it even further.

- 36 renowned international speakers
- 14 focus sessions
- 5 plenary sessions
- 3 Poster & Video Awards categories
- 1 unforgettable congress

Mark **June 29-30** in your calendar and register today for inspiring days with Focus on implant dentistry—International Congress on Ankylos 2018 at the Estrel Congress Center in Berlin, Germany.

Trust experience. Discover excellence.



Scientific Chairman
Dr. Paul Weigl
University of Frankfurt am Main



For all the latest information and to register:
ankyloscongress.com
#Ankylos



 **Dentsply
Sirona**
Implants

Dr Rolf Vollmer

First Vice President and Treasurer of DGZI



Dental implantology— the “third” chance for patients

In dentistry, implantology and oral surgery are one of the few disciplines dealing with the presumably hopeless cases. Patients have insufficient oral health due to their own neglect or serious illnesses. The daily quality of life is reduced as a result of unstable prosthetics, insufficiently treated bounded saddles and a general functional insufficiency. These health issues place an excessive psychosocial burden on many affected patients. Dentists dedicated to dental implantology are, in fact, the last hope to provide help in such cases.

Modern implantology and its individually adaptable implant prosthetics offer patients a “third” chance to integrate a fixed dentition. The restoration of single teeth, fixed complete prostheses on either four or six implants in the fully edentulous maxilla or mandible and guided bone regeneration plus soft-tissue management are just some examples of the implantological repertoire.

In addition, thorough backward planning by digital workflows and navigated surgery—may it be dynamic/virtual or by drilling template—expands this repertoire. You will find some examples how these techniques are applied in this issue.

We owe it to our patients to implement the best available solution and methods. Thus, further education is a must—either at the implantological meetings and/or by thoroughly studying specialist magazines like this one. The research articles, case reports and congress reviews

of this issue of *implants—international magazine of oral implantology* shall present you more ideas and solutions enabling you to treat your patient even better.

In addition, I would like to invite you to our **48th DGZI annual congress on the 28 and 29 September in Düsseldorf, Germany**. For the first time the meeting is taking place as “Future Congress for Dental Implantology”. According to its theme “Visions in Implantology” we will focus on future developments in dental implantology expected for the next ten coming years.

We, the DGZI, will once again set new standards in quality and latest topics of implantological education. Live streams of surgeries from chosen competence centres in Germany will be presented. The future podium and interactive table clinics are highlights of the main programme on Friday and a highly scientific presentation programme will wait for you on Saturday.

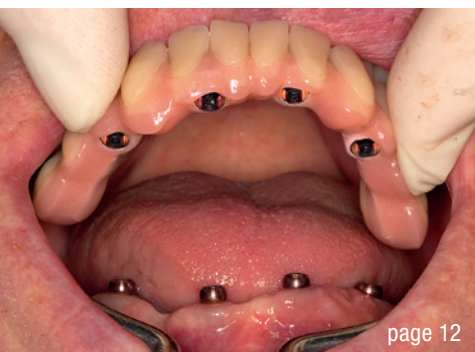Register now and provide your patients with the best “third” chance. We look forward to welcoming you in Düsseldorf.

With best wishes for the upcoming semester,

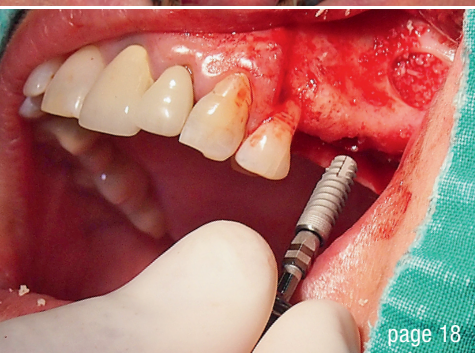
Yours,

A handwritten signature in black ink, appearing to read 'R. Vollmer'.

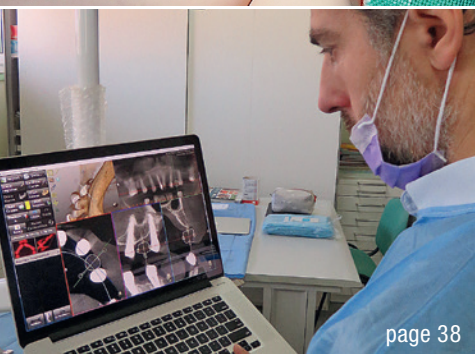
Dr Rolf Vollmer



page 12

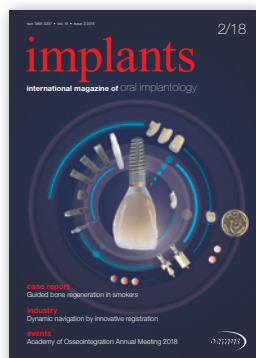

page 18



page 38

Cover image courtesy of bredent medical GmbH & Co. KG www.bredent-medical.com



editorial

Dental implantology—the “third” chance for patients 03
Dr Rolf Vollmer

research

L-PRF in different intraoral applications (Part II) 06
Prof. Nelson R. Pinto, Dr Andy Temmerman, Ana B. Castro, Simone Cortellini, Prof. Dr Wim Teughels & Prof. Dr Marc Quirynen

case report

Fixed complete prosthesis with no screws and no cement 12
Dr Karl-Ludwig Ackermann, Gerhard Neuendorff & Janez Fiderschek

Biomechanical considerations in solving demanding cases 18
Dr Juraj Brozović & Barbara Mikulić

Mandibular dental reconstruction 26
Dr Lyndon Cooper, Dr Ghadeer Thalji, Dr Carly Park & Lee Culp

Guided bone regeneration in smokers 30
Dr Dr Branislav Fatori & Dr Inge Schmitz

Implant digital workflow opportunities 34
Dr Ross Cutts

industry

Dynamic navigation by innovative registration 38
Dr Ricardo Henriques

Bone loss around tapered implants with split coronal microthreads 42
Drs Jerry Kohen, Tal Bar, Sorin Moscovici & Prof. Ofer Moses

events

Oral Reconstruction **Global Symposium 2018** 48
Katharina Rühling

Discovering **new horizons** 50

Academy of Osseointegration **Annual Meeting 2018** 52
Dr Mohamed Awwad

news

manufacturer news 44

news 56

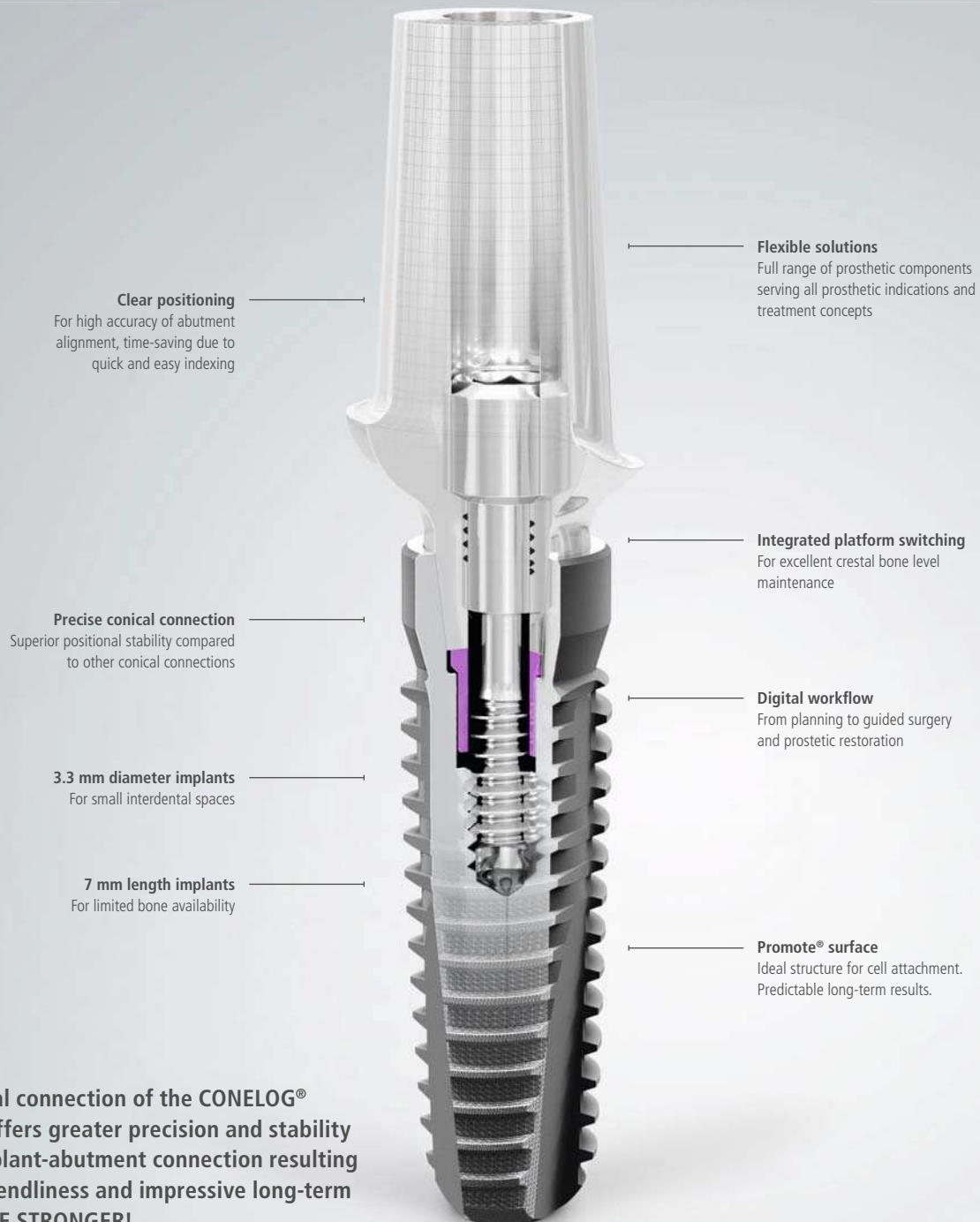
about the publisher

imprint 58

TRULY CONICAL PRECISION

CONOLOG[®]
SYSTEM

BE STRONGER!



Clear positioning

For high accuracy of abutment alignment, time-saving due to quick and easy indexing

Flexible solutions

Full range of prosthetic components serving all prosthetic indications and treatment concepts

Precise conical connection

Superior positional stability compared to other conical connections

Integrated platform switching

For excellent crestal bone level maintenance

3.3 mm diameter implants

For small interdental spaces

Digital workflow

From planning to guided surgery and prosthetic restoration

7 mm length implants

For limited bone availability

Promote[®] surface

Ideal structure for cell attachment. Predictable long-term results.

The conical connection of the CONOLOG[®] implant offers greater precision and stability of the implant-abutment connection resulting in user friendliness and impressive long-term success. BE STRONGER!



Read more here:
www.camlog.com/en/whitepaper-conelog

a perfect fit[™]

camlog

L-PRF in different intraoral applications

Part II: Open-flap debridement & ridge preservation

Prof. Nelson R. Pinto¹, Dr Andy Temmerman², Ana B. Castro², Simone Cortellini², Prof. Dr Wim Teughels² & Prof. Dr Marc Quirynen²

¹ Department of Periodontology and Oral Implantology, Faculty of Dentistry, Universidad de Los Andes, Santiago, Chile

² Department of Oral Health Sciences, Section of Periodontology, KU Leuven & Dentistry, University Hospitals, KU Leuven, Leuven, Belgium

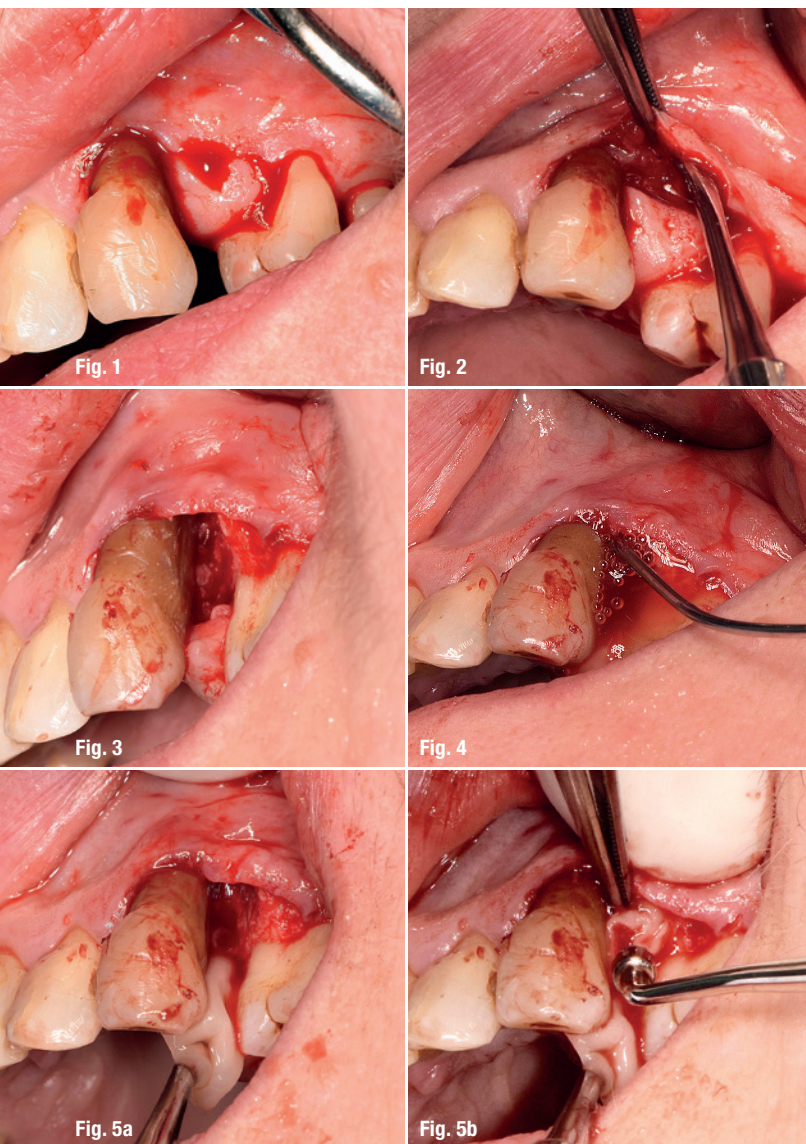


Fig. 1: Intrasulcular incision with papilla preservation. **Fig. 2:** Minimal flap elevation (palatally pediculated). **Fig. 3:** Defect after root planing. **Fig. 4:** Rinsing intrabony defect with L-PRF exudate. **Figs. 5a & b:** Application of chopped L-PRF membranes into the defect (preferably face side towards the bone).

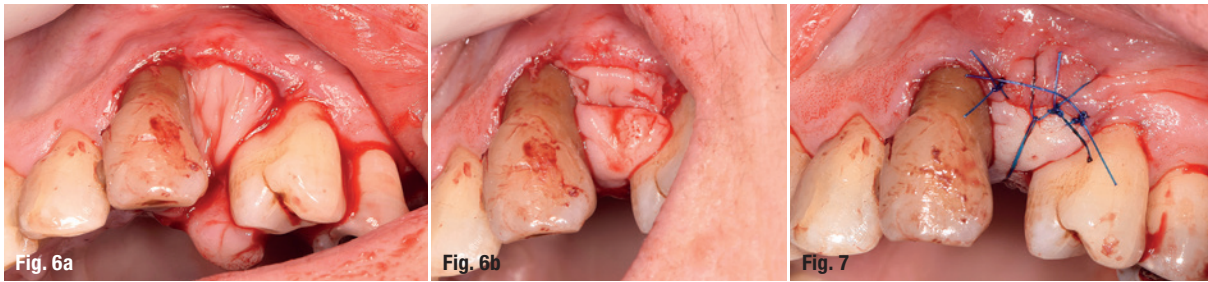
Recent research clearly indicates that wound healing in both soft and hard tissue can be significantly enhanced by L-PRF (leukocyte- and platelet-rich fibrin). This second generation of platelet concentrates may even have the potential to replace substitutes like growth factors and biomaterials in many situations. A further benefit is its easy and inexpensive preparation, lowering the treatment cost also for the patient.

Major indications for the use of L-PRF and the step-by-step preparation of L-PRF clots, membranes and plugs were introduced in the first part of this article series in *implants 1/18*.

In this second part, two treatment approaches for platelet concentrate protocols will be presented. The focus will be on L-PRF application in the regeneration of intrabony defects during open-flap debridement and in ridge preservation.

L-PRF in treatment of periodontal and/or bone defects

The use of L-PRF in the treatment of periodontal and/or bone defects can be described as natural tissue regeneration and natural bone regeneration, by analogy to guided tissue regeneration and guided bone regeneration. With natural tissue regeneration and natural bone regeneration the defect is filled with L-PRF—optionally combined with a biomaterial, to prevent collapse—and sealed with L-PRF membranes. These membranes have a protective function (induction of the periosteum) and serve as a competitive barrier. Epithelium and connective tissue are kept away from the intrabony crater so that the cells of the periodontal ligament or periosteum have the time to regenerate cementum, bone and ligament. These cells can also migrate through the membranes, which results in rapid neo-angiogenesis. L-PRF also promotes the proliferation and differentiation of osteoblasts and bone marrow stromal cells *in vitro*.



Figs. 6a & b: Coverage of bony defect with two or more layers of L-PRF membranes. **Fig. 7:** Tension-free flap suturing, preferably with primary closure of the interdental papilla.

This stimulation appears to be dose-dependent with leucocytes playing a key role.¹

A series of clinical studies has evaluated the benefits of applying L-PRF alone during open-flap debridement.² They all reported an adjunctive improvement when L-PRF was used, on parameters like probing pocket depth reduction (1.1 ± 0.5 mm extra reduction), clinical attachment gain (1.2 ± 0.6 mm extra gain) and bone defect fill (1.5 ± 0.3 mm or $46 \pm 12.8\%$ extra bone fill).²

In some studies, L-PRF was combined with a bone substitute, and even here an additional benefit could be

observed.² When L-PRF was compared with enamel matrix proteins, similar improvements were reported.²

Step-by-step approach for regenerative treatment of intrabony defects with L-PRF

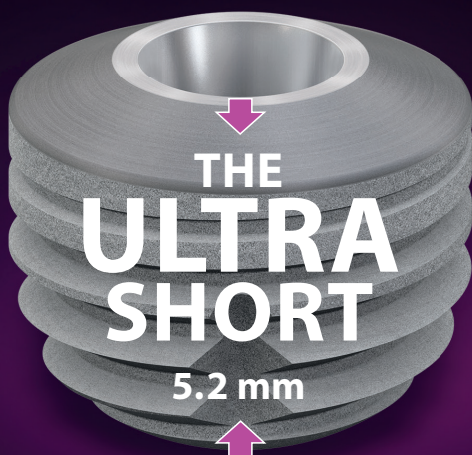Protocol for L-PRF as sole biomaterial for intrabony defect regeneration during open-flap debridement

- Intrasulcular incision with maximal preservation of gingival complex (Fig. 1).
- Minimal flap elevation and degranulation of intrabony defects (Fig. 2).
- Optimal root planing (Fig. 3).

AD

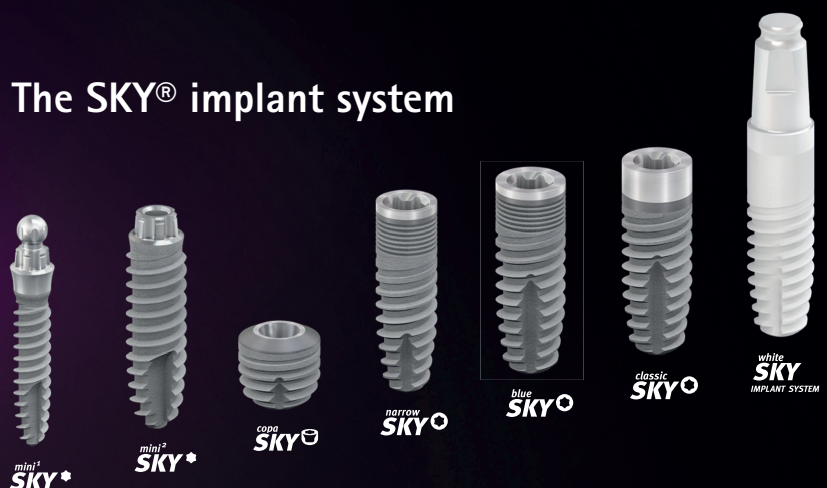
New options!

The ultra-short implant for optimum exploitation of the available bone



| Primary stable | Precise | Physiological

The SKY® implant system



- Rinsing defect with L-PRF exudate (collected at the bottom of the Xpression box [Intra-Lock International] after compressing the clot; Fig. 4).
- Application of an L-PRF membrane (or only a part of it) into the defect (preferably with the face part of the membrane pointing towards the bone; Figs. 5a & b).
- Coverage of the bone defect with approximately two layers of L-PRF membranes, running ≥ 2 mm over the bony borders underneath the periosteum in order to seal the socket and to force the soft tissue to grow over instead of underneath the membranes (Figs. 6a & b).
- Tension-free flap suturing in seeking to provide primary closure of the interdental papilla (Figs. 7 & 8).

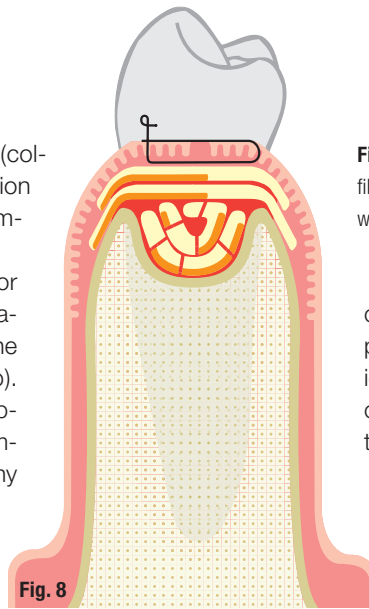


Fig. 8: Graphic representation of an intrabony defect filled with chopped L-PRF membrane parts and covered with L-PRF membranes. Primary closure is not required.

currently on which technique to use for this purpose.³ According to the authors' opinion the use of L-PRF in extraction sockets could be a less costly, simplified and effective treatment alternative.

A recent split-mouth comparison between natural healing of extraction sockets and sockets filled with L-PRF in 22 patients confirmed the above mentioned benefits with significant

less horizontal and vertical resorption, increased socket fill, higher bone quality and faster soft-tissue and bone healing.⁴ This was reported even at sites with bone dehiscences.⁴ The observed reduction in bone resorption was comparable to the best-performing clinical procedures using bone substitutes in combination with connective tissue grafting and/or the placement of a membrane.⁴

Postoperative care

- Soft food intake, no biting/chewing in treated area, no mechanical cleaning of the treated area,
- 0.12% chlorhexidine twice a day for one minute for at least three weeks,
- medication with painkillers, as necessary.

L-PRF for ridge preservation

After tooth extraction and loss of the bundle bone, the alveolar ridge undergoes a remodelling process in both vertical and horizontal directions. This process often complicates the placement of implants in an ideal position. In recent years, many surgical techniques have been developed to prevent, or at least minimise, this bone resorption.

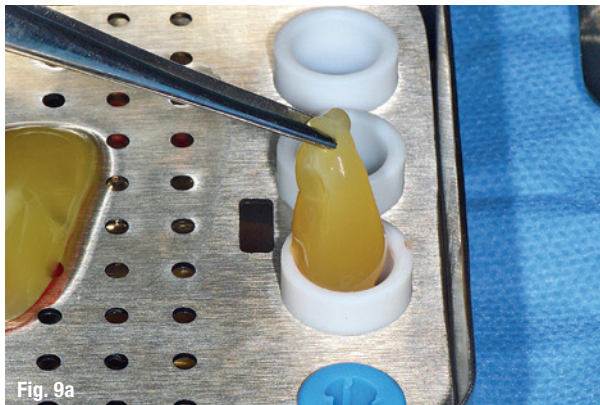
Different bone grafts or bone substitutes have been developed to be used in extraction sockets, with or without the addition of a soft-tissue graft or soft-tissue substitute to seal the alveolus. A recent systematic review by Vignoletti et al., however, concluded that there is no clear guideline

Step-by-step approach for ridge preservation with L-PRF

In this approach, L-PRF is used as a filling material for a tooth socket, aiming at maintaining the alveolar bone dimensions (Figs. 9a & b).

Protocol for ridge preservation with L-PRF

- Atraumatic tooth extraction with maximal preservation of the alveolar bone.
- Accurate removal of inflamed and granulation tissue (if needed with a bur; Fig. 10).
- Preparation of envelope (approx. 2mm in width) between bony borders of the socket and surrounding soft tissue needed to slide in the L-PRF membranes at the end in order to prevent the fast ingrowth of connective



Figs. 9a & b: Preparation of L-PRF plugs with Xpression kit.



GC Implants:
Quality derived
from tradition



GC

www.gctech.eu