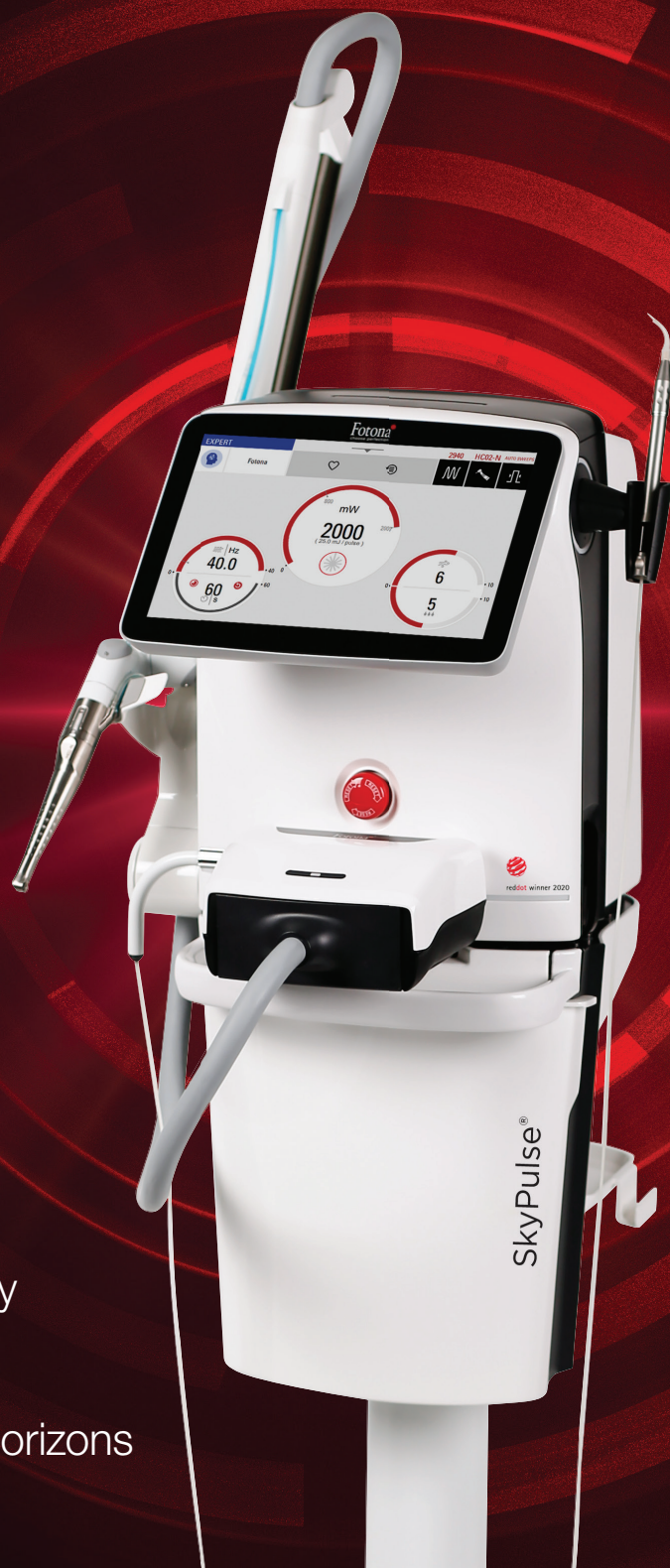

implants

international magazine of oral implantology



industry

New zygomatic
implant design

feature

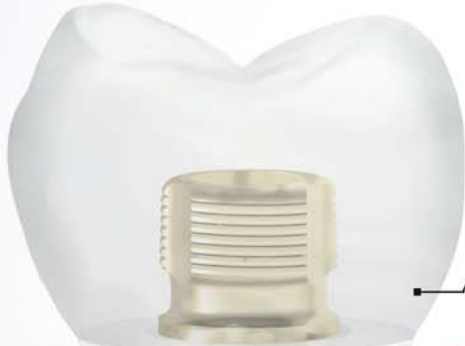The art of ultra-
aesthetic dentistry

DGZI Special

Onward to new horizons



Tissue Level Implants with Zirconia Collar



Digital workflow at
your fingertips

Zirconia crown made by Index
One milling machine

Aesthetic gingival area

Zirconia collar

Gingival integration
& Osseointegration

Bone area

Pure Titanium body



Unique, like your smile

The Z1® implants are medical devices intended for placement in the mouth, in case of partial or total tooth loss, by qualified healthcare professionals. These medical devices are regulated health products which, in accordance with this regulation, bear the CE marking. These dental implants are manufactured in France by Sudimplant SAS, owner of the Z1® trademark. For any information, please contact your dentist.



Find us online
www.tbr.dental

Dr Georg Bach

President of the DGZI



The second half of this year will be **crucial**

Dear readers,

The crisis in the first half of 2020 has forced considerable challenges upon us, which are here to stay for the months and probably years to come. As is the case with many crises, however, there are also opportunities and positive aspects, in contrast to the economic damage and the structural disruptions. We as dentists, together with our teams, are currently doing everything we can to re-establish regular practice routines and to get our patients back into dental care—in accordance with the necessary infection prevention measures, of course. Recent weeks have shown that dentistry has a clear obligation regarding the general health of the population. There is no other medical profession that provides the population in all its variety with such regular care, through dentists working in public clinics and private practices. Especially within the German healthcare system, patients in risk groups, the old and the young, the chronically ill and emergency patients receive reliable dental treatment of the highest standard. After all, oral health plays a crucial part in maintaining the systemic health of patients. Untreated inflammation in the oral cavity, denture pressure points, caries, periodontal disease and other conditions can cause not only adverse situations in the masticatory apparatus but also damage to the entire body.

Dental implantology plays a key role here, being the only dental therapy capable of treating patients of nearly all age groups with a myriad of prosthetic possibilities and

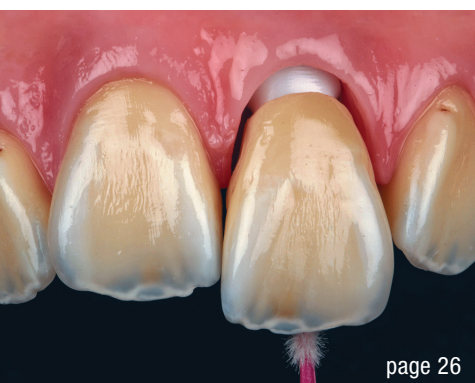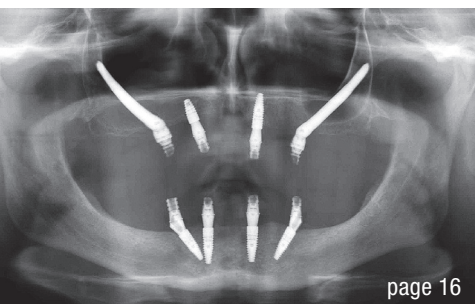
surgical protocols in such an individually tailored and sophisticated way. Undoubtedly, there is a medical necessity for and effectiveness in rehabilitating masticatory function with dental implants, even in high-risk patients. We as professional implantologists should thus continue our efforts with great courage to educate our patients regarding the best possible treatment options even in these challenging times. The second half of this year will be decisive in terms of not only crisis management but also further implantological training. In this light, it is my great pleasure to cordially invite you, on behalf of the German Association of Dental Implantology (DGZI), to Bremen in Germany on 6 and 7 November, for our 3rd Future Congress for Dental Implantology and a celebration of 50 years of DGZI.

With this in mind, I wish you an enlightening read with this new issue of *implants* and a healthy late summer and autumn. I look forward to welcoming you to our special anniversary congress in Bremen, the founding city of DGZI!

Yours,

A handwritten signature in black ink, appearing to be 'G. Bach', written in a cursive style.

Dr Georg Bach



Cover image courtesy of Fotona d.o.o.
www.fotona.com
 Original Background:
 © foxaon1987/Shutterstock.com



editorial

The second half of this year will be **crucial** 03
 Dr Georg Bach

case report

Er:YAG laser scanner for **implant site** preparation 06
 Drs Norberto Berna, Giovanni Olivi, Luca Marigo & Massimo Cordaro
Successful restoration of the maxilla and mandible 12
 Drs Branislav Fatori & Inge Schmitz

industry

New **zygomatic** implant design 16
 Drs Sepehr Zarrine, Carlos Aparicio & Edmond Bedrossian
 More **efficient** workflows for crestal bone preservation 24

feature

The art of **ultra-aesthetic** dentistry 26
 Nasser Shademan

interview

Bringing titanium and zirconia **together** in one implant 28
 An interview with Dr Anders Henningsen

DGZI Special

Onward to new horizons 34
 An interview with Dr Georg Bach
 Reflect on **50 years** of implantology in Bremen this autumn 36
 DGZI news 38

news

manufacturer news 30
 news 40

about the publisher

imprint 42

DEDICAM – EVERYTHING JUST FITS INDIVIDUAL CAD/CAM PROSTHETICS FROM CAMLOG.

DEDICAM PRODUCTS IMPRESS. With an efficient digital workflow and Camlog quality.

EVERYTHING FROM A SINGLE SOURCE. Tailored to your individual needs.

EVERYTHING IS POSSIBLE. Wide range of patient specific products and services from inlays to bars.

EVERYTHING IS EFFICIENT. Open interfaces, precise fabrication and punctual delivery.

EVERYTHING IS COMPREHENSIVE. Wide range of implant manufacturers supported.

Whether implants or tooth-supported prosthetics: at DEDICAM you will find a portfolio that leaves nothing to be desired.

For further information on the DEDICAM[®] portfolio and how to get started within the digital workflow by Camlog please contact your local Camlog distributor, or visit Camlog world-wide at www.camlog.com/en/dedicamr.



Er:YAG laser scanner for **implant site** preparation

Drs Norberto Berna, Giovanni Olivi, Luca Marigo & Massimo Cordaro, Italy

Introduction

Numerous studies have reported the ability of mid-infrared lasers (Er:YAG laser with a wavelength of 2,940nm and Er,Cr:YSGG laser with a wavelength of 2,780nm) to ablate hard biological tissue without creating thermal damage.¹⁻⁵ Among the various applications, the possibility of preparing the implant site entirely with laser irradiation was originally illustrated *in vivo* by Dr Berna, one of the authors of this article, in 2003. A patent for this form and method was issued and registered at that time. The first group of 62 patients received this method of treatment, using an Er,Cr:YSGG laser, between November 2001 and December 2002. Since then, another larger group of patients have been treated with this method. An Er:YAG laser and a dedicated laser scanner handpiece have never been used in human patients for this proce-

cedure, however. The major obstacles to the wide use of this technique are the time to create the osteotomy,⁶ the low energy capability of the devices previously available and the time required to learn to use a handpiece that works in no contact. In the present study, a high performance Er:YAG laser was used with a tiptless laser scanner handpiece that allows more precision, a higher energy output and a shorter pulse duration in comparison with the previously used device.

Materials and methods

A 67-year-old patient, a non-smoker without any systemic diseases, was examined using CBCT (PaX-i3D Smart, Vatech) in order to assess the surgical area, the bone volume and the bone density in the edentulous area, region #15 (Fig. 1). Before the surgery, the patient

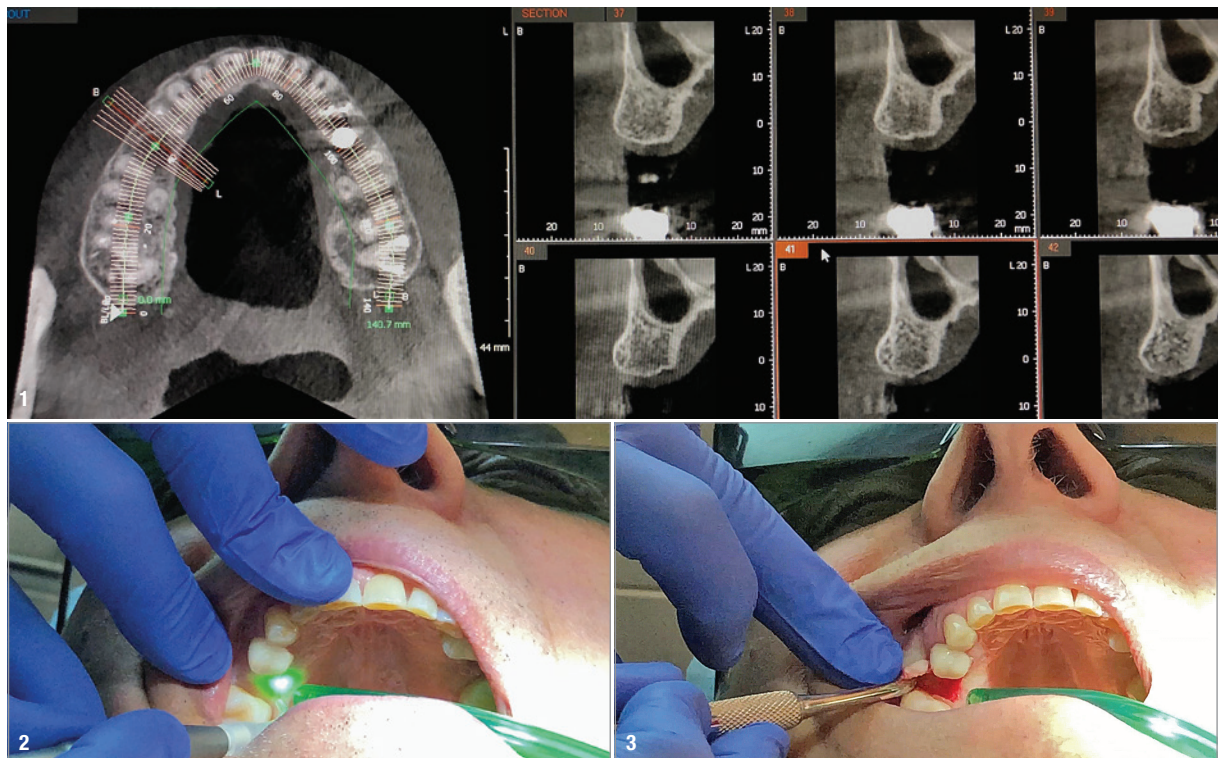


Fig. 1: A CBCT scan was taken pre-op. **Fig. 2:** Flap incision using a LightWalker Nd:YAG laser head (200 µm diameter fibre, 3W, 70Hz, MSP). **Fig. 3:** Flap reflection was carried out with a Prichard elevator.

EXCEPTIONALLY NO ADVERTISING AT THIS POINT, BUT A GREAT THANK YOU TO EVERYONE WHO HAS RESEARCHED AND DEVELOPED WITH US IN THE PAST YEARS.

Henning Alberti, h4sterne.de, Visual Designer and Photographer | **Jandar Amir**, Dentallabor Moss GmbH, Trainee | Prof. Dr. med. habil. Dipl.-Ing. **Rainer Bader**, Management, Orthopädische Klinik und Poliklinik Universitätsmedizin Rostock, Forschungslabor für Biomechanik und Implantattechnologie FORBIOMIT | Dr. **Angela Bergmann**, pipVerlag, Medical Writing & Editorial Staff | Dr. med. Dr. med. dent. **Wilken Bergmann**, Bundeswehrkrankenhaus Hamburg, Specialist in oral and maxillofacial surgery Focus on implantology | Dr. med. dent. **Michael Berthold Seehofer**, Zahnärzte in München, Oral Surgery Specialist | **Nico Bizer**, NB VIDEOfACTORY, Managing Director | Family **Bjelajac** | **Ralf Blank**, TBI Technologie-Beratungs-Institut GmbH, Managing Director | Dr. **Catrin Bludszuweil-Philipp**, ASD Advanced Simulation & Design GmbH, Managing Director | **Uwe Bräuer**, GENIUS Venture Capital GmbH, Managing Director | **Ulrike Burmeister**, Poliklinik für Zahnerhaltung und Parodontologie, Universitätsmedizin Rostock, Senior Consultant | Dr. med. dent. **Claudio Cacaci**, IMPLANTAT COMPETENCE CENTRUM, Gemeinschaftspraxis Cacaci & Randelzhofer, Dentist & Oral Surgeon | **Catrin Crasemann**, Creative Consultant | Dr. med. Dr. med. dent. **Michael Dau**, Klinik und Poliklinik für Mund-, Kiefer und Plastische Gesichtschirurgie, Specialist in Oral and Maxillofacial Surgery, Universitätsmedizin Rostock | **Denise Nielsen**, TIZIO Hybrid Implants GmbH, Sales & Logistic | **Mario Dombrowski**, FMZ GmbH, Head of Manufacturing | PD. Dr. rer. nat. **Nadja Engel**, Klinik und Poliklinik für Mund-, Kiefer und Plastische Gesichtschirurgie, Head of Research Laboratory | **Stefanie Flentje**, Dentallabor Moss GmbH, Master of Dental Technician | **Andre Flentje**, grafjik Kommunikationsdesign, Graphic Design and Photographer | **Karin Franke**, Schackow Joksch Rechtsanwälte PartG mbB, Attorney | Prof. Dr. med. Dr. med. dent. **Bernhard Frerich**, Klinik und Poliklinik für Mund-, Kiefer und Plastische Gesichtschirurgie, Universitätsmedizin Rostock, Clinic Director | **Rene Friedrich**, ZM Präzisionsdentaltechnik GmbH, Dental Technican | Dr. **Andreas Frost**, Dental Office, Dentist | Dr. **Claudia Fruijtier-Pöloth**, CATS Consultants GmbH, Managing Director | Dr. **Antonia Fuchs**, Dental Office, Dentist | Dr. **Cornelia Ganz**, TIZIO Hybrid Implants GmbH, Head of Research & Development | **Reinhard Gedack**, D.I.E. WERBEFILM GmbH, Senior Executive Producer | **Patrik Gölz**, paddefilm, Best Cameraman | Dr. **Gian-Garlo Gullo**, Metoxit AG, Managing Director | Dipl.-Ing. **Dierk Hansmann**, Patentanwälte Hansmann & Hansmann, Patent Attorney | **Robert Hauschild**, FMZ GmbH, Research & Development | Dr. med. Dr. med. dent. **Anders Henningsen**, ELBE MKG, Specialist in Oral and Maxillofacial Surgery Focus on Implantology | **Ulrike Hinz**, TIZIO Hybrid Implants GmbH, Quality Management Officer | Dr. med. **Michael Hopp**, Dental Office, Dentist | Dr. med. dent. **Ulrike Hoppe**, Dentalmedizin Hamburg, Dentist | **Frank Idel**, Gebr. Brasseler GmbH & Co. KG, Senior Manager Engineering & Quality Control | **Hubert Joksch**, Schackow Joksch Rechtsanwälte PartG mbB, Attorney | Dr. rer. hum. Dipl.-Biol. **Anika Jonitz-Heincke**, Forschungslabor für Biomechanik und Implantattechnologie FORBIOMIT, Orthopädische Klinik und Poliklinik Universitätsmedizin Rostock, Head of the Tissue Regeneration Group | **Stephan Jung**, Dentallabor Moss GmbH, Dental Technican | **Kerstin Jung**, Kommunikation Dental, Editor | **Rita Kohlbach**, FMZ GmbH, Logistic | Prof. Dr. med. Dr. rer. nat. **Markus Kipp**, Institut für Anatomie, Universitätsmedizin Rostock, Institute Director | **Wolfgang Klinger**, ACF Amberger Central Fräs-Center GmbH, Managing Director | Priv.-Doz. Dr.-Ing. habil. **Daniel Klüß**, innoproof GmbH, Managing Director | **Thomas Knüppel**, KLOPSCH & PARTNER RECHTSANWÄLTE mbB, Attorney | **Susanne Knüppel**, STEUERBORD, Tax Advice & Economic Advice | Dr. **Stefan Köbel**, Decema GmbH, Managing Director | Dipl.-Ing. **Uwe Koch**, primec GmbH, Managing Director | **Joanna Moss**, Dentallabor Moss GmbH, Trainee | Prof. **Hans-Georg Neumann**, DOT GmbH, Managing Director | Dr. **Barbara Neumann**, Composita GmbH | **Hans-Christian Neumann**, Composita GmbH, Managing Director | Dr. med. dent. **Thomas Niedermeier**, Dental Office, Dentist & Implantologist | **Cord Obenhausen**, Gebr. Brasseler GmbH & Co. KG, Regional Sales Manager | Dr. **Hartmut Ohm**, ABZ Abrechnungs- und Beratungsgesellschaft für Zahnärzte eG, Chairman of the Board | **Iris Peters**, STEUERBORD, Tax Advice & Economic Advice | Dr. **Pantelis Petrakakis**, pipVerlag, Freelance Journalist & Dentist | Dr. **Andreas Pippig**, Dental Office, Dentist | **Otto Prandtner**, Plattform für feinste Dentaltechnologie GbR, Dental Technican | Dr. med. dent. **Friedrich Preusse**, Dres. Kleier & Schlieper, Oral Surgery Specialist | **Dirk Pfützner**, FMZ GmbH, Managing Director | **Katja Quednau**, FMZ GmbH, Quality Management | **Lars Quiring**, D.I.E. WERBEFILM GmbH, Compositing Artist | **Ronny Raasch**, OstseePharma Consulting GmbH, Managing Director | Dr. med. dent. **Peter Randelzhofer**, IMPLANTAT COMPETENCE CENTRUM, Gemeinschaftspraxis Cacaci & Randelzhofer, Dentist | **Daniel Reimer**, FMZ GmbH, Production | Dr. med. dent. **Morten Reimer**, Zahnarztpraxis, Dentist | Dr. **Michael Reise**, estetic ceram ag, Head of Research & Development | Dr. **Bärbel Riemer-Krammer**, Dental Office, Dentist | **Nicole Sabelny**, TIZIO Hybrid Implants GmbH, Quality Management Officer | Dr. med. dent. **Reza Saeidi-Pour**, Seehofer – Zahnärzte in München, Dentist | **Nico Schade**, STEUERBORD, Tax Advice & Economic Advice | **Julian Scheinkönig**, SCHEINKÖNIG, Creativ Director | **Carsten Schiele**, Rostock Business and Technology Development GmbH, Project Manager | Dr. **Benedikt Seeber**, Metoxit AG, CTO | Dr. med. dent. **Peter Seehofer**, Seehofer – Zahnärzte in München, Dentist | **Katrin Seidel**, TIZIO Hybrid Implants GmbH, Office | Prof. Dr.-Ing. **Hermann Seitz**, Lehrstuhl für Mikrofluidik, Universität Rostock, Chair Director | **Marc Simon**, D.I.E. WERBEFILM GmbH, Executive Producer | **Lara Speitmann**, projekt rk Messe Design Werbung, Project Manager | **Egbert Sprenger**, estetic ceram ag, Managing Director | Prof. Dr. Dr. h.c. **Frank Stein**, Healthcare Projects Consulting & Management, QM Consulting | **Marianne Steinbeck**, pipVerlag, Publisher | Dr. **Bernhard Steinfeldt**, Zahnarztpraxis, Dentist | **Anja Stolzenburg**, FMZ GmbH, Logistic | Prof. Dr. **Joachim Tinschert**, Universitätsklinikum Aachen, Klinik für Zahnärztliche Prothetik, Dentist | **Nico Tjarks**, Homepage Helden GmbH, Managing Director | **Thomas Ulrich**, ulrich-fotodesign, Photographer | **Danny Vogel**, Forschungslabor für Biomechanik und Implantattechnologie FORBIOMIT, Orthopädische Klinik und Poliklinik Universitätsmedizin Rostock, Head of the Experimental Biomechanics Group | **Martin Vollbrecht**, Dental Balance GmbH, Managing Director | **Helge Vollbrecht**, Dental Balance GmbH, Managing Director | Prof. Dr. med. habil. **Brigitte Vollmar**, Universitätsmedizin Rostock, Institute Director Experimental Surgery | Dr. **Wolfram Weber**, Decema GmbH, Managing Director | **Christian Weiß**, Rostock Business and Technology Development GmbH, Managing Director | **Wolfgang Weisser**, CTB-Zirkel, Master of Dental Technician | **Christina Wels**, ZM Präzisionsdentaltechnik GmbH, Dental Technican | **Steve Wendland**, Rostock Business and Technology Development GmbH, Senior Consultant Technology Advancement | **Daniel Wolter**, Klinik und Poliklinik für Mund-, Kiefer und Plastische Gesichtschirurgie, Medical-Technical Assistance | **Kastriot Xhoxhaj**, estetic ceram ag, Sales and Marketing | **Ralf Zerbe**, FMZ GmbH, Production | Dr. rer. hum. Dipl.-Ing. **Carmen Zietz**, innoproof GmbH, Managing Director | Dr. med. dent. **Catarina Zimmermann**, Dentalmedizin Hamburg, Dentist & Oral Surgeon | **Elbpänt Marshall & Partner** Rechtsanwaltskanzlei, Patent Attorney | **Claudia Voss**, TIZIO Hybrid Implants GmbH, Sales Director | **Jennifer Wilken**, TIZIO Hybrid Implants GmbH, Managing Director



TIZIO H6



TIZIO F3

WE WOULD BE HAPPY TO PRESENT OUR INNOVATIVE
HYBRID TECHNOLOGY TO YOU IN DETAIL. YOU CAN
FIND CONTACT AND FURTHER INFORMATION AT
WWW.TIZIOIMPLANTS.COM
WE ARE PLEASED TO MEET YOU. STAY HEALTHY.



TIZIO HYBRID IMPLANTS

The Root of the Future

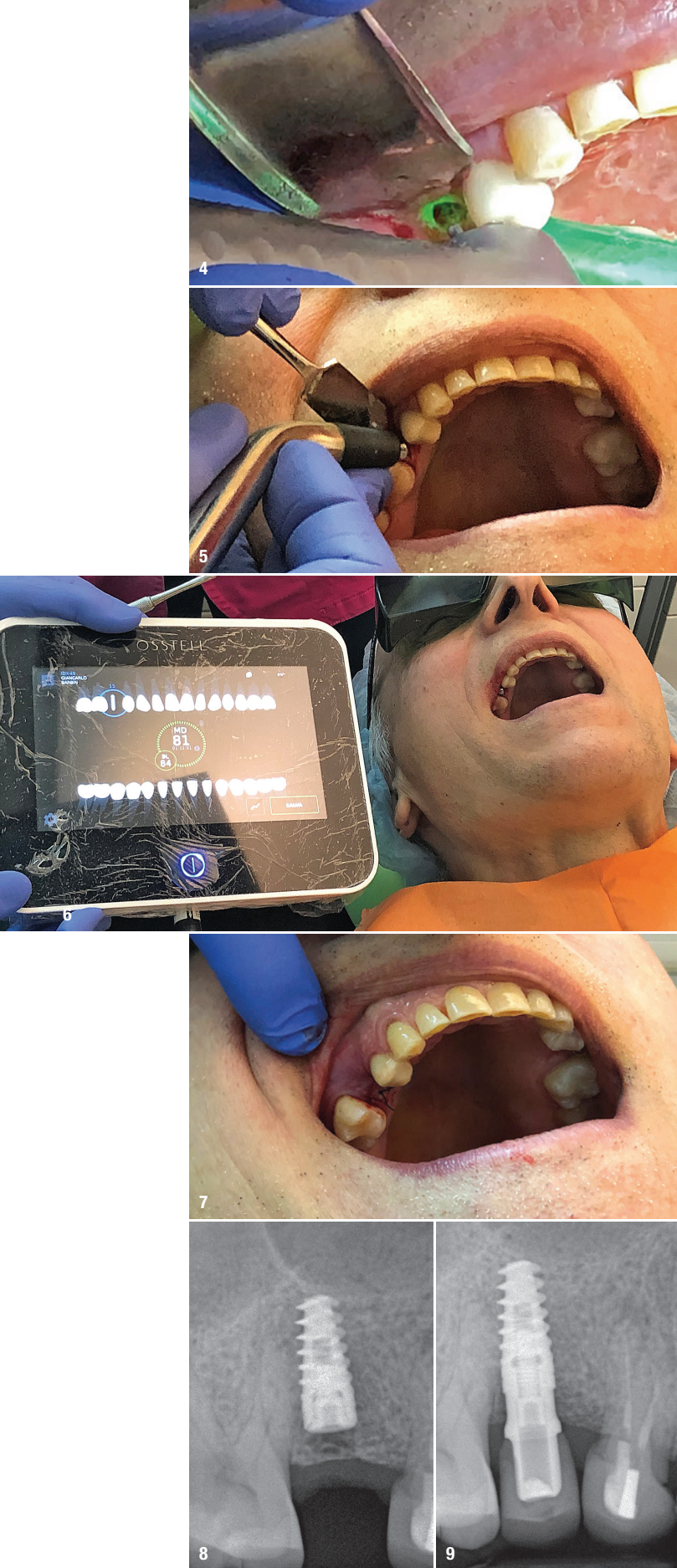

Fig. 4: The stabilised laser preparing the osteotomy, operated at 380mJ, 20Hz and 50 microseconds. **Fig. 5:** The Osstell handpiece detecting primary stability. **Fig. 6:** Determining the ISQ value. **Fig. 7:** Clinical situation post-op. **Fig. 8:** Radiograph taken immediately after surgery. **Fig. 9:** Radiograph taken after eight months of loading.

had received all the information regarding the treatment and the possible alternative treatment through a personalised informed consent form. The implant insertion axis has been planned for the best functional result of the prosthesis. A customised dental resin holder was created to support the laser scanner handpiece intra-orally, in the correct position according to the insertion axis of the implant. Local anaesthesia was administered using articaine (1 : 100,000). A full-thickness incision was performed using an Nd:YAG laser (1,064 nm wavelength; 200µm diameter fibre; MSP: 3W, 70Hz; LightWalker AT, Fotona) on the palatal paramedian line; two mesial and distal releasing incisions were also performed without involving the papillae (Fig. 2). The access flap was then reflected with a Prichard elevator (Fig. 3).

An Er:YAG laser with a wavelength of 2,940 nm (LightWalker AT) equipped with a laser scanner handpiece (X-Runner, Fotona) was used (Fig. 4). The laser parameters used were 380mJ and 20Hz, delivered with a super-short pulse (50 microseconds). An external source of sterile saline solution stored at 5°C in a refrigerator was used, and the saline was delivered via a peristaltic pump to promote photothermal ablation and to reduce the temperature in the surgical site. The scanner allows one to program and precisely perform a circular osteotomy of 3.5 mm in diameter, the same diameter as the implant manufacturer's final drill. During the osteotomy, the insertion depth was checked using a millimetre probe, until the preset depth of 12 mm was reached. The author prefers to place implants 2 mm deeper sub-crestally to prevent angular resorption and to manage the emergence profile of the prosthesis more effectively. A tapered screw implant made of Grade IV titanium and with a sandblasted and acid-etched surface (HELLI, IDC) was inserted. It had a maximum diameter of 4.2 mm on the external thread and a length of 10.0 mm. Once inserted, the implant stability quotient (ISQ) was determined using the Osstell handpiece (Osstell; Figs. 5 & 6). The flap was sutured (Fig. 7), a postoperative radiograph was taken (Fig. 8), and after five days, the sutures were removed. At that time, the patient was asked to assess the postoperative pain he had experienced by assigning a numeric value of between 0 and 10 on a verbal numeric scale.

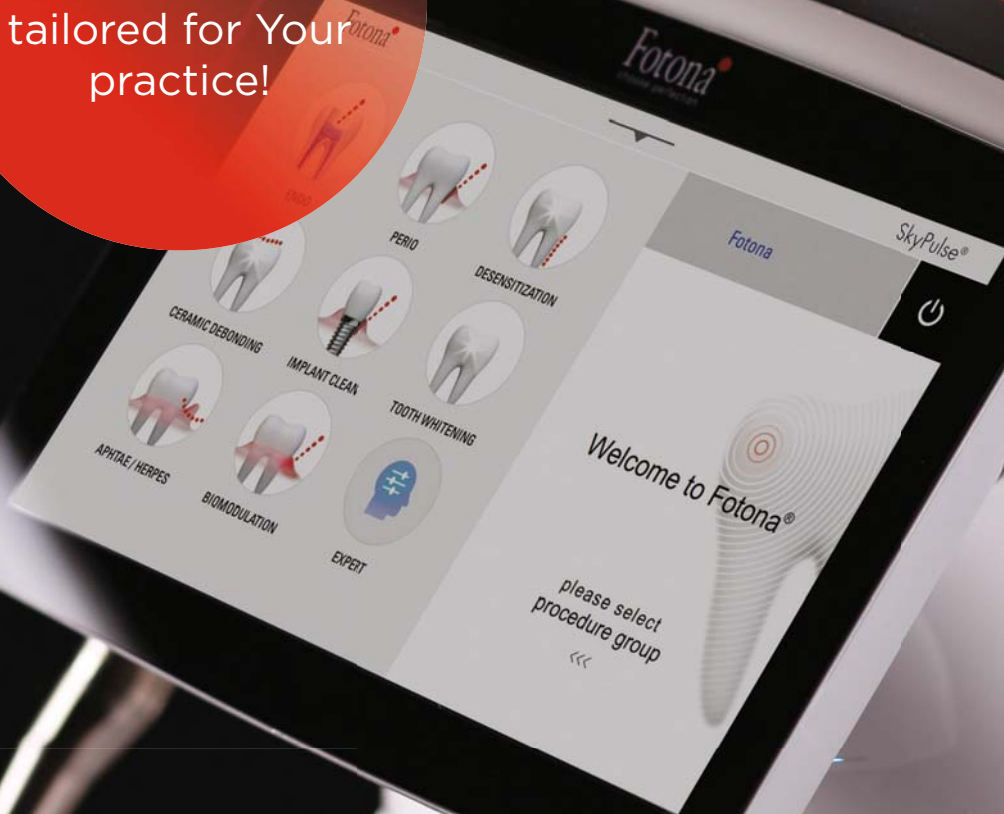
Results

The total clinical time for preparing the osteotomy was approximately 7 minutes. The implant had a high primary stability value at the time of insertion: the ISQ score measured in the buccolingual direction was 84 and the score measured in the mesiodistal direction was 81. The reported numeric value of postoperative pain was 1. At the second stage of the implant treatment, which was performed after 40 days, new ISQ values of 84 buccolingually and 82 mesiodistally were determined. After three months, the values had increased to 86 buccolingually


SkyPulse®

A new generation of compact
Fotona lasers

A compact, easy
to use Er:YAG Laser
tailored for Your
practice!



103.696 CE ENG/1



Committed to Engineering

The Highest Performance, Best Made Laser Systems in the World

Fotona
choose perfection

www.fotona.com