

# implants

international magazine of oral implantology



## research


CBCT bone-densitometry  
for pre-surgical decision-making

## case report

Explantation of an implant in a heavy smoker

## interview

The perfect link between man and technology




IT'S SIMPLE  
WHEN YOU  
HAVE ALL THE  
**OPTIONS**



**mis<sup>®</sup> | C1**

THE CONNECTION FOR PREDICTABLE BIOLOGY. **MAKE IT SIMPLE**

The MIS C1 conical connection implant system offers uncompromising accuracy, with high initial and biological stability and a safe, yet simple, procedure. A consistent concave emergence profile of the C1 prosthetic components improves soft tissue esthetic results. Learn more about the C1 implant and MIS at: [www.mis-implants.com](http://www.mis-implants.com)



**Dr Rolf Vollmer**

First Vice President and Treasurer of DGZI



# The role of **implantology** in coming years

Early in the 70s I was active in the field of implantology and I was convinced that dental implantology could develop into a scientifically recognised dental discipline following a large number of “trial and error” attempts. This dream came true and DGZI already in 1993 introduced an implantologist’s qualification by means of a standardised test. This was a completely new concept in Germany at that time. This qualifying examination has been named the “Implantology Specialist—DGZI”.

Considering the current trends, particularly the age stomatology, it becomes obvious that implantology will play an important role in the rehabilitation of older patients in the next 20 years. Further considering the fact that a large number of edentulous patients exists in many countries, there is a significant potential for treating many people who could benefit from this type of treatment. As the aesthetic demands of patients increase, we can assume that even in cases of the traumatic loss of teeth, implantology is the treatment of choice. On the one hand, a trend towards simpler and cheaper implants is observed in the industry, while on the other hand even so-called market leaders offer special types of implants at excessively high prices. As a logical consequence, the complete treatment becomes very expensive due to high material costs. Due to these concepts like “All-on-4” to “All-on-One”/“All-in-One” are promoted or implants reduced in diameter and length. Demands on aesthetics have dramatically increased today.

In my opinion, the current development has both its positive and negative aspects. I believe that it poses a par-

ticular problem for the newcomer because it suggests that implants can be inserted without problems into the jaw, perhaps with navigation, but without requiring a flap procedure. The comparison with the speed of vehicles should not be dismissed. Exceeding the speed limit on the highway may result in a fine. Exceeding the speed limit in implantology may lead to implant failure. I hope that the dental industry in future can help simplify the field of implantology by introducing standardised implant accessories or by consistently using existing standards. One example are the connecting screws (implant–abutment) which are only compatible with other systems in rare cases, as well as the corresponding screwdrivers or hex wrenches. A company should not need to prove its uniqueness by using connecting screws of a certain diameter or special threading with a particular pitch.


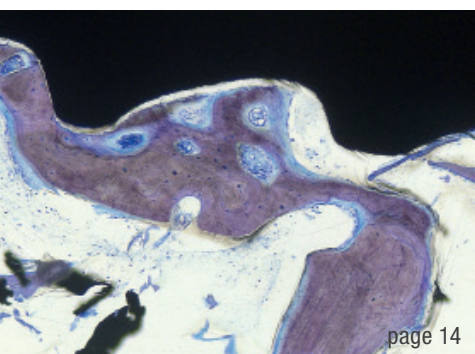
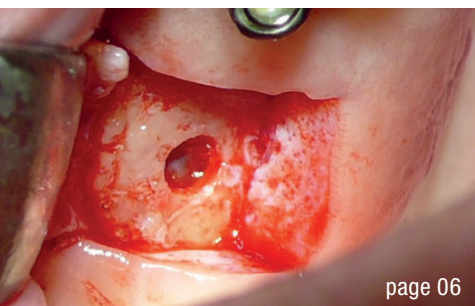
Let us see what is coming up in the next years and join our curriculum. The DGZI Curriculum as a first step in education will update you on the state of the art today and even experienced colleagues will have a chance to improve their knowledge.

We hope to see you in Germany! Join our DGZI family!

With best regards

A handwritten signature in black ink, appearing to read 'R. Vollmer'.

Dr Rolf Vollmer



Cover image courtesy of  
TIZIO Hybrid Implants  
www.tizioimplants.com



## editorial

- The role of **implantology** in coming years 03  
Dr Rolf Vollmer

## research

- CBCT **bone-densitometry** for pre-surgical decision-making 06  
Prof. Angelo Trödhä

## case report

- A **viable** alternative for complex clinical situations 12  
Dr Sepehr Zarrine
- Explantation** of an implant in a heavy smoker 14  
Dr Branislav Fatori, Dr Inge Schmitz & Prof. Werner Götz

## industry

- Predictable, immediate results with **Tapered Pro** implants 20
- Improve** your implant business **case-by-case** 22

## practice management

- Practice **strategies** in the age of corona 24  
Dr Anna Maria Yiannikos

## interview

- The **perfect** link between man and technology 26

## DGZI Special

- Training** programme of the DGZI in **cooperation** with the GBOI 34  
Dr Rolf Vollmer
- DGZI news 36
- Application Route for International Practitioners 37
- Reflect on **50 years** of implantology in Bremen this autumn 38

## news

- manufacturer news 28
- news 40

## about the publisher

- imprint 42




## Tapered Pro predictable, immediate results

Immediate implant treatment requires predictability. Tapered Pro implants have been developed based on over 10 years of tapered implant success. The unique design elements provide a predictable solution for immediate treatment.

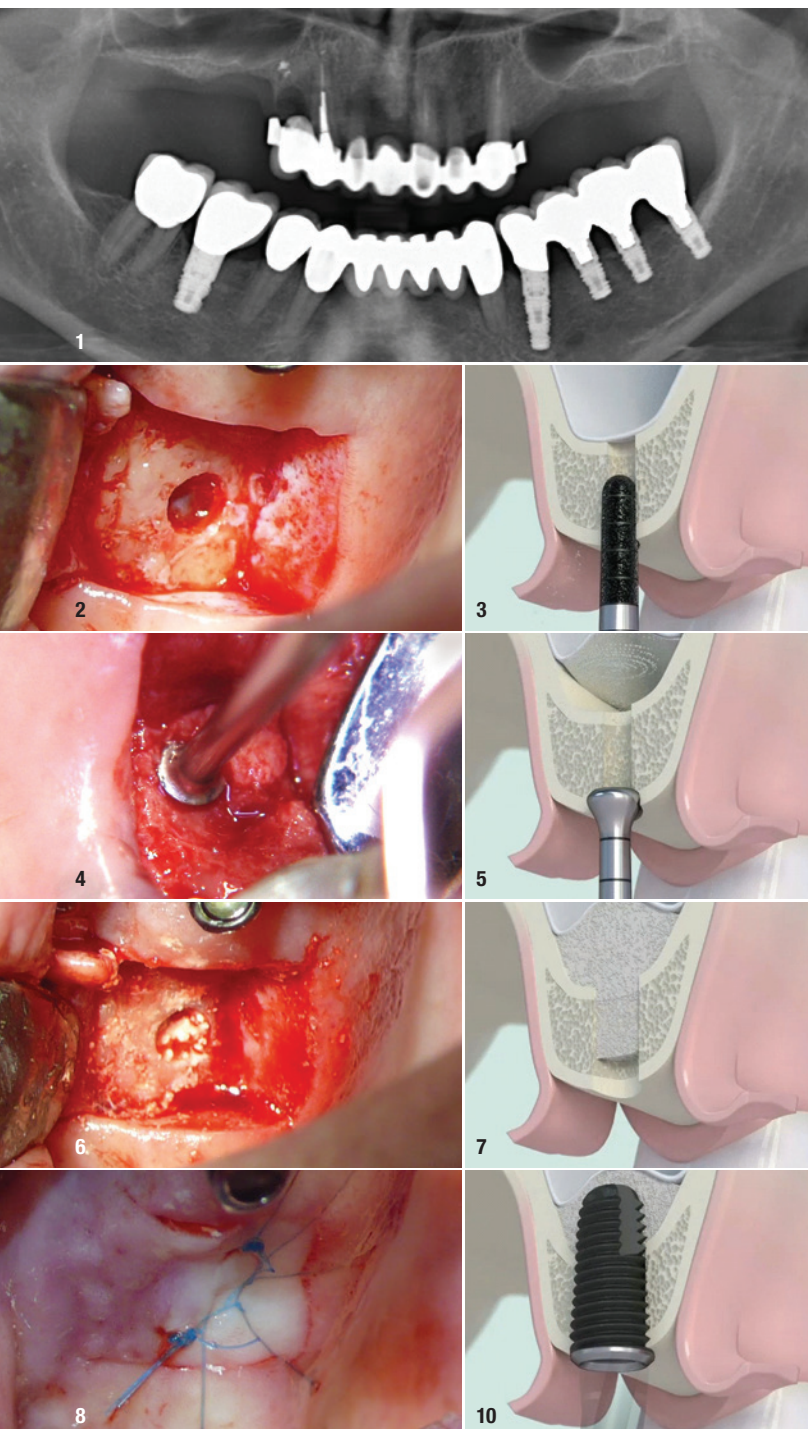
**design features include:**

- tapered body and aggressive threads provide primary stability
- end cutting, self-tapping thread design for controlled implant placement in challenging sites
- reduced collar diameter preserves vital bone
- unique Laser-Lok microchannels create connective tissue attachment and retain crestal bone, allowing better control of esthetic outcomes



# CBCT bone-densitometry for pre-surgical decision-making

Prof. Angelo Trödhan, Austria

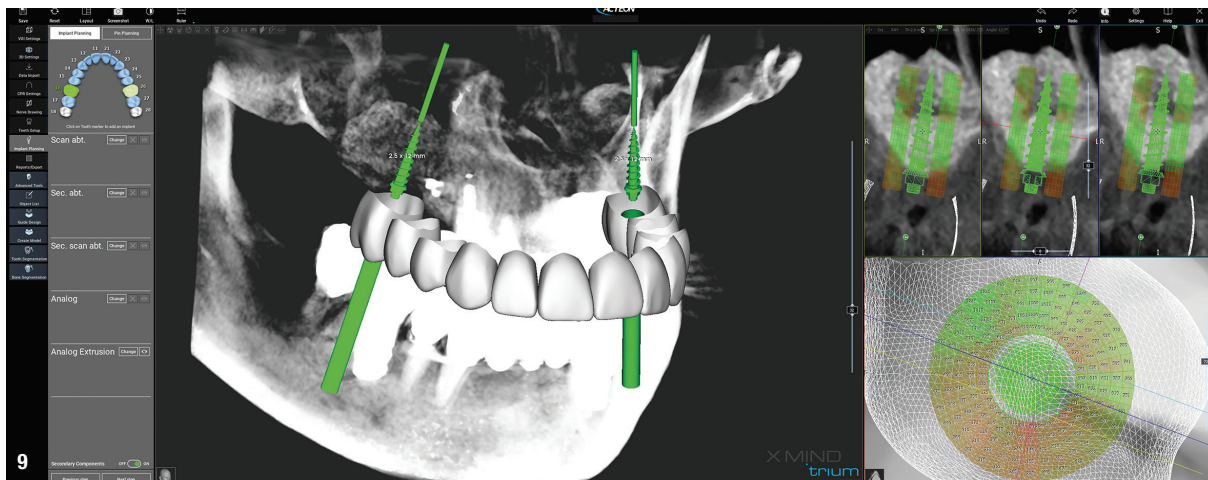


## Introduction

The high prevalence of tooth-related diseases, a growing geriatric population and a rapidly growing awareness to replace lost teeth by dental implants force dentists, oral and maxillofacial surgeons to cope with promises made by implant manufacturers such as “new teeth in one hour”. While implant manufacturers try to maximise their sales numbers by such marketing strategies, it will always be the practitioner’s full responsibility to treat patients with strictly evidence-based treatment protocols, especially when it comes to the immediate functional loading of dental implants.

Esposito et al. (2007), Javed et al. (2010), Walker et al. (2011) and Cannizzaro et al. (2012) proved in reviews, Cochrane studies and split-mouth randomised clinical trials that primary implant stability—represented by insertion torque values (ITV)—shows a significant correlation between the biomechanical quality of bone and the risk of immediate and long-term implant failure when implants are loaded functionally at time of insertion.<sup>1–4</sup> Furthermore, experimental and clinical studies published by Turkyilmaz et al. (2007), Pommer et al. (2014) and Wada et al. (2016) proved a significant correlation between primary implant stability measured by ITV and computerised axial tomography (CAT) scan-based bone densitometry in native alveolar bone.<sup>5–7</sup>

Since alveolar bone loss caused by natural atrophy or destructive iatrogenic procedures at the time of tooth extraction demands immediate (“alveolar ridge preservation”) or later (“guided bone regeneration”) bone augmentation procedures, Di Lallo et al. (2014) and Trödhan et al. (2014) in randomised clinical studies found a significant difference of primary implant stability when augmented alveolar bone was compared with native alveolar bone.<sup>8,9</sup> Recently, a randomised clinical study was performed by Trödhan et al. (2019) to investigate if a significant correlation between pre-surgical cone-beam computed tomography (CBCT) bone densitometry performed with X-Mind trium CBCT (ACTEON) and primary implant stability in augmented sinus sites could be proven.

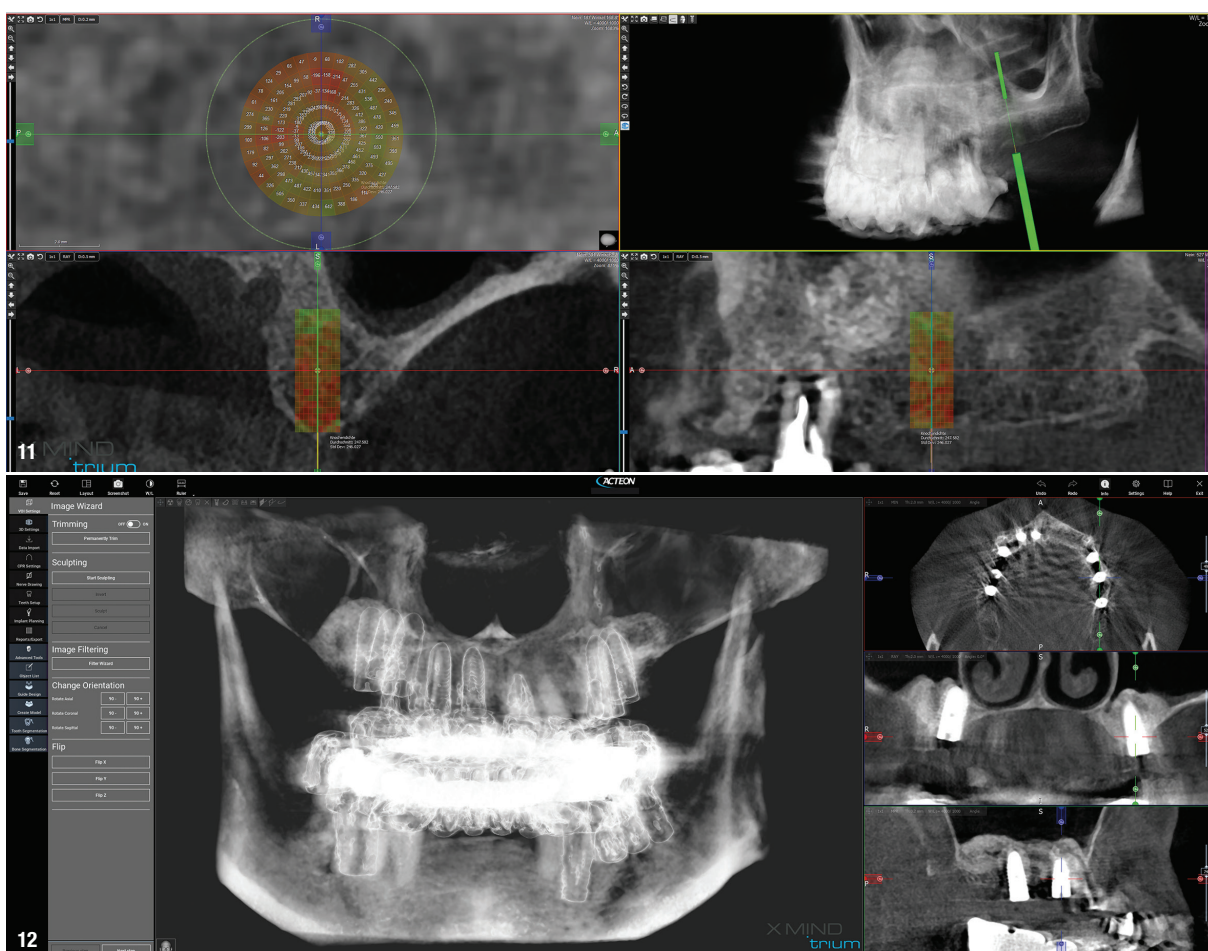


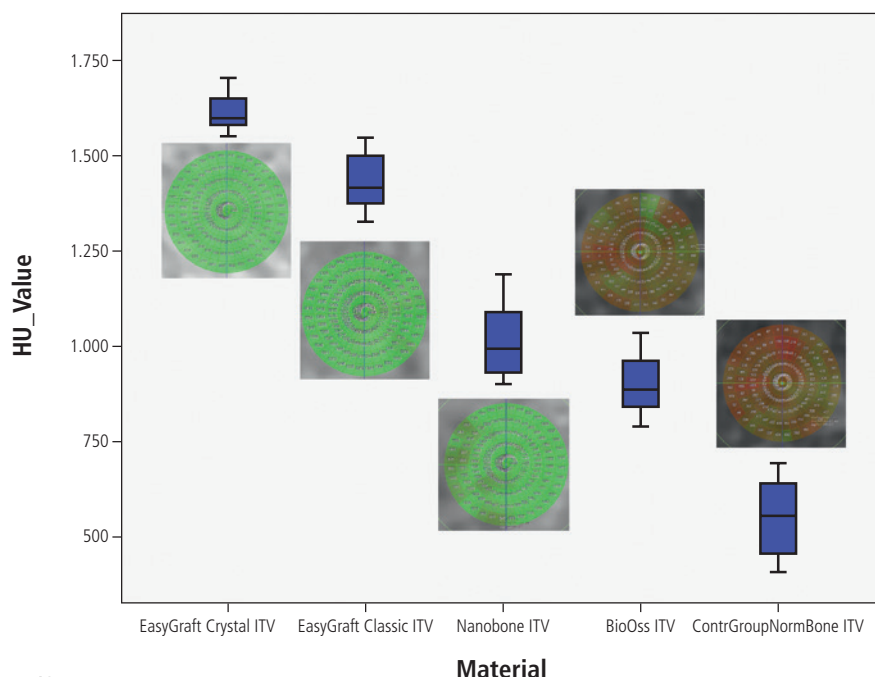
## Study design

A randomised clinical study was conducted on 128 patients. 101 patients with less than 4mm subantral crest-height underwent a uni- or bilateral transcrestal hydrodynamic ultrasound Piezotome sinus lift (INTRALIFT) with four different and randomly allocated bone graft materials (mono- or biphasic mouldable and self-hardening biomaterial, granular synthetic and xenogeneic bone substitute) in 114 INTRALIFT sites. The transcrestal Piezotome INTRALIFT provides the least risk of membrane-perforations and has proven to detach the peri-

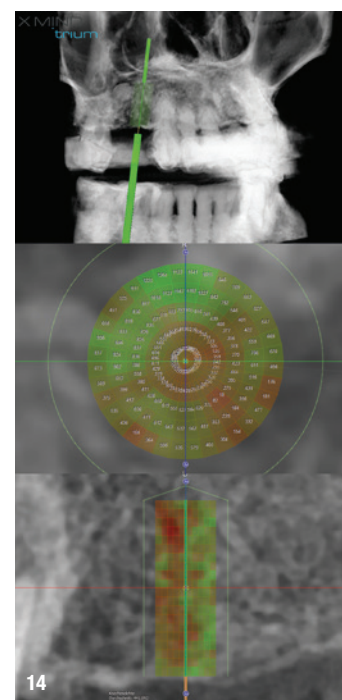
osteum of the sinus membrane cleanly from the bony base of the antrum, thus preventing biases of the study already at the stage of the surgery. The clean detachment of the periosteum from the bone base does not interfere with the regular bone regeneration in the subantral scaffold by dissection or lacerations of the periosteal layer of the sinus membrane, which carries the pre-osteoblast cell layer.<sup>10–15</sup>

Figure 1 shows a split-mouth case with a bilateral INTRALIFT procedure: after a small crestal “booklet”-flap of approx. 7 x 7 mm is detached, the sinus floor is safely





13



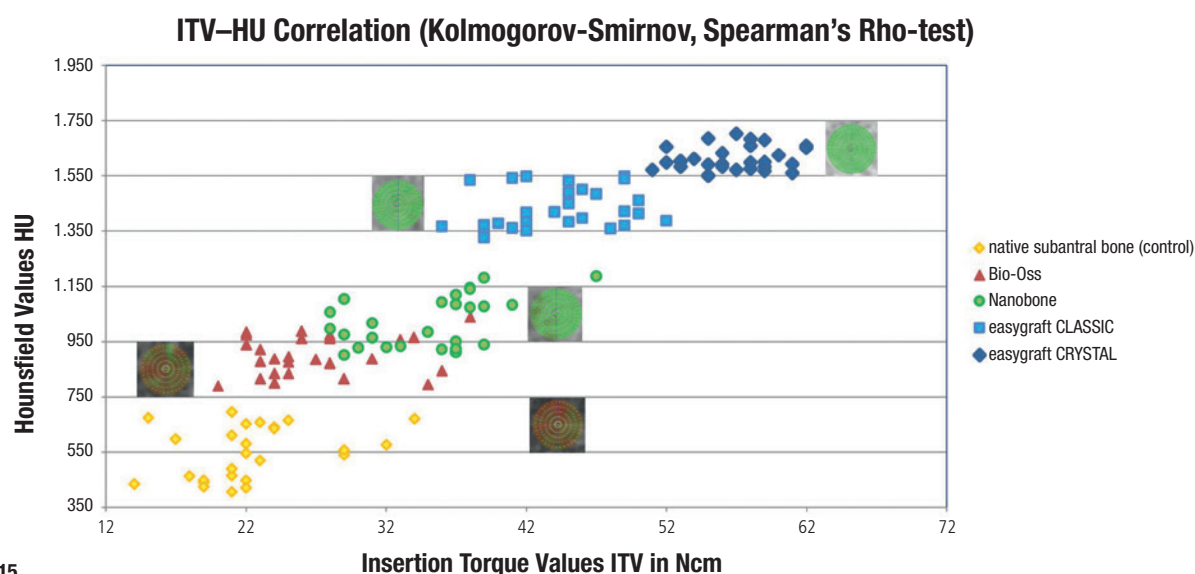
14

opened with ultrasound Piezotome tips (Figs. 2 & 3), the sinus membrane then detached by the hydrodynamic cavitation effect of the Piezotome-tip TKW5 plugged into the approach canal (Figs. 4 & 5) and the subantral scaffold filled with 2cm of randomly assigned biomaterial (Figs. 6 & 7), followed by wound closure (Fig. 8). After a mean healing period of 8,4 months X-Mind trium CBCT scans were performed, the digital setup of the future bridge constructed with the AIS 3D app and the bone density determined in the sinus-lift site around a virtual implant (Fig. 9). Standardised implants (4mm in diameter and 12mm in length) were then inserted in the position of the virtual implant and insertion torque val-

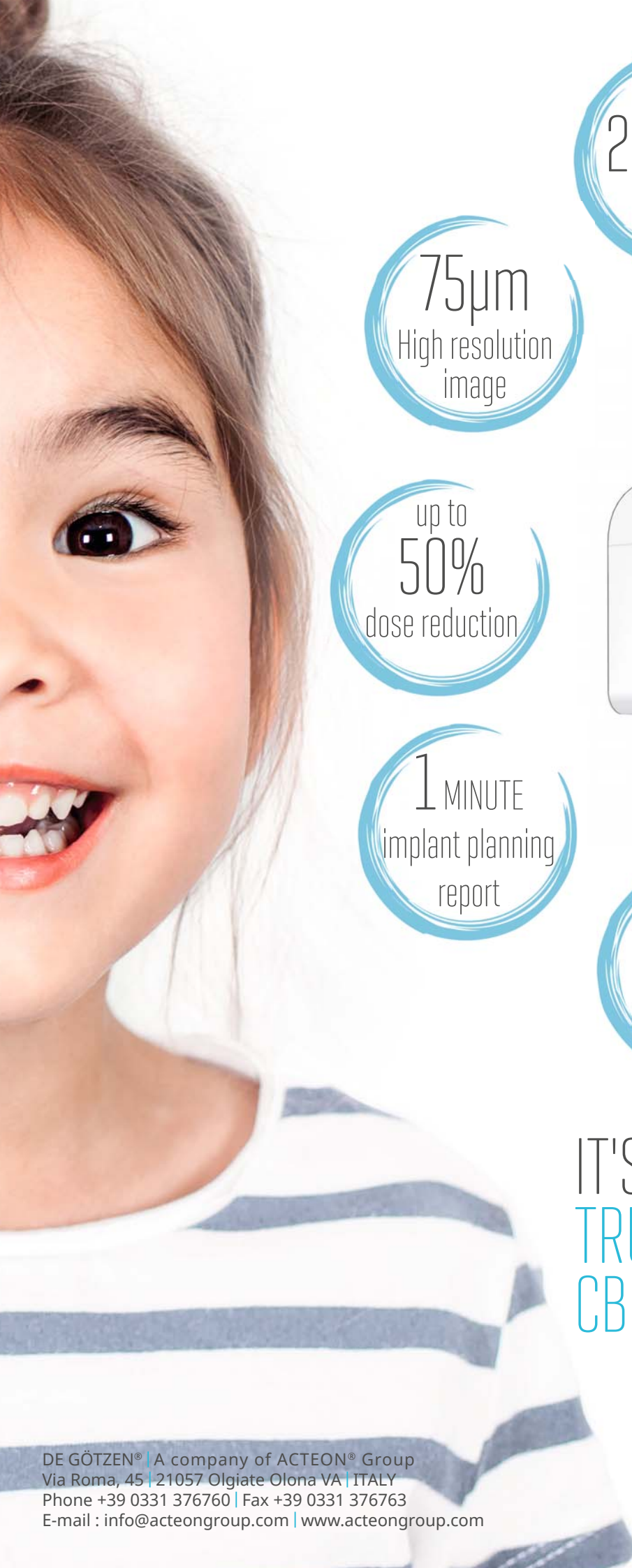ues (ITV) measured intra-surgically (test groups; Fig. 10). A total of 27 patients with sufficient native subantral crestal bone (min. crest width: 6mm, height: 12mm) were screened by X-Mind trium CBCT for bone density with the virtual implant (Fig. 11), the standardised implant inserted and the ITV recorded (control group). Figure 12 depicts the final result after implant insertion in the patient case shown in Figures 1–9.

### Study outcomes

As can be seen in Fig. 13, the mean CBCT bone density values in Hounsfield units (HU) at the implant site dif-



15



2D & 3D  
exams

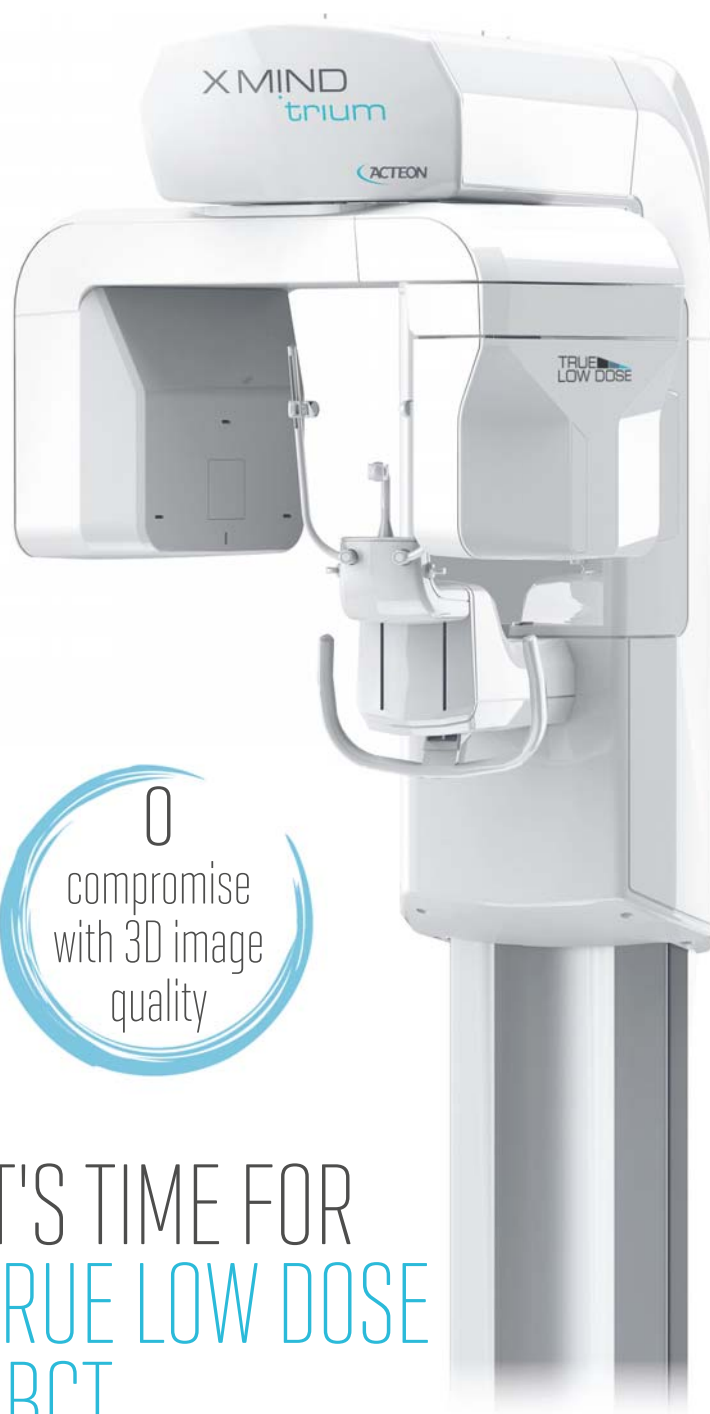MAC  
Compatible

75 $\mu$ m  
High resolution  
image

up to  
50%  
dose reduction

1 MINUTE  
implant planning  
report

0  
compromise  
with 3D image  
quality



IT'S TIME FOR  
TRUE LOW DOSE  
CBCT