

laser

international magazine of laser dentistry



research

Laser-assisted removal of instrument fragments

industry

Periodontal aesthetics with soft-tissue lasers

practice management

Return on investment of laser technology



Fotona
choose perfection

The universe at your fingertips.

● LightWalker

The highest technology dental laser system

Supreme clinical results:

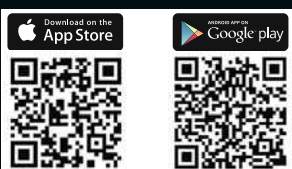
- TwinLight® Perio Treatments
- TwinLight® Endo Treatments
- No-sutures soft-tissue surgery
- Patient-friendly conservative dentistry
- Pre-sets for over 40 applications


Unmatched simplicity of use:

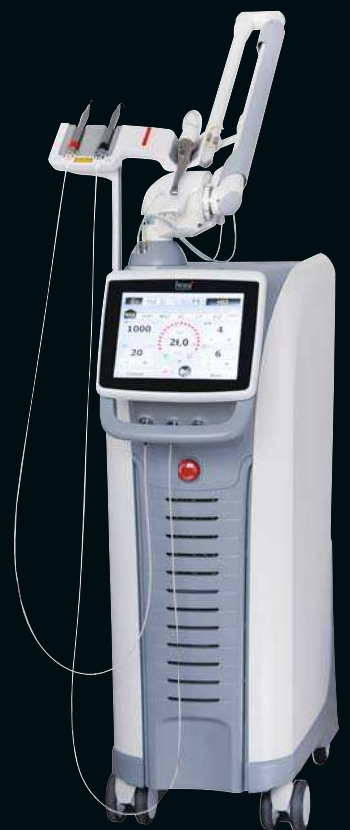- Balanced and weightless OPTOflex® arm
- Nd:YAG handpiece detection system
- Quantum Square Pulse technology for fast minimally invasive treatments
- X-Runner™ - the first digitally controlled Er:YAG dental laser handpiece

Journey into a new dental experience with speed, precision and great results.

Visit www.fotona.com today!



 Fotona App



88897/25

Dr Stefan Grümer

Vice-Chairman,
WFLD Organising Committee



Save the date

Dear colleagues, dear friends,

The preparations for the joint congress of DGL and WFLD in Aachen, Germany, are in full swing. To be celebrating the 30th anniversary of the International Society for Laser Dentistry (ISLD, founded in 1988) in Aachen, is a huge honour and motivation to make this event special.

Save the date
WFLD World Congress
1 to 3 October 2018 in Aachen, Germany

And that's the plan:

It is intended to be an international event of a high scientific level, with pronounced practical orientation. The possibilities of high-quality education of one of the most modern university clinics in Germany shall offer the appropriate setting.

An entirely new concept will be used to realise these intentions: In order to combine a maximum practical orientation medially with the corresponding background knowledge, high-quality scientific presentations of internationally renowned speakers on current developments of laser research—taking place in three auditoriums—will be linked with innovative live patient demonstrations accompanied by theoretical introductions and follow-ups of presentation teams.

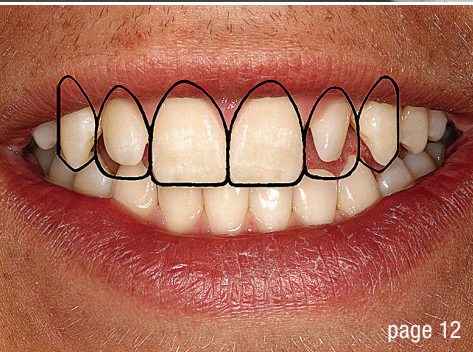
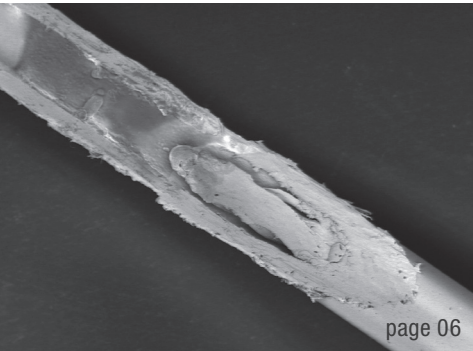
In times of Ultra HD and multi-channel projection, the auditorium gets right up close to dentistry of the highest level being demonstrated with diverse wavelengths and devices—guaranteeing a maximum learning effect. Theory and practical experience will further be connected in the workshop events. Highly modern video-projection walls for poster presentations will last but not least promise interactive multi-media adventures, that have not existed in that manner before.

A large number of companies, not only of the field of laser dentistry, will be using the congress-accompanying exhibition to present their products and innovations. Well-known exhibitors have already agreed to participate.

For many laser-enthused colleagues from all over the world it will be “Coming back home to Aachen!” in October. For others the door to the world of laser is only just opening. I am looking forward to welcoming you all and, of course, the numerous friends from DGL, WALED and WFLD/ISLD here in Aachen—only your plentiful participation and active contribution will make this congress something special.

See you soon in Aachen,

Dr. Stefan Grümer



editorial

Save **the date** 03
Dr Stefan Grümer

research

Nd:YAG **laser-assisted removal** of instrument fragments 06
Dr Georgi Tomov

case report

Gingival depigmentation using diode laser 08
Dr Chayanee Prakongsantikul & Assoc. Prof. Dr Sajee Sattayut

industry

Creating **natural-looking** composite restorations 12
Dr Daniel H. Ward

Periodontal aesthetics with **soft-tissue lasers** 16
Dr David L. Hoexter

Periodontal tissue regeneration 20
Dr Alan Dalessandro, Dr Harvey Shiffman,
Dr Steven R. Pohlhaus & Dr Larry Lieberman

practice management

Return on investment of dental **laser** education and technology 24
Dr Imneet Madan

Successful **communication** in your **daily practice** 28
Dr Anna Maria Yiannikos

news

manufacturer **news** 30

news international 32

DGL

Save **the date** 37
Dr. Stefan Grümer

news germany 38

about the publisher

imprint 42

Cover image:
© AlexandrBognat/Shutterstock.com





Master of Science (M.Sc.) in Laser in Dentistry

Next Start: **15th October 2018** | Aachen, Germany | 4 semesters



Become part of the International Dental Elite

- Create new economic potential for your practice
- Two year career-accompanying postgraduate programme at the University of Excellence RWTH Aachen
- Combination of lectures, skill training sessions, live ops, tutorials, and practical workshops
- Internationally accepted and accredited by the German Government, the European Union, the Washington Accord and the Bologna Process
- Science-based and practice-orientated on highest national and international level
- Increased patient satisfaction: minimal contact reduced vibration and pain

**RWTH INTERNATIONAL
ACADEMY
AACHEN UNIVERSITY**

RWTH International Academy
Kackertstraße 10 | 52072 Aachen | Germany
phone +49 241 80 23543 | fax +49 241 80 92525
info@academy.rwth-aachen.de
www.academy.rwth-aachen.de

AALZ

Aachen Dental Laser Center

AALZ GmbH
Pauwelsstraße 17 | 52074 Aachen | Germany
phone +49241 47 57 13 10 | fax +49 241 47 57 13 29
info@aalz.de
www.aalz.de



PROFESSIONAL EDUCATION PROGRAMMES

Your contact for more information: Leon Vanweersch • vanweersch@aalz.de - www.aalz.de

Nd:YAG laser-assisted removal of instrument fragments

Dr Georgi Tomov, Bulgaria

The Nd:YAG lasers tested in laboratory studies have been claimed to be able to successfully manage the removal of instrument fragments within root canals¹⁻⁴. This is done in four ways, all correlated to temperature effects:

1. Laser melts the dentine around the fragment and then Hedstrom files are used to bypass and retrieve the fragment.
2. Laser melts the entire fragment.
3. Laser energy melts the solder, connecting the fractured instrument with a brass tube charged with solder and placed at the exposed coronal end of the fragment.
4. Laser welds the file fragment positioned within a metal hollow tube (e.g. Endo-Eze[®] Tip, Ultradent Products; Figs. 1a & b).

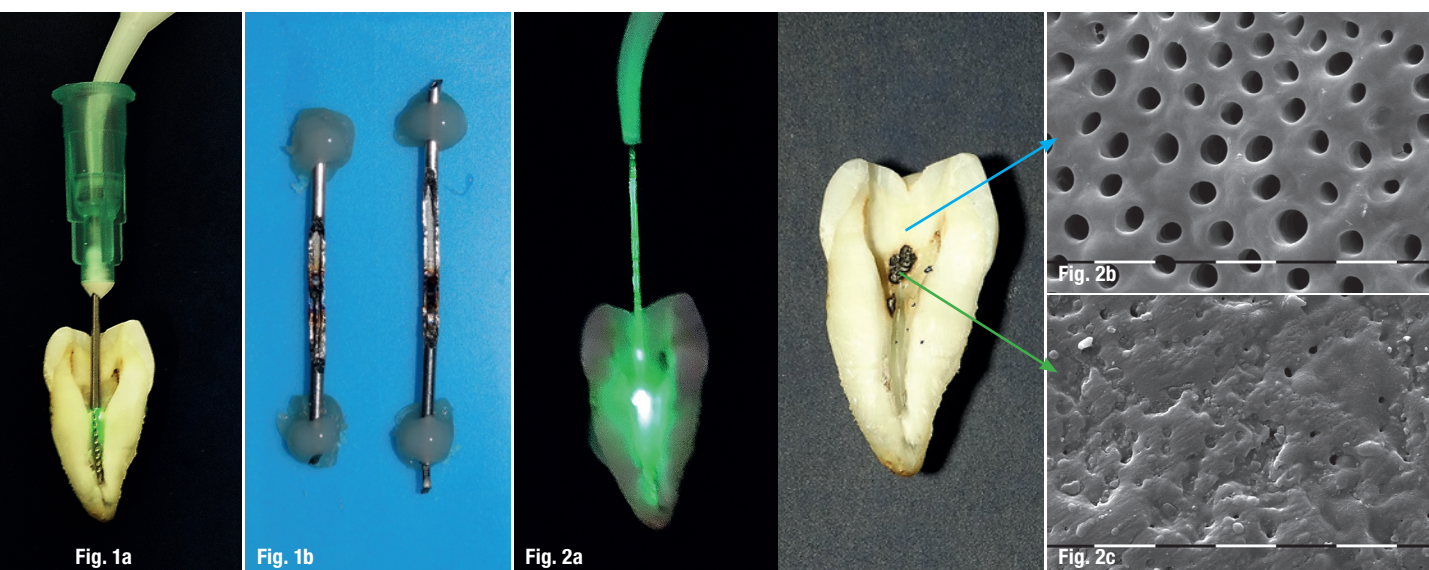
The removal of a claimed minimum amount of root dentine^{1,2,4} can be attributed to the potential given to the user of Nd:YAG laser to distinguish dentine¹ from obstructions by the difference in acoustics produced by the two materials. Ebihara et al. observed that some orifices of the dentinal tubules were blocked with melted dentine after

laser irradiation.¹ Yu et al. found that the temperature rose by 17 °C to 27 °C, but argued that, since the initial temperature was lower than human body temperature, these results were irrelevant.²

The findings demonstrated that a pulsed Nd:YAG laser irradiation has the capability of removing broken files. The success rate reported by Yu et al. was 55 per cent.² However, the thermal effects found after Nd:YAG irradiation in dry root canals were considerable (Figs. 2a-c). Thus, the focus now is on the outcomes of using a laser fibre inserted into a hollow tube (alone or in the presence of solder) both to avoid dentinal carbonisation and to achieve welding between the separated file and metal tube.

Intraoral laser welding

The intraoral laser welding phenomenon is well researched.¹⁻⁴ Even for metals that absorb well, such as steel, the laser light is initially reflected. A small percentage of the laser light is absorbed, heating the metal surface.



Figs. 1a & b: Welding of separated K-type file in Endo-Eze[®] Tip (18 gauge) using Nd:YAG laser irradiation at 400 mJ and 10 Hz **(a)**. Longitudinally cross-sectioned metal tubes with melted K-type files inside **(b)**. **Figs. 2a-c:** Undesirable thermal effects of Nd:YAG irradiation (3W, 300 mJ, 10 Hz) in a dry root canal **(a)**. When the optic fibre comes into contact with the dentinal wall it can cause carbonisation and melting. SEM image of a control dentinal surface **(b)** and dentine irradiated with an Nd:YAG laser, revealing areas of melting and dentinal tubule closure **(c)**.




Fig. 3: SEM image of a K-type file after Nd:YAG laser irradiation at 400 mJ and 10 Hz revealing a melted metal surface with an irregular granular structure after solidification.

The increased surface temperature increases the absorption of the laser power. This creates a snowball effect, in which the material is rapidly heated by the laser, leading to melting and the consequent formation of a weld.

Hagiwara et al. performed laser welding on stainless steel or nickel-titanium files using an Nd:YAG laser in order to evaluate the retention force between the files and the metal extractor.³ Additionally, they evaluated the increase in temperature on the root surface during laser irradiation. They reported that the retention force on stainless steel was significantly greater than that on nickel-titanium. The maximum temperature increase was 4.1 °C. The temperature increase on the root surface was greater in the vicinity of the welded area than at the apical area. Scanning electron microscopy (SEM) revealed that the files and extractors were welded together. Similar results were found by Tomov (unpublished data; Fig. 3).


In vitro study

Cviki et al. used a brass tube charged with solder and placed at the coronal end of the fractured instrument in their *in vitro* experiment.⁴ Nd:YAG laser energy was used to melt the solder, connecting the fractured instrument with the brass tube. They reported that the fractured end-

odontic instruments were removed successfully in 17 out of 22 cases (77.3 per cent) in which more than 1.5 mm was tangible. When less than 1.5 mm was tangible, the removal success rate decreased to three out of 11 cases (27.3 per cent).

These results obtained from *in vitro* experiments indicate that the laser welding method is effective in removing broken instruments from root canals, but its efficacy has to be further verified in clinical trials.


All figures: © Georgi Tomov, 2016



contact

Dr Georgi T. Tomov

DDS, MS, PhD
Associate Professor and Head of
the Department of Oral Pathology
Faculty of Dental Medicine
Medical University of Plovdiv
Bulgaria
dr.g.tomov@gmail.com



Kurz & bündig

Im Zuge von Laborstudien wurden Nd:YAG-Laser bereits erfolgreich, mit dem Ziel Instrumentenfragmente aus Wurzelkanälen zu entfernen, genutzt. Dies kann auf vier verschiedene Arten erfolgen, jeweils korrelierend mit temperaturinduzierten Effekten. Der Autor betont, dass in früheren Studien von geschmolzenem Dentin verschlossene Dentintubuli festzustellen waren, welche durch die Nd:YAG-Laserbestrahlung verursacht wurden. Die thermalen Effekte erwiesen sich besonders bei trockenen Wurzelkanälen als erheblich. Um diese Dentinkarbonisierung und -schmelze zu vermeiden, legt sich der Fokus nun verstärkt auf Laserschweißen, d.h. das Fragment wird (meist mithilfe von Lötmetall) innerhalb einer Messingröhre unter Verwendung von Lichtleitfasern gebunden und entfernt. Im Ergebnis von In-vitro-Experimenten erwies sich diese Methode des Laserschweißens als effektiv im Entfernen abgebrochener endodontischer Instrumente aus Wurzelkanälen. Ihre Effizienz gilt es, in klinischen Versuchen weiter zu belegen.

Gingival depigmentation using diode laser

A non-ablative technique with test patch

Dr Chayanee Prakongsantikul & Assoc. Prof. Dr Sajee Sattayut, Thailand

Gingival hyperpigmentation is a condition affecting aesthetic appearance. There are many techniques for treating gingival hyperpigmentation, but still no technique available for patients to select a satisfactory gingival colour. In this case report, we present a technique of gingival depigmentation using a diode laser that provides a test patch for the patient to decide on the gingival colour.

Introduction

Nowadays, people are increasingly concerned about aesthetics. The appearance of the smile is affected by not only the teeth but also the gingivae. Much of gingival hyperpigmentation is due to normal physiological variation rather than being pathological in nature. In this case report, although it did not present any medical problems,

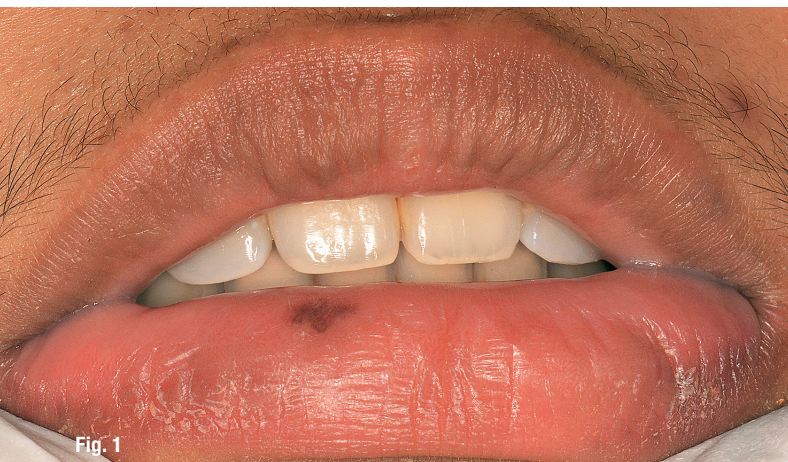

Fig. 1

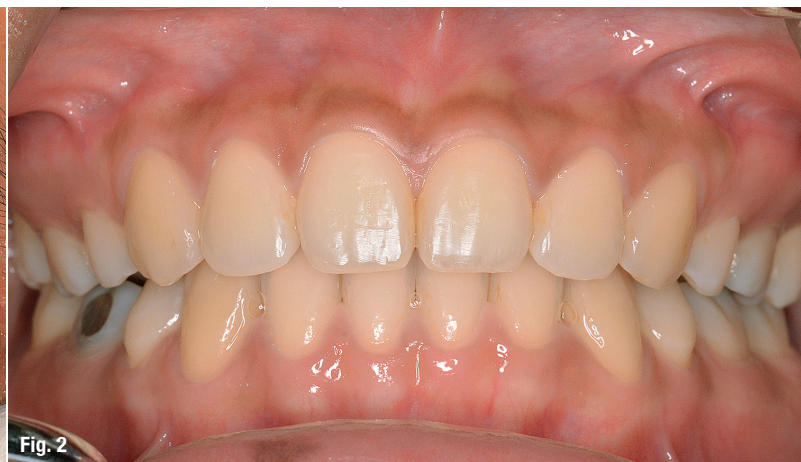

Fig. 2

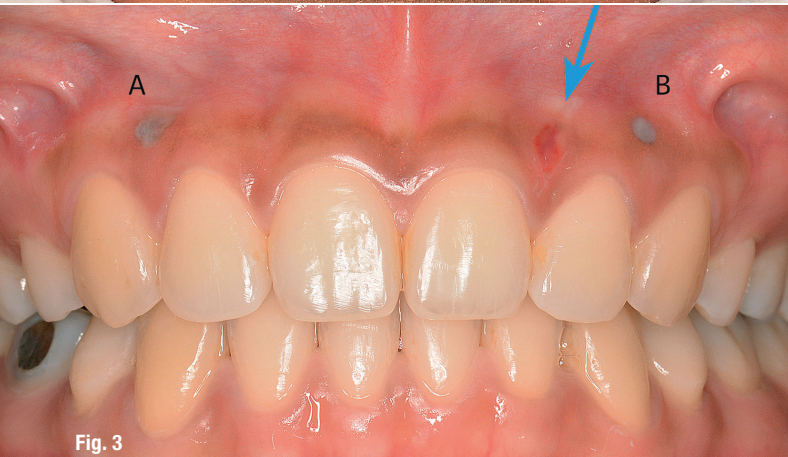

Fig. 3

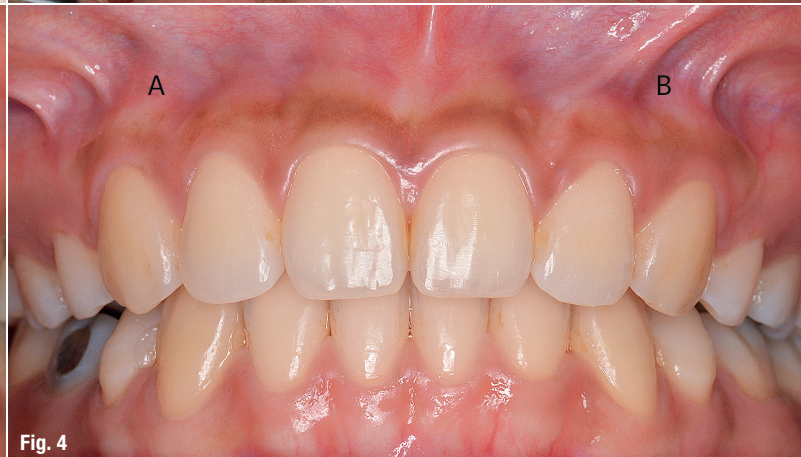

Fig. 4

Fig. 1: A melanotic macule of the lower lip. **Fig. 2:** Pre-op hyperpigmentation of the gingiva of the maxillary anterior teeth. **Fig. 3:** Test patches as indicated by A and B. The blue arrow is pointed to an incisional biopsy area. **Fig. 4:** Two weeks after laser dose testing and incisional biopsy, complete healing of the gingiva was observed. The patient was able to detect the difference in colour between the areas treated with Settings A and B.

it was an aesthetic concern for our patient and appeared as darkened gingiva.¹

There are many techniques for the treatment of gingival hyperpigmentation, such as gingivectomy using scalpel, rotary, electrosurgery, laser and chemical agents to resurface the gingiva and applying cryosurgery to eliminate melanotic cells.²⁻⁴ These abrasive techniques involve a non-favourable appearance during the healing process. Even though depigmentation using a carbon dioxide laser provides less discomfort, wound coverage using a gingival dressing is still needed.⁴ Non-abrasive techniques that use laser for gingival depigmentation are worth investigating, as well as the technique of using a tissue testing patch for fulfilling aesthetic concerns.

This case report presents a new non-abrasive technique using an 808 nm diode laser in the case of physiological hyperpigmentation of the gingiva. The laser test patches were used before treating the whole area in order to gain greater patient satisfaction regarding the gingival colour.

Case report

A 22-year-old Thai woman presented to the oral surgery clinic, faculty of dentistry at Khon Kaen University, complaining of brownish gingiva, particularly at the maxillary anterior teeth. The patient reported no underlying disease or any medicine allergy. Furthermore, she reported no history of smoking. Extraoral examination found an oral pigmented lesion at the lower lip (Fig. 1). Intraoral examination found pigmented lesions at the attached gingivae from the maxillary right canine to the maxillary left canine (Fig. 2). The patient was diagnosed with physiological pigmentation of the gingiva and a melanotic macule on the lower lip.

Incisional biopsy was conducted under local anaesthesia at the attached gingiva between the maxillary left central incisor and the lateral incision in order to determine the depth of the melanin pigment in the gingiva. Haemostasis was achieved using an 808nm diode laser at 0.5W for 5 seconds (Fig. 3).

Then the two test patches were undertaken at the attached gingiva (Fig. 3) between the maxillary right lateral

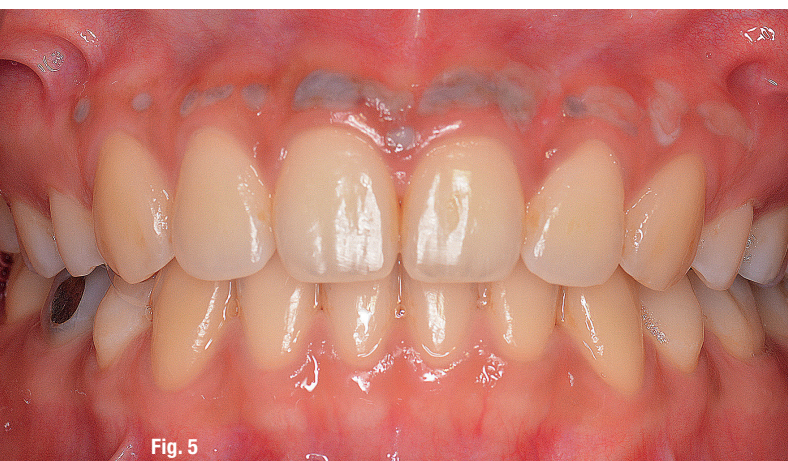

Fig. 5

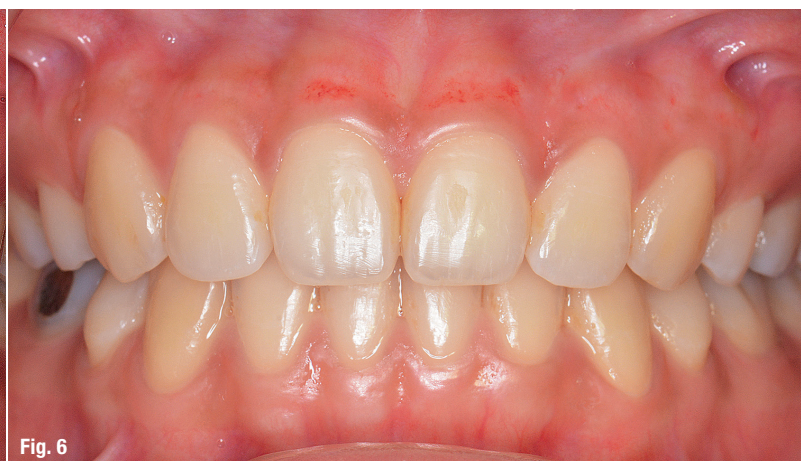

Fig. 6

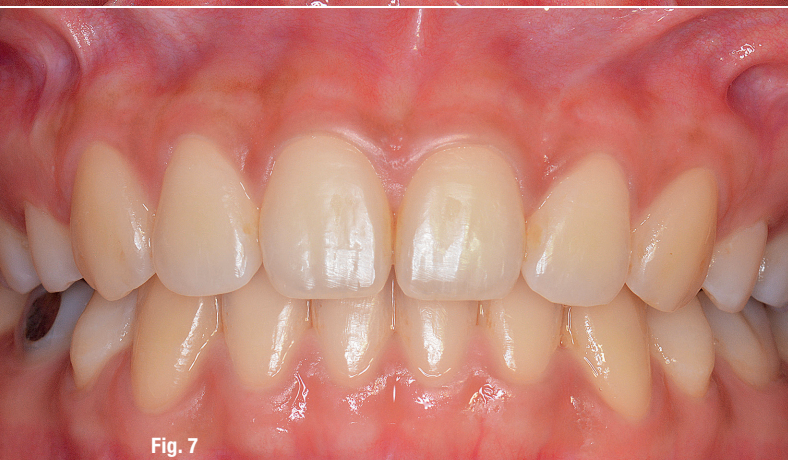

Fig. 7

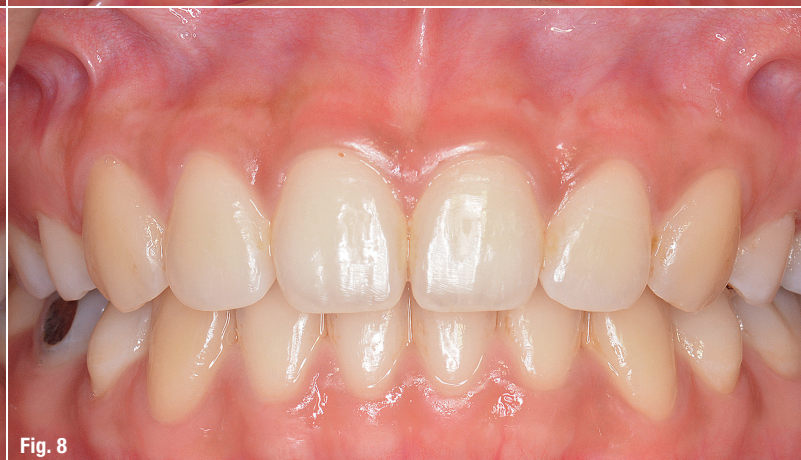

Fig. 8

Fig. 5: The immediate post-laser depigmentation photograph showed no photo-ablative effect. **Fig. 6:** After seven days, the area treated showed partial recovery with mildly reddened gingiva at the central incisors. There was no ulcerated area clinically. **Fig. 7:** After two weeks, the area treated showed complete healing of the gingiva. **Fig. 8:** After three weeks, the area treated showed uniformly normal-coloured gingiva.