

**DENTAL PROFESSIONALS**

# DENTAL TRIBUNE

The World's Dental Newspaper · Middle East & Africa Edition

PUBLISHED IN DUBAI

www.dental-tribune.me

September-October 2017 | No. 5, Vol. 7

**ENDO TRIBUNE**

Cleaning is Key

All roads lead south

►A1-4

**LAB TRIBUNE**

Many ways with one material

inLab MC X5: Open 5-axis production unit...

►B1-4

**HYGIENE TRIBUNE**

Unique worldwide Dental Hygiene Conference on Social Responsibility a Huge Success

►C1-8

**IMPLANT TRIBUNE**

A proven heritage

Advancing levels of precision in dental implants...

►D1-4

**ORTHO TRIBUNE**

Oral hygiene in orthodontics

Insignia™ Resolves Adult Open Bite...

►E1-4

## Where Science Meets The Art Of Beauty

By Dental Tribune MEA/CAPPmea

"Where Science Meets The Art Of Beauty" is the theme for this years' fast approaching 9th Dental Facial Cosmetic Conference/Exhibition (DFCIC) to be held at the InterContinental Festival City, Dubai from 01-05 November 2017. The 9th DFCIC will host over 36 international dental experts from various countries and dental specialties, the experts will be there with a single goal to share their knowledge and expertise with our attendees.

Beyond the excellent scientific content that will be offered at the 9th DFCIC, we will also be hosting over 35 companies that have signed up for exhibiting their latest products, which you will not only be able to interact with but also purchase the latest tools, materials, trends and developments to help your practice advance further.

Keeping regional requirements and challenges in mind, CAPP Events has also innovated a new approach to providing FREE CME in partnership with chosen exhibitors to maximize your time and engagement. Being a science lead conference, there is also space allocated for the research driven members of the dental community to display their latest research posters which will lead to a healthy scientific discourse and display the direction of the most current regional research.

For the keen amongst you, CAPP Events has also organized 20 hands-on training courses pre- and post-conference between 01-05 November 2017. These hands-on courses have been designed in a way to appeal to both the General Dentists and the Specialists across the board with current hot topics. Ranging from Minimal Invasive Veneers to the Diagnosis and Management of Dentofacial



Deformities and everything in between (full list provided below).

The conference will be accredited by DHA and HAAD and enjoys up to 35 CE Credits through CAPP as an ADA CERP Recognized Provider of Continuing Education.

**Dental Hygienist Seminar**

This years event is a continuation of the partner-

ship between CAPP and Colgate Oral Care Academy with the support of the International Federation for Dental Hygienists (IFDH). In keeping with the current regional needs, the consortium wanted to highlight the needs of the Dental Hygienists who are a growing segment in the local dental profession. The specialized skills of a dental hygienist are necessary to keep our patients' oral

►Page 2



## 9<sup>TH</sup> DENTAL FACIAL COSMETIC CONFERENCE

Conference/Exhibition: 03-04 November 2017

Hands-On Courses: 01-05 November 2017

35 CME in one week

InterContinental Hotel | DFC | Dubai



**14 CME conference**

Page 2 Final Conference Final Program

Page 2 Hands-On Courses Program

Page C1 Dental Hygienist Seminar in Hygiene Tribune

Page 37 Free Exhibition & Free Training at the Exhibition area

REGISTER NOW: E: events@cappmea.com | T: +971 4 3476747 | F: +971 4 3476867 | M: +971 50 2793711

[www.cappmea.com/aesthetic](http://www.cappmea.com/aesthetic)

## ◀Page 1

cavity disease free and because of this fact and with the essential support of Colgate Oral Care Academy, we have arranged a whole day of education for the Dental Hygienist. The Dental Hygienist Seminar is a full day event within the DFCIC which will take place on Friday 03 November 2017 and will see over 7 experts in the field present to all our participants and talk on topics ranging from "Working Posture In Daily Work Life" to "Integrating Oral Cancer Screening Into Your Practice" and "Periodontal Assessment & Diagnosis". Considering the current move towards Implant Dentistry there is also a lecture on "The Hygienists Role In Maintaining Tooth Supported And Implant Supported Restorations".

**At a Glance**

• 35 CME at a Glance at various booths inside the trade show /exhibition – Over 30 leading dental manufacturers to showcase latest novelties (03-04 Nov 2017)

- 9th Dental Facial Cosmetic Int'l Conference (03-04 Nov 2017)
  - Dental Hygienist Symposium (03 Nov 2017)
  - Hands-On courses (01-05 Nov 2017)
1. Treatment Planning And Functional Smile Design: Dynamic Smile Analysis, Face Analysis And Teeth Selection, By Dr. Eduardo Mahn (7 CE Credits)
  2. The All Ceramic Course: How To Choose The Best Ceramic Material And Prepare For The Different Type Of Crowns We Currently Have?, By Dr. Eduardo Mahn (7 CE Credits)
  3. Advanced Restorative Masterclass – Aesthetic Indirect Restorations, By Prof. Brian Millar & Bill Sharpling (7 CE Credits)
  4. Minimal Invasive And Non-Prep Veneers: Smart Smile Design With Veneers, By Asst. Prof. Dr. Cagdas Kislaoglu, Part 1 (7 CE Credits)
  5. Minimal Invasive And Non-Prep Veneers: Smart Smile Design With Veneers, By Asst. Prof. Dr. Cagdas Kislaoglu, Part 1 (7 CE Credits)

6. Introduction to designing surgical implant guides by Dr. Alexandros Manolakis
7. Direct Veneers: How To Create The Right Shape And Texture And Achieve The Desired Shade, By Dr. Eduardo Mahn (7 CE Credits)
8. Enhanced Biofilm Management Using Modern Air Polishing Techniques, By Mary Mowbray (2 CE Credits)
9. Master Class With Novel Biocare, By Dr. Tristan Staas
10. ITOP: Individually Trained Oral Prophylaxis, By Dr. Carla Mora (7 CE Credits)
11. Post-Endodontic Treatment: Should We Place Posts, Do Crowns Or Just Composites And Onlays?, By Dr. Eduardo Mahn (7 CE Credits)
12. The New Concept of ABB – Certification Course, By Dr. Andrew Wallace (7 CE Credits)
13. Class IV Restorations, By Dr. Matthew Holyoak (6 CE Credits)
14. Periodontal Instrumentation & Sharpening, By Mary Rose Pincelli

15. Working Posture, By Dr. Penelope Jones (3 CE Credits)
16. Veneers Demystified: A Masterclass Hands-On Workshop For Clinical Success, By Dr. Ozair Banday (7 CE Credits)
17. New Concepts And Innovation In The Diagnosis And Management Of Dentofacial Malformations, By Dr. Ashraf Ayoub (7 CE Credits)
18. Endodontics For the 21st Century, The 3Dimensional Revolution, By Prof. James Prichard (7 CE Credits)
19. Indirect Veneers, By Dr. Munir Silwadi (7 CE Credits)
20. Veneers Vs Crowns: The Challenge In Smile Design, Dr. Eduardo Mahn (7 CE Credits)

**REGISTER NOW**

W: [www.cappmea.com/aesthetic](http://www.cappmea.com/aesthetic)  
Tel: +971 4 347 6747  
Fax: +971 4 347 6867  
Mob: +971 50 2793711  
E-mail: [events@cappmea.com](mailto:events@cappmea.com)



## 9<sup>TH</sup> DENTAL FACIAL COSMETIC CONFERENCE

InterContinental Hotel, DFC  
Dubai, UAE

Conference/Exhibition: 03-04 November 2017

Hands-On Courses: 01-05 November 2017

35 CME in one week

### Preliminary Program | 03-04 Nov

**Dr. Daniel Vasquez, USA**

Lecture: *The Power of One Visit Dentistry*  
Lecture: *Smile Design 360*

**Dr. Knut Hufschmidt, Austria**

Lecture: *No Limits! - The World of Direct Restorations*  
Lecture: *Esthetic Solutions! - From Single Tooth...*

**Prof. James Prichard, UK, BARD Faculty**

Lecture: *From Reciprocation to Rotation...*

**Prof. Louis Hardan, Lebanon**

Lecture: *Direct Composite Restorations: Simplified...*

**Prof. Emilio Carlos Zanatta, Brazil**

Lecture: *Interdisciplinary Dentistry: Occlusion Aspects*

**Prof. Ashraf Ayoub, UK**

Lecture: *New Concepts and Innovations in...*

**Prof. Hien Chi Ngo, Australia**

Lecture: *Minimal Intervention Management of Erosion*

**Prof. Dr. Péter Windisch, Hungary**

Lecture: *Hard- and Soft Tissue Corrections around...*

**Dr. Matthew Holyoak, UK, BARD Faculty**

Lecture: *Diagnosis & Management of Tooth Surface...*

### Hands-On Courses | 01-05 Nov

**Dr. Eduardo Mahn, Chile | 01-05 Nov**

*Treatment Planning and Functional Smile Design: Dynamic Smile...*  
*The All Ceramic Course: How to Choose the Best Ceramic Material and...*  
*Direct Veneers: How to Create the Right Shape and Texture and Achieve...*  
*Post-Endodontic-Treatment: Should We Place Posts, Do Crowns or...*  
*Veneers Vs Crowns: The Challenge in Smile Design*

**Prof. Brian Millar & Bill Sharpling, UK | 02 Nov**

*Advanced Restorative Masterclass - Aesthetic Indirect Restorations*

**Asst. Prof. Dr. Çağdaş Kışlaoğlu, Turkey | 02-03 Nov**

*Minimal Invasive and Non Prep Veneers... Day 1*  
*Minimal Invasive and Non Prep Veneers... Day 2*

**Dr. Alexandros Manolakis, Greece | 03 Nov**

*Introduction to Designing Surgical Implant Guides*

**Mary Mowbray, New Zealand | 03 Nov**

*Enhanced Biofilm Management Using Modern Air Polishing Technique*

**Dr. Tristan Staas, The Netherlands | 03 Nov**

*Master Class With Nobel Biocare*

**Dr. Andrew Wallace, UK, Inman Aligner Academy | 04 Nov**

*The New Concept of Alignment, Bleaching and Bonding*  
*Inman Aligner – Certification*

**Dr. Tristan Staas, Netherlands**

Lecture: *Immediate Replacement, A Biologic Concept...*

**Dr. Faysal Succaria, Lebanon**

Lecture: *Veneer Cementation: Mechanics and Esthetics*

**Dr. Manuel Roman, Spain**

Lecture: *Designing Smiles with Digital Clear Aligner...*  
Lecture: *Complex Treatments with Dental Implants...*

**Dr. Andrew Wallace, UK, Inman Aligner Academy**

Lecture: *Progressive Smile Design. An Introduction*

**Dr. Ozair Banday, USA**

Lecture: *Full Mouth Rehabilitation with Comprehensive*  
Lecture: *Treatment Planning to Achieve Optimal...*

**Dr. Carla Mora, Chile**

Lecture: *iTOP: Individually Trained Oral Prophylaxis*

**Dr. Mario J. Besek, Switzerland**

Lecture: *An other Dimension of Composite Restoration*

**Dr. Med. Dent. Alexandros Manolakis, Greece**

Lecture: *Single Implant Restorations in the Aesthetic...*

**Dr. Matthew Holyoak, UK | 04 Nov**

*Class IV Restorations*

**Robyn Watson, Australia & Mary Rose Pincelli Boglione, Italy | 04 Nov**

*Periodontal Instrumentation & Sharpening*

**Dr. Carla Mora, Chile | 04 Nov**

*iTOP: Individually Trained Oral Prophylaxis*

**Dr. Penelope Jones, Australia | 04 Nov**

*WorkingPosture*

**Prof. James Prichard, UK | 05 Nov**

*Endodontics for the 21st Century, the 3Dimensional Revolution*

**Prof. Ashraf Ayoub, UK | 05 Nov**

*New Concepts and Innovations in the Diagnosis and Management of Dentofacial Malformations*

**Dr. Ozair Banday, USA | 05 Nov**

*Veneers Demystified: A Masterclass Hands-On Workshop for Clinical...*

**Dr. Munir Silwadi, UAE | 05 Nov**

*Indirect Veneers*

**14 CME**  
conference

**Submit Your**  
Poster Presentation

REGISTER NOW: E: [events@cappmea.com](mailto:events@cappmea.com) | T: +971 4 3476747 | F: +971 4 3476867 | M: +971 50 2793711

[www.cappmea.com/aesthetic](http://www.cappmea.com/aesthetic)

**IMPRINT**

**GROUP EDITOR**  
Daniel ZIMMERMANN  
[newsroom@dental-tribune.com](mailto:newsroom@dental-tribune.com)  
Tel.: +44 161 223 1830

**CLINICAL EDITORS**  
Magda WOJTKIEWICZ  
Nathalie SCHÜLLER

**EDITORS**  
Kristin HÜBNER  
Yvonne BACHMANN

**EDITOR & SOCIAL MEDIA MANAGER**  
Monique MEHLER

**MANAGING EDITOR & HEAD OF DTI COMMUNICATION SERVICES**  
Marc CHALUPSKY

**COPY EDITOR**  
Sabrina RAAFF

**PUBLISHER/PRESIDENT/CEO**  
Torsten R. OEMUS

**CHIEF FINANCIAL OFFICER**  
Dan WUNDERLICH

**CHIEF TECHNOLOGY OFFICER**  
Serban VERES

**BUSINESS DEVELOPMENT MANAGER**  
Claudia SALWICZEK-MAJONEK

**PROJECT MANAGER ONLINE**  
Tom CARVALHO

**JUNIOR PROJECT MANAGER ONLINE**  
Hannes KUSCHICK

**E-LEARNING MANAGER**  
Lars HOFFMANN

**EDUCATION DIRECTOR TRIBUNE CME**  
Christiane FERRET

**EVENT SERVICES/PROJECT MANAGER TRIBUNE CME & CROIXTURE**  
Sarah SCHUBERT

**TEAM ASSISTANT**  
Julia MACIEJEK

**MARKETING SERVICES**  
Nadine DEHMEL

**SALES SERVICES**  
Nicole ANDRA

**ACCOUNTING SERVICES**  
Anja MAYWALD  
Karen HAMATSCHEK  
Manuela HUNGER

**MEDIA SALES MANAGERS**  
Antje KAHNT (International)  
Barbora SOLAROVA (Eastern Europe)  
Hélène CARPENTIER (Europe)  
Maria KAISER (North America)  
Matthias DIESSNER (Key Accounts)  
Melissa BROWN (International)  
Peter WITTECZEK (Asia Pacific)  
Weridiana MAGESWKI (Latin America)

**EXECUTIVE PRODUCER**  
Gernot MEYER

**ADVERTISING DISPOSITION**  
Marius MEZGER

**DENTAL TRIBUNE INTERNATIONAL**  
Holbeinstr. 29, 04229 Leipzig, Germany  
Tel.: +49 341 48 474 302  
Fax: +49 341 48 474 173  
[www.dental-tribune.com](http://www.dental-tribune.com)  
[info@dental-tribune.com](mailto:info@dental-tribune.com)

**DENTAL TRIBUNE ASIA PACIFIC LTD.**  
Room A, 20/F  
Harvard Commercial Building  
105-111 Thomson Road, Wanchai, HK  
Tel.: +852 3113 6177  
Fax: +852 3113 6199

**THE AMERICA, LLC**  
116 West 23rd Street, Ste. 500, New York  
N.Y. 10011, USA  
Tel.: +1 212 244 7181  
Fax: +1 212 244 7185

**DENTAL TRIBUNE MEA EDITION EDITORIAL BOARD**

Prof. Khaled BALTO, KSA  
Prof. Paul TIPTON, UK  
Dr. Aisha SULTAN ALSUWAIDI, UAE  
Dr. Ninette BANDAY, UAE  
Dr. Nabeel HUMOOD ALSABEEHA, UAE  
Dr. Mohammad AL-OBAIDA, KSA  
Dr. Meshari F. ALQTAIBI, KSA  
Dr. Jasim M. AL-SAEEDI, Oman  
Dr. Mohammed AL-DARWISH, Qatar  
Dr. Dobrina MOLLOVA, UAE  
Dr. Ahmed Kazi BDS, MScD(Impl.), MSc(OMFS), UAE  
Dr. Munir SILWADI, UAE  
Dr. Khaled ABOUSEADA, KSA  
Dr. Rabih ABI NADER, UAE  
Dr. Ehab RASHED, UAE  
Aiham FARRAH, CDT, UAE  
Retty M. MATTHEW, UAE

**PARTNERS**

Saudi Dental Society  
Lebanese Dental Association  
Qatar Dental Society  
Oman Dental Society

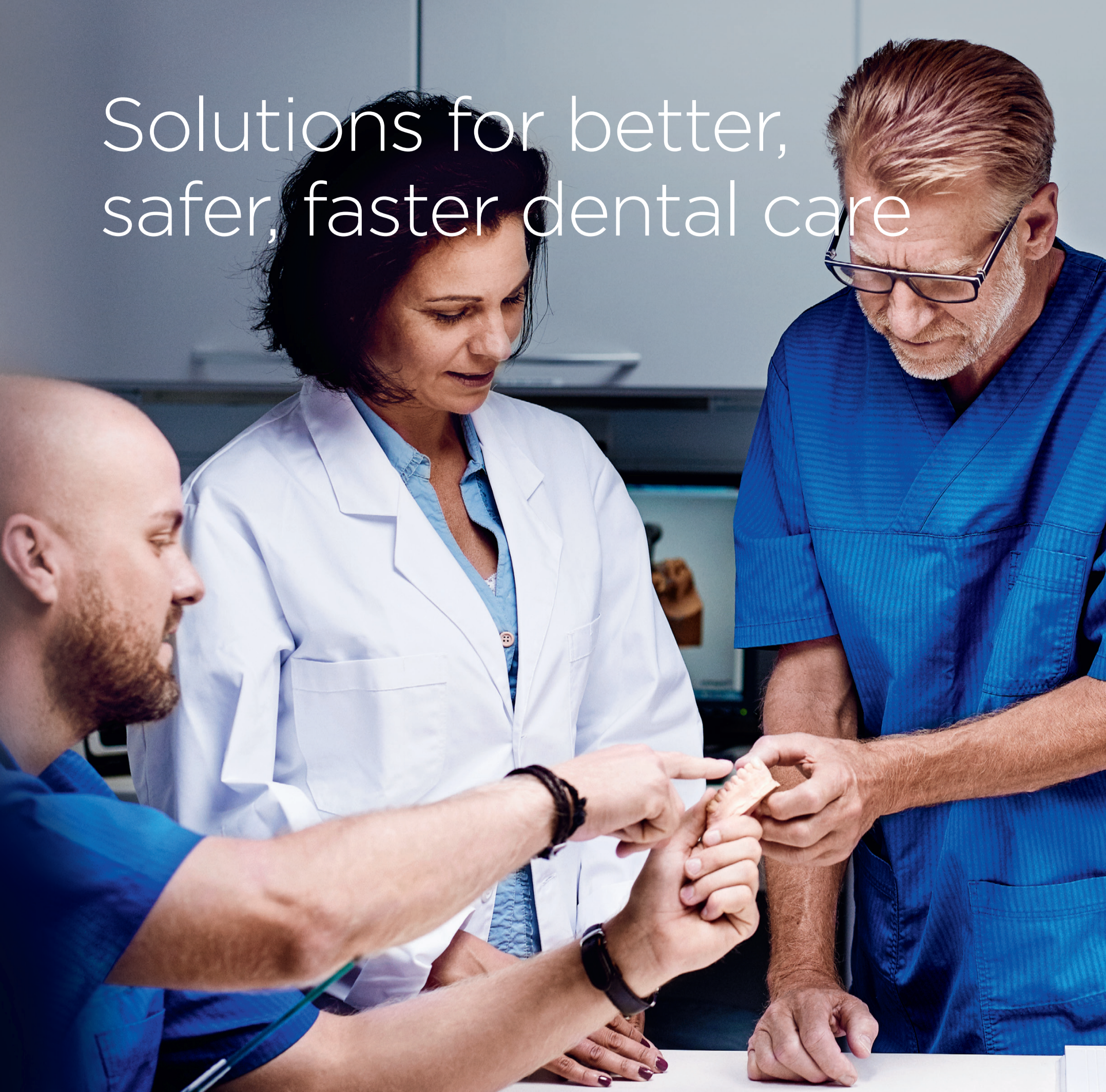**DIRECTOR OF mCME**  
Dr. Dobrina MOLLOVA  
[mollova@dental-tribune.me](mailto:mollova@dental-tribune.me)  
Tel.: +971 50 42 43072

**DIRECTOR**  
Tzvetan DEYANOV  
[deyanov@dental-tribune.me](mailto:deyanov@dental-tribune.me)  
Tel.: +971 55 11 28 581

**DESIGNER**  
Kinga ROMIK  
[k.romik@dental-tribune.me](mailto:k.romik@dental-tribune.me)

**PRINTING HOUSE & DISTRIBUTION**  
Al Nisr Printing  
P. O. Box 6519, Dubai, UAE  
800 4585/04-4067170

# Solutions for better, safer, faster dental care



Dentsply and Sirona have joined forces to become the world's largest provider of professional dental solutions. Our trusted brands have empowered dental professionals to provide better, safer and faster care in all fields of dentistry for over 100 years. However, as advanced as dentistry is today, together we are committed to making it even better. Everything we do is about helping you deliver the best possible dental care, for the benefit of your patients and practice.

Find out more on  
[dentsplysirona.com](https://dentsplysirona.com)

#### Clinical Procedures

- Preventive
- Restorative
- Orthodontics
- Endodontics
- Implants
- Prosthetics

#### Platform Technologies

- CAD/CAM
- Imaging Systems
- Treatment Centers
- Instruments

THE DENTAL  
SOLUTIONS  
COMPANY™

 **Dentsply  
Sirona**

# Class II Amalgam Replacement

By Dr. Robert Margeas, USA

## About the Case

The patient presented with recurrent decay under an aging amalgam. Because of the presence of decay as well as the depth of the prep, Vitrebond™ Light Cure Glass Ionomer Liner/Base was chosen and applied to the deepest dentin. After application of the liner, the selective etch approach using Single Bond Universal Adhesive was chosen for its excellent seal on enamel margins while minimizing the chance of post-operative sensitivity. Once the adhesive is cured, Filtek™ Bulk Fill Posterior Restorative was placed in a single increment up to 5mm. Post-operative photos taken two weeks after placement indicate a very pleasing result.

## Challenge

A deep Class II restoration can be prone to post-operative sensitivity. Use of a liner/

base such as Vitrebond™ Liner/Base, as well as a self-etch bonding approach on dentin, combines two techniques for keeping post-operative sensitivity to a minimum. Once the bonding agent is in place, the bulk fill approach allows for a fast, efficient placement technique for posterior restorations.

## The 3M Difference

3M innovations such as Single Bond Universal Adhesive, Filtek™ Bulk Fill Posterior Restorative and Sof-Lex™ Spiral Finishing and Polishing Wheels\* provide an efficient and simple procedure while also reducing costly chair time. In cases where deep posterior restorations are presented, Vitrebond™ Light Cure Glass Ionomer Liner/Base can reduce the risk of post-op sensitivity. <sup>DT</sup>

## Dr. Robert Margeas, DDS

Dr. Robert Margeas currently serves as Adjunct Professor in the Department of Operative Dentistry at the University of Iowa College of Dentistry. He is also the Clinical Director and Instructor at the Center for Esthetic Excellence, Chicago, IL. Dr. Margeas has published numerous articles on esthetic dentistry and is a highly sought after international lecturer on the subject. His credentials include board certification by

the American Board of Operative Dentistry and he is a Fellow of the Academy of General Dentistry (AGD). Dr. Margeas is on the Editorial Board for Contemporary Esthetics and is a consultant in Oral Health matters for the country of Canada. He maintains a very successful private practice, with a focus on comprehensive esthetic restorative dentistry, in Des Moines, IA.

## Step by Step

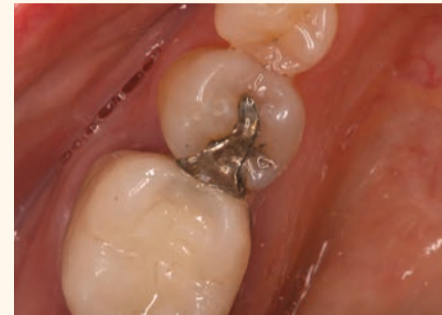

Fig. 1: Pre-operative condition

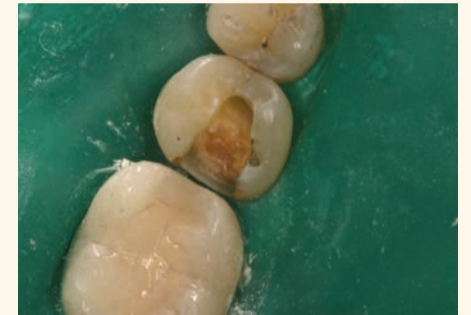

Fig. 2: After removal of failing amalgam

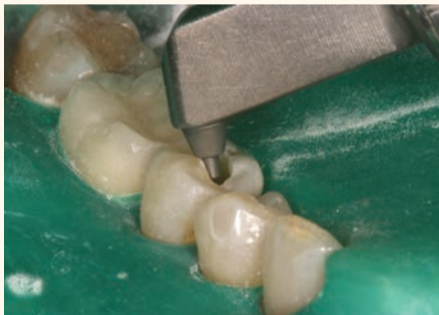

Fig. 3: Use of micro air abrasion to clean the cavity preparation

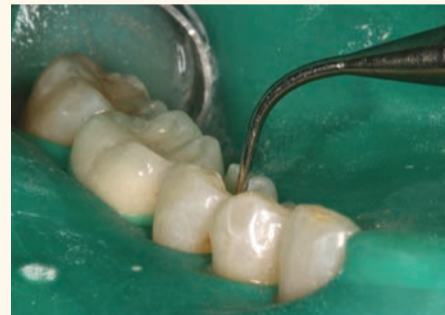

Fig. 4: Application of Vitrebond™ Light Cure Glass Ionomer Liner/Base

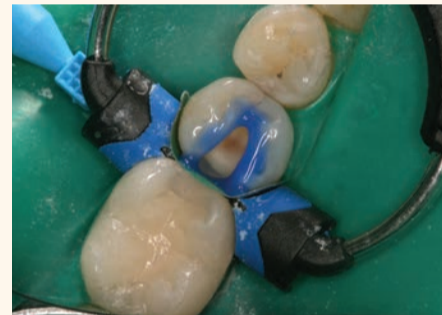

Fig. 5: Etchant applied using the selective enamel etch technique

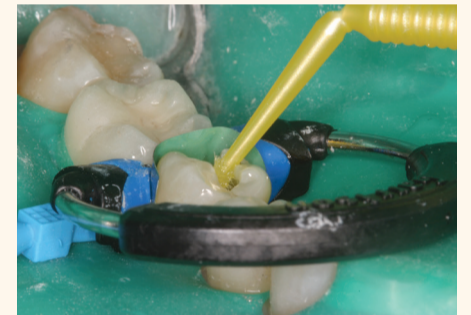


Fig. 6: Application of Single Bond Universal Adhesive

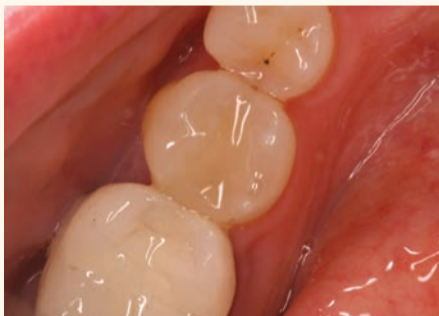

Fig. 7: Placement of Filtek™ Bulk Fill Posterior Restorative in a single increment

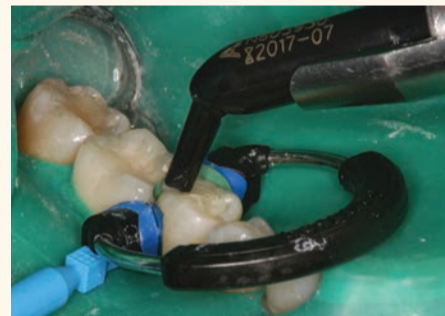

Fig. 8: Polishing with Sof-Lex™ Spiral Polishing Wheel (white)\*

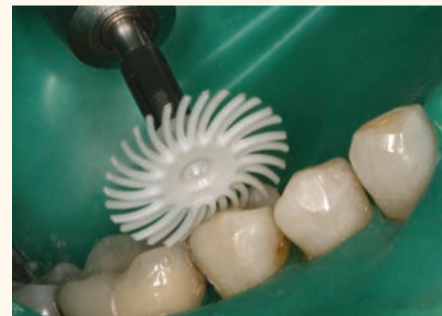

Fig. 9: Immediately post-polishing; adjacent enamel is still desiccated

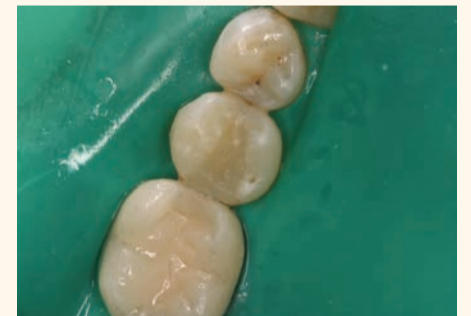

Fig. 10: Final restoration, two weeks post-op

\*Replaced with the new Sof-Lex™ Diamond Polishing system consisting of two new wheels - pre-polishing spiral (beige) and diamond-impregnated polishing spiral (pink).

## Total versatility Uncompromising performance

By 3M

Simplifying the bonding step is no easy task. That's why 3M developed 3M™ Single Bond Universal Adhesive. It's a single-bottle solution that offers a simple one-step, one-coat, 35-second application—without compromising strength. Years of clinical evaluations have stacked the evidence. It can be used in all etching techniques, including total-etch, self-etch and selective-etch; in both direct and indirect applications; and on all dental surfaces, without any extra primer—taking versatility to a whole new level. <sup>DT</sup>

Virtually no post-operative sensitivity in total-etch or self-etch applications.

Total number of total-etch restorations: 3,467

0.4%  
Percent of total-etch restorations with 3M™ Single Bond Universal Adhesive having post-op sensitivity

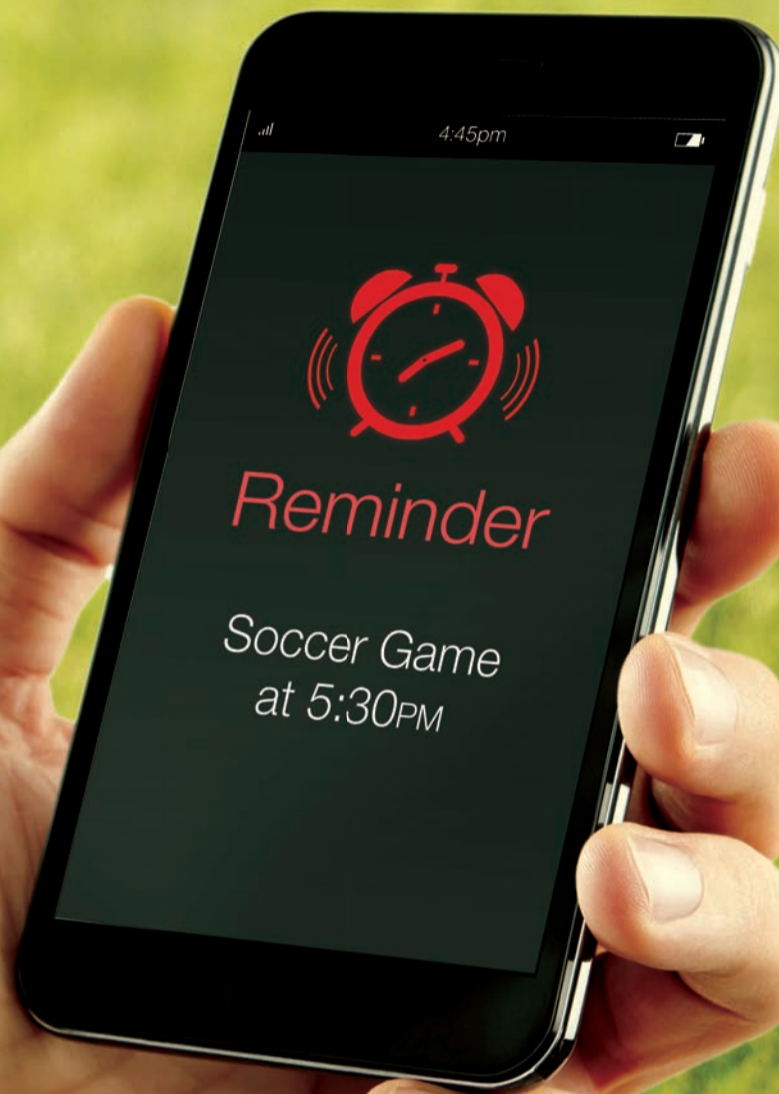Total number of self-etch restorations: 3,495

0.06%  
Percent of self-etch restorations with 3M™ Single Bond Universal Adhesive having post-op sensitivity

Source: 3M internal data

To learn more about 3M™ Single Bond Universal Adhesive please visit [www.3mgulf.com/dental](http://www.3mgulf.com/dental)





3M Oral Care

# Takes less time, so you have more time.

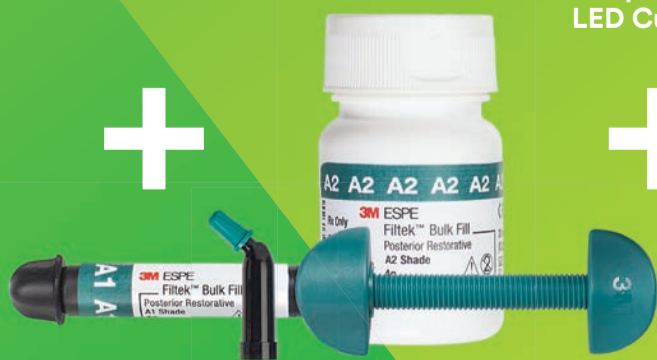There are things in life you don't want to miss. And the more complicated a procedure is, the greater chance there is for something to go wrong and disrupt your day. That's why 3M Oral Care has simplified posterior restorations ... the most frequently performed direct restoration. By using Filtek™ Bulk Fill Posterior Restorative with three other innovative products, you'll move through posterior restorations with speed and simplicity. See how our Posterior Restorative Procedure can help keep you on schedule ... because we know your time outside of work matters.

[www.3MGulf.com/espe](http://www.3MGulf.com/espe)

Single Bond  
Universal Adhesive



Filtek™ Bulk Fill  
Posterior Restorative



Elipar™  
DeepCure-S  
LED Curing Light



Sof-Lex™ Spiral  
Finishing and  
Polishing Wheels



# Implant maintenance with guided Biofilm Therapy

By E.M.S.

With more and more Implants placed, the challenges of the dental professionals increase to remove calculus and biofilm safely and efficiently. E.M.S., the inventor of PI-EZON® and AIR-FLOW® technologies, offers a peek coated Implant tip which guarantees safe and efficient removal of calculus without leaving scratches on the Implant surface. Furthermore the PLUS powder for all

EMS AIR-FLOW devices ensures easy and smooth removal of Biofilm in supra and sub gingival areas around the Implant.

How to best prevent and treat Mucositis and Peri-Implantitis? With PLUS powder and the Perio nozzle for AIR-FLOW it is simple, predictable and ensures superior clinical results. For more information visit the EMS

**EMS**<sup>+</sup>  
MAKE ME SMILE.

booth at the 9th Dental Facial Cosmetic Conference in Dubai on 03-04 November 2017.

You can also look up more details at [www.ems-dental.com](http://www.ems-dental.com) or contact your regional distributor of EMS products. <sup>DT</sup>

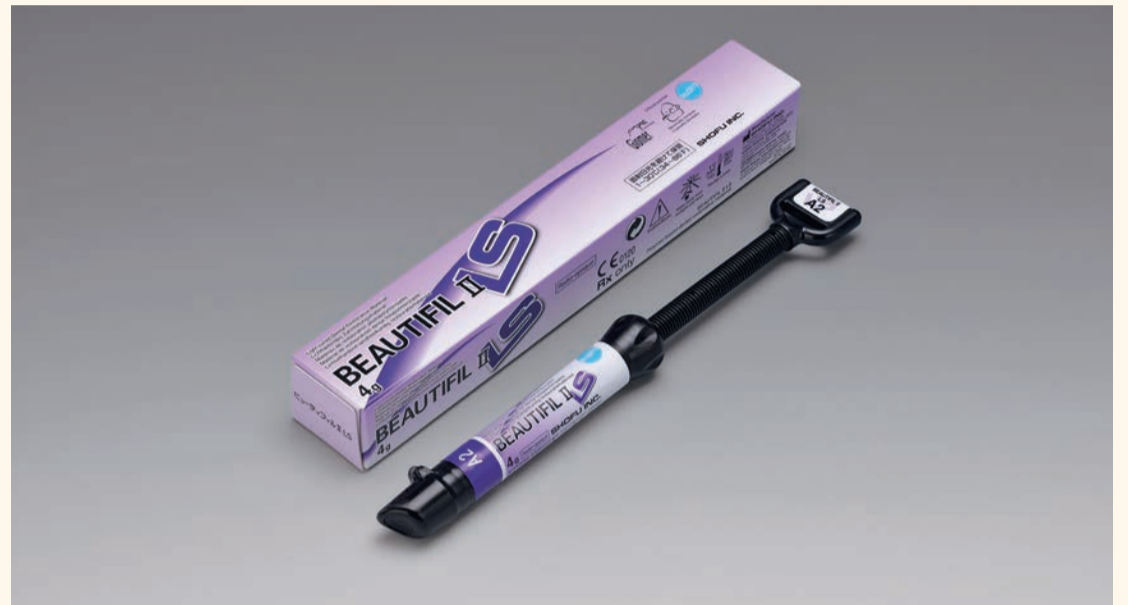## Beautiful II LS

By SHOFU

Beautiful II LS breaks new ground in direct resin technology with its extremely low polymerization shrinkage and related stress while exhibiting superior aesthetics, optimal mechanical properties, ease of handling and polish, lasting natural lustre and remarkable abrasion resistance for universal application. A novel low shrinkage "SRS" monomer formulation and unique filler technology significantly minimizes polymerization shrinkage stress while

resulting in a more durable, robust and stable polymer complex that offers greater predictability to your restorations. Tooth-like optical characteristics enable an easy shade match for a wide spectrum of simple to complex, challenging cases. Beautiful II LS exhibits additional anti-plaque benefits and sustained fluoride protection to all your restorations.

Visit us @DFCIC booth no. 29 for a Hands-on trial of Beautiful II LS and the array of benefits that it offers for your practice! <sup>DT</sup>



Beautiful II LS

## Super-Snap X-Treme Technique Kit



Super-Snap X-Treme Technique Kit

By SHOFU

A comprehensive "new" technique kit from Shofu features the proven Super-Snap (Black-Contouring & Violet-Finishing) and the innovative Super-Snap X-treme (Green-Polishing & Red-Super-polishing) disks in both 12 mm and 8 mm diameter, colour coded for easy identification and sequential use to achieve a natural

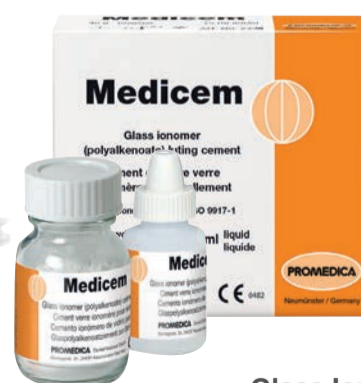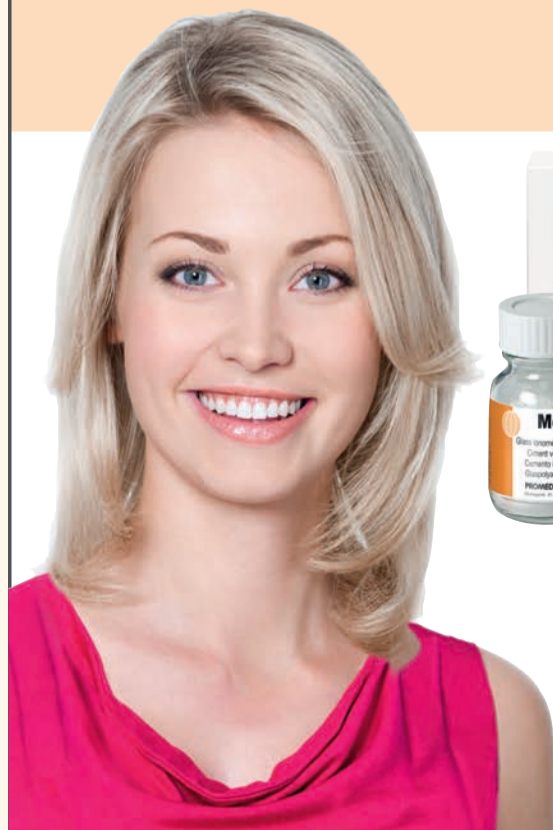and lasting lustre on all direct resin composites. Unique 3D structure of the Super-Snap X-Treme Red disks imparts a satiny smooth and flawless surface on the resin restoration. Double sided Polystrips that correspond to the colour codes of the disks, enable easy interproximal finishing and polishing. The kit also contains Dura White stones, Composite and Composite Fine points

to complement the disks and easily create detailed surface anatomy in direct aesthetic resin restoration.

Try these X-Treme disks and find how you can achieve the most natural polish on your direct aesthetic resin restoration @DFCIC, Booth no. 29 <sup>DT</sup>

## PROMEDICA

Highest quality made in Germany

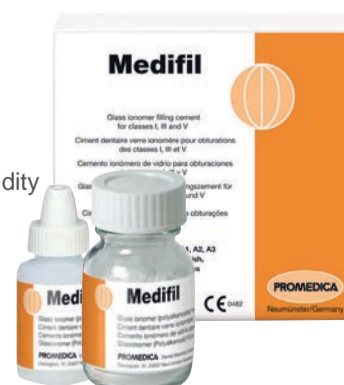

### Glass ionomer luting cement

- High level of adhesion
- Highly biocompatible, low acidity
- Continuous fluoride release
- Precision due to micro-fine film thickness
- Translucency for an aesthetic result

### Glass Ionomer Filling Cement

- For fillings of classe I, III and IV
- Excellent biocompatibility and low acidity
- High compressive strength
- No temperature rise during setting
- Enamel-like translucency
- Excellent radiopacity
- Stable and abrasion resistant



**PROMEDICA**

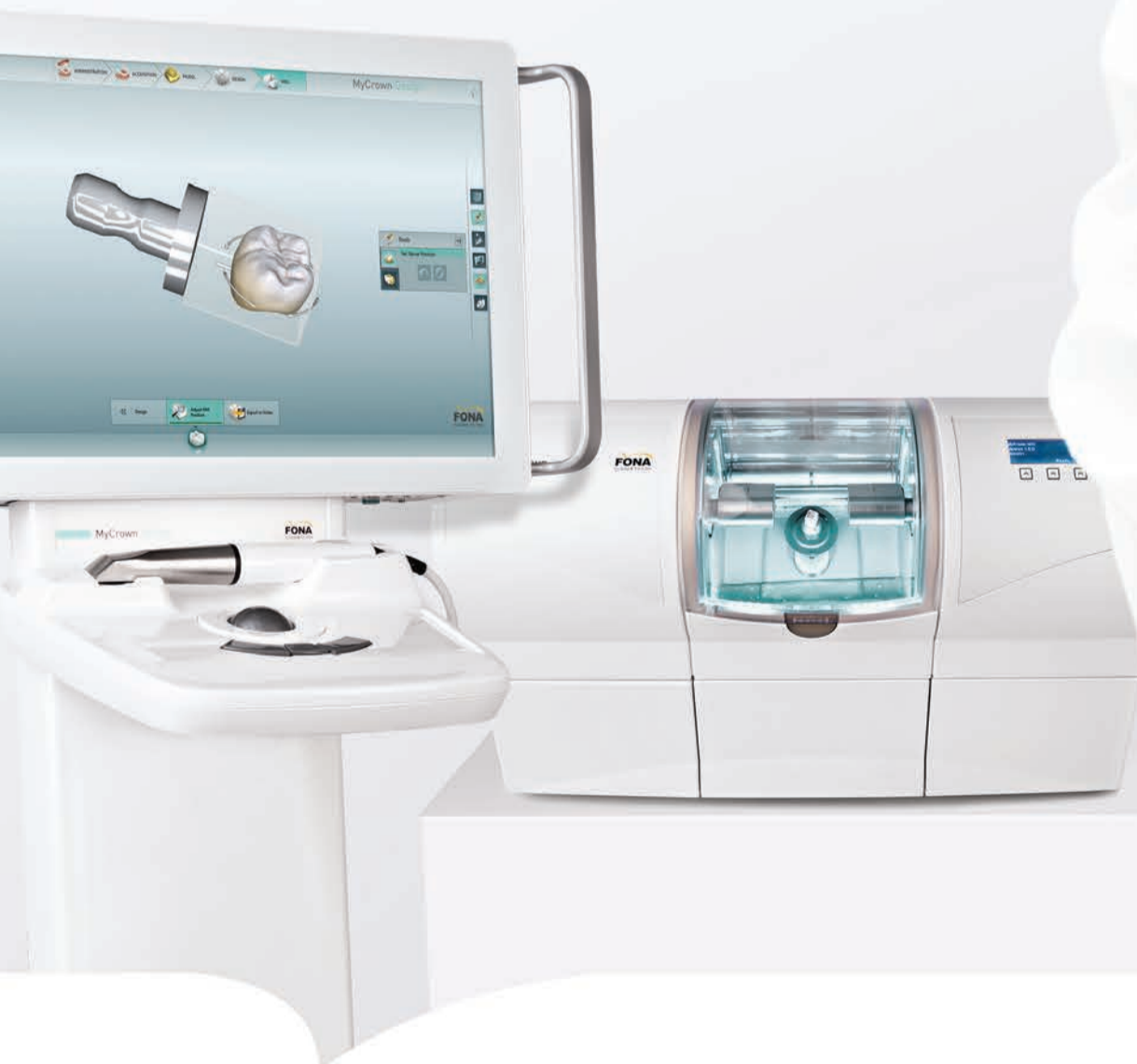**Dental Material GmbH**  
24537 Neumünster / Germany  
Tel. +49 43 21 / 5 41 73  
Fax +49 43 21 / 5 19 08  
eMail [info@promedica.de](mailto:info@promedica.de)  
Internet [www.promedica.de](http://www.promedica.de)

Visit [www.promedica.de](http://www.promedica.de) to see all our products

# MIND BLOWING

## MyCrown

- Fully Integrated System
- Fast and Easy to Use
- Grow Your Clinic



Find out more on  
[www.fonadental.com](http://www.fonadental.com)

**FONA**  
CLOSER TO YOU



# Canal preparation and obturation: An updated view of the two pillars of nonsurgical endodontics

*mCME articles in Dental Tribune have been approved by:*  
**HAAD as having educational content for 1 CME Credit Hour**  
**DHA awarded this program for 1 CPD Credit Point**

**ADA C-E-R-P®** Continuing Education Recognition Program

Centre for Advanced Professional Practices (CAPP) is an ADA CERP Recognized Provider. ADA CERP is a service of the American Dental Association to assist dental professionals in identifying quality providers of continuing dental education. ADA CERP does not approve or endorse individual courses or instructors, nor does it imply acceptance of credit hours by boards of dentistry.

CAPP designates this activity for 1 CE Credit

By Ove A. Peters, USA

The ultimate goal of endodontic treatment is the long-term retention in function of teeth with pulpal or periapical pathosis. Depending on the diagnosis, this therapy typically involves the preparation and obturation of all root canals.

Both steps are critical to an optimal long-term outcome. This article is intended to update clinicians on the current understanding of best practices in the two pillars of nonsurgical endodontics, canal preparation and obturation, and to highlight strategies for decision making in both uncomplicated and more difficult endodontic cases.

Prior to initiating therapy, a clinician must establish a diagnosis, take a thorough patient history and conduct clinical tests. Recently, judicious use of cone-beam computed tomography (CBCT) has augmented the clinically available imaging modalities. Verifying the mental image of canal anatomy goes a long way to promote success in canal preparation. For example, a missed canal frequently is associated with endodontic failures.<sup>1</sup>

As most maxillary molars have two canals in the mesiobuccal root, case referral to an endodontist for microscope-supported treatment should be considered. Endodontists

are increasingly using CBCT and the operating microscope to diagnose and treat anatomically challenging teeth, such as those with unusual root anatomies, congenital variants or iatrogenic alteration. The endodontic specialist, using appropriate strategies, can achieve good outcomes even in cases with significant challenges (Fig. 1).

## Preparation of the endodontic space

The goal of canal preparation is to provide adequate access for disinfecting solutions without making major preparation errors such as perforations, canal transportations, instrument fractures or unnecessary removal of tooth structure. The introduction of nickel-titanium (NiTi) instruments to endodontics almost two decades ago<sup>2</sup> has resulted in dramatic improvements for successful canal preparation for generalists and specialists. Today there are more than 50 canal preparation systems; however, not every instrument system is suitable for every clinician and not all cases lend themselves to rotary preparation.

Several key factors have added versatility in this regard, for example, the emergence of special designs such as orifice shapers and mechanized glide path files. Another recent development is the application of heat

treatment to NiTi alloy, both before and after the file is manufactured. Deeper knowledge of metallurgical properties is desirable for clinicians who want to capitalize on these new alloys. Finally, more recent strategies such as minimally invasive endodontics have emerged.<sup>3</sup>

## Basic nickel titanium metallurgy

What makes NiTi so special? It is highly resistant to corrosion and, more importantly, it is highly elastic and fracture-resistant. NiTi exists reversibly in two conformations, martensite and austenite, depending on external tension and ambient temperature. While steel allows 3 percent elastic deformation, NiTi in the austenitic form can withstand deformations of up to 7 percent without permanent damage or plastic deformation.<sup>4</sup> Knowing this is critical for rotary endodontic instruments for two reasons. First, during preparation of curved canals, forces between the canal wall and abrading instruments are smaller with more elastic instruments, hence less preparation errors are likely to occur.

Second, rotation in curved canals will bend instruments once per rotation, which ultimately will lead to work hardening and brittle fracture, also known as cyclic fatigue. Steel can withstand up to 20 complete bending cycles, while NiTi can endure up to 1,000 cycles.<sup>4</sup>

Recently manufacturers have learned to produce NiTi instruments that are in the martensitic state and even more flexible than previous files. Figure 2 shows how instrument conditions (austenite vs. martensite) are determined in the testing laboratory, using prescribed heating and cooling cycles.<sup>5</sup> Heat-treated files with high martensite content typically do not have a silver metallic shade but are colored due to an oxide layer, such as gold or blue.

It is important to note that CM files frequently deform; however, with a delicate touch, cutting is adequate and often even superior to conventional NiTi instruments.<sup>6</sup> It is imperative for clinicians to retrain themselves prior to using these new instruments to avoid excessive deformation and subsequent instrument fracture.

## Preparation strategies

Experimental and clinical evidence suggests that the use of NiTi instruments combined with rotary movement results in improved preparation quality. Specifically, the incidence of gross preparation errors is greatly reduced.<sup>7</sup> Canals with wide oval or ribbon-shaped cross-sections present difficulties for rotary instruments and strategies such as circumferential filing and ultrasonics should be used in those canals.

Studies found that oscillating instruments recommended for these canal types did not perform as well,<sup>8</sup> particularly in curved canals. Specific

instruments developed to address these challenges include the Self-Adjusting File (SAF) System (ReDent-NOVA, Raana), TRUShape® (Dentsply Sirona, Tulsa, Okla.) and XP Endo® (Brasseler, Savannah, Ga.). However, there is no direct clinical evidence that these instruments lead to better outcomes.

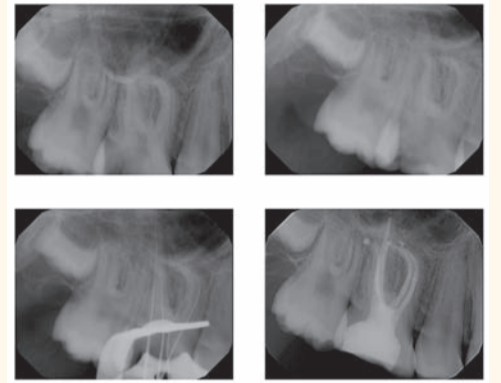
Canal transportation with contemporary NiTi rotaries, measured as undesirable changes of the canal center seen in cross-sections of natural teeth, is usually very small. This indicates that canal walls are not excessively thinned and apical canal paths are only minimally straightened (Fig. 1), even when preparing curved root canals. While preparation usually removes dentin somewhat preferentially toward the outside of the curvature,<sup>9</sup> current NiTi instruments, including reciprocating files, can enlarge the canal path safely while minimizing procedural errors.

Almost all current rotaries are non-landed, meaning they have sharp cutting edges, and they can be used in lateral action toward a specific point on the perimeter. This "brushing" action allows the clinician to actively change canal paths away from the furcation in the coronal and middle thirds of the root canal<sup>10</sup> but may create apical canal straightening when taken beyond the apical constriction. Circumferential engagement of canal walls by active instruments may lead to a threading-in effect, but contemporary rotaries are designed with variable pitch and helical angle to counteract this tendency.

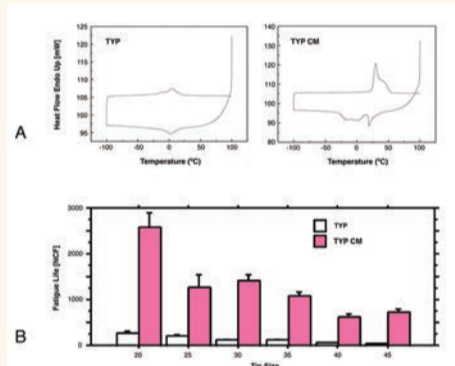
An important design element for all contemporary rotaries is a passive, non-cutting tip that guides the cutting planes to allow for more evenly distributed dentin removal. Rotaries with cutting, active tips such as dedicated retreatment files should be used with caution to avoid preparation errors.

## NiTi instrument usage

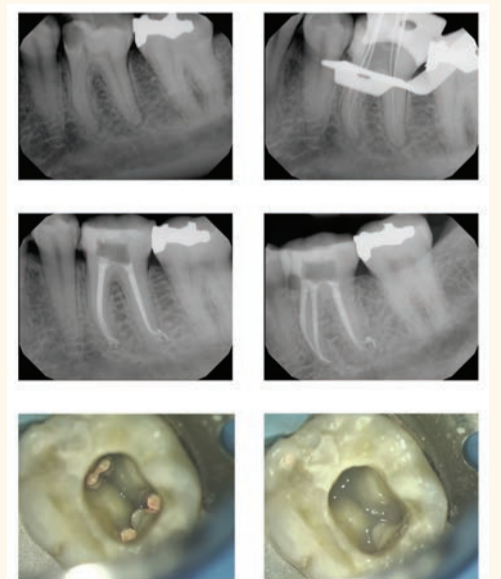
As a general rule, flexible instruments are not very resistant to torsional load but are resistant to cyclic fatigue. Conversely, more rigid files can withstand more torque but are susceptible to fatigue. The greater the amount and the more pe-



**Fig. 1:** Root canal treatment of tooth #3 diagnosed with pulp necrosis and acute apical periodontitis. The mesiobuccal root has a significant curve and two canals with separate apical foramina. Case courtesy of Dr. Jeffrey Kawilarang. (Photos/Provided by American Association of Endodontists)



**Fig. 2:** Behavior of controlled memory nickel-titanium rotaries compared with standard instruments. Shown are data from Typhoon Differential scanning calorimetry, which document the transition between austenite and martensite at about 5 degrees C for standard NiTi and at about 25 degrees C for controlled-memory (CM) alloy (A). At room temperature, this results in a drastically increased fatigue lifespan (B). Image A modified and reprinted with permission from Shen et al. J Endod 2011; 37:1566-1571



**Fig. 3:** Root canal treatment of tooth #19 with four canals diagnosed with irreversible pulpitis and acute apical periodontitis. A second canal in the distal root of a mandibular molar is not infrequent. Note multiple apical foramina in both the mesial and the distal apices. Prior to temporization, the orifices were protected with a barrier of light-curing glass ionomer. Case courtesy of Dr. Paymon Bahrami.

ripheral the distribution of metal in the cross section, the stiffer the file.<sup>11</sup> Therefore, a file with greater taper and larger diameter is more susceptible to fatigue failure; moreover, a canal curvature that is

## mCME SELF INSTRUCTION PROGRAM

CAPPmea together with Dental Tribune provides the opportunity with its mCME - Self Instruction Program a quick and simple way to meet your continuing education needs. mCME offers you the flexibility to work at your own pace through the material from any location at any time. The content is international, drawn from the upper echelon of dental medicine, but also presents a regional outlook in terms of perspective and subject matter.

### Membership

Yearly membership subscription for mCME: 1,100 AED  
 One Time article newspaper subscription: 250 AED per issue. After the payment, you will receive your membership number and allowing you to start the program.

### Completion of mCME

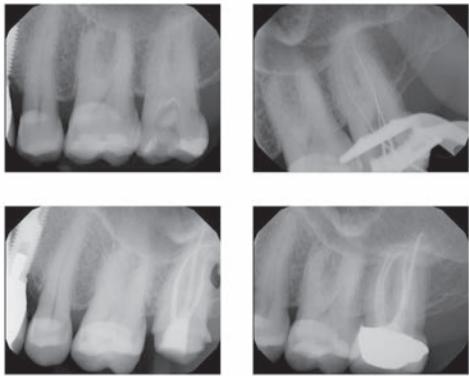
- mCME participants are required to read the continuing medical education (CME) articles published in each issue.
- Each article offers 2 CME Credit and are followed by a quiz Questionnaire online, which is available on [www.cappmea.com/mCME/questionnaires.html](http://www.cappmea.com/mCME/questionnaires.html).
- Each quiz has to be returned to [events@cappmea.com](mailto:events@cappmea.com) or faxed to: +97143686883 in three months from the publication date.
- A minimum passing score of 80% must be achieved in order to claim credit.
- No more than two answered questions can be submitted at the same time
- Validity of the article – 3 months
- Validity of the subscription – 1 year
- Collection of Credit hours: You will receive the summary report with Certificate, maximum one month after the expiry date of your membership. For single subscription certificates and summary reports will be sent one month after the publication of the article.

The answers and critiques published herein have been checked carefully and represent authoritative opinions about the questions concerned.

Articles are available on [www.cappmea.com](http://www.cappmea.com) after the publication. For more information please contact [events@cappmea.com](mailto:events@cappmea.com) or +971 4 3616174

FOR INTERACTION WITH THE AUTHORS FIND THE CONTACT DETAILS AT THE END OF EACH ARTICLE.





**Fig. 4: Root canal treatment of tooth #15 with four canals, diagnosed with irreversible pulpitis and acute apical periodontitis. The tooth was restored with a crown immediately after finalizing the root canal treatment. Case courtesy of Dr. Reza Hamid**

more coronal is more vulnerable to file fracture.

Instrument handling has been shown to be associated with file fracture. For example, a lower rotational speed (~250 rpm) results in delayed build-up of fatigue<sup>12</sup> and reduced incidence of taper lock.<sup>13</sup>

Material imperfections such as microfractures and milling marks are believed to act as fracture initiation sites.<sup>14</sup> Such surface imperfections after manufacturing can be removed by electropolishing but it is unclear if this process extends fatigue life.<sup>15</sup> Manufacturers' recommendations stress that rotaries should be advanced with very light pressure; however, the recommendations differ with regard to the way the instruments are moved. A typical recommendation is to move the instrument into the canal gently in an in-and-out motion for three to four cycles, directed away from the furcation, then withdraw to clean the flutes.

It is difficult to determine exactly the apically exerted force in the clinical setting; experiments have suggested that forces start at about 1 Newton (N) and range up to 5 N.<sup>16</sup> Precise torque limits have been discussed as a means to reduce failure. Most clinicians use torque-controlled motors, which are based on presetting a maximum current for a DC electric motor.

To reduce friction, manufacturers often recommend the use of gel-based lubricants in dentin; however, such lubricants have not been shown to be beneficial and actually did increase torque for radial-landed ProFile® instruments.<sup>17</sup> Therefore, it is recommended to flood the canal system with sodium hypochlorite (NaOCl) during the use of rotaries. The best way to do this is to create an access cavity that can act as a reservoir (Fig. 3).

There are several concerns about reusing NiTi instruments. The effectiveness of disinfection procedures is not clear. It has been shown that protein particles cannot completely be removed from machined nickel-titanium surfaces.<sup>18</sup> Moreover, it is clear that with additional usage, the chance for instrument fracture increases. Current recommendations advise that clinicians are judicious when reusing rotary instruments as there is no conclusive evidence of disease transmission occurring. Recently, the term minimally invasive endodontics has been used to describe smaller-than-usual apical sizes and, perhaps more importantly, an understanding that the long-term success of root canal-treated teeth will improve by retaining as much dentin structure as feasible.<sup>3</sup> The thought process for this was the finding that most root-canal treated teeth survive 10 years and longer.<sup>19</sup> In studies, the reasons cited for the extraction vary but in many cases teeth are either fractured or non-restorable for other reasons.<sup>20,21</sup> In consequence, a smaller coronal dimension of rotaries is considered

while maintaining apical sizes to support antimicrobial efficacy. There currently is no direct clinical evidence to support this strategy but it is clear that root fractures pose problems in the long-term outcomes of our patients. Another recent development is the emergence of certain specialized rotaries, such as dedicated orifice shapers and so-called glide path files. The orifice shapers have larger tapers, such as .08, which means that they are not flexible and can overprepare at the canal orifice level. Glide path files, for example PathFiles® and ProGlider® (Dentsply Sirona), are delicate

instruments and may fracture when used incorrectly. It is recommended to use a small K-file (size #10) before any rotary instrumentation and to use a delicate touch.

### Clinical results

While results from in vitro studies on rotary systems are abundant, clinical studies on these instruments are sparse. Comparing NiTi and stainless steel K-files, Pettiette et al.<sup>7</sup> found less canal transportation and fewer gross preparation errors such as strip perforations. Subsequently, using radiographic evaluation of the same patient group, they demonstrated better healing in the NiTi group.<sup>22</sup> An earlier outcome study with three rotary preparation paradigms did not show any difference between the three systems with an overall favorable outcome rate of about 87 percent.<sup>23</sup>

The most consistent clinical results are obtained when the manufacturer's directions are followed.

While these vary by instrument, a set of common rules applies to root canal preparation. Root canal systems are best prepared in the following sequence:

- Analysis of the specific anatomy of the case.
- Canal scouting.
- Coronal modifications.
- Negotiation to patency.
- Determination of working length.
- Glide path preparation.
- Root canal shaping to desired size.
- Gauging the foramen, apical adjustment.

### Obturation of the endodontic space

A well-shaped and cleaned canal system should create the conditions for intact periapical tissues. On the other hand, this root canal system is inaccessible to the body's immune system and therefore it cannot combat coronal leakage. Accordingly, best practices dictate that root canals should be filled as completely as possible to prevent ingress of nutrients or oral microorganisms.

None of the established techniques for root canal filling provides a definitive coronal, lateral and apical seal.<sup>24</sup>

### Basic strategies in root canal obturation

Ideally, root canal fillings should seal all foramina leading to the periodontium, be without voids, adapt to the instrumented canal walls and end at working length. There are various acceptable materials and techniques to obturate root canal systems, including:

- Sealer (cement/paste/resin) only.
- Sealer and a single cone of a stiff or flexible core material.
- Sealer coating combined with cold compaction of core materials.
- Sealer coating combined with warm compaction of core materials.
- Sealer coating combined with carrier-based core materials.

Several of these techniques have shown comparable success rates re-

garding apical bone fill or healing of periradicular lesions, so a clinician may choose from a variety of techniques and approaches that works best for him or her. Existing research directs clinicians toward preparation and disinfection of the root canal as the single most important factor in the treatment of endodontic pathosis, and no particular sealing technique can claim superior healing success.<sup>25</sup>

### Current developments in root canal obturation materials

After the introduction of MTA (mineral trioxide aggregate) as a material for perforation repair and apical surgery more than two decades ago, materials with similar bioactive properties now are available as root canal sealers. Bioceramic root canal cement (BC Sealer™, Brasseler) has clinically acceptable radiopacity and flow.<sup>26</sup> Moreover, it is well-tolerated in cell culture experiments.<sup>27</sup> However, there is no clinical evidence that using this cement leads to better outcomes.

In fact, most research has indicated the type of cement used has comparatively little impact.<sup>28</sup>

In contemporary practice, heat generators are used to plasticize gutta-percha. Additionally, cordless heating devices are available. Another recent addition is a carrier-based material, Guttacore® (Dentsply Sirona), which uses modified gutta-percha materials instead of plastic as its base. Early data indicate that obturation with this new material is similar to warm vertical compaction or lateral compaction.<sup>29</sup>

### Practical aspects of obturation

The main steps in the sequence of root canal obturation are:

- Choosing a technique and timing the obturation.
- Selecting master cones.
- Canal drying, sealer application.
- Filling the apical portion (lateral and vertical compaction).
- Completing the fill.
- Assessing the quality of the fill.

The root canal system should be assessed before choosing an obturation technique. In the presence of open apices or procedural errors such as apical zipping and also for teeth with apices in close proximity to the mandibular canal, there is significant potential for overfills. In order to avoid such mishaps, these cases may be better obturated with cold lateral condensation to avoid overfilling, or in some cases, MTA may be placed as a barrier.

In general, canals should be filled only when there are no symptoms of acute apical periodontitis or an apical abscess, such as significant pain on percussion or not dryable due to secretion into the canal. Gutta-percha cones first should be disinfected by submerging them in an NaOCl solution for about 60 seconds.

In addition to a solid filler such as gutta-percha, a sealer or cement should be used. Most sealers are toxic in the freshly mixed state, but this toxicity is reduced after setting. When in contact with tissues and tissue fluids, zinc oxide eugenol-based sealers are absorbable while resin-based materials typically are not absorbed.<sup>30</sup> Some by-products of sealers may adversely affect and delay healing. Therefore, sealers should not be routinely extruded into the periradicular tissues.

The appropriate amount of sealer is then deposited into the canal system. This may be done using a lentulo spiral, a K-file or the master cones themselves; each method is acceptable, provided that an appropriate amount of sealer is deposited. If the master cones are the carrier for the sealer, they should be removed and inspected for a complete coating

with sealer and then replaced in the canal.

The master cones are placed close to working length using a slight pumping motion to allow trapped air and the excess sealer to flow in a coronal direction. The marking on the cone should be close to the coronal reference point for working length determination. For lateral compaction, a preselected finger spreader is then slowly inserted alongside the master cone to the marked length and held with measured apical pressure for about 10 seconds. During this procedure, the master cone is pushed laterally and vertically as the clinician feels the compression of the gutta-percha. Rotation of the spreader around its axis will disengage it from the gutta-percha mass and facilitate removal from the canal.

The space created by the spreader is filled by inserting a small, lightly sealer-coated accessory gutta-percha cone. Using auxiliary cones larger than the taper of the spreader will produce voids or sealer pools in the filling and should be avoided. The procedure is repeated by inserting several gutta-percha cones until the entire canal is filled.

For vertical compaction, electrically heated pluggers are used to melt a master cone fitted to length.

Tapered gutta-percha cones optimize the hydraulic forces that arise during compaction of softened gutta-percha with pluggers of a similar taper. After fitting the master cone as before, different hand pluggers and heated pluggers are placed into the root canal to verify a fit to within 5 to 7 mm of the apical constriction.

For both lateral and vertical compaction the gutta-percha mass in each canal should end about 1 mm below the pulpal floor, leaving a small dimple.

In cases where placement of a post is planned, gutta-percha is confined to the apical 5 mm.<sup>31</sup> All root canals that do not receive a post may be protected with an orifice barrier (Fig. 3) to protect from leakage prior to placement of a definitive restoration.<sup>32</sup>

This has been shown to promote healing of apical periodontitis.<sup>33</sup> Materials that are suitable for such a barrier include light-curing glass ionomers, flowable composites or fissure sealants. In order to facilitate retreatment if necessary, such a barrier should be thin so that the gutta-percha fill is just visible.

### Radiographic appearance of filled root canal systems

Prepared and filled canals should demonstrate a homogenous radiopaque appearance, free of voids and filled to working length. The fill should approximate canal walls and extend as much as possible into canal irregularities such as an isthmus or a c-shaped canal system. This is difficult to achieve clinically and frequently requires the clinician to use a thermoplastic obturation technique. This complicated procedure may benefit from the use of the dental operating microscope.

Other anatomical spaces that may be filled include accessory canals that are most common in the apical root third (Fig. 3, mesial and distal root) but may be found in other locations such as the furcation. It has been well established that accessory anatomy may contribute to periapical periodontitis<sup>34</sup> but clinical experience suggests the role of accessory anatomy in causing bone resorption is comparatively small.

Indeed, it appears that filling accessory canals is not predictable and not per se a prerequisite for success.<sup>35</sup> In order to avoid overextension of root filling material into the periapical tissue, specifically in the mandibular canal, it is recommended to accurately determine working

length to prevent destruction of the apical constriction. For infected root canal systems, it seems that the best healing results are achieved when the working length is slightly short of the tip of the root, as visible on a radiograph.<sup>35,36</sup>


Determination of apical canal anatomy is often difficult. It may be appropriate for second mandibular molars that are in close proximity to the mandibular canal to be referred to a specialist. Overfills are not only an impediment to healing but in the worst case can be associated with permanent nerve damage. In general, undesirable and uncorrectable outcomes of root canal treatment, identifiable on the final radiograph, include:

- Excessive dentin removal during access and instrumentation.
- Preparation errors such as perforation, ledge formation and apical zipping.
- Presence of an instrument fragment in not fully disinfected canals.
- Obturation material overfill and overextension.

Each of these outcomes must be documented and the patient notified as they may reduce the likelihood of a successful outcome. In cases such as par- or dysesthesia after an overfill, immediate referral to a surgeon is indicated.

### Summary and conclusions

Root canal preparation with contemporary instruments is a predictable procedure in most cases for a well-trained clinician following established guidelines. Cases with a recognized high degree of difficulty are best referred to an endodontist. While many cases can be treated successfully in routine practice, the additional training, expertise and technology of endodontists is necessary in cases that are beyond the typical spectrum. The best long-term outcomes are obtained when a correctly planned final restoration is placed as soon as possible after root canal treatment is completed (Fig. 4).

Root canals may be filled through various methods, typically using a combination of a cement and a solid filling material such as gutta-percha. The specific obturation material used appears to have a smaller role on outcomes. Overfills, particularly into the area of the inferior alveolar nerve, have the potential to permanently harm a patient. The absence of gross errors that are associated with persistent presence of bacterial infection and excessive dentin removal during access and canal preparation have the greatest impact on outcomes. 

### References

1. Karabucak B, Bunes A, Chehoud C, Kohli MR, Setzer F. Prevalence of apical periodontitis in endodontically treated premolars and molars with untreated canal: A cone-beam computed tomography study. *J Endod* 2016;42:538-41.
2. Walia H, Brantley WA, Gerstein H. An initial investigation of the bending and torsional properties of nitinol root canal files. *J Endod* 1988;14:346-51.
3. Gluskin AH, Peters CI, Peters OA. Minimally invasive endodontics: challenging prevailing paradigms. *Br Dent J* 2014;216:347-53.

*Editorial note: A complete list of references is available from the publisher and also at [www.aae.org/colleagues](http://www.aae.org/colleagues).*

This article originally appeared in *ENDODONTICS: Colleagues for Excellence*, Fall 2016. Reprinted with permission from the American Association of Endodontists, ©2016. The AAE clinical newsletter is available at [www.aae.org/colleagues](http://www.aae.org/colleagues).