

roots

international magazine of

endodontics



opinion

3-D endodontic instrumentation:
Revision of a historical protocol

industry report

Strategies for the treatment of
extremely curved root canals

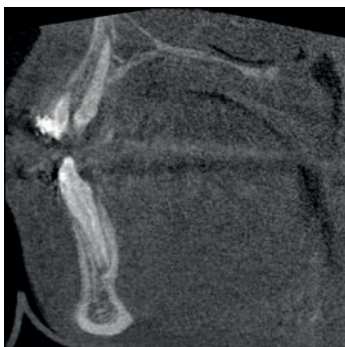case report

Management of referred pain

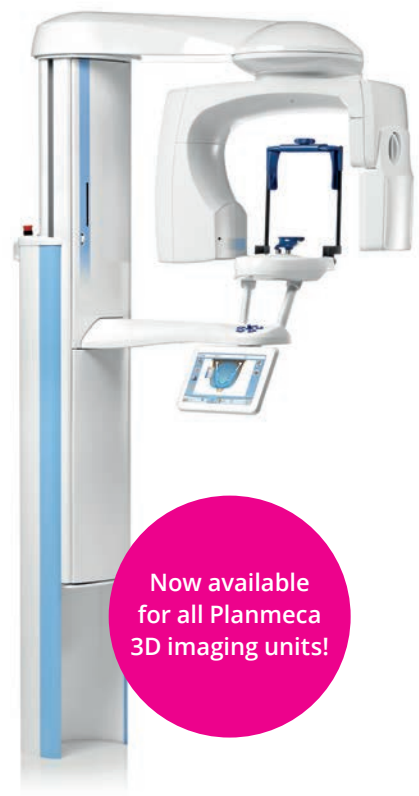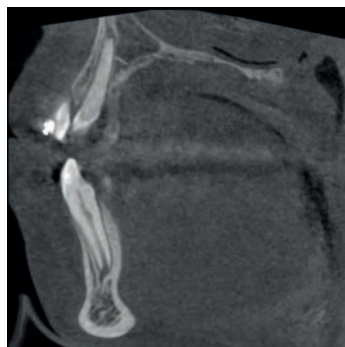
YOUR PATIENTS ARE NOT STATUES, AND THAT'S OK.

Patient movement is the number one contributor to compromised image quality. Our new **Planmeca CALM™** corrective algorithm will allow you to eliminate movement artefacts from CBCT images and succeed every time.

Without Planmeca CALM™



With Planmeca CALM™



Now available
for all Planmeca
3D imaging units!

Find more info and your local dealer!

www.planmeca.com



PLANMECA CALM™

Movement artefact correction for CBCT images

Planmeca Oy Asentajankatu 6, 00880 Helsinki, Finland. Tel. +358 20 7795 500, fax +358 20 7795 555, sales@planmeca.com

Dr Kenneth S. Serota

Guest Editor



$E=mc^3$: Endodontics is equal to the third power of many changes

Revolutionary protocols and materials science demonstrate the evolving sophistication of modern era root canal therapy. The technological advances of the past three decades have enabled greater debridement and disinfection of the labyrinthine root canal space. Iterations of apex locators, enhanced magnification and illumination, new file designs and metallurgy provide for bio-minimalism and diminished fracture potential. The development of bio-active adherent sealers has enhanced the biologic potential of root filling. However, the sum of these innovations has not as yet produced a substantive increase in treatment outcome percentages. For years, clinicians have accepted on faith the purported marketing claims of company-supported *in vitro* testing. Fortunately, scientific determination of the metrics of success of product-neutral studies has replaced the possibility of experimental bias.

The most profound change in endodontics is the recognition that root canal therapy is a restoratively driven discipline. Bio-smart materials used in the root and crown do not require egregious removal of tooth structure as dictated by classical protocols. Clinicians blinded by the optics of the “artistry” of radiographic results are recognizing that this does not represent the totality of the biologic requirements of success.

The “look” academically disenfranchised the clinician from the understanding of the biomechanical dynamics of dentine and its impact on the potential for fracture. The excessive removal of tooth structure to enable treatment needs was counterintuitive to long term success and is fortunately a protocol of the past. As well, the overlooked impact of both light and heavy parafunctional loading on endodontically treated teeth is now recognized as the

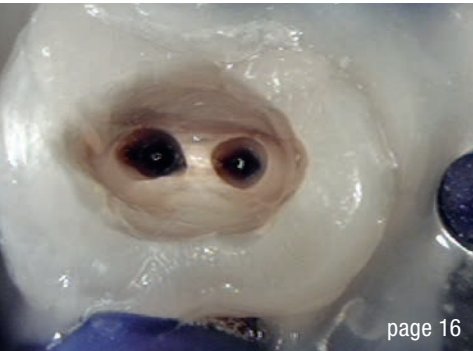most important tipping point in the configuration of the restoration required.

The rigid restorative mandate of posts and cores had the propensity to cause catastrophic failure. Fortunately, reduced taper, new irrigation products have reduced the retention of greater volumes of tooth structure and the costs of new equipment. Overprepared tooth structure is not necessary in the adhesion era.

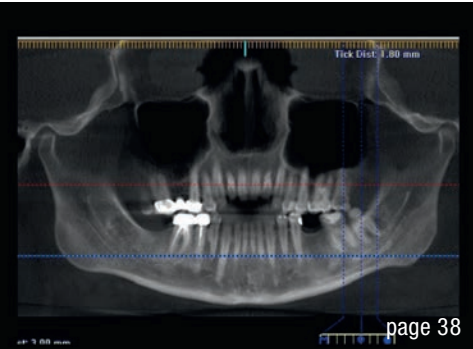
The dogma of the protocol of cleaning shaping, irrigation and “monobloc obturation” is axiomatic folly. The pendulum swings of new equipment and treatments are not necessarily best practices. The primary disease vector of pulpal and peri-radicular is biofilms and to date, the mechanism for their removal remains elusive. The work of Kishen and Shrestha on biofilm disruption by nanoparticles shows the greatest hope for elimination of recrudescence disease as a consequence of biofilm resistance intractability.

The ebbs and flows of endodontic growth, even if measured in dollops, has always have been part of the tenets of interdisciplinary dental therapeutics. The recognition that endodontics is an equal member at the table of disciplines is now assured as it has chosen to extend its involvement beyond the orifice. Endodontics is a foundational component of the state of oral health. Its outreach is now extended to a point commensurate with its potential.


Dr Kenneth S. Serota
Guest Editor



page 16

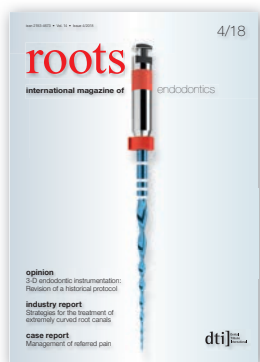

page 38



page 42

Cover image courtesy of VDW
(www.vdw-dental.com)



editorial

$E=mc^3$: **Endodontics** is equal to **the third power** of many changes 03
Dr Kenneth S. Serota (Guest Editor)

opinion

3-D endodontic instrumentation:
Revision of a historical protocol 06
Dr Kenneth S. Serota

industry report

Hand files are heroes in complex anatomies—
A mandibular molar with **seven root canals** 12
Dr Hugo Sousa Dias

Strategies for the treatment of **extremely curved root canals** 16
Dr Bernard Bengs

Endodontic reboot: Adaptive core debridement
and disinfective finishing 22
Drs Gilberto Debelian, Martin Trope & Kenneth S. Serota

case report

Diode laser-assisted **vital pulp therapy** in pulp polyp treatment 28
Drs Maziar Mir, Masoud Mojahedi,
Jan Tunér & Masoud Shabani

Novel applications of a bioactive resin in perforations,
root resorption and endodontic-periodontic lesions 32
Dr Marta Maciak

Management of referred pain 38
Drs Chady Torbay, Sara Salloum, Claudia Dib,
Edgard Jabbour & Philippe Sleiman

practice management

Successful **communication** in your **daily practice**
Part V: Bad online reviews 42
Dr Anna Maria Yiannikos

interview

“We gain a better outcome for endodontic treatment” 44

manufacturer news

46

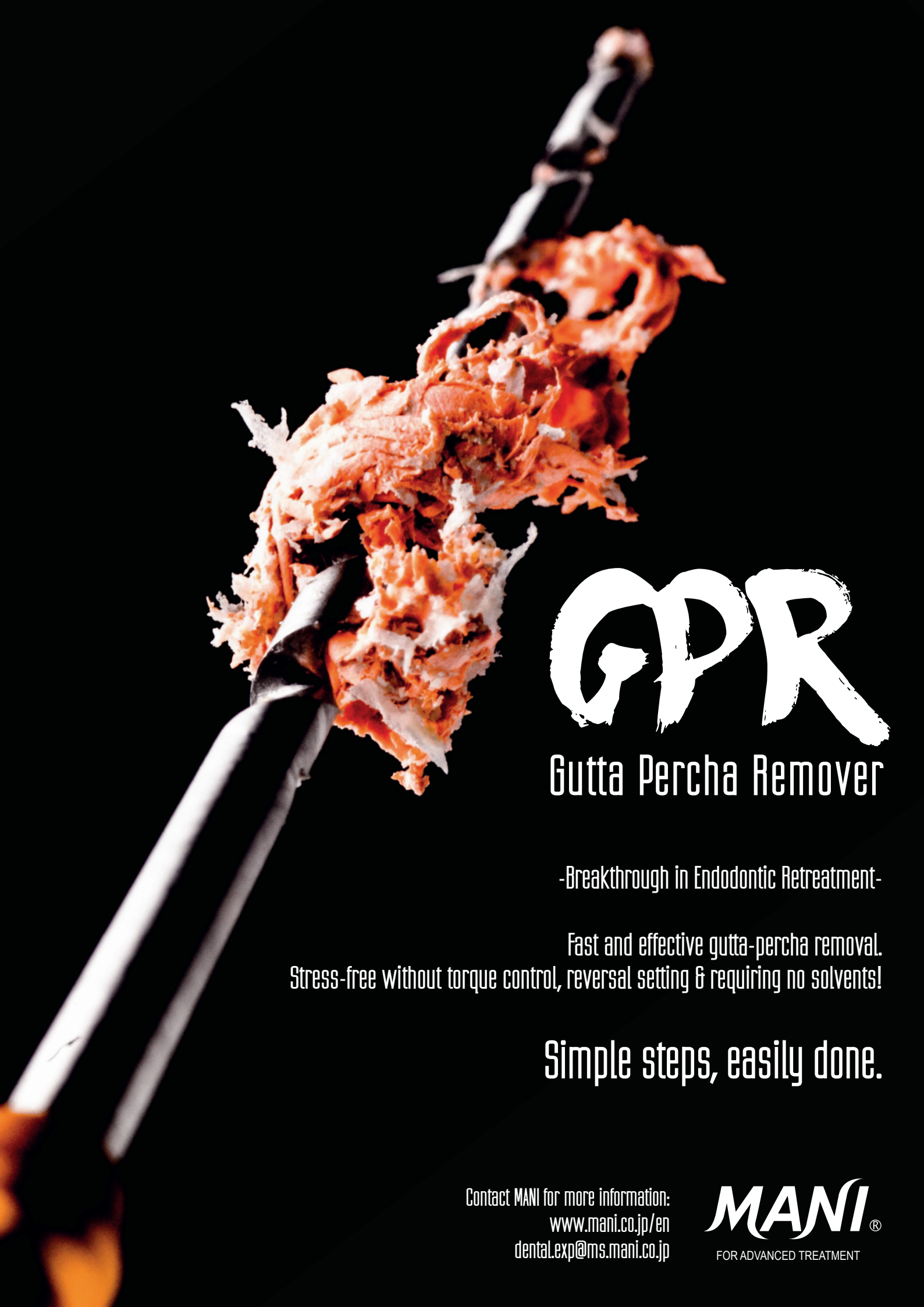meetings

International Events 48

about the publisher

submission guidelines 49

international imprint 50



GPR

Gutta Percha Remover

-Breakthrough in Endodontic Retreatment-

Fast and effective gutta-percha removal.
Stress-free without torque control, reversal setting & requiring no solvents!

Simple steps, easily done.

Contact MANI for more information:
www.mani.co.jp/en
dental.exp@ms.mani.co.jp

MANI[®]
FOR ADVANCED TREATMENT

3-D endodontic instrumentation: Revision of a historical protocol

Dr Kenneth S. Serota, USA

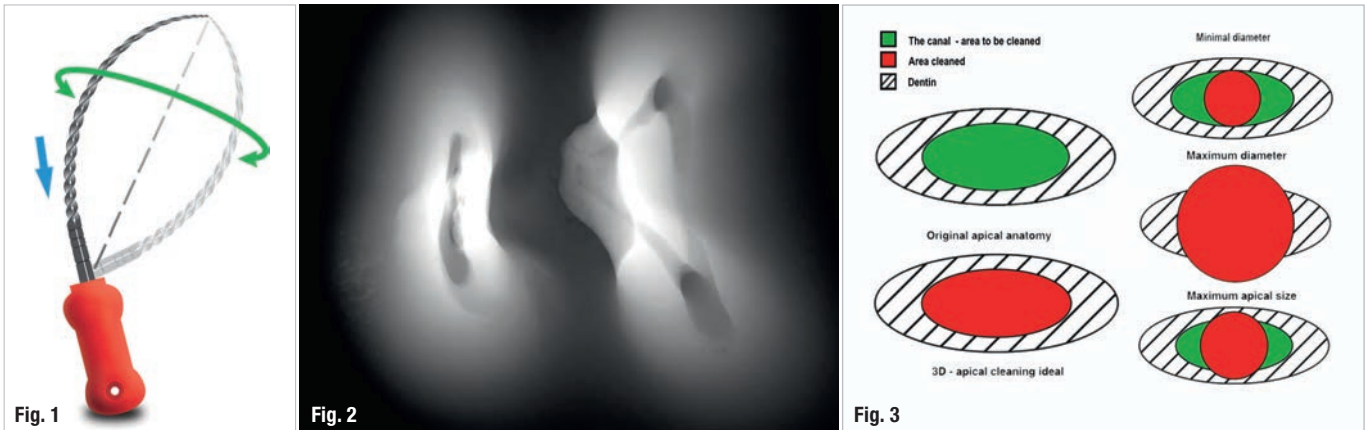


Fig. 1: The envelope of motion, as described by Dr Schilder, is generated by pre-curving a reamer and rotating and withdrawing the instrument during the working cycle. All the work is done on the outstroke, obviating the potential for ledge creation. **Fig. 2:** An axial view (cross section) of the mesial root of a mandibular molar demonstrates that the geometry of the canal space is irregular, elliptic/ovoid, but not round. (Unknown source) **Fig. 3:** The root shape mimics the canal shape. As such, making a round shape using the largest diameter file is clinically impractical. Using a preset taper greater than 0.04 jeopardises the integrity of the root structure.

The past

The goal of the instrumentation phase of root canal therapy is to debride, disinfect and shape the root canal space prior to root filling while retaining an optimal amount of tooth structure. This is of paramount importance in the regions of peri-cervical dentine and isthmus/furcal anatomy.¹ Historically, the significant flaws of stainless-steel

files and reamers were their cutting geometry and rigidity. The technical protocol for these instruments, even Dr Schilder's innovative envelope of motion,² failed to correct debridement inadequacies. The root canal does not natively present in the round; Dr Schilder's approach, while an improvement, failed to address the instrument design and technique changes required to optimise shaping and cleaning of the canal space (Figs. 1 & 2). The root shape




Fig. 4: CBCT provides a z-axis image that demonstrates the number of canals present. As evident in the clinical case, the thinness of the dental isthmus housing the second mesiobuccal canal could readily have been compromised with a round file of the predetermined taper, a serious concern if only the flat film was relied upon. (Courtesy of Dr Martin Trope) **Fig. 5:** Micro-CT shows green (untreated canal) and red (treated portion of the canal after the use of a round file of minimum diameter). Less than 50% of the interfacial dentine was touched and debrided. (Courtesy of Dr Frank Paqué)

mimics the canal shape.³ Therefore, it is impossible to adequately sculpt the interfacial dentine of the canal unless the file chosen corresponds to the largest diameter of the non-round canal (Fig. 3), which can lead to weakening or perforation of the root structure. Studies assessing the planes of geometry of the root canal repeatedly demonstrate that the buccolingual diameter is greater than the mesiodistal diameter—canals are predominantly ovoid throughout the dentition, not round.⁴

Until recently, our reliance upon flat film radiography to assess the spatial dimensions of root filling furthered the lack of appreciation for file taper sizes and flexibility fundamentals. The z-axis was hidden from view in flat film periapical radiographs; only the narrower mesial–distal dimensions of the root canal space were evidenced (Fig. 4). Faux 3-D imagery could be produced in theory by combining of angled mesial, distal and central ray radiographic projections. In 2-D, cleaning to the narrowest diameter appears adequate in post-treatment radiographs. The introduction of microcomputed tomography (μCT) and cone beam computed tomography (CBCT) has changed our understanding of the planes of geometry produced by our current treatment protocols. Mapping of the root canal space by μCT after instrumentation demonstrates that barely 50% of the canal is cleaned (Fig. 5).^{5, 6} The idiom, “you can’t put a square peg into a round hole” suggests an endodontic idiom: you can’t put a round file into an ovoid canal and achieve the desired result.

The most under-appreciated sequela of round files is the creation of significant amounts of dentinal debris. Traditionally, the focus has been on the debris pushed through the apex during instrumentation to avoid post-treatment pain caused by periapical inflammation. The assumption that residual debris moves coronally and is flushed from the canal by irrigants is questionable. In fact,

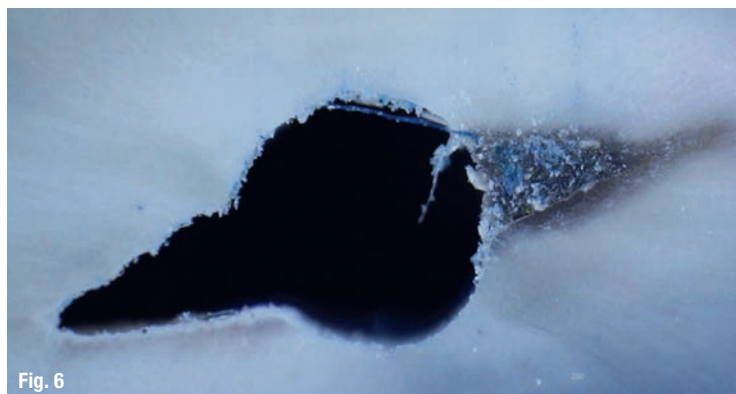


Fig. 6: An irregular canal space is shown after instrumentation with a file (round core). Note the existing debris accumulation in the canal irregularities resultant from instrumentation. (Courtesy of Dr Gustavo De-Deus)

debris is pushed into the non-round parts of the canal, blocking these areas from further cleaning and disinfection by irrigation solutions and adjunctive technologies.^{7, 8}

Additionally, when irregularities are compacted with detritus, increased pressure is exerted within the canal space with the attendant possibility of microfractures (Fig. 6). This is of critical concern with the new generation of nickel-titanium (NiTi) files, but not a factor with use of the XP-3D Shaper (Brasseler USA).⁹ The trend towards fewer files and larger tapers exacerbates this potential fracture problem.

Cognitive dissonance

The introduction of NiTi files fostered a transition to instruments that would potentially obviate the flaws inherent in the use of carbon and stainless-steel files. NiTi files are super-elastic and self-centring, and avoid ellipticisation of the apical terminus. With appropriate taper selection,

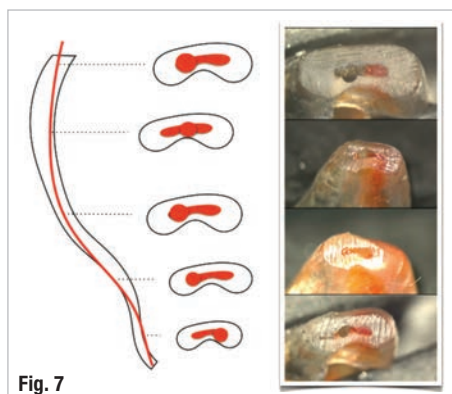


Fig. 7

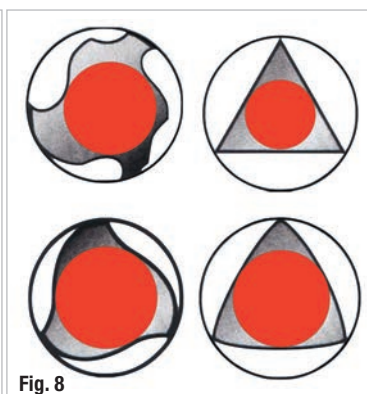


Fig. 8

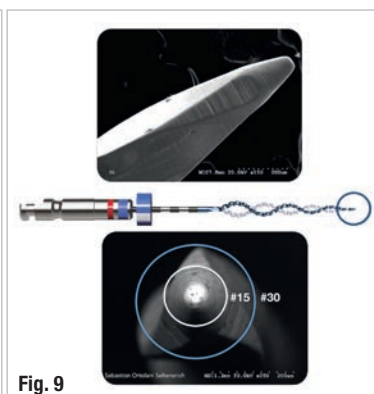

Fig. 9

Fig. 7: The majority of the root canal space is ovoid. As demonstrated by the canal shape at successive levels from the apex, round files, in spite of self-centring, can weaken the root structure with a typical 0.06-tapered instrument and will NOT debride the canal in its entirety. (Courtesy of Dr Gustavo De-Deus)

Fig. 8: There are approximately 157 file systems available globally. Most are made from round blanks; canals, however, are not “made” in the round.

Fig. 9: The Booster Tip has no cutting flutes on the first 0.25 mm. The next 0.25 mm section has six cutting flutes, which alters the apical extent of the canal to a size 30.02 (size/taper) instrument. The tip design of traditional NiTi instruments enables the instrument to follow the glide path rather than actively cutting and risk ledging or torsional failure if the tip inadvertently catches in an irregularity in the canal wall. (Courtesy of Dr Sebastián Ortolani Seltenerich)

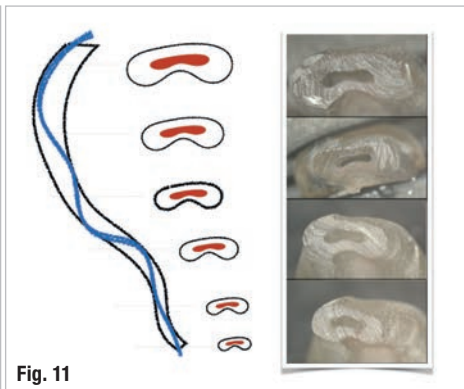
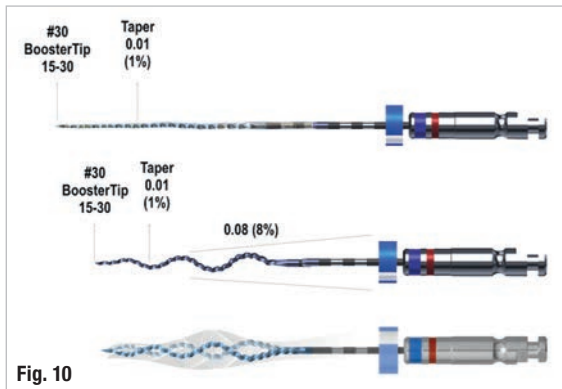


Fig. 10: The file dimensions of the XP-3D Shaper are shown in its martensitic phase and in its austenitic phase. **Fig. 11:** The tooth shapes the canal, not the file, as evidenced in the cross-sectional images at 1, 3, 5 and 7 mm from the apex. (Courtesy of Dr Gustavo De-Deus)

NiTi instruments should prevent thinning of the coronal and middle thirds of the root minimising thus preventing wall weakening or strip perforation. However, each generation of NiTi files, whether ground, twisted or heat-treated, shaped and cleaned far less debris than expected from the root canal space. Unfortunately, while a few systems included 0.04 tapers, the vast majority of single- or multi-tapered files have 0.06, 0.07 and 0.08 tapers. Some of the latest systems use asymmetrical rotary motion, conforming S-shaping and reciprocal motion. Unfortunately, separation of an NiTi instrument due to taper lock, cyclic fatigue and torsional resistance remains an omnipresent concern. The advantages of super-elasticity and self-centring were incalculable; however, the improvements were compromised by the persistence of round-core manufacturing (Figs. 7 & 8). The flaw in every iteration of NiTi files remains the same: the cutting geometry produces a round shape.

Inevitability of bio-minimal adaptive shaping

A new generation of adaptive/virtual core files, the XP-3D system, has dramatically changed the landscape of endodontic instrumentation. The XP-3D Shaper was designed to adapt to the anatomical shape of the canal while respecting the native framework of the root canal space without

packing debris into untouched areas. The XP-3D Finisher (Brasseler USA) has a reach of at least 3mm, thereby touching even the widest canal diameters while not changing the original shape of the canal.¹⁰

Booster Tip

The Booster Tip (BT) lead section fits into the pre-established glide path, ensuring precise guidance and centring of the instrument. A traditional glide path instrument produces a 15.02 or 10.04 size/taper.

There are no cutting flutes on the lead section of the BT, ensuring precise guidance and centring of the instrument. The XP-3D Shaper has a BT, which enables the instrument to follow the glide path into the apical component to a depth of 0.25 mm. The next 0.25 mm section of the BT is configured with six cutting flutes. Rotation of these flutes sizes the next 0.25 mm of the canal space from a 15.02 to a 30.02 (size/taper) instrument; thus, the apical size chosen for the XP-3D Shaper is size 30 (Fig. 9).

XP-3D Shaper

To better explain the unique properties of the file, the physical characteristics of the MaxWire technology must be understood. At room temperature, the XP-3D Shaper is in the martensitic phase, enabling it to be bent and more readily placed in the canal. No more than three to five easy up-and-down strokes (swaths) of the serpentine XP-3D Shaper with the BT should result in an apical terminus shaped to a size 30 file and a canal taper of 0.02 (Figs. 10 & 11). The choice of a 0.3mm diameter enables a 31-gauge irrigating needle to approximate the working length, preventing vapour lock. Maximum irrigation efficiency is ensured. Additionally, a shelf for seating the gutta-percha point prior to root filling is created. With an increasing number of strokes, the file has the capacity to expand from tapers

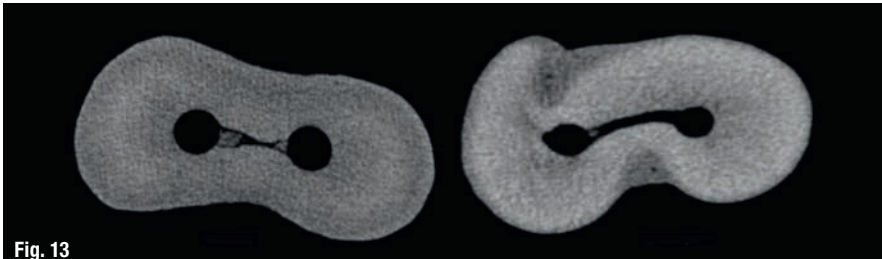
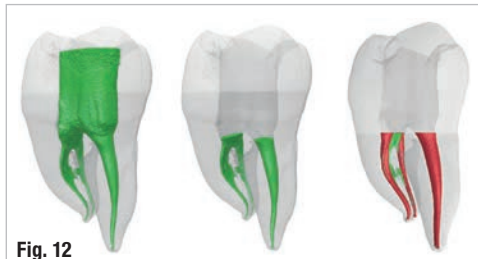


Fig. 12: In small (mesial) canals, the XP-3D Shaper file will first reach a 0.3mm diameter and in time increase the canal taper subject to the resistance of the dentine. The virtual/adaptive core prevents packing of debris in irregularities. **Fig. 13:** The μCT image to the left shows the packing of the debris into the isthmus by a reciprocating file. The image on the right shows the canal after preparation with the XP-3D Shaper. Increased resistance due to packing of debris is a common flaw in round NiTi files and can result in fracture.

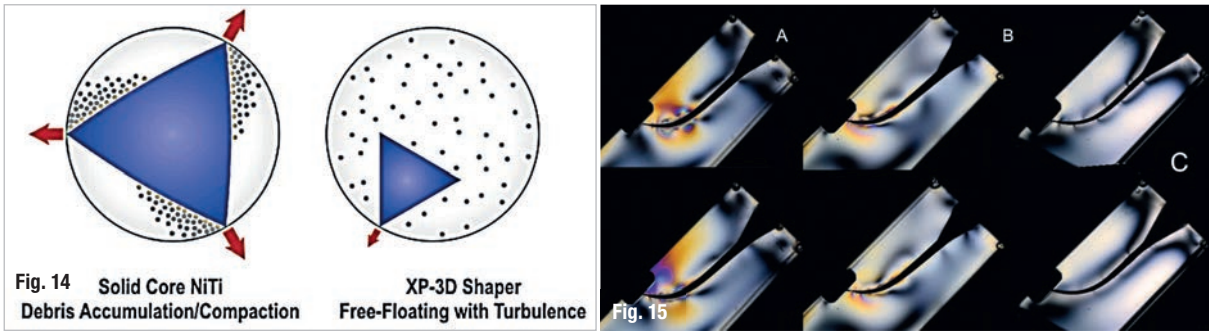


Fig. 14: The image shows the comparison of the mechanism of cutting by a file made from a round blank and by the XP-3D Shaper. No matter how much relief is provided by reducing the taper along a file with an apical third taper of 0.06/0.07/0.08, enhanced resistance is created and irrigation turbulence is not enhanced. The OPPOSITE is true of the Shaper. **Fig. 15:** Photoelastic stress analysis using a monochromatic light source and plastic models demonstrates that a reciprocating file (A) creates high stress in the apical third, a rotational file (B) shows strong stress in the apical third and the XP-3D Shaper file (C) shows no stress in the apical third.

of 0.01 to 0.02/0.04/0.06/0.08 while maintaining the flexibility of the original 0.01 taper. At body temperatures, the file attains its austenitic characteristics and attempts to achieve its potential of an 0.08 taper, a maximum that is needed in only the most unique cases.

As much healthy tissue as possible must be maintained; therefore, it is recommended that when the working length has been achieved in the first three to five strokes, an additional ten long strokes will achieve a 0.04 taper, which is sufficient to adequately disinfect the root canal space in very tight canals. In larger canals, the file will easily create larger tapers, as lesser dentinal resistance is met. As a function of its serpentine shape, light brushing and up to 30 long strokes will result in over 90% of the walls being touched in these larger non-complex canals (Figs. 12 & 13).

To summarise: the file is adaptive to the original shape of the canal; thus, the tooth shapes the canal space, in contrast to round NiTi files, where the file shapes the tooth. As shown in Figure 10, the file has a sinusoidal/serpentine shape. The space available for this shape in motion

enables a light brushing technique to adapt and debride 90% or more of the walls in larger non-complex canals, which contrasts dramatically with the debris removal with round NiTi files. As previously discussed, round files will pack debris into the canal irregularities, a major drawback in sufficiently cleaning a canal. The serpentine shape, virtual core and 0.01 taper of the XP-3D Shaper enable it to adapt to the canals and ensure that debris remains in turbulent solution, ensuring its optimal removal from the canal (Fig. 14). This enables the irrigants to work maximally as the canal is shaped. Tests using photoelastic models have shown that apical pressure is not built up using the XP-3D Shaper, obviating concerns regarding microcracks. Round-core files should significant generation of apical pressure (Fig. 15).

Recently, new and costly irrigation devices have been introduced in the endodontic armamentarium as adjuncts to the traditional side-vented needle and passive ultrasonic irrigation. The EndoActivator (Dentsply Sirona), the EndoSafe Plus (Vista Dental), the Endovac Pure (apical negative pressure irrigation; Kerr) and the GentleWave (Sonendo) are all relatively new.¹¹ The GentleWave sys-

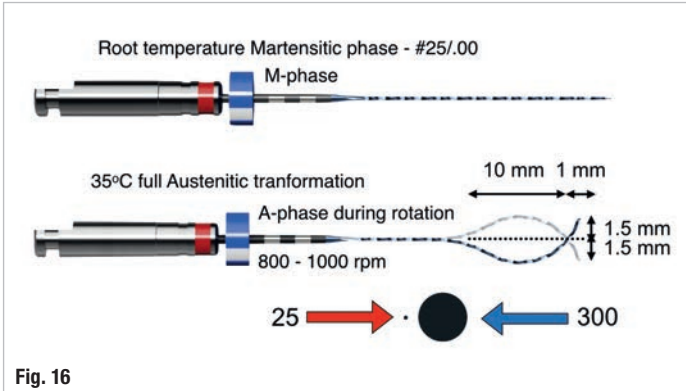


Fig. 16: The dimensions of the XP-3D Finisher are shown in the martensitic and austenitic phases. At body temperature, the last 10 mm of the instrument during rotation achieves a sickle shape with a diameter of 3 mm. Pressure on the bulb can further enhance the tip diameter.

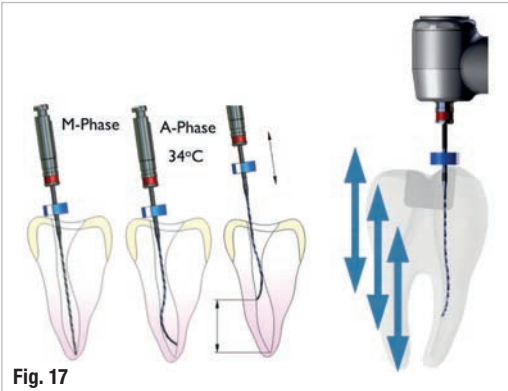


Fig. 17: The anatomy of the canal will cause the XP-3D Finisher to expand or contract and enter small irregularities in the canal walls with an up-and-down motion. No other file can reach these indentations.