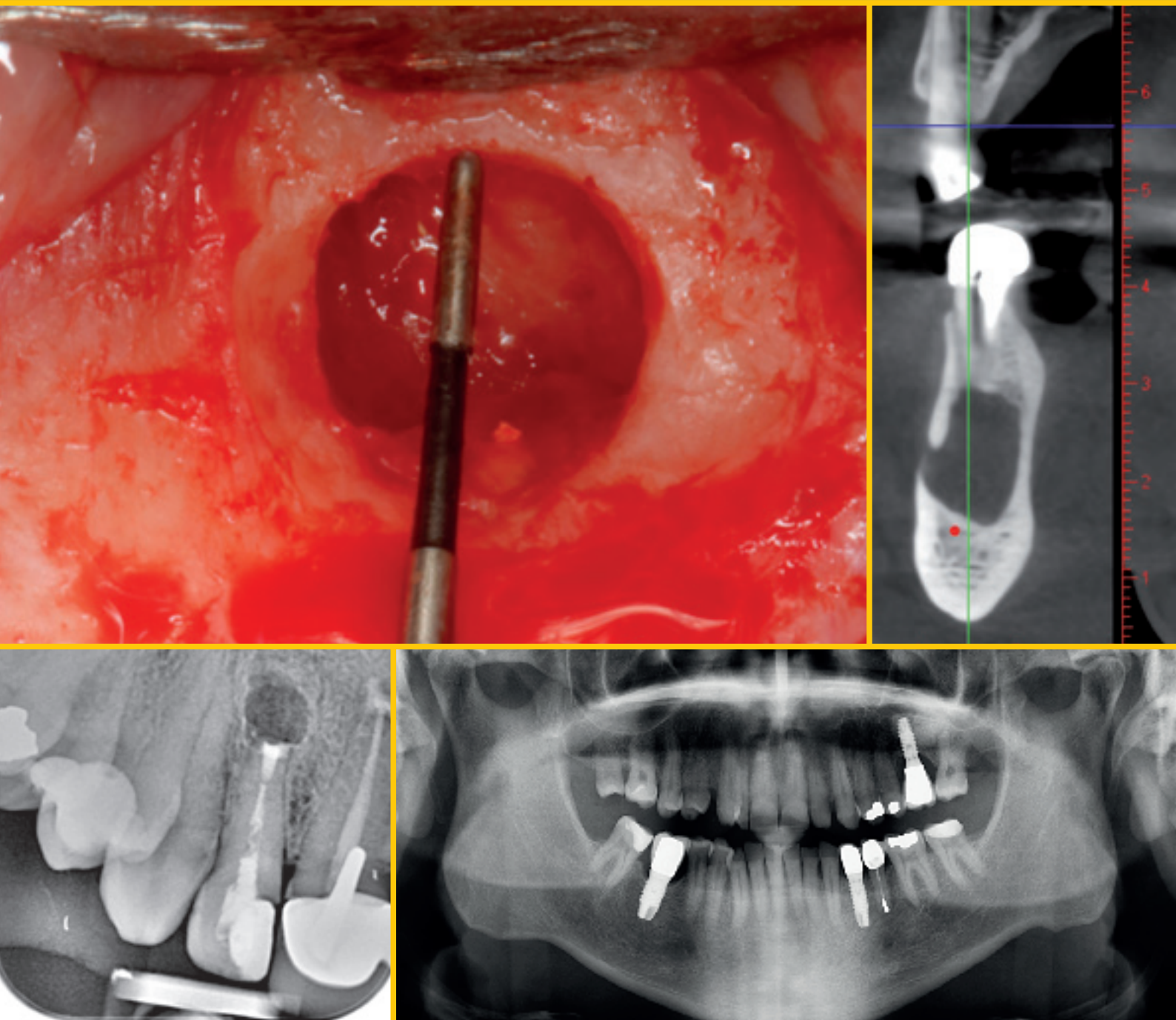


# Journal of Oral Science & Rehabilitation

Journal for periodontology, implant dentistry,  
dental prosthodontics and maxillofacial surgery



# IT'S SIMPLE TO BE A WINNER



## PROVEN SUCCESS MEETS ENHANCED STABILITY

The biological stability and predictable esthetics of the SEVEN, combined with the extensive research and development process have given the SEVEN a potential advantage in soft tissue preservation and growth as well as an array of restorative benefits. Learn more about the SEVEN implant system and MIS at: [www.mis-implants.com](http://www.mis-implants.com)

**mis**<sup>®</sup>  
**SEVEN**<sup>®</sup>



# Success in treatment with dental implants

Success in treatment with dental implants is determined not only by osseointegration, but also by the stability of the soft tissue around the restoration, giving it a natural appearance. The stability of this tissue is important for preventing periimplant bone resorption. The presence of a healthy periimplant mucosal interface has been associated with long-term implant success and protection against marginal bone loss. The soft tissue around implants plays a role in the protection and maintenance of the periimplant bone; in the crestal zone, it prevents bacterial invasion through different mechanisms in each of their components, provides resistance to frictional forces and limits the entry of foreign bodies.

The biological seal around the oral implant consists of two main layers: the epithelial junction and the underlying adhesion of the connective tissue. The main function of the epithelial junction is to form a physical barrier. The connective tissue function is much more complex, serving for defense, support and nutrition. The connective tissue is organized around the pillar in circular fibers, achieving stabilization of the pink tissue and helping to reduce bone resorption.

The connective tissue is of crucial importance in stabilizing epithelial apical migration and in preventing bone resorption. The discrepancy between the diameter of the implant and the abutment can establish a point at which circular connective fibers can be retained. The connective tissue surrounding the dental implant is in direct contact with the surface of the titanium dioxide and contains a dense network of collagen fibers that originate in the periosteum of the alveolar bone crest and extend to the mucosal margin.

The quality of this mucosa is determined in part by the prosthetic accessory materials in contact with it and the topography of the implant. The development of new dental implants, prosthetic abutments and crowns offers novel surfaces and designs capable of improving soft-tissue insertion, with a view to avoiding microbial contamination of vital bone.

The biologically oriented preparation technique (BOPT) concept has been described as affording an adaptive profile of the soft tissue, invading the sulcus in a controlled manner. With this technique, the collagen fiber distribution appears to increase mucosal fixation around the teeth (and implants) and increase soft-tissue stability over the long term, with the aim of maintaining periimplant bone protection. The convergent conical portion of the implant–abutment assembly, together with the BOPT design crowns, offers positive outcomes, such as the prevention of bone remodeling and preservation of the alveolar ridge, adequate periimplant tissue stability, and improved periimplant function and esthetics, without the need for more invasive and costly bone or soft-tissue regeneration techniques. New histological studies and larger samples are recommended to evaluate histologically and histomorphometrically the disposition of connective tissue fibers around implants and, thereby, demonstrate that adequate tissue stability and coronal migration of periimplant soft tissue are necessary for a successful outcome in implant treatment.

Prof. Miguel Peñarrocha Diago  
Editor-in-Chief

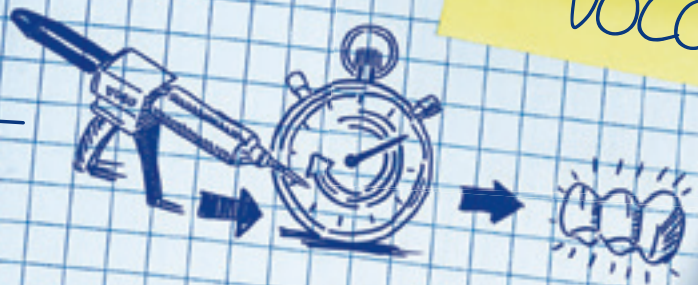# Contents

- 3     **Editorial**  
Prof. Miguel Peñarrocha Diago
  
- 6     **About the Journal of Oral Science & Rehabilitation**
  
- 8     **Juan Cervera Ballester et al.**  
New perspectives in periapical surgery:  
Ostectomy and osteotomy
  
- 18    **Lucía Caeiro Villasenín et al.**  
Prevalence of oral lesions among patients in the dental faculty  
of the University of Santiago de Compostela, Spain
  
- 26    **Francesco Saverio Ludovichetti et al.**  
Does the cleaning method after air abrasion  
with different particles affect the zirconia  
bond strength?
  
- 34    **Juan Cervera Ballester et al.**  
Periapical surgery with a new retrograde root  
canal filling material: Tricalcium silicate cement
  
- 42    **Industry news**  
VOCO
  
- 44    **Guidelines for authors**
  
- 46    **Imprint — About the publisher**

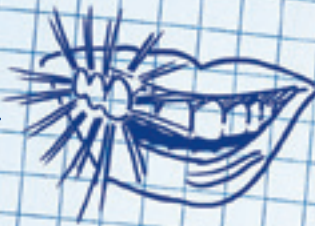

The proven  
crown and bridge  
material from  
VOCO

1. Processing!



2. Aesthetics!



Gloss without polishing!

3. Durability!



Order now!

## 3 FOR OPTIMAL TEMPORARIES

## Structur 3

### Safe and quick processing

- Intraoral time: just 45 seconds
- 1:1 mixing ratio ensures homogeneous blend

### Outstanding aesthetics

- Natural appearance
- Available in 8 shades

### Long-lasting

- High compressive strength
- Excellent fracture resistance



Please visit us in Cologne  
12.-16.03.2019  
Stand R8/S9 + P10, Hall 10.2  
Stand C40, Hall 5.2



VOCO on IDS  
Free info app  
zur IDS 2019



## About the Journal of Oral Science & Rehabilitation

The aim of the *Journal of Oral Science & Rehabilitation* is to promote rapid communication of scientific information between academia, industry and dental practitioners, thereby influencing the decision-making in clinical practice on an international level.

The Journal of Oral Science & Rehabilitation publishes original and high quality research and clinical papers in the fields of periodontology, implant dentistry, prosthodontics and maxillofacial surgery. Priority is given to papers focusing on clinical techniques and with a direct impact on clinical decision-making and outcomes in the above-mentioned fields. Furthermore,

book reviews, summaries and abstracts of scientific meetings are published in the journal.


Papers submitted to the *Journal of Oral Science & Rehabilitation* are subject to rigorous double-blind peer review. Papers are initially screened for relevance to the scope of the journal, as well as for scientific content and quality. Once accepted, the manuscript is sent to the relevant associate editors and reviewers of the journal for peer review. It is then returned to the author for revision and thereafter submitted for copy editing. The decision of the Editor-in-Chief is made after the review process and is considered final.

## About Dental Tribune Science

Dental Tribune Science (DT Science) is an online open-access publishing platform ([www.dtscience.com](http://www.dtscience.com)) on which the *Journal of Oral Science & Rehabilitation* is hosted and published.

DT Science is a project of the Dental Tribune International Publishing Group (DTI). DTI is composed of the leading dental trade publishers around the world.

For more, visit → [www.dental-tribune.com](http://www.dental-tribune.com)



## Benefits of publishing in the journal for authors

There are numerous advantages of publishing in the *Journal of Oral Science & Rehabilitation*:

- Accepted papers are published in print and as e-papers on **www.dtscience.com**; abstracts are published on **www.dental-tribune.com**.
- Authors' work is granted exposure to a wide readership, ensuring increased impact of their research through open-access publishing on **www.dtscience.com**.
- Authors have the opportunity to present and promote their research by way of interviews and articles published on both **www.dtscience.com** and **www.dental-tribune.com**.
- Authors can also post videos relating to their research, present a webinar and blog on **www.dtscience.com**.

## Subscription price

€50.00 per issue, including VAT and shipping costs.

## Information for subscribers

The journal is published quarterly. Each issue is published as both a print version and an e-paper on **www.dtscience.com**.

## Terms of delivery

The subscription price includes delivery of print journals to the recipient's address. The terms of delivery are delivered at place (DAP); the recipient is responsible for any import duty or taxes.

Copyright © Dental Tribune International GmbH. Published by Dental Tribune International GmbH. All rights reserved. No part of this publication may be reproduced, stored or transmitted in any form or by any means without prior permission in writing from the copyright holder.

# New perspectives in periapical surgery: Ostectomy and osteotomy

Juan Cervera Ballester,<sup>a</sup> Isabel Menéndez Nieto,<sup>a</sup>  
David Soto Peñaloza,<sup>a</sup> María Peñarrocha Diago<sup>a</sup>  
& David Peñarrocha Oltra<sup>a</sup>

<sup>a</sup> Department of Stomatology, Faculty of Medicine and Dentistry, University of Valencia, Valencia, Spain

Corresponding author:

**Dr. David Peñarrocha Oltra**

Unidad de Cirugía Bucal. Clínicas Odontológicas  
Facultad de Medicina i Odontología  
Universitat de València  
Gascó Oliag, 1  
46021 Valencia  
Spain

*david.penarrocha@uv.es*

How to cite this article: Cervera Ballester J, Menéndez Nieto I, Soto Peñaloza D, Peñarrocha Diago M, Peñarrocha Oltra D. New perspectives in periapical surgery: ostectomy and osteotomy. J Oral Science Rehabilitation. 2019 Mar;5(1): 8-17.

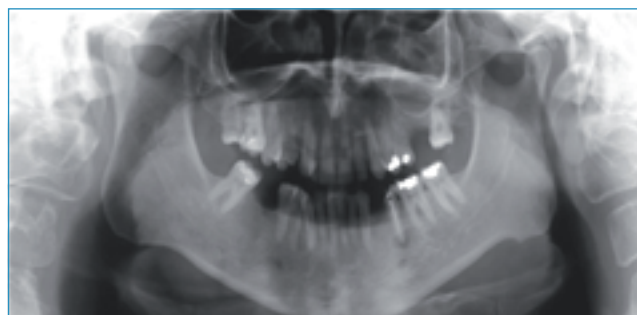

Fig. 1a

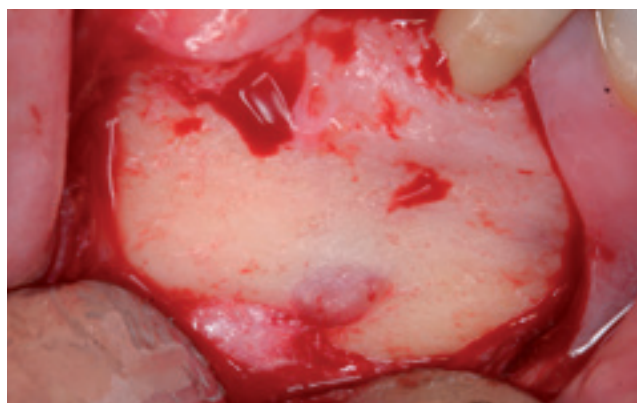


Fig. 1b

## Abstract

### Objective

The aim of this investigation was to review the surgical factors related to ostectomy in periapical surgery and their relationship to prognosis.

### Method

An update was made of different techniques to achieve adequate access to the periapical lesion. Visual control of the affected roots is important for a successful result in periapical surgery; for this reason, the bone tissue from the vestibular cortical bone must be removed through an ostectomy or osteotomy.

### Results

The technique used and the amount of bone removed must be analyzed preoperatively, since it will have a direct relationship to the surrounding anatomical structures, the healing time and the need to perform bone regeneration techniques.

### Conclusion

With the use of microsurgical techniques, the size of the ostectomy should not exceed 5 mm in order to reduce the healing time and thus improve the prognosis of periapical surgery. Osteotomy is an alternative technique that allows preservation of the external cortical bone, but has been little studied.



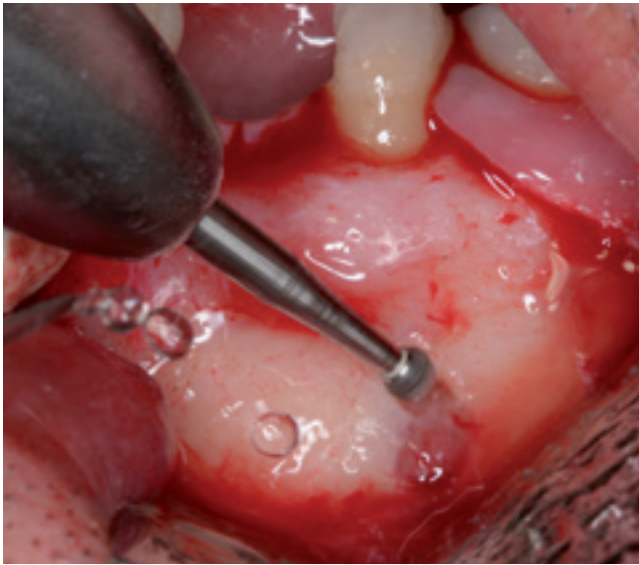

Fig. 1c

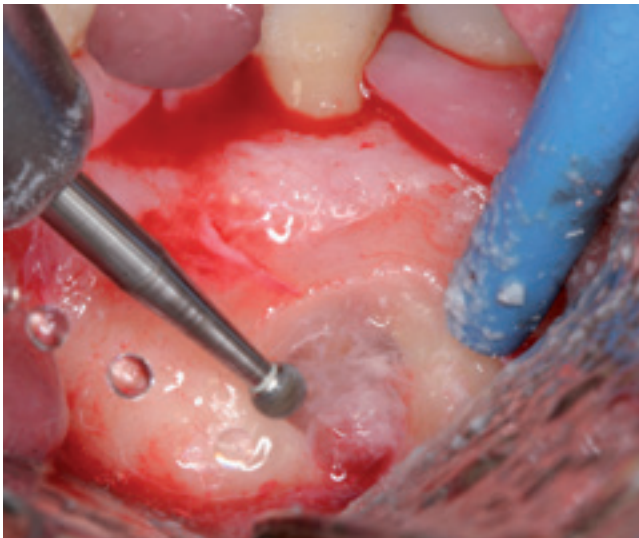

Fig. 1d

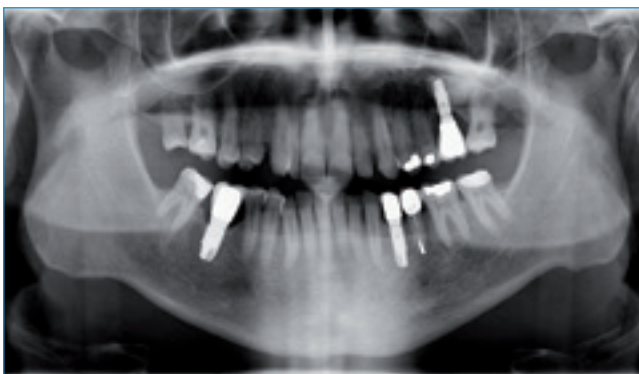

Fig. 1e

### Keywords

Ostectomy; osteotomy; periapical surgery; endodontic surgery; prognosis.

## Introduction

Periapical surgery entails 3 procedures: root end resection, root end cavity preparation and bacteria-tight sealing of the root canal system at the cut root end with a retrograde filling. For this, it is necessary to remove the periapical inflammatory pathological tissue to reach the dental apex.<sup>1</sup> Many years ago, in 1845, Hullinhen proposed surgical trephination through the soft tissue and bone and into the pulp to alleviate a pathological pulp process.<sup>2</sup> At present, to access the periapical lesion and obtain visual control of the affected roots, the soft tissue has to be raised and bone tissue from the vestibular cortical bone must be removed through an ostectomy or osteotomy.<sup>3</sup> In some cases, the pathological periapical lesion has already perforated the cortical bone, providing direct access to the apex and allowing the removal of the pathological tissue with only a remodeling of the peripheral bone.

Before surgery, it is important to calculate on a parallel radiograph the length and number of roots, the curvature of these, and the position of the apices and the important anatomical structures, such as the foramen, inferior dental nerve and maxillary sinus.<sup>4</sup> At present, the incorporation of cone beam computed tomography (CBCT) as a complementary radiographic technique has greatly simplified the diagnosis and detection of all these characteristics. Ahn et al. proposed introducing a CAD/CAM-guided surgical template in periapical surgery to minimize the extent of ostectomy for locating the root apex in cases with a thick and intact buccal bone plate and to facilitate surgery on teeth close to problematic anatomical structures.<sup>5</sup>

The aim of this investigation was to review the surgical factors related to ostectomy in periapical surgery and their relationship to prognosis.

## Surgical technique

Ostectomy entails the removal of bone tissue from the cortical bone to reach the dental apex. How large an ostectomy should be is predicated on the native size of the lesion, adequate armamentarium access, and proximity to vital structures, such as the mental nerve, mandibular canal and maxillary sinus.<sup>6</sup> In conclusion,