

DENTAL TRIBUNE

The World's Dental Newspaper • Pakistan Edition



PUBLISHED IN PAKISTAN

www.dental-tribune.com.pk

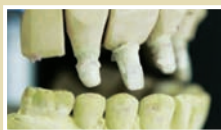NOVEMBER, 2016 - Issue No. 06 Vol.3

Barriers to cleft lip and palate surgery ...



NEWS

► Page 4



Abutment fracture in a bridge ...

CLINICAL PRACTICE

► Page 6



Seven dental marketing mistakes...and how to avoid them

CLINICAL PRACTICE

► Page 13

PDA Int'l Dental Congress opens amid enthusiastic response

DT International

LAHORE - Pakistan Dental Association's (PDA) 13th International and 33rd National Dental Congress on "Innovations in Dentistry ... A way forward" began here on Friday at the Expo Centre amid enthusiastic response from dental surgeons from across the country and abroad.

Inaugurating the conference, Prof Khalid Masood Gondal DGIR, regional director and senior vice president of the College of Physicians and Surgeons of Pakistan (CPSP), lauded the scientific programmes of the Congress and the products displayed at the Exhibition.

Urging the participants of the congress to seek more specialization in their respective fields, he informed the audience that there are 200 fellows in dentistry with 1000 trainees under 135 faculty members. The CPSP has earned global recognition and its work is appreciated throughout the world for performing exceptionally well with limited resources, he said, adding that the college was supporting Ireland and Saudi Arabia in the field of dentistry and more memorandum of understandings (MoUs) are underway in this regard.

The proceedings of the conference began with the



Congress chairman & president PDA
Prof Saqib Rashid with conference secretary
Dr Arham Chohan, Prof Kefi Iqbal Dean JSMU
& Dr Salman Zafar

recitation from the Holy Quran by Dr Hafiz Shakir. President of Pakistan Dental Association (PDA), Prof Saqib Rashid, who is also the conference chairman, expressed his gratitude to the organizing committee for making elaborate and wonderful arrangements for conference.

He also thanked the sponsors, including GSK,
Continued on Page 15

KMDC's novel idea to comply with PMDC rules

By Azizullah Sharif

KARACHI - Karachi Medical and Dental Colleges (KMDC) which comes under the umbrella of Karachi Metropolitan Corporation (KMC) has evolved a novel idea to comply with the Pakistan Medical and Dental Council's (PMDC) recent rule whereby it is mandatory for medical and dental institutions to get them affiliated with medical universities, instead of general universities.

The idea behind the KMDC's move is to become a constituent college of Karachi University.

This was disclosed by the KMDC's Principal and Chairperson of Academic Council, Prof. Dr Nargis Anjum, while talking to the Dental News.

Elaborating on the issue, she said that all formalities vis-à-vis making the college a constituent body of the Karachi University

Continued on Page 15

PDA CC & Sindh takes up SRB issue

DT Pakistan Report

KARACHI - Pakistan Dental Association in its endeavor to resolve the issues confront the dental community has taken up the issue of imposition of Sales Tax with the Sindh Revenue Board.

In this regard a meeting was held with senior dental surgeons from Karachi to discuss unjustified imposition of 13% Sales Tax on Dentists. Dr Saqib Raheed and Dr Mahmood Shah who are spearheading the campaign with active support of Dental News is exploring all legal options to do away with this notification.

It has been decided that a multi-pronged strategy comprising of meetings with Sindh Chief Minister, Commissioner Revenue, as well as, Legal Options will be utilized against this Unjustified 13% Sales Tax on Dentists. Dr Saqib has already met the commissioner and the lawyer in this regard and now seeks active support from the community to take it forward. It is pertinent to mention that this initiative is being taken to ensure that patients do not have to pay

Continued on Page 15

Private medical institutes voice concern over new policy

DT Pakistan Report

LAHORE - The Punjab government has introduced new induction policy in all the medical and dental colleges of the province "all of a sudden" and "without consulting the major stakeholders".

A spokesperson for the private medical and dental colleges said here that at least one year should have been given to the private institutions for planning.

Calling medical education a serious issue, the spokesperson said private institutions mostly get students who have passed 12th grade examination equivalent to intermediate science (F.Sc.) or HSSC examination level of

Pakistan from a foreign university, examining body or education system with three subjects out of which biology and chemistry are essential subjects, with 60 per cent in aggregate as certified by the Inter Boards Committee of Chairmen (IBCC).

"Students having passed 12th grade examination from a foreign university or examining body can never get equation with F.Sc. students who get unbelievable marks, especially from certain areas and BISEs. It is an open secret that how these FSc students get such an extremely high score.

"Private medical and dental institutions get no help from the

government and totally depend upon fee collection. And when a student is paying, he or she should have the right to choose institution of choice. It is also very important to judge students to see if they are able to pay fees on a regular basis. Over the years, we have learnt which students are not to be admitted. Such students pay fee for one year and then get stuck with next years, causing problems not only for themselves but for the institution concerned also," said the spokesperson, adding that a stay order against the arbitrary and unilateral decision of the Punjab government has been obtained from a court on last Saturday.

‘The Future of Oral Health’ explores impact of oral disease on whole body

DT International

NEW YORK, N.Y., USA: The impact of oral disease on whole-body health and the changes to the practice of dentistry worldwide are the subjects of “The Future of Oral Health,” a new publication produced by Scientific American Custom Media, in collaboration with Colgate-Palmolive Company. The issue launched Oct. 21 at the American Dental Association’s Annual Meeting in Denver during a panel discussion moderated by Jeremy Abbate, vice president and publisher of Scientific American and the publishing director of “The Future of Oral Health.”

Panelists for the discussion, which was titled “The Evolving Landscape of Global Oral Health, Its Prevention and Treatment,” included Michael C. Alfano, DMD, PhD; Caswell A. Evans, DDS, MPH; Sharon Guynup; Thomas E. Van Dyke, DDS, PhD, Dipl. ABP (Periodontology) and Marko Vujicic, PhD.

The publication explores science, policy and new delivery models to better understand the current and future state of the multifaceted oral health field. Within the issue are updates on:

- The oral health of a growing elderly population; global health issue of caries and periodontal diseases and the latest industry developments helping to improve access and cost-of-care in these areas.
- The state of the science linking oral health and other

areas of medicine and changes in the relationships between the dental and medical communities as they slowly desilo and integrate to deliver better care and greater access for patients.

- New tools being employed in diagnostics, biotechnology, and digital health that are advancing care, along with a special look at how dentistry and oral health will be managed in the future.
- Philosophies and technologies that have fueled industry changes and ways in which global demographics are mandating more accommodating, on-demand approaches to dentistry that reduce cost and bring care to hard-to-reach populations.

“We are thrilled to be working with Colgate to bring these important issues to an international audience,” Abbate said, in a press release. “Examining oral health through the lens of global health, access to care, and future technology is a relevant conversation, not just for dentistry, but for the larger allied health space.”

Pat Verduin, Colgate’s chief technology officer, said: “Solutions in oral health must address evolving patient needs, changing global demographics, and the ever-advancing innovation landscape that will affect delivery methods and models of care. We are very proud to be a part of this multifaceted conversation.”

— DT, USA

Studies show e-cigarettes harmful to oral health

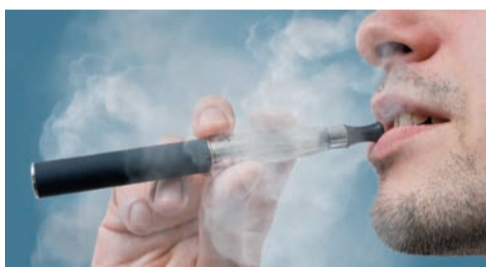DT International

ROCHESTER, N.Y., USA / QUEBEC CITY, Canada: Electronic cigarettes continue to grow in popularity among young adults and current and former smokers because they are often perceived as a healthier alternative to conventional cigarettes. However, two recent studies by scientists in the U.S. and Canada have found that regular exposure to e-cigarette vapors causes damage to the gingival tissue, which may lead to infection, inflammation and periodontal disease.

Both studies investigated the effect of e-cigarettes on oral health on cellular and molecular levels through in vitro experiments. The team of Prof. Mahmoud Rouabhia from the Faculty of Dentistry at Université Laval in Quebec City exposed gingival epithelial cells to e-cigarette vapor, finding that a large number of these cells died within a few days. “Mouth epithelium is the body’s first line of defense against microbial infection,” Rouabhia explained. “This epithelium protects us against several microorganisms living in our mouths.”

To simulate what happens in a person’s mouth while inhaling, the Canadian researchers placed human epithelial cells into a small chamber containing a saliva-like liquid. E-cigarette vapor was pumped into the

chamber at a rate of two 5-second “inhalations” per minute for 15 minutes a day. Observations under the microscope showed that the percentage of dead or dying cells, which is about 2 percent in unexposed cell cultures, rose to 18, 40 and 53



Two research teams from the U.S. and Canada have found that e-cigarette vapors are harmful to the gingival tissue and may increase the risk of periodontal disease.

percent after one, two and three days of exposure to e-cigarette vapor, respectively.

“Contrary to what one might think, e-cigarette vapor isn’t just water,” Rouabhia stated. “Although it doesn’t contain tar compounds like regular cigarette smoke, it exposes mouth tissues and the respiratory tract to compounds produced by heating the vegetable glycerin, propylene glycol, and nicotine aromas in e-cigarette liquid.”

The cumulative effects of this cell damage have not yet been documented, but they are worrying, according to Rouabhia. “Damage to

the defensive barrier in the mouth can increase the risk of infection, inflammation, and gum disease. Over the longer term, it may also increase the risk of cancer. This is what we will be investigating in the future,” he concluded.

Researchers at the University of Rochester Medical Center in the U.S. came to similar conclusions. Dr. Irfan Rahman, Professor of Environmental Medicine at the university’s School of Medicine and Dentistry, and his colleagues exposed cell cultures of human gingival epithelial cells and periodontal ligament fibroblasts to e-cigarette vapors. “We showed that when the vapors from an e-cigarette are burned, it causes cells to release inflammatory proteins, which in turn aggravate stress within cells, resulting in damage that could lead to various oral diseases,” he explained.

Most e-cigarettes feature a battery, a heating device and a cartridge to hold liquid, which typically contains nicotine, flavorings and other chemicals. The U.S. researchers found that the flavoring chemicals negatively affect gingival cells too. “We learned that the flavorings—some more than others—made the damage to the cells even worse,” said study author Fawad Javed, a postdoctoral resident at Eastman Institute for Oral Health, part

Continued on Page 15

DENTAL TRIBUNE

The World's Dental Newspaper - Pakistan Edition

Publisher/CEO

Syed Hashim A. Hasan
hashim@dental-tribune.com.pk

Editor Clinical Research:

Dr. Inayatullah Padhiar

Editors Research & Public Health

Prof. Dr. Ayyaz Ali Khan

Editor - Online

Haseeb Uddin

Designing & Layouting

Sh. M. Sadiq Ali

Dental Tribune Pakistan

3rd floor, Mahmood Centre, BC-11, Block-9
Clifton, Karachi, Pakistan.
Tel.: +92 21 35378440-2 | Fax: +92 21 35836940
www.dental-tribune.com.pk
info@dental-tribune.com.pk

Dental Tribune Pakistan cannot assume responsibility for the validity of product claims or for typographical errors. The publisher also does not assume responsibility for product names or statements made by advertisers. Opinions expressed by authors are their own and may not reflect of Dental Tribune Pakistan.

International Imprint

Group Editor

Daniel Zimmermann

newsroom@dental-tribune.com

Tel.: +44 161 112 1830

Clinical Editor

Magda Wojtkiewicz

Online Editors/Social Media Manager

Claudia Duschek

Editor

Anne Faulmann

Editorial Assistant

Kristin Hübner

Copy Editors

Sabrina Raaff

Hans Motschmann

Publisher/President/CEO

Torsten Oemus

Chief Financial Officer

Dan Wunderlich

Chief Technology Officer

Serban Veres

Business Development Manager

Claudia Salwiczek-Majonek

Jr. Manager Business Development

Sarah Schubert

Project Manager Online

Tom Carvalho

Event Manager

Lars Hoffmann

Education Manager

Christiane Ferret

International PR & Project Manager

Marc Chalupsky

Marketing & Sales Services

Nicole Andrä

Event Services

Esther Wodarski

Accounting Services

Karen Hamatschek

Anja Maywald

Manuela Hunger

Media Sales Managers

Matthias Diessner (Key Accounts)

Melissa Brown (International)

Antje Kahnt (International)

Peter Witteczek (Asia Pacific)

Weridiana Mageswki (Latin America)

Maria Kaiser (North America)

Hélène Carpentier (Europe)

Barbora Solarova (Eastern Europe)

Executive Producer

Gernot Meyer

Advertising Disposition

Marius Mezger

Dental Tribune International

Holbeinstr. 29, 04229 Leipzig, Germany

Tel.: +49 341 48 474 302 | Fax: +49 341 48 474 173

info@dental-tribune.com | www.dental-tribune.com

Regional Offices

Asia Pacific

Dental Tribune Asia Pacific Limited

Room A, 20/F, Harvard Commercial Building,

105-111 Thomson Road, Wanchai, Hong Kong

Tel.: +852 3113 6177 | Fax: +852 3113 6199

The Americas

Tribune America, LLC

116 West 23rd Street, Ste. 500, New York, N.Y.

10011, USA

Tel.: +1 212 244 7181 | Fax: +1 212 244 7185

new



Dentine hypersensitivity protection, now in a daily mouthwash

The first Sensodyne® mouthwash containing 3% potassium nitrate and fluoride, clinically proven to provide ongoing protection from the pain of dentine hypersensitivity with twice-daily rinsing.^{1-4*} Recommend Sensodyne mouthwash to your patients after dental procedures and as a daily use mouthwash



*Rinse twice daily after brushing with a fluoride toothpaste.

GSK is committed to the effective collection and management of human safety information relating to our products and we encourage healthcare professionals to report adverse events to us on +92(21)111-475-725 or pk_pharmasafety@gsk.com.

References: 1. Gillam DG et al. J Clin Periodontol 1996;23:993-997. 2. Morris A et al. Efficacy of a Potassium Nitrate Mouthrinse for Relieving Dentinal Hypersensitivity, IADR/AADR/CADR 87th General Session and Exhibition, April 1-4 2009. 3. Pereira R et al. J Periodontol 2001;72(12):1720-1725. 4. GSK Data on File (Study RH01751): A Clinical Study Investigating the Efficacy of a Mouthwash in Providing Long Term Relief from Dentinal Hypersensitivity. Prepared November 2015. CHPAK/CHSENO/0050/15.

Barriers to cleft lip and palate surgery persist in Vietnam


DT International

LOS ANGELES, USA - Charitable organisations perform more than 80 per cent of cleft lip and cleft palate surgeries in Vietnam, a new study by US researchers has found. According to the scientists, this reflects the complex and persistent barriers to surgical care in low- to middle-income countries (LMICs) and shows that charitable missions remain a critical source of access to surgical care for these states.

Cleft lip and palate are the most common craniofacial birth defects, occurring in between one in 500 to one in 2,500 infants worldwide. “The defect not only results in physical obstacles to feeding and language development, but patients are often subjected to significant social stigma,” the researchers stated.

They surveyed approximately 450 Vietnamese families seeking cleft lip and/or palate repair surgery for their affected child. Some of the children had already undergone surgery for their condition previously (54 per cent) and 46 per cent of them were seeking surgical care for the first time. The families were seen at four medical missions sponsored by the international charity Operation Smile. Parents were asked in-depth questions about their perceptions of the barriers to surgical and medical care for their child’s condition.

Facing structural, financial and cultural barriers to cleft lip and palate surgery, patients in LMICs rely on charitable care outside the centralised health care system, the study report pointed out. “As a result, surgical treatment of cleft lip and palate is delayed beyond the standard optimal window



For their child affected by cleft lip and/or palate, more than 80 per cent of Vietnamese families surveyed in a study sought surgical care in a charitable mission—although 73 per cent of them had health insurance

compared to more developed countries,” the researchers wrote. At the time of initial cleft surgery, the children’s average age was 3.25 years. By comparison, in developed countries, the recommended age for cleft lip and palate repair surgery is between 3 and 18 months of age.

Nearly three-quarters of the families had health insurance coverage. Nevertheless, 83 per cent had their surgery performed by a charitable organisation outside of the national health care system. While most parents had a local hospital that was more accessible than the charitable mission was, many said that they could not obtain cleft treatment there, mainly owing to cost. About 40 per cent stated that, without the charitable mission, they would not have had access to any surgical or medical treatment for their child’s condition.

The survey found a wide range of structural, financial and cultural barriers to cleft care. Structural barriers included lack of trained medical staff, equipment and medicine. Financial barriers were identified as not only the cost of the surgery, but

Continued on Page 15

For dentists, the era of advanced degrees

By Dennis J. Tartakow

Today, it is more common than ever before for dentists to go back to school for advanced degrees. Why? Until the 1990s, most doctors were content to have only one advanced degree and never step foot in a school again. So why are so many individuals going back to school for advanced degrees, and is advanced education really worth the effort?

Many doctors viewed the idea of continued learning more as a need, rather than a desire, to become more educated as clinicians, educators and/or leaders. This obviously has become a reality. Then with the coming of state-required mandatory C.E. credits for licensure, Internet courses began springing up, and schools and private institutions viewed this as a new way of increasing revenue.

In 2002, 22 dental schools offered dual-degree programs. Dental schools in the United States and Canada were not encouraging potential dental scientists to follow career paths that dental education desperately needed; some dental students view dentistry only as a technical discipline, while others who are interested in teaching and research careers might pursue research degrees (PhD).

Today in 2016, almost all postgraduate orthodontic programs range from two to four years in duration; some offer certificates in orthodontics, and others confer MS and/or PhD degrees. With the progressive emphasis on evidence-based dentistry and the ongoing shortage of dental faculty, dental schools became instrumental in training future dental faculty.

Continued on Page 15

Five-minute dental screening: Japanese company introduces new saliva test

DT International

TOKYO, Japan - A new saliva test from Japan analyses various oral parameters in a matter of minutes. According to Lion Corporation, which developed the Salivary Multi Test together with Aichi Gakuin University’s School of Dentistry, the device can identify markers associated with oral health, such as the quantity of cavity-causing bacteria and number of white blood cells, using just a small sample of saliva.

In addition to the Salivary Multi Test Meter—the actual measuring instrument—a computer, a printer, test paper and software (available for Windows and macOS) are needed for analysing the saliva samples. After applying the saliva to the test paper, the patient’s individual results are visualised in a radar chart on the computer monitor.

Items tested include salivary acidity, leukocyte count, ammonia values and the presence of fungi. According to Lion, six items can be measured simultaneously in one analysis and test results can be obtained within 5 minutes.

The Japanese company spent seven years developing the Salivary Multi Test in cooperation with Aichi Gakuin University and now aims to distribute the system to dental clinics in the country at a price of ¥198,000 (€1,710). In addition, Lion hopes that organisations and pharmacies that offer



Within 5 minutes, the saliva-testing device produces results regarding the quantity of cavity-causing bacteria and number of white blood cells, for example. Lion Corporation sells the Salivary Multi Test exclusively via a dedicated website.

health check-ups will introduce the system for early and easy detection of oral health problems as well.

More information about the system is available on the company’s website, lionpro.lionshop.jp (in Japanese only), through which the system is exclusively sold.

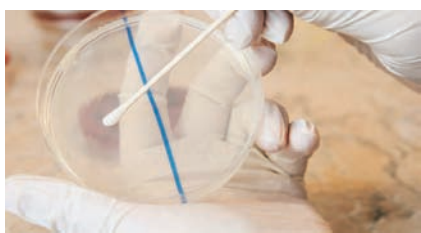Lion Corporation is a Japanese manufacturer of toiletries and personal care goods, including oral hygiene products. The company was founded in 1891 and has its own chemical engineering research division for developing new products.

— DT, Asia Pacific

New organic toothpaste may inhibit harmful bacteria

DT International

SEOUL, South Korea - A Seoul dentist has developed an all-natural toothpaste that aims to reduce the health risks posed by *Streptococcus gordonii*, an oral bacterium that initiates dental plaque



A new toothpaste has been developed to destroy *Streptococcus gordonii*.

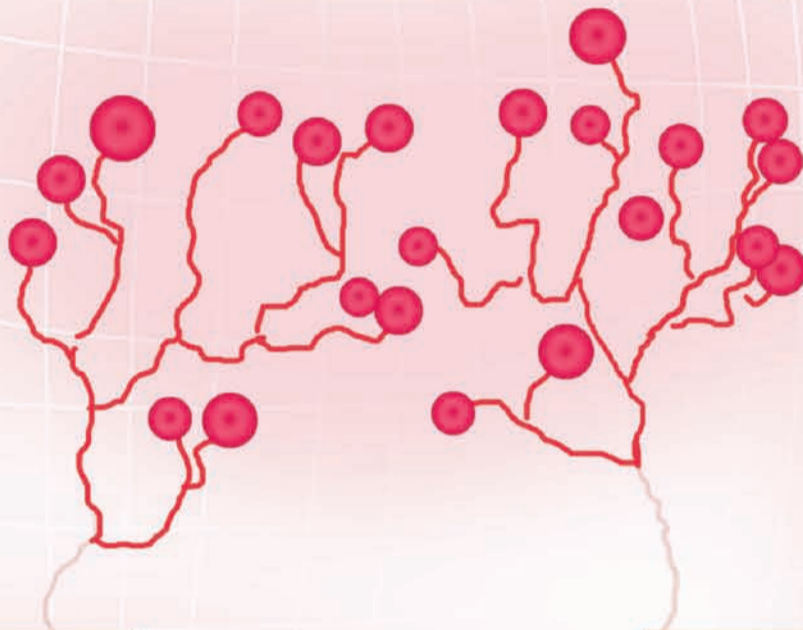
Mimicking the human protein fibrinogen, the oral bacterium can cause blood clots and lead to growths on the heart valves (endocarditis)—a disease with a 30 per cent mortality rate

formation. Once in the bloodstream, which it may enter through bleeding gingivae, for example, the bacterium also causes blood

Continued on Page 15

Colgate

Sensitive Pro-Relief™



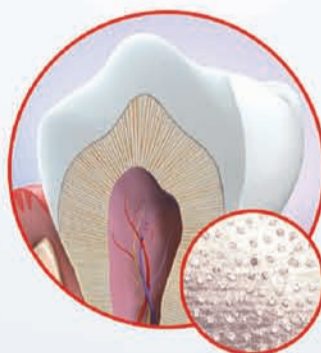
REPAIR
THE CAUSE

PREVENT
PAIN RETURNING

THERE'S A BETTER WAY TO TREAT
SENSITIVE TEETH. ^

REPAIR

Forms a calcium-rich layer and helps repair[†] sensitive areas of teeth for instant and superior relief ^{^, 1-3}



PREVENT

Regular use helps strengthen gums and provides lasting protection to prevent further tooth sensitivity

NEW



Colgate

PAKISTAN'S #1 SENSITIVITY TOOTHPASTE RECOMMENDED BY DENTISTS*

*Based on Professional Dentists Tracking Study - IPSOS Pakistan Nov 2015

^ vs. toothpastes with 5% potassium nitrate. For instant relief, apply directly to the sensitive tooth and gently massage for 1 minute.
Reference: 1. Li Y et al. J Clin Dent. 2011; 22(Spec Iss):113-120. 2. Nathoo S et al J Clin Dent 2009; 20 (Spec Iss):123-130. 3. Ayad F et al. J Clin Dent. 2009; 20 (Spec Iss): 10-16.

Abutment fracture in a bridge supported by natural teeth and implants

By Dr Gregory-George Zafiropoulos, Dr Giorgio Deli & Dr Rainer Valentin

Implant treatment has evolved into a reliable modality for the replacement of missing teeth. Although rare, complications may occur, and some uncertainty surrounds the treatment of some of these events, especially when restorations are supported by a combination of natural teeth and implants.[1] Often the fabrication of an entirely new restoration is necessary if one or several of the natural teeth need to be removed. Here, we report two cases in which a natural tooth abutment of

was restored with fixed crowns and implant retained bridges. The maxilla was restored with a removable teeth-implant supported, palatal free bridge (Figs. 1a–d) using double crowns as attachments, as previously described.[2–4] No implants were placed in regio #16 and #26, since the patient decided against performing sinus lift procedures and the remaining bone height was inadequate to allow implant placement. Furthermore, the patient did not agree to extraction of teeth

Germany), fixated in the superstructure with a self-curing copolymer cement (AGC Cem, Wieland, Pforzheim, Germany), as previously described were used as secondary telescopes.[5,6] The metal framework was milled from a titan 5 alloy (ZENOTEC Ti Disc; Wieland) and covered with microceramic composite (Ceramage, SHOFU, Ratingen, Germany). The patient was put on a three-months maintenance schedule. Six years after implant and prosthetic treatment, the patient reported to the

denture was removed from the patient's mouth together with the impression (Fig. 3a). This allowed for the fabrication of a cast with an exact duplication of the abutments (Fig. 3b). The casts were placed in an articulator using the denture as a guide to achieve correct occlusion (Fig. 4a). A temporary fixed partial denture (from #14 to #24 with #15 and #25 cantilevers) from coloured polymethyl methacrylate (PMMA; Zenotec; Wieland, Pforzheim, Germany) was milled based on a scan of the maxilla

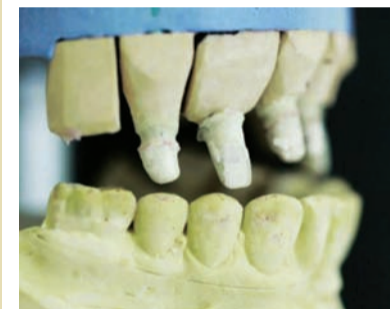

Fig 1a: Casts placed in the articulator; a) right side, restoration not in place; b) left side, restoration not in place; c) anterior view, restoration in place; d) left side with restoration in place

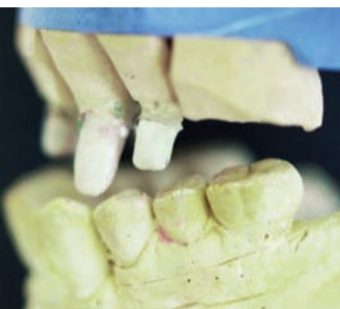

Fig 1b: Casts placed in the articulator; a) right side, restoration not in place; b) left side, restoration not in place; c) anterior view, restoration in place; d) left side with restoration in place

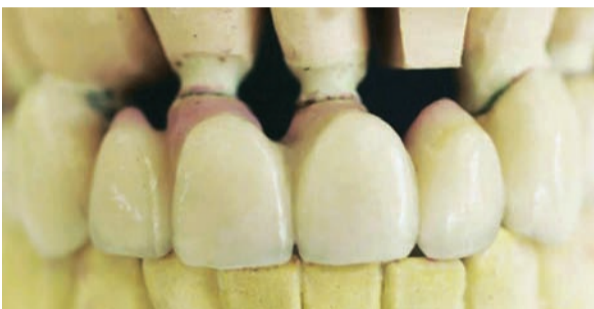

Fig 1c: Casts placed in the articulator; a) right side, restoration not in place; b) left side, restoration not in place; c) anterior view, restoration in place; d) left side with restoration in place

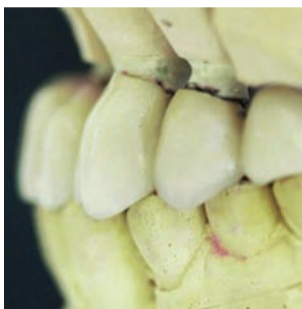

Fig 1d: Casts placed in the articulator; a) right side, restoration not in place; b) left side, restoration not in place; c) anterior view, restoration in place; d) left side with restoration in place

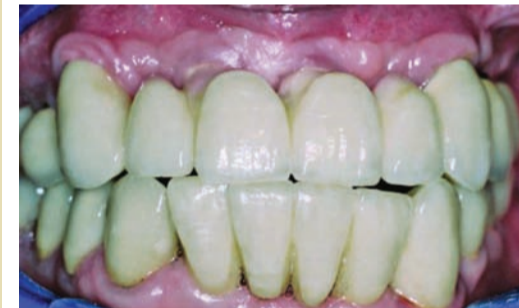

Fig 2a: Restauration after initial treatment, before the accident; a) anterior view; b) intraoral view; c) implants with abutments and teeth #13 and #23 with gold copings in place; d) panoramic radiograph

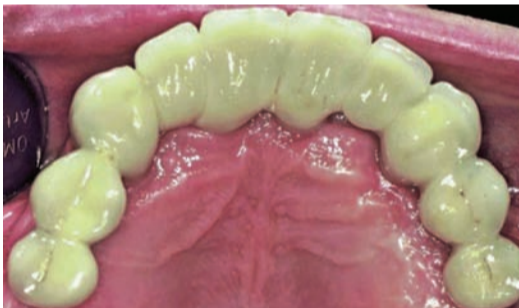

Fig 2b: Restauration after initial treatment, before the accident; a) anterior view; b) intraoral view; c) implants with abutments and teeth #13 and #23 with gold copings in place; d) panoramic radiograph

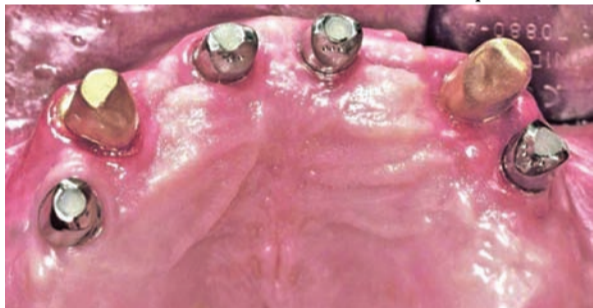

Fig 2c: Restauration after initial treatment, before the accident; a) anterior view; b) intraoral view; c) implants with abutments and teeth #13 and #23 with gold copings in place; d) panoramic radiograph

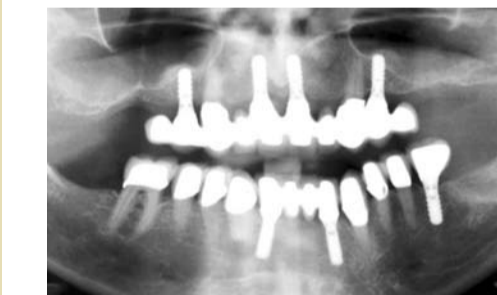

Fig 2d: Restauration after initial treatment, before the accident; a) anterior view; b) intraoral view; c) implants with abutments and teeth #13 and #23 with gold copings in place; d) panoramic radiograph



Fig 3a: Impression with the maxillary restoration



Fig 3b: Impression with the fabricated cast

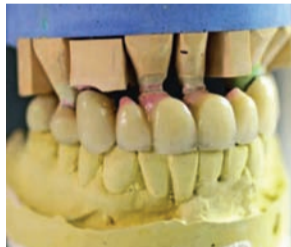

Fig 4a: Cast articulated using the maxilla restoration as a guide

a restoration supported by implants and natural teeth fractured. We describe the technique used to replace the fractured tooth with an implant, which allowed the re-use of the existing restoration.

Case 1

The patient was a 62-year-old male non-smoker in good general health, who was taking no medication and had received implant treatment at the author's office six years before developing the complications described in this article. The mandible

#13 and #23. Therefore, the final restoration had to be supported by four implants (#14, #11, #21, #24; 4.1×10 mm, RN, Straumann, Basel, Switzerland) and two natural teeth (#13, #23) with cantilevers in the areas #15–16 and #25–26 (Figs. 2a–d). Customised implant abutments (torqued to 35 Ncm) and gold copings placed on natural teeth #13 and #23 served as primary telescopes (Fig. 2c). Electroformed pure gold copings with a thickness of 0.25 mm (AGC Galvanogold, Wieland, Pforzheim,

office. Tooth #13 had been fractured in a car accident. He refused any new restoration and insisted on keeping the existing one. Thus, implant placement in position #13 was planned. The fractured tooth #13 was extracted. The maxillary denture was inserted and a bite registration in central occlusion was performed using self-curing acrylic resin (PATTERN RESIN; GC, Alsip, USA). An impression (Impregum; 3M ESPE, Neuss, Germany) of the maxilla was taken with the denture in place. The

cast, and was adhered on the abutments using provisional cement (TempBond, Kerr Co., Orange, USA; Fig. 4b). In addition, a surgical stent fitting onto the abutments was milled from clear PMMA (Zenotec; Wieland, Pforzheim, Germany; Fig. 5a). The planned axis of implant #13 was determined using a dental parallelometer (Fig. 5b), and a drill sleeve was placed into the surgical stent (Fig. 5c). An implant (4.5×10 mm, SB line; Dentegris, Duisburg, Germany) was inserted with a torque of 35 Ncm using a two-phase

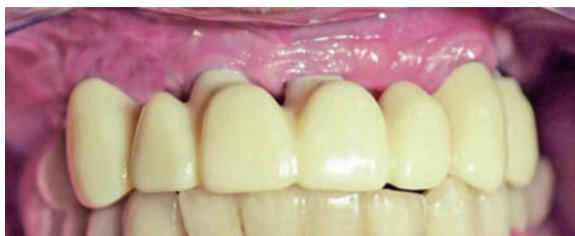

Fig 4b: Provisional FPD in place



Fig 5a: Surgical stent




Fig 5b: Determination of the axial direction




Fig 5c: Drill sleeve was placed into the surgical stent

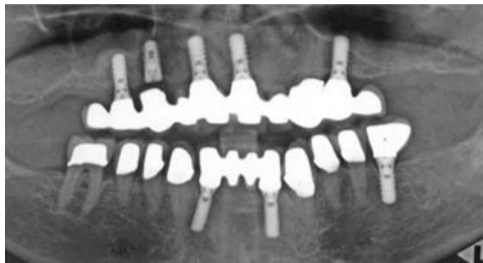

Fig 6: Panoramic radiograph obtained after implant insertion at position #6.

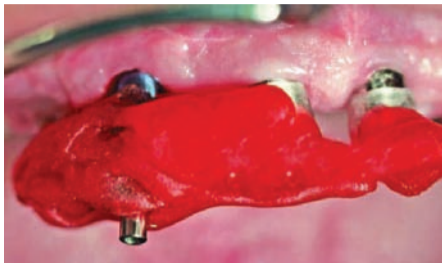


Fig 7: Impression post in the surgical guide




Fig 8a: Transfer of the implant position to mounted cas

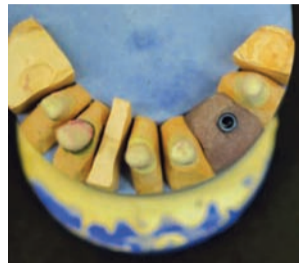

Fig 8b: The implant analog in cast

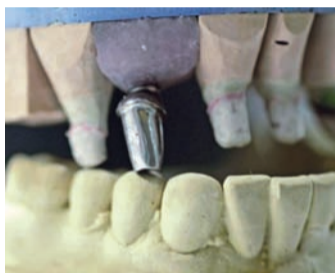

Fig 9a: Fabricated customised abutment; b) try-in of the abutment in the restoration

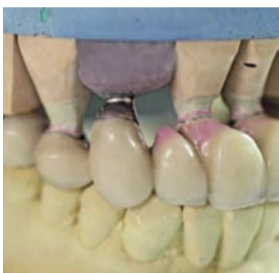

Fig 9b: Try-in of the abutment in the restoration

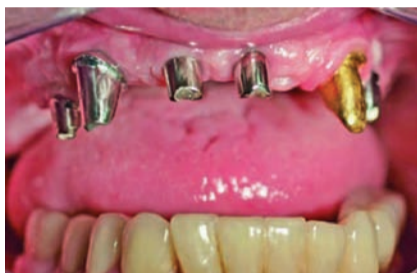

Fig 10a: a & b) : Abutment mounted on the implant; c) panoramic radiograph of custom-made abutment #13 in place

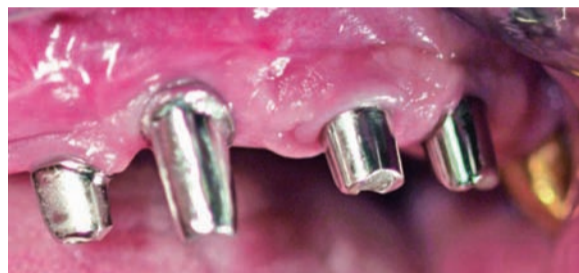

Fig 10b: a & b) : Abutment mounted on the implant; c) panoramic radiograph of custom-made abutment #13 in place

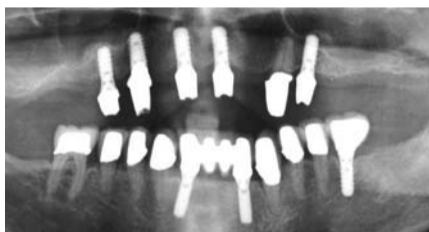


Fig 10c: a & b) : Abutment mounted on the implant; c) panoramic radiograph of custom-made abutment #13 in place

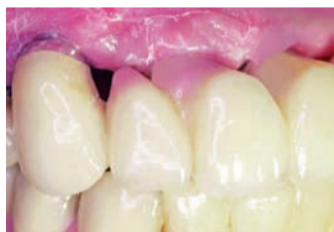

Fig 11a) : Denture in place; a) close-up; b) anterior view

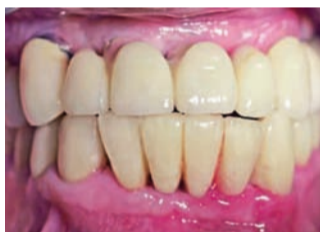

Fig 11b) : Denture in place; a) close-up; b) anterior view

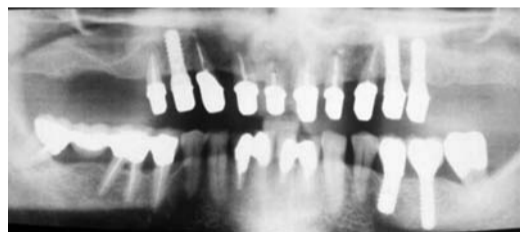


Fig 12: Orthopantomograph taken at the completion of the perioimplant- prosthodontic treatment



Fig 13a: Surgical guide for implant placement #15; b) X-ray after implant placement

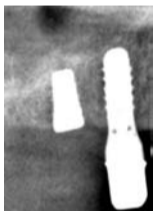


Fig 13b: Surgical guide for implant placement #15; b) X-ray after implant placement

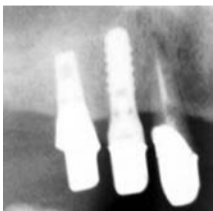


Fig 14a: Customised gold implant abutment #15 in place; a) X-ray; b) clinical view

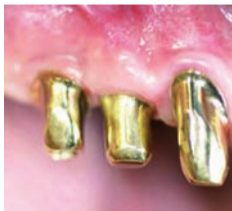

Fig 14b: Customised gold implant abutment #15 in place; a) X-ray; b) clinical view

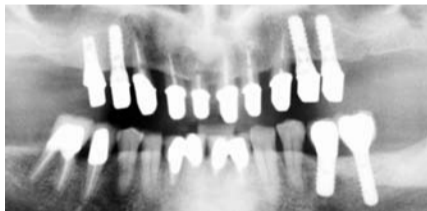

Fig 15: Orthopantomograph taken at the completion of treatment

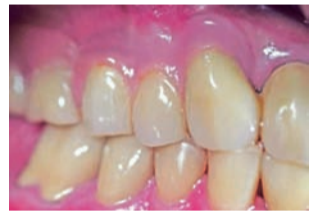

Fig 16: Clinical view

protocol (Fig. 6). Three months after implant placement, an impression post was positioned on the implant and the surgical stent was placed in the patient's mouth after the drill sleeve had been removed. The impression post was attached to the surgical stent using modeling resin (PATTERN RESIN, GC, Alsip, USA; Fig. 7). After this, the implant analog was attached to the impression post (Fig. 8a) and fixed in the cast using acrylic resin (Fig. 8b). A customised abutment fitting crown #13 was fabricated (Figs. 9a and b), positioned on the implant #13 and torqued to 35 Ncm (Figs. 10a–c). Subsequently, the denture was inserted (Figs. 11a and b).

Case 2

The patient (male, 61 years old and in very good general health) had a foul-mouth periodontal-implant and prosthodontic rehabilitation in 1998. After combined periodontal and

implant treatment the mandible was restored with single-fix crowns retained on natural teeth and implants (Fig. 12). The maxilla was restored (in the same way described above for the first case with a removable palatal free metalceramic bridge using double crowns, e.g. telescopic crowns, as attachments, retained on seven natural teeth (#14,13–23) and three implants (#13, 24, 25; RN, 10 x 4.1 mm, Straumann, Basel, Switzerland). Because the patient did not consent to a sinus augmentation, no implants were placed in regio #16 and #26. Tooth #14 was treated endodontically and was used as the last abutment (Fig. 12).

Thirteen years after prosthetic rehabilitation, the patient reported to the office with a root fracture in tooth #15. The tooth was extracted, the secondary telescopic crown in regio #15 was removed, and the

supraconstruction was temporarily filled with a photocured, highly elastic temporary material (Fermit, Ivoclar Vivadent, Ellwangen, Germany). The patient again refused a sinus lift and therefore the immediate implant placement regio #15 was scheduled. The axis of the tooth #15, the fabrication of the transfer key and the implant placement, were performed as pre-viously described in case 1. A short implant (Endopore 4.1 x 9 mm, Sybron Implant Solutions, Bremen, Germany) was inserted into area #15 (Fig. 13). Four months after implant placement, impressions were taken and a customised gold implant abutment and new secondary telescopic crown were fabricated and integrated into the same position as tooth #15 (Figs.14 and 15). During a healing period as well as after the integration of the new abutment and the new secondary telescope in the

bridge, the patient further used his telescopic maxillary restoration (Figs. 16a–d).

Discussion

The use of natural teeth and implants to support dentures incurs risks that may lead to loss of an abutment and, subsequently, the whole restoration. Recent reports have demonstrated a high long-term success rate of removable restorations supported by natural teeth and implants when double crowns, e.g. telescopic crowns, are used as attachments.[7-9] However, the use of the combination, e.g. connection, of natural teeth and implants to support fixed dentures is not advisable due to the higher risk of complications.[1,10] Cause for the loss of the abutment in case 1 was trauma from a car accident and not mechanical failure or periodontal infection or bone defects.

Continued on Page 15

Live MOUTH SMART

Join us
for World Oral
Health Day 2017!

Be confident through life

Good oral hygiene habits, avoiding risk factors and having a regular dental check-up from early in life can help maintain optimal oral health into old age. Visit the website to find out how to Live Mouth Smart.

www.worldoralhealthday.org



World Oral
Health Day
20 March



FDI World Dental Federation

Official World Oral Health Day 2017 Partners



World Oral Health
Day 2017 Supporter





Different Ways to Stay Healthy During Cold and Flu Season

Get Your Flu Shot

A cold is a mild infection of the upper respiratory tract that causes a runny nose, cough and sore throat. The flu hits much harder: Symptoms usually include fever, headaches, muscle aches and, at times, nausea and vomiting. You've heard it before, but it bears repeating: Get your flu shot! It's the best way to prevent the illness, and it's safe. Keep in mind that the vaccine's effectiveness wears off, so it's IMPORTANT to get inoculated every year.

Wash Your Hands

Both the common cold and the flu are contagious viral infections; you can catch a cold or flu if you come into contact with a contaminated person or object and then proceed to touch your face. Both viruses are airborne, and the influenza virus spreads particularly easily, so protect yourself, and those around you, by practicing good hygiene.

Wash your hands often-scrub with hot, soapy water for at least 20 seconds, or use an alcohol-based hand sanitizer if water isn't an option. Don't cough or sneeze into your hands; use tissues or your sleeve. And always avoid touching your eyes, nose and mouth.



It's that time of year again-cold and flu season is just around the corner. This year, be proactive by taking steps to prevent these illnesses before they start. Here are some strategies for staying healthy.

Keep it Clean

Virus droplets from a sick person's sneeze or cough can land on all kinds of surfaces, so make sure to disinfect things like doorknobs, remotes and phones. This is especially IMPORTANT if someone in your home or office has a cold or flu. Don't share drinking glasses, utensils or-yikes!-a toothbrush with anyone who's sick.

Boost Your Immune System

Regularly clean kids' toys. And when you hit the gym, remember to wipe down equipment before and after using it.

Speaking of the gym: Don't neglect your workouts as the weather cools down. Exercising is key to preventing illness because it keeps your immune system strong and healthy.

Eating a balanced diet will help stave off illness, too. Make sure you're consuming plenty of fruit and vegetables daily, and stay well-hydrated by drinking lots of water or herbal teas. Finally, make sure you're getting enough zz's: A restful night's sleep is crucial to a healthy immune system.

And if You Do Get the Flu...

Keep Oscilloccinum® readily available. One of the most popular homeopathic medicines, Oscilloccinum (Oscillo for short) helps reduce the duration and severity of flu-like symptoms such as fever, chills, body aches and headaches.

Listen to your body and give yourself the rest and recovery time you need. If your symptoms worsen-if you experience shortness of breath, chest pain, severe vomiting, or fever lasting more than 3 days-see your family doctor right away.

3 Ways to Manage Your Asthma

Wheezing, coughing, chest tightness-asthma is breathtaking, and not in a good way. Though there is currently no cure for the condition, the majority of sufferers can live full lives with the help of medication and trigger management. Here are three ways you can manage your asthma.

How to Prevent Asthma Attacks: Aerobics

Regular aerobic exercise helps strengthen the lungs and control weight, which, in turn, minimizes symptoms. Asthma should not be getting in the way of an active lifestyle, but if it does, try using a reliever inhaler (which relaxes the airways quickly) about 15 minutes before working out and take time to thoroughly warm up.

"If exercise continues to trigger symptoms despite these steps, it's a sign your asthma isn't properly controlled," says Dr. Guy Brusselle, the science council chair of the European Respiratory Society. Adjustments to your medication routine, made by a GP or a specialist, may be in order.



Beware of Cold Days

When winter arrives, many people find that the cold air sets off their symptoms and can worsen existing complaints. If you're among those sufferers, drape a scarf over your nose and mouth when you're outdoors on sub-zero days. Ideally, asthma patients should also get the annual flu shot and the one-time pneumonia vaccine to help avoid illnesses known to bring on attacks.



Visit Your Doctor Annually

What works one year might be less effective the next, as asthma tends to change over time. At least every 12 months, check in with a doctor who will track changes and administer a peak expiratory flow test to measure the amount of air you can move through your airways. You and the physician can then ensure your regimen is still appropriate for your asthma's severity.

Whatever you do, don't skip the annual visit, even if the coughing and wheezing have mostly subsided. You may be able to cut back on your



controller medication (pills or inhalers designed to continually prevent inflammation), since you should be taking the lowest amount necessary. Still, sufferers should carry a reliever inhaler at all times. No matter how mild the asthma, being prepared is always the smartest plan.

— Courtesy Reader's digest