

DENTAL TRIBUNE

The World's Dental Newspaper • India Edition

PUBLISHED IN INDIA

www.dental-tribune.com


VOL. 2 No. 1

News in brief

Calcium plays role in taste perception

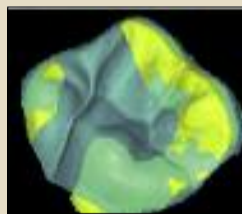
A new study, published in the *Journal of Biological Chemistry*, says that various extracellular calcium-sensing receptor (CaSR) agonists enhance sweet, salty, and umami taste, although they have no taste of their own. These characteristics are known as “kokumi taste” and it often appears in the Japanese cuisine.

The researcher Yuzuro Eto and his colleagues found that calcium and certain calcium channel activators trigger calcium channels located on the tongue, enhancing a specific taste. Further, it was found that glutathione (a common kokumi taste element) has no taste of itself but can enhance the basic taste sensation by interacting with these channels. The researchers believe that their study will pave the way in creation of healthy foods with minimal sugar or salt but, can still elicit strong taste.



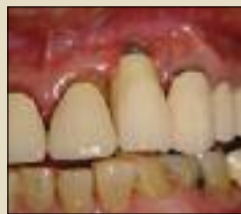Combination remedies are best for smoking cessation

A study, published in the Archives of *Internal Medicine*, says that the combined therapy with bupropion and nicotine lozenges, for smoking cessation, is better than any monotherapy. The study compared six-month abstinence rates among 1,346 smokers after treatment with five active pharmacotherapies—bupropion alone, lozenge, nicotine patch, nicotine patch & lozenge, and bupropion & lozenge. Combined pharmacotherapy of bupropion & lozenge was found to be superior with the abstinence rate of 29.9% followed by nicotine patch & lozenge combination with the abstinence rate of 26.9%. The nicotine patch alone was found to be least effective. These results reinforce the conclusion drawn from previous studies on efficacy of such a combined approach.



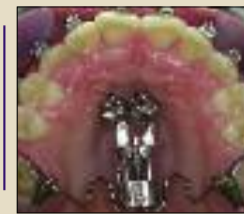Technology
The CAD/CAM evolution

▶ Page 6



Clinical
Implant aesthetics

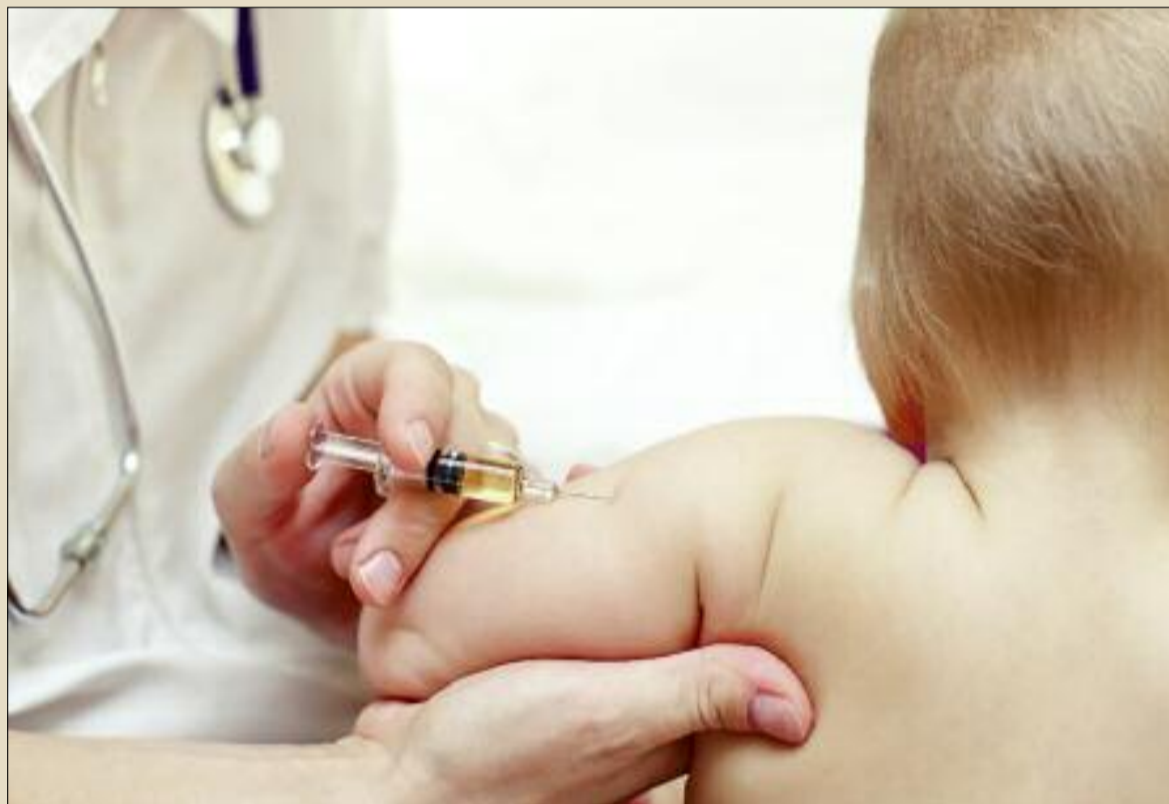▶ Page 9



Trends & Applications
Miniscrews—a focal point in practice

▶ Page 22

First vaccine for treating gum disease



A new vaccine could help to replace traditional periodontal treatment methods. (DTI/Photo Dmitry Naumov)

Daniel Zimmermann
DTI

HONGKONG/LEIPZIG, Germany: Scientists, at the University of Melbourne, Australia, have announced that they have partnered with CSL Limited and Sanofi Pasteur, the country's largest biopharmaceutical companies, to further develop and commercialise a vaccine for the treatment of gum disease. The programme, which has been for ten-years in develop-

ment, involves bacterial peptides and proteins that trigger the immune response to periodontal inflammation. The vaccine is currently being tested in mouse models and is expected to progress to clinical trials soon, the researchers said.

The new vaccine approach is targeting the ‘ring leader’ of a group of pathogenic bacteria called *P. gingivalis* that cause periodontitis. According to a US-

based consortium for *P. gingivalis* research, elevated levels of the organism were found in the majority of periodontal lesions, as well as in low levels in healthy sites. In addition, the organism also produces a number of enzymes that have been shown to interact with and degrade host proteins. Although the bacterium can be eliminated through periodontal therapy, it is often found in recurrent infections.

“Periodontitis is a serious disease and dentists face a major challenge in treating it, because most people will not know they have the disease until it's too late and the infection has progressed to advanced stages,” says Prof. Eric Reynolds, CEO of the Cooperative Research Centre for Oral Health Science and the Head of the University of Melbourne's Dental School. “This new approach will provide dentists and patients with a specific treatment.”

Traditional periodontal therapy involves manual scaling and cleaning, and even surgery with instruments or dental lasers in an effort to contain the bacterial infection. Reynold said that their new line of vaccine products will possibly prevent the progression of the disease, rather than managing its symptoms and damaging consequences. Sanofi Pasteur has an option, to an exclusive worldwide licence, to commercialise the intellectual property associated with these products.

DTI

Painless plasma jets could soon replace dentist's drill

Claudia Salwiczek
DTI

LEIPZIG, Germany: Firing low temperature plasma beams at dentin reduces the amount of dental bacteria by up to 10,000-fold, according to a new study published in the February issue of the *Journal of Medical Microbiology*. Plasma technology could thus be an effective and less painful alternative to the dentist's drill.

Scientists at the Leibniz

Institute of Surface Modification, Leipzig and dentists from the Saarland University, Homburg, Germany, tested the effectiveness of plasma against common oral pathogens. The researchers infected dentin from extracted human molars with 4 strains of bacteria and then exposed it to plasma jets for 6, 12 or 18 seconds. The longer the dentin was exposed to the plasma the greater the amount of bacteria that were eliminated.

Dr Stefan Rupf from Saarland University, who led the research, said that the recent development of cold plasmas showed great promise for use in dentistry. “The low temperature (around 40 degrees Celsius) means they can kill the microbes while preserving the tooth. The dental pulp at the centre of the tooth, underneath the dentin, is linked to the blood supply, and nerves and heat damage to it must be

avoided at all costs.”

Plasmas have an increasing number of technical and medical applications. Hot plasmas are already used to disinfect surgical instruments. “Presently, there is huge progress being made in the field of plasma medicine and a clinical treatment for dental cavities can be expected within 3 to 5 years,” Dr Rupf added. DTI

FDI, FOLA, and DTI launch campaign for Haitian dentists



FOLA president Adolfo Rodríguez, center, asking for help for Haiti at a meeting in Panama. In the image, he's surrounded by the president, right, and vice president of the Panama Dental Association

Javier M. de Bison
DT Latin America

PANAMA CITY, Panama: The president of the Haitian Dental Association Dr. Samuel Prophet has told Dental Tribune Latin America that he and several colleagues, he was able to contact in Port-au-Prince were fine after the devastating earthquake in his country. "So far, we only have reports of two missing dentists", Prophet wrote in an email.

The recent earthquake not only devastated Haiti's meager

health resources, but also most dental practices. In a country where there were only 500 dentists for nine million people before January 12th, the extent of the devastation has affected regular people and dental professionals alike.

The president of the Latin American Dental Federation (FOLA), Dr. Adolfo Rodríguez, launched a campaign after the quake asking companies and dental professionals to donate dental instruments, materials, and equipment. He's organising

the campaign for Haiti with the help of FDI World Dental Federation, and Dental Tribune International.

In addition, Dr. Rodríguez is putting together teams of dental volunteers to travel to Haiti to attend to the dental needs of the population. "We also need to show our support for our colleagues in Haiti, most of whom have lost everything," Rodriguez said. "We need to get them back on their feet by helping them to rebuild their practices."

Dr Prophet said, in his email, that "many of our colleagues have lost their practices and we were thinking about how to help them. It's very good news to know that FOLA, FDI and Dental Tribune are trying to help Haitian dentists." If dentists know "that help is on the way they can have hope!" Dental Tribune will publicize, in its worldwide print and online editions, the campaign for Haiti.

At a meeting in Panama, Dr Rodríguez of FOLA received the support of the presidents of Central American Dental Associations, and made an emotional appeal to dental manufacturers to donate much needed supplies. He said, "Colgate has already agreed to donate brushes and toothpaste, and that he intended to meet with KaVo do Brasil in the upcoming CIOPS meeting in Sao Paulo to ask for donations of new and used dental units."

Some prominent Latin American Dental Professionals from Brazil, Uruguay, and Costa Rica among others have already expressed their interest in

participating in dental teams to help the most urgent needs of the Haitian population.

The president of FOLA said, "this tragedy is also an opportunity to build a public health service that includes dental care. We have asked the Pan American Health Organization (PAHO), FDI, all Latin American dental associations, companies, and other institutions for help in putting together teams of dental professionals to travel to Haiti and start working there, and leave in place basic dental treatment centers." Dr. Rodríguez said that this will be a long-term programme that includes rebuilding the dental school at the university, as well as private practices.

The Latin American dental leader said he has also asked for funding from the government of Dominican Republic. Companies and dentists interested in helping Haiti should contact Dr. Rodriguez at arn@codetel.net.do, phone at +809 519-0789.

DT

Dental health meet to raise awareness in public

Dr. Isha Goel
DT India

A dental health awareness program 'Dental Health Utsav' for the public was organized in Delhi that registered attendance by about 5000 city folks. This mass outreach gathering was held at the Maulana Azad Institute of Dental Sciences (MAIDS) on 15th of December, 2009, as part of an annual public health initiative to raise awareness on the importance of role of dental health to stay fit. In addition to providing free health check-up and advice, the organizers conducted events to engage public with lecture sessions, smile competition, and a dental quiz, to get the message across.

This assembly was well attended by representatives of the establishment, including the chief minister, the health minister, and the health secretary of Delhi. Dr. Mahesh verma, head of the MAIDS and chief organizers of this meeting, commented, "the first symptoms of various dis-

eases including diabetes, AIDS, certain cancers, eating disorders, venereal disease, and substance abuse can be traced through one's oral health." He further added, "in recent years, dozens of studies have shown that periodontal disease may contribute to cardiovascular disorders, stroke and bacterial lung infection, and thus, maintaining good oral health is important for overall health, and the mouth can serve as a looking glass."

Expressing her concern at the growing incidence of dental problems in school-going children, the chief minister, Mrs. Shiela Dixit said, "preventing tooth decay in youngsters by intervening early should be initiated at school itself. More than 80 % of population is suffering from various dental ailments and most of them are preventable with early education."

On the occasion, the MAIDS was also entrusted with the task

to provide dental emergency services to the athletes and delegates during the 2010 Commonwealth Games, which are to be held in the city in October this year. GB Pant Hospital, a tertiary care facility located in the same campus will offer other emergency services to the participants of this sports meet. DT



Courtesy: Maulana Azad Institute of Dental Sciences, New Delhi.

International Imprint

DENTAL TRIBUNE

The World's Dental Newspaper • India Edition

Published by Jaypee Brothers Medical Publishers (P) Ltd., India

©2010, Dental Tribune International GmbH. All rights reserved.

Dental Tribune India makes every effort to report clinical information and manufacturer's product news accurately, but cannot assume responsibility for the validity of product claims, or for typographical errors. The publishers also do not assume responsibility for product names or claims, or statements made by advertisers. Opinions expressed by authors are their own and may not reflect those of Dental Tribune International.

Publisher
Torsten Oemus
t.oemus@dental-tribune.com

Chairman DT India
Jitendar P. Vij
jaypee@jaypeebrothers.com

Director
P. N. Venkatraman
venkatraman@jaypeebrothers.com

Chief Editor
Dr. Naren Aggarwal
naren.aggarwal@jaypeebrothers.com

Editor
Dr. Isha Goel
isha.goel@jaypeebrothers.com

Editorial Consultants
Dr. Gurkeerat Singh
Dr. Amit Garg

Dental Tribune India
Published by: Jaypee Brothers Medical Publishers (P) Ltd.
4838/24, Ansari Road, Daryaganj,
New Delhi 110002, India
Phone: 43574557
e-mail: jaypee@jaypeebrothers.com
Website: www.jaypeebrothers.com

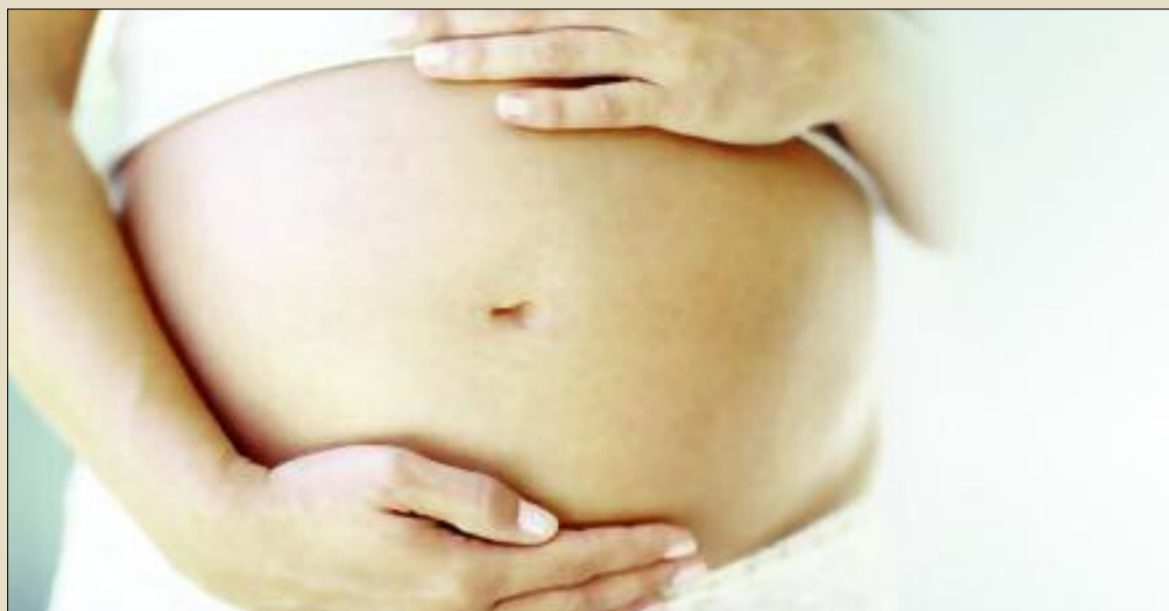Oral bacteria linked to stillbirth

By Case Western Reserve University School of Dental Medicine

CLEVELAND, OH, USA:

Researchers at the Department of Periodontics at Case Western Reserve University School of Dental Medicine reported the first documented link between a mother with pregnancy associated gum disease to the death of her fetus. The studies findings will be discussed in the February issue of *Obstetrics & Gynecology*.

Approximately 75 per cent of pregnant women experience gum bleeding due to the hormonal changes during pregnancy. "There is an old wives' tale that you lose a tooth for each baby, and this is due to the underlying changes during



Pregnant women should take extra care of their oral health. (DTI/Photo Yuri Arcurs)

pregnancy," said Yiping Han, lead researcher of the study. "But if there is another underlying condition in the background, then you may lose more than a tooth but a baby."

Due to pregnancy-associated gingivitis, *Fusobacterium nucleatum*, a bacteria commonly found in the mouth, entered the blood and worked its way to the placenta. Han was able

to match the bacterium found in the mother's mouth with the bacterium in the baby's infected lungs and stomach.

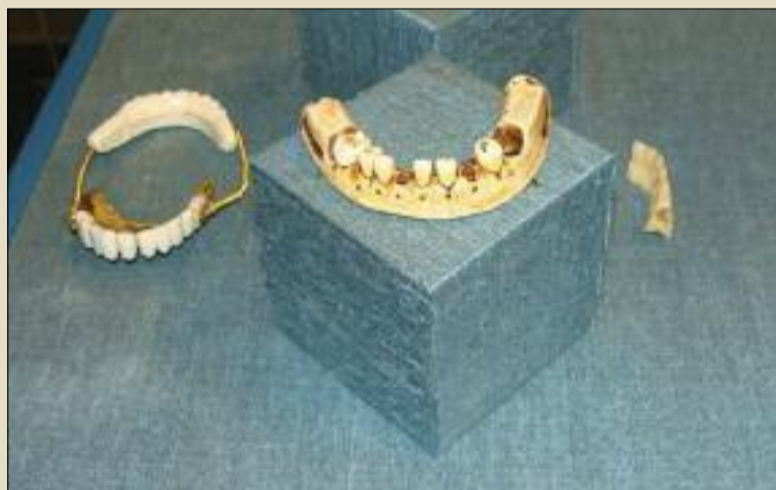Normally a mother's immune

system takes care of the bacteria in the blood before it reaches the placenta. In this case, the mother had experienced an upper respiratory infection and a low-grade fever just a few days before the stillbirth. The baby died from a septic infection and inflammation caused by the bacteria.

The study underlines the growing importance of good oral health care. In addition to this direct link from the mother to her baby, oral bacteria have been associated with heart disease, diabetes and arthritis.

(Edited by Claudia Salwiczek, DTI)

Museum dispels myth about George Washington's teeth



George Washington's teeth are on display at the National Museum of Dentistry in Baltimore. (DTI/Photo Fred Michmershuizen)

Fred Michmershuizen
DTA

BALTIMORE, MD, USA: Did you know that George Washington's false teeth were not really made of wood? Those who visit the National Museum of Dentistry, located here, can see first president's famous choppers on display, & they can find out more about his tooth troubles. The story about wooden teeth is a myth.

"Many people are surprised to find out that George Washington never had wooden dentures," said Museum Curator Dr. Scott Swank, in a recent press release. "We think the myth arose since ivory dentures tend to stain like wood after years of eating and drinking."

The National Museum of Dentistry features a gallery devoted to the first president

and his tooth troubles. His dentures — which were actually made of ivory — are on display, as well as forceps made to pull his teeth on the Revolutionary War battlefield and examples of presidential portraits that show how tooth loss affected Washington's appearance.

According to the museum, Washington lost his first tooth when he was 22 years old. Despite the fact that he brushed with tooth powder daily, he would have only one tooth in his mouth by the time he was inaugurated president in 1789. Washington had many illnesses during his life, including smallpox and malaria. Treatments included remedies like mercurous chloride, which is known to destroy the teeth.

His favorite dentist, John Greenwood, would make several

sets of dentures for Washington during his lifetime — and none of them would be made from wood, according to the

museum. In fact, they were carved from hippopotamus ivory and elephant ivory. Some of the dentures were set in

gold and held in place with springs that held the upper and lower teeth together.

In Pericoronitis / Tooth Abscess¹

BIDANZEN FORTE
Seriatopепtidase Tablets 10 mg

OPENS WAY FOR SPEEDY HEALING

- Significantly reduces post-surgical cheek swelling and pain^{2*}

* Data derived from a study comparing BIDANZEN FORTE 10 mg tablets with 1000 mg of paracetamol in surgical extraction of 21 teeth.
Ref: 1. Prescribing Information Bidanzen Forte
2. Al-Husseini TH, Fuster T. Effect of the proteolytic enzyme seriatopепtidase on swelling, pain and tissue after surgical extraction of mandibular third molars. Int J Oral Maxillofac Surg. 2008 Mar;37(3):284-8

BIDANZEN FORTE - Abbreviated Prescribing Information:
Active ingredient: Enteric film coated tablet containing Seriatopепtidase 5mg (10,000 units) and 10 mg (20,000 units) respectively. Indications: Reduction of swelling after operations: tonsure, chronic sinusitis and parodontitis. Difficulty to expectorate: chronic, pulmonary tuberculosis, bronchial asthma, post-operative, perforation of wisdom tooth, alveolar abscess, cystitis, Osseous and Arteriosclerosis. Adults: Daily dose of 70-80 mg orally, in 3 divided doses after each meal, as rapidly as possible according to local and age conditions. Children: One 5 mg tablet 2-3 times daily after meals, depending on degree of severity of disease. Contraindications: Hypersensitivity, Windings and Pericarditis. Interactions: Effects on Ability to Drive and Use Machines: Pregnancy and Lactation: No specific data available. Adverse Reactions: Skin - Stives - Abrasion syndrome, local epidermal necrosis, rash, psoriasis. Hypersensitivity - Shock, anaphylactic symptoms, Hiccup - Hiccup, sneeze.

GSK
GSK SmithKline Beecham
Refer to full prescribing information before use.
For full prescribing information please contact: GSK SmithKline Beecham Pharmaceuticals Ltd., Dr. Amal Basant Road, White, Mumbai 400 033.
® Registered Trademark

AMD updates laser for soft tissue surgery



Alan Miller, President/CEO of AMD LASERS. (DTI/Photo courtesy of AMD Lasers, USA)

NEW YORK, USA/LEIPZIG, Germany: The US-based manufacturer AMD LASERS has recently launched the Picasso Lite to the worldwide dental markets. As first in the industry, this new and improved soft tissue dental laser will be able to use convenient disposable tips or a low-cost strippable fiber for a wide range of applications, the company said in a press

release. Picasso Lite aims specifically at dental hygienists and dentists who have no or little experiences with dental lasers.

Dentists can use Picasso Lite for all kinds of soft tissue surgery, including troughing, gingivectomies, frenectomies, exposing implants/teeth/ortho brackets, and treating aphthous ulcers and herpetic lesions. According to the company, it cuts and coagulates tissue with reduced trauma, bleeding, and necrosis of tissue.

Picasso Lite, which is priced at US\$2,495, comes with a set-up DVD, online laser certification, accessories and a world power adapter. AMD LASERS offers a two-year warranty on all its products. [DTI](#)

Countries in Asia less than average in health care spending



Health care spending has improved in Asia but still is below average. (DTI/Photo Sean Prior)

Daniel Zimmermann
DTI

LEIPZIG, Germany: Asian countries have been found to spend less of their GDP's for health care than most other countries in Europe and the US. According to a new health

care report by the Organisation for Economic Co-operation and Development (OECD) in Paris, only New Zealand provided more money for health care than the average of all observed countries. Japan, Korea and Australia, however, spent less than the OECD average of 8.9 per cent of GDP.

The US currently spends more on health care than any other country—almost two and a half times greater than the OECD average of US\$ 2,984, adjusted for purchasing power parity. Luxembourg, France and Switzerland also spend far more than the OECD average. At the other end of the scale, health-care expenditure in

Turkey and Mexico is less than one-third of the OECD average.

The latest edition of Health at a Glance demonstrates that all the countries observed could do better in providing good quality health care. Key indicators presented in the report provide information on health status and the determinants of health, including the growing rates of child and adult obesity, which are likely to drive higher health spending in the coming decades. Based on new data on access to care, the report demonstrates that all OECD countries provide universal or near-universal coverage for a core set of health services, except the US, Mexico and Turkey. [DTI](#)

Europe's Swiss Smile enters India

DELHI, India: Swiss Smile Dental Clinics—Europe's leading dental service brand has chosen India for its business expansion outside Europe. Swiss Smile has tied up with Global Tech Park to launch a chain of clinics in India at a total investment of around US\$ 30 million. The planned dental clinics will provide state-of-the-art facilities and trained consultants offering specialized dental care to customers, all under one roof.

Dr. Sathya Kallur, CEO and Director of clinical operations of India, speaking on the plan said, "starting from Bangalore, we are planning to set up ten dental clinics in major cities of India like NCR, Hyderabad, Chandigarh, Mumbai, Ahmedabad, Chennai, Kolkata and Pune within next three years." Dr. Sathya added that this venture will also attract medical tourism in India by offering quality services at leaner costs

to overseas patient.

Medical tourism, in India, is estimated to grow 29 per cent by 2009-12 to become a \$2.4 billion industry. India Brand Equity Foundation (IBEF) quoted a market research report "Booming Medical Tourism in India" to claim that despite the economic slowdown, medical tourism in India is the fastest growing segment of the tourism industry. [DTI](#)

Customized implant abutments: Sirona launches titanium bases



The Sirona TiBase, shown here with the abutment screw and scan body, is compatible with numerous popular implant systems. (DTI/Photo Sirona)

by Sirona Dental Systems, Inc.

BENSHEIM, Germany: Since December 2009, the Sirona inLab system is capable of producing customised zirconium oxide abutments for a wide range of popular implant systems. Following the successful launch with CAMLOG, Sirona has now introduced its own titanium bases for implant systems from Nobel Biocare, Straumann, Astra Tech, Friadent, Biomet 3i and Zimmer. The matching TiBase connector, supplied in a set with the scan body and abutment screw, is adhesively bonded to the milled and sintered zirconium oxide mesostructure.

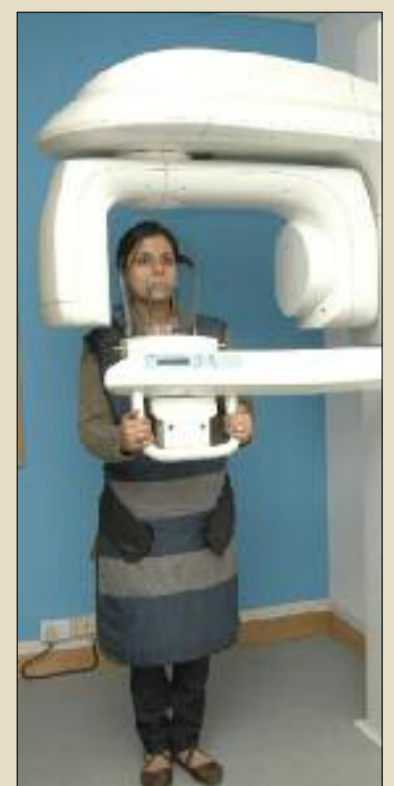With the aid of the new inLab 3D for Abutments V3.65, it is now possible to design a zirconium oxide abutment and matching crown in one single step. After the implant position

using the inEos scanner is acquired, a fully anatomical crown can be designed in only one step. The mesostructure is created automatically by reducing the crown. Optimum flexibility is ensured by various adjustable parameter settings, e.g. telescope angle, shoulder width and gingival pressure.

Both components i.e. the zirconium oxide abutment and the feldspar or glass-ceramic crown can be milled on the inLab MC XL unit. Alternatively, users have the option of applying a veneer facing directly to a partially reduced abutment, as is the case with a conventional crown stump. The prefabricated inCoris ZI meso zirconium oxide blocks are rotation-secured. They are available in two different shades and in two connector sizes, which speeds up the milling process. [DTI](#)

Cone-Beam CT in India

DELHI, India: Kodak has installed its 9500 3D cone-beam computed tomography (CBCT) machine for dental imaging at Diwan Chand Imaging Center in Delhi, India. This is the first machine from Kodak in India.



CBCT designed for imaging hard tissues of the maxillofacial region allows three-dimensional imaging of a focused area, with relatively low radiation exposure. CBCT technology promises to change the paradigm in dental radiology by providing clear and clean view of the entire field determining bone structure, tooth orientation, nerve canals and pathology, and to aid dental professionals in making accurate diagnosis and in treatment planning. [DTI](#)

Courtesy: Diwan Chand Satyapal Aggarwal Diagnostic Imaging Research Centre, New Delhi.

The legacy of smile continues... with Sun Medical

The Etruscans
Initiator of Restorative Dentistry

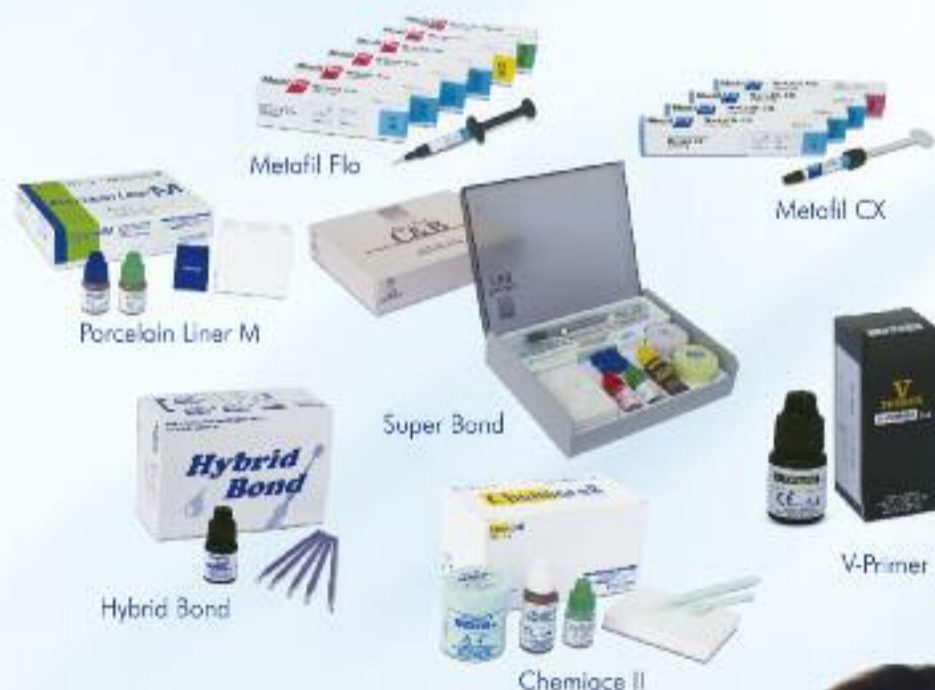“A civilization of rich human knowledge, which through its culture, art and inventions has influenced the generations.”

At Sun Medical, we have taken what the Etruscans started to a whole different level. Developed with hard core R&D and intensive quality management, we are on a mission to serve the world with the finest dental materials.

Sun Medical, the future of modern restorative dentistry.

Presenting Futuristic Dental Care in India

- ⊙ **Super Bond** – Dental adhesive system with 4-META/MMA-TBB
- ⊙ **Hybrid Bond** – Bonding agent for resin based dental restorations and protective coat for dentin
- ⊙ **Chemiace II** – 4-META adhesive resin cement
- ⊙ **Metafil Flo** – Hybrid resin-based dental restorative material
- ⊙ **Metafil Cx** – Composite resins with TMPT fillers chemically bonded to matrix
- ⊙ **V-Primer** – Adhesive Primer for metals /precious metals
- ⊙ **Porcelain Liner M** – Adhesive Primer for Porcelain Bonding



www.hubdirectres.com/215/MITSUJ01/10

A Sincere Company

Sun Medical, based on intensive R&D and academically oriented dental manufacturing company from Japan.



Sun Medical Co. Ltd. - 571-2, Furutaka-cho, Moriyama, Shiga, 5240044, Japan, Phone: 81-77-582-9981,
Fax: 81-77-582-9984, E-mail: export@sunmedical.co.jp, Website: www.sunmedical.co.jp

Glaze Dental Depo Pvt. Ltd. - Bungalow no. 7, R.S.C. No. 19, SVP Nagar, Near Akashdeep Building, Behind Versova Telephone Exchange,
4 Bungalow, Andheri (W), Mumbai - 400053, Phone: 91-22-6457-5500 Upto 5523, Fax: 91-22-64575504/5, Website: www.glazedepo.com

The CAD/CAM evolution

Computers in practice and laboratory will determine action

Prof. Albert Mehl
Switzerland

Impression-free practice, virtual construction models and articulation on Windows desktops, biogeneric occlusal surface design with intelligent software, as well as rapid prototyping, and 3-D printing are just some of topics increasingly mentioned in lectures and publications dealing with CAD/CAM. Already, 'conventional' CAD/CAM technology is in use in dental offices and laboratories, and now the next step in CAD/CAM evolution is anticipated. Only a few years ago, discussion focused on exactness of fit, the reduced costs for dentists and patients, and user-friendliness. The quality of CAD/CAM restorations was viewed with cynicism, and only a few pioneers gave scientific attention to this technology. At present, the situation is quite different. The hesitant & doubtful attitude towards computer-manufactured dental prostheses has been discarded, and an accepted, standard procedure has taken its place. Many

of CAD/CAM systems has clearly improved. Based on more powerful computers and effective measuring techniques developed in the 1990s, it was possible to adapt 3-D recording/imaging systems to the needs of dentistry and simplify their operation. Continued development of CAD software enabled a multitude of construction options (Fig. 1) and an improvement in the quality of the grinding/milling units. Economic efficiency, combined with high quality restorations, is the current hallmark of CAD/CAM technology. It is not only dentists and dental engineers who benefit from standardised and excellently-controlled treatment and manufacturing methods, the patient does as well.

What is the latest in CAD/CAM development? Anyone well acquainted with the field predicted early on that manufacturing centres would play a crucial role: high capacity utilisation, specialised staff, centralised material purchasing, and high

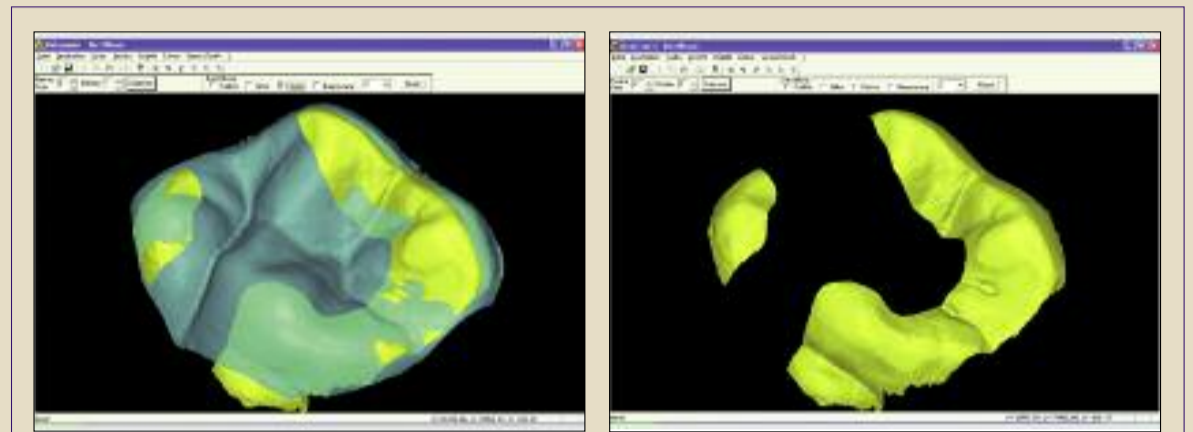


Fig. 2: The remaining tooth substance determines the morphology of the occlusal surface in the defect region, largely through, for instance, the position of the cusp tips, the cusp slopes, and the course of fissures. The natural rules governing the biogeneric occlusal surface can be found through the analysis of many thousands of occlusal surfaces of natural teeth. (DTI/Photo A.Mehl)—Fig. 3: Using the natural laws thus found, an occlusal surface is calculated that replaces the defect as naturally as possible, by adapting it to the remaining tooth structure. (DTI/Photo A.Mehl)

pointment treatment has a time-saving benefit for the patient and eliminates provisional restoration, which additionally minimises the risk of cusp fracture, enamel-margin chipping, and weakening of the dentine bond. The biogeneric formation of occlusal surfaces enables the reconstruction of missing occlusal surfaces for inlays, onlays, and partial crowns according to nature's designs (Figs. 2, 3).

CAD/CAM and all-ceramics are often mentioned in conjunction with each other, which is understandable given the discussion above, but this doesn't represent all the options. The enormous potential in milling procedures and, just recently, in the laser sintering of metals is often completely forgotten. The manufacture of metal restorations (eg, non-precious metals, titanium, or gold alloys) will thus eventually become a domain of CAD/CAM technology.

What does the future of CAD/CAM technology hold? Intra-oral 3-D measuring will at least in part make the impression-free practice possible (Fig. 4). The speed, operation, and precision of the images are being continually improved and the measurement range expanded. Once a 3-D data set of tooth surfaces has been stored, a completely novel form of dental diagnostics can be conducted, by comparing data that were recorded at different time points. Thus, quantitative, 3-D progression control of orthodontic treatment, the analysis of erosion

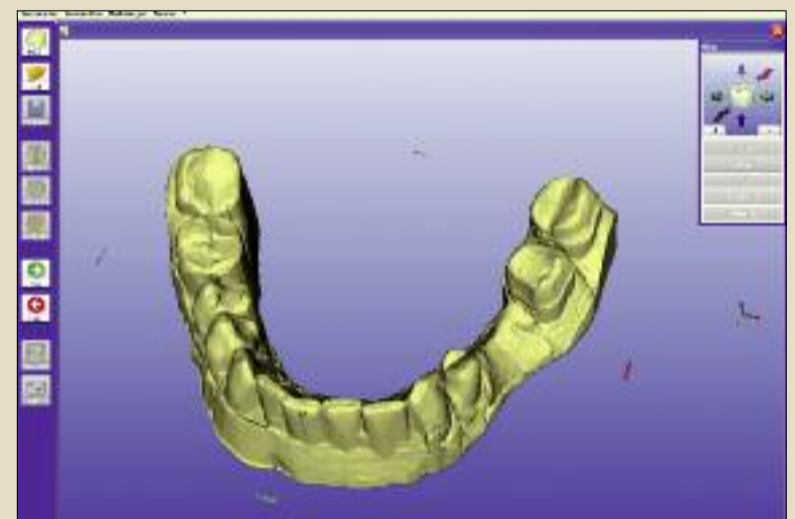


Fig. 4: In the future, intra-oral camera scanners will enable optical impressions of the entire jaw, thus preparing the way for the impression-free practice. (DTI/Photo K. Wiedhahn)

& abrasion, periodontal change, or inter ventions is possible.

A distinct advantage of computer-assisted procedures over the conventional wax-up technique also lies in the functional and morphological occlusal surface design. Complex algorithms can store an immense amount of basic knowledge about tooth structures and individual genetic contexts. Virtual articulators can simulate any programmable movement, so that considerably more natural laws and limits, as well as individual parameters, can be integrated into the restoration surface than has been possible up to now.

The needs of CAD/CAM technology have propelled basic research to new heights and thus advanced other areas of dentistry. Through cooperative ventures, universities and industry can form a useful symbiosis to promote and shape this exciting development. Until now, CAD/CAM or computer-assisted dentistry has not been a central subject at the

universities. But because the technology is relatively new and the performance potential of CAD/CAM technology is tremendous, this is certain to change in the next few years, which in turn will influence the training of dental students and indirectly the treatment possibilities in practices as well, in the interests of our patients. ■



Fig. 1: Virtual automatic reconstruction: the scanned data of the antagonist, functional movement, adjacent teeth and the preparation can be considered in toto, in order to create a fitting occlusal surface that follows all the rules of dentistry and dental engineering. (DTI/Photo A. Mehl)

companies now invest immense resources in the further development of this technology.

What impelled this rapid change? On the one hand, the value of zirconium dioxide ceramic in particular, which can only be processed with computer-assisted techniques, became evident. This material made all-ceramic fixed partial dentures possible for the first time. Other ceramics, too, exhibited better material properties after automated milling because the blanks used could be industrially manufactured under optimal conditions. On the other hand, the technology

quality standards for 'standard care' facilitate an economical throughput, which in turn enables the amortisation of the investment in highly developed manufacturing machines, while increasing economic efficiency. Mid-sized and smaller labs will use their core competence in the computer-assisted manufacture of high quality, aesthetic restorations and special fabrication of partial prostheses.

Another important current trend is the chairside manufacture of inlays, onlays, partial crowns, and single crowns. The dentist is this CAD/CAM procedure's target group. The one-ap-

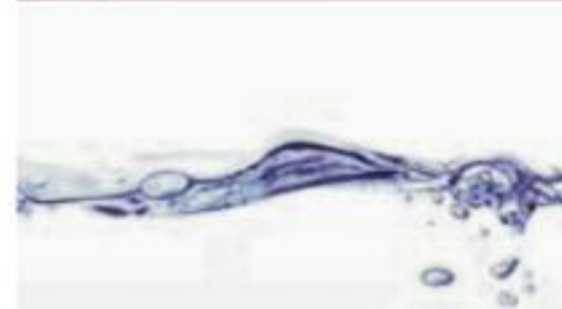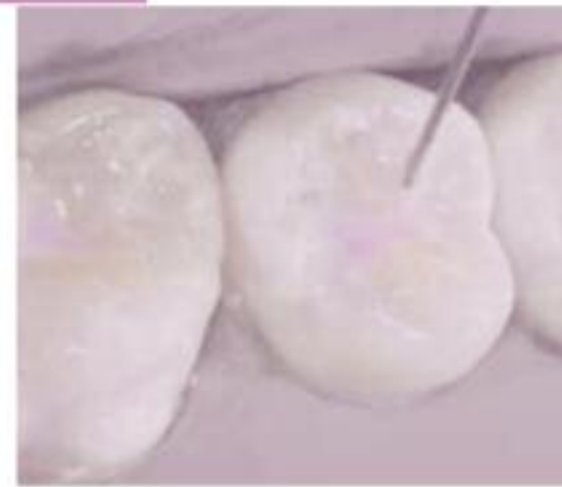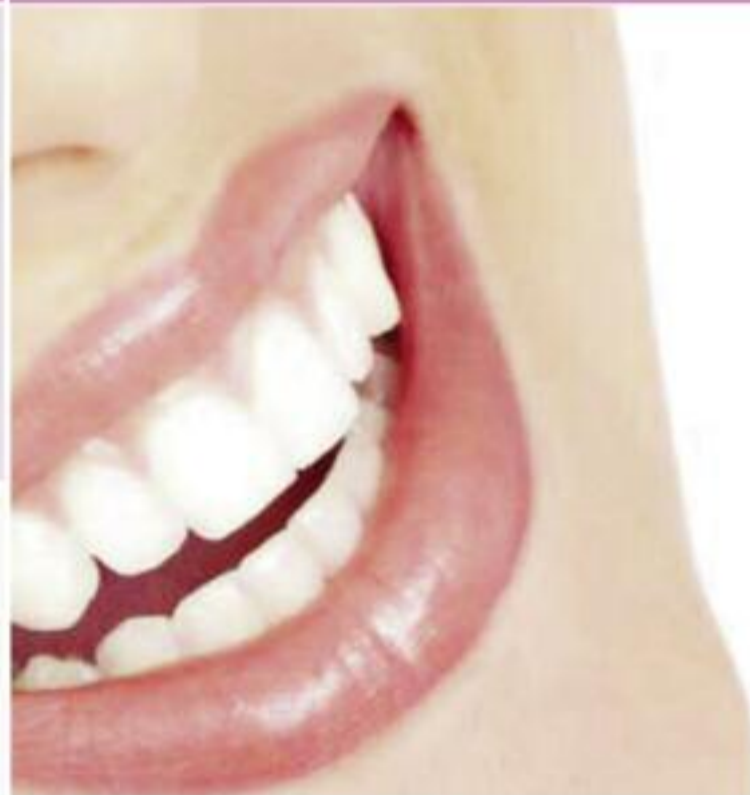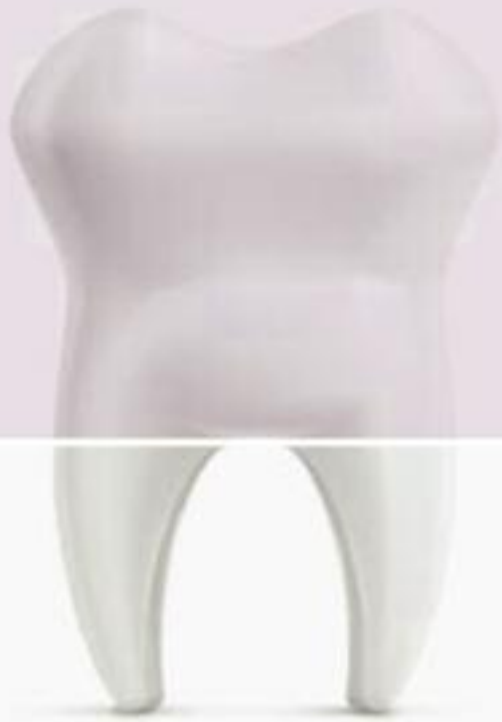Contact Info



Prof. Albert Mehl is currently guest professor at the Center for Dentistry and Oral Medicine, University of Zürich, Switzerland. He can be reached at info@ag-keramik.de.

Clinpro™

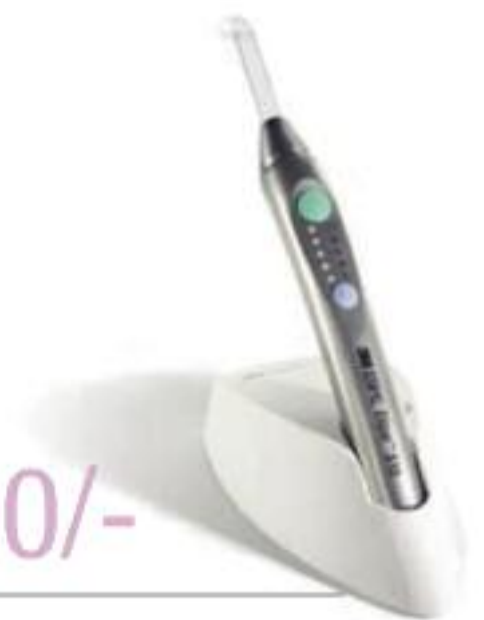3M ESPE Preventive Care



Setting New Standards For Prevention Around The World

3M ESPE gives you an

exclusive opportunity to win an
Elipar™ S10 LED Curing Light worth **Rs 66,000/-**



For more information on the "Clinpro Promotion Offer"
contact your 3M ESPE sales representative or call **1-800-425-3030**

*offer valid till March 31" 2010

Directa presents new solutions for Class II cavity preparations

Daniel Zimmermann
DTI

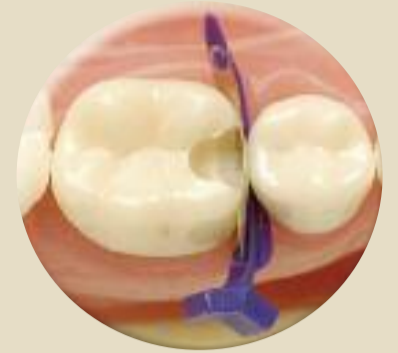LEIPZIG, Germany: Placing a matrix band to attain a good contact point and avoiding interproximal overhang after excavation for Class II fillings has always been a time consuming & laborious procedure. Directa has announced to offer a unique

and easy solution for this procedure by combining a separating plastic wedge with a stainless steel matrix. The Fendermate is available in regular and narrow width and for left or right application and will be colour coded for better identification.

According to the Swedish company, the combined matrix and wedge are inserted as one piece. A new technology contours and compliments the curvature of the patients tooth and holds its shape without having to use a retentive ring that inhibits access to a cavity.

The contact point is created by the dual curvature of Fender-Mate so that further burnishing will not be necessary.

With the combination of FenderMate and Fender Wedge, Directa also offers a tissue friendly approach for the



preparation and filling of Class II cavities. [DTI](#)



**DENTAL TRIBUNE
DT STUDY CLUB**
COURSES | DISCUSSIONS | TECHNOLOGY | ON-DEMAND

“Online learning is not the next big thing,
it is the now big thing.”

Donna J Abernathy
Training and Development, Editor

DTSC - COURSES, COMMUNITY, TECHNOLOGY, ON-DEMAND

The DT Study Club makes all of this possible from the comfort of your own computer and without travel expenses. In other words, welcome to the community!

The purpose of this study club is to provide practitioners like yourself an opportunity to learn and network with like-minded colleagues in a friendly, non-threatening environment. We encourage you to take advantage of Dental Tribune's global outreach to access a variety of fresh perspectives and cultures, enhancing your educational mix.

24/7 LIVE AND INTERACTIVE ONLINE COURSES

Fulfill your yearly CE requirements with our growing list of archived ADA CERP approved courses.



DISCUSSION FORUMS

focused on helping today's practitioners to stay up to date. Networking possibilities that go beyond borders to create a truly Global Dental Village



VIDEO REVIEWS OF PRODUCTS

Our opinion leaders unveil new products, services, and give you their first impressions of the industry's hottest topics.



PEER REVIEWED CASE STUDIES

Upload, comment, participate. We encourage you to share your cases for review with like-minded practitioners.





REGISTER FOR FREE ON WWW.DTSTUDYCLUB.COM

CONTESTS WITH CHANCES TO WIN FREE TUITION FOR ADA/CERP C.E. ACCREDITED WEBINARS

SPONSORSHIP AND SPEAKING INQUIRIES:
JULIA WEHKAMP, J.WEHKAMP@DTSTUDYCLUB.COM, (416) 907-9836.

Pm

PRACTICE MANAGEMENT

Gd

GENERAL DENTISTRY

Co

COSMETICS

En

ENDODONTICS

Im

IMPLANTOLOGY

Pe

PERIODONTICS

Or

ORTHODONTICS

Dh

DENTAL HYGIENE



WWW.DTSTUDYCLUB.COM

Rice University to work on oral cancer test

Daniel Zimmermann
DTI

NEW YORK, NY, USA/LEIPZIG, Germany: Researchers at the BioScience Research Collaborative at Rice University in Houston in the US have received a US\$2 million grant from the US National Institutes of Health for the development of a new test for detecting oral cancer. The test, which utilises latest LED and nano microchip technology, aims to provide an accurate diagnosis in less than 30 minutes and can be performed in the dental office. Additional tests for the detection of cardiovascular diseases and HIV are also in development, the researchers said.

Oral cancer affects about 300,000 people per year worldwide, and most cases are diagnosed in the late stages. If oral cancer is detected early, the prognosis for patients is excellent, with a 5-year survival rate of more than 90 per cent. Unfortunately, the actual 5-year survival rate for oral squamous cell carcinoma is only about 50 per cent, amongst the lowest rates for all major cancers.

“We want to provide an accurate diagnosis for oral cancer using a minimally invasive test that requires no scalpels or off-site lab tests,” said principal investigator Prof. John McDevitt, Rice’s Brown-Wiess Professor of Chemistry and Bioengineering. “The payoff for this could be tremendous because oral cancers today are typically diagnosed much too late in their development.”

According to McDevitt, the test is being developed in collaboration with other scientists from universities in the US and the UK. [DTI](#)

Implant aesthetics

Prof. Porus S. Turner & Team
India

Since 1980s, osseointegration with dental implants has become a predictable dental procedure with high success rate of over 97%.¹⁻⁵ Today making a fixed partial denture after reducing two adjacent teeth is not the treatment of choice, and, instead, a single tooth replacement with an implant-supported crown has become the most frequent indication in implant therapy.⁶ In the posterior areas of the oral cavity, the most important objective of a single tooth replacement is to allow adequate mastication, while the aesthetic outcome is of lesser concern. In contrast, replacing the anterior teeth in the pre-maxillary zone - often referred to as the 'aesthetic zone' - requires a cosmetic finish to patient's satisfaction. This presents a major challenge for implant clinicians & technicians (Fig 1). There are major difficulties in placing the implants because of various local risk factors that can compromise the final aesthetic outcome (Table 1).

From our experience, the following criteria are important to prevent loss of hard and soft tissues to achieve optimum aesthetics:

All attempts should be made to place an implant immediately after extraction and definitely not more than four weeks after extraction, to minimize resorption of the labial plate of bone.

Extraction should be carried out with minimal damage to bone and soft tissues. The use of microsurgical blades, periostomes and, finally, very thin luxators is highly recommended (Fig 2a-c).

Correct 3D placement of the implant should be achieved, especially in the bucco-lingual region, taking care not to touch the fragile buccal plate. It is not necessary to fill the complete socket labio-palatally with a large diameter implant; rather a space may be left labially, which can be grafted by autogenous or synthetic bone (Fig 3).

Table 1. Hurdles in placing implants in the pre-maxillary zone

● High incidence of missing labial plate of bone
● High potential loss of interdental papillae leading to black triangles
● Less than optimal bone quality

Implant should be tapered with a progressive thread design, i.e. the implant threads get progressively deeper towards the apical end engaging more bone in the soft spongy area of the apical region. This ensures primary stability even in a compromised bone. However, for implant stabilization, its crestal part should have shallower threads to prevent excessive stress in the dense cortical bone of the region.⁷⁻¹⁰

Implant should not have any polished collar and should be surface-treated (roughened) right up to its top. This allows bone to grow right up to the platform of the implant resulting in minimal bone loss due to remodeling (figs 4 and 5).

The implant abutment connection should be a conical-tapered one to prevent micro-movement and microleakage. This will help lead to stability of the peri-implant hard and soft tissue.

Implantation should be delayed, if the tooth to be extracted is infected and loss of the labial plate of bone is expected. After waiting for 3 weeks for the soft tissue closure, implant can be placed with guided bone regeneration along with a modified Maryland bridge (Fig 6a-f). To better explain the concepts for achieving optimum aesthetics, we here are providing two case reports.

Case report 1

A male, aged 62 years, reported with a fractured central incisor and requested to be rehabilitated urgently with a fixed restoration. It was decided to do an immediate implantation with a fixed provisional restoration on a final abutment. The 'ANKYLOS' implant system was selected for using in this patient due to its numerous advantages in immediate implantation and provisionalisation.

The tooth was extracted atraumatically as described

earlier. After preparation of the osteotomy as per the protocol of 'ANKYLOS', a 4.5 mm diameter and 14 mm long implant was motor driven into place (Fig 7a). The final ratcheting was done by hand to place the implant 3 mm away from the free gingival margin (Fig 7b). We achieved

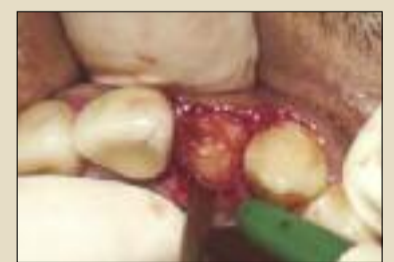
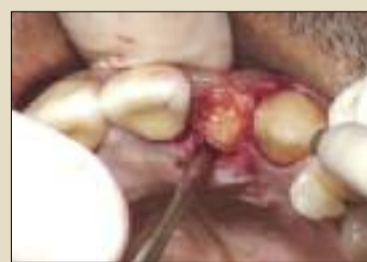
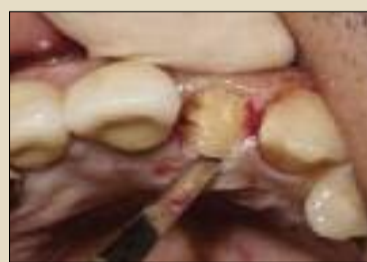Fig. 2a, b & c: Atraumatic extraction of the tooth starting with microsurgical no 15 blade followed by periostome in fig. 2b: and finally a thin luxator in fig. 2c. The periostomes and luxators should apply pressure on the mesio-distal surfaces and the palatal surfaces only. The microsurgical blade may be used to sever the periodontal ligament fibers on the labial aspect.

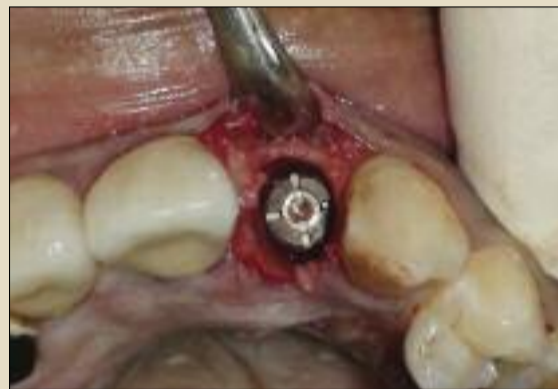

Fig. 5: Correct labio-palatal placement of the implant in the extraction socket with space of about 2-3mm on the labial aspect, which may be grafted with particulate synthetic bone like Algipore (Dentsply, Friadent Germany).

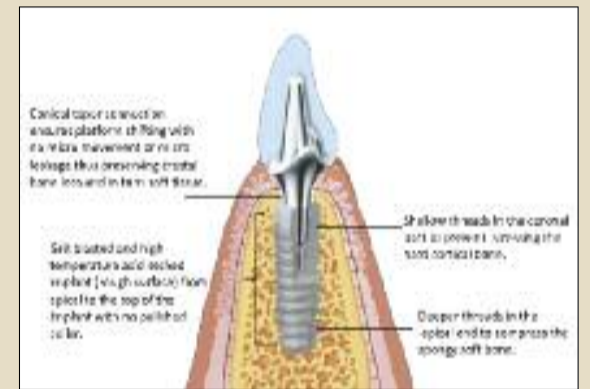


Fig. 4: Shows the unique 'ANKYLOS' implant (Dentsply Friadent, Germany) with progressive thread design and conical tapered connection.

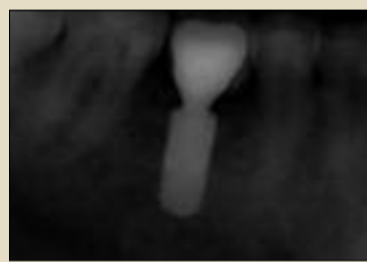

Fig. 5: Although the implant is placed sub-crestally, observe the excellent preservation of crestal the bone. Implant in service since last 2 years.

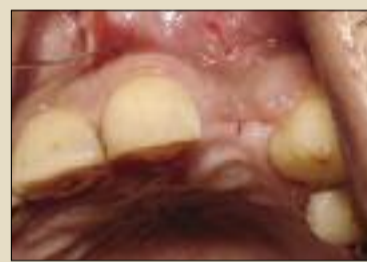

Fig. 6a: Healing of soft tissue after three weeks of extraction.

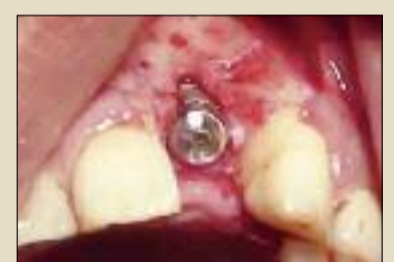

Fig. 6b: Buccal defect on labial aspect after the removal of cover screw and placement of sulcus former.

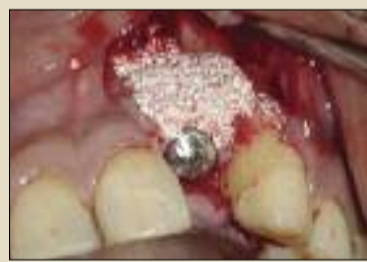

Fig. 6c: Grafting of the defect with mineralized red algae (Algipore, Dentsply Friadent).

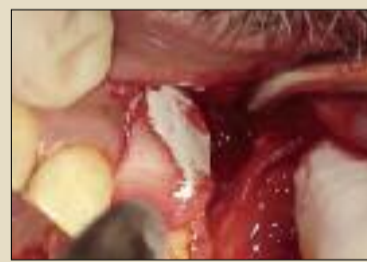

Fig. 6d: Covering of grafted bone with absorbable collagen membrane (BioGide, Geistlich, Switzerland).

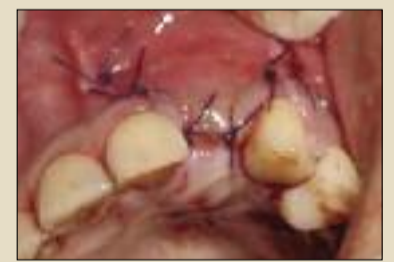

Fig. 6e: Excellent primary closure achieved due to waiting for three weeks after extraction.

good primary stability in the region of 35 Ncm and therefore we removed the cover screw and placed the final 'ANKYLOS' Balance Abutment tightening it only by hand pressure. The conical-tapered connection of the 'ANKYLOS' system can be friction-locked with very little

torque. An alginate impression was taken of the abutment and a crown was fabricated on the prepared cast using the unique shading system of the composite Ceram-X (Dentsply) to match the color of the adjacent lateral incisor (Fig 7c). After a period of 4 weeks to allow heal-

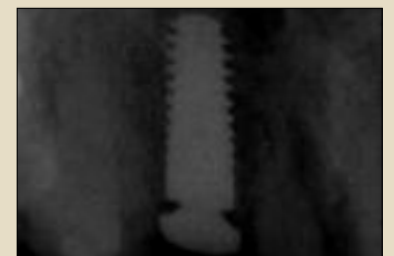

Fig. 6f: IOPA radiograph of the 'ANKYLOS' implant with sulcus former in place to further support the soft tissue.

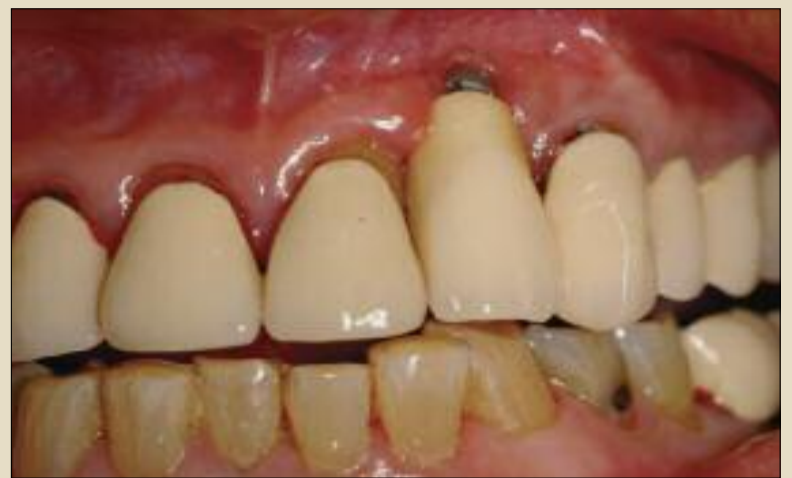

Fig. 1: Although this implant is surviving and is functional to the patient, aesthetically it is not a success due to the labial placement of the implant.