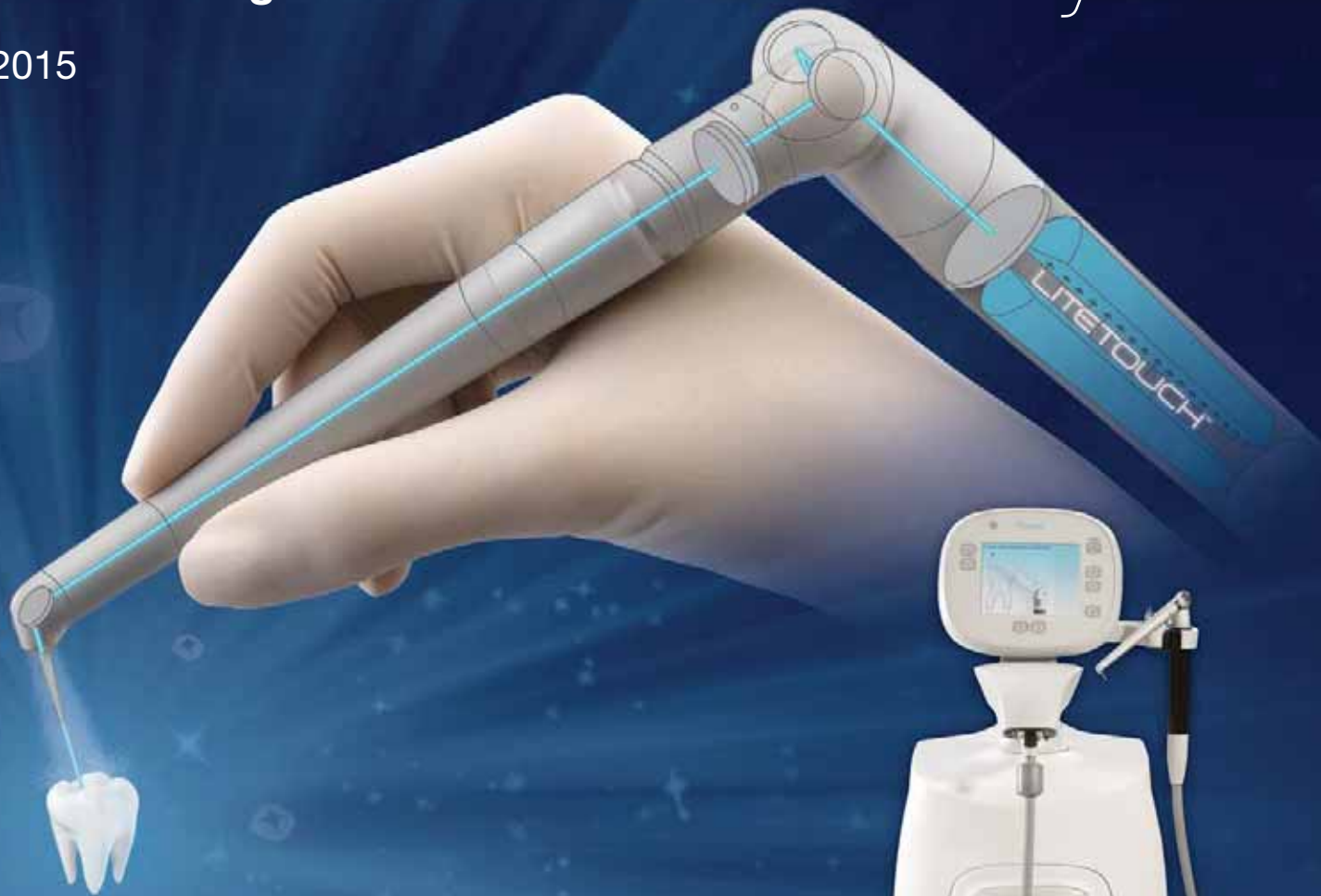

laser



international magazine of laser dentistry

3²⁰¹⁵



| **research**

Use of the Er:YAG laser for initial treatment of chronic periodontitis

| **case report**

Periimplantitis and Er:YAG laser

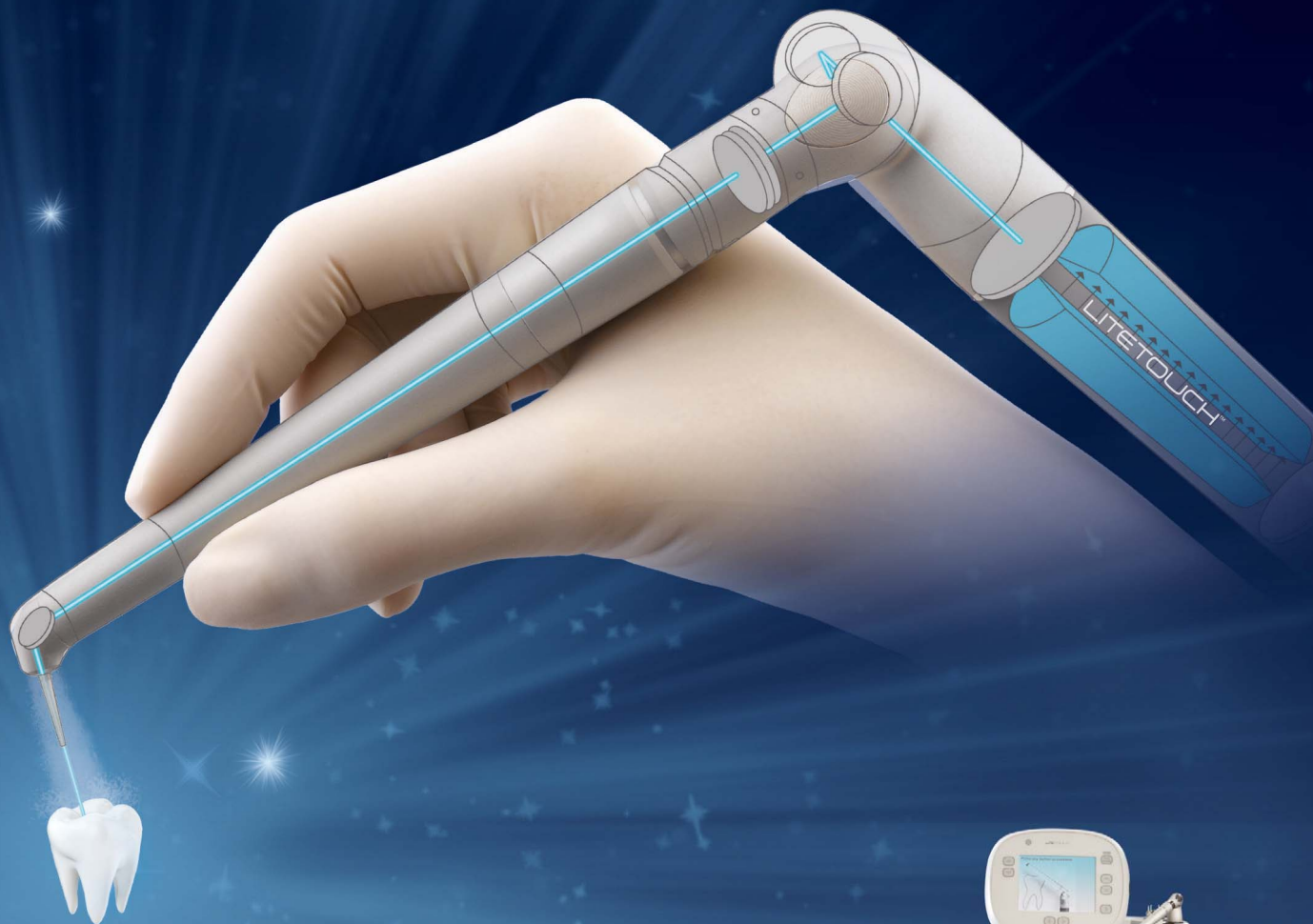| **industry**

Laser snoring and sleep apnoea reduction



Syneron™
DENTAL LASERS

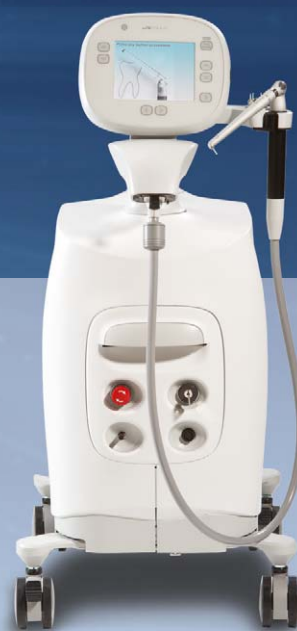*Express
your mastery*



LITETOUGH™

Er:YAG Laser-in-Handpiece

Dentists' Choice for Hard & Soft Tissue Procedures



LPB87413EN

To learn more about our innovative technology solutions,
contact: dental@syneron.com, www.synerondental.com



Dear colleagues,



Prof. Dr. Norbert Gutknecht
Editor-in-Chief

This year, after much time and effort, we have arranged a scientific program featuring a number of international experts for the annual congress of the Deutsche Gesellschaft für Laserzahnheilkunde (DGL), themed "Wavelengths". Furthermore, in response to repeated requests from our foreign colleagues, we have expanded the congress to include an international audience. In order to accommodate this change, we have scheduled the first congress day, 27 November, for international lectures which will be interpreted.

As you can see in our preliminary program, in addition to guest speakers such as Prof. Jens Malte Baron, a dermatologist from the RWTH Aachen University Hospital, Dr James Carroll, a specialist in low-level laser therapy from the UK, Dr Joshua Weintraub from Stevenson, USA, and Prof. Dr. Peter Rechmann from the University of San Francisco, USA, a substantial number of national and international lecturers will discuss the wide range of wavelengths for use in laser dentistry. In addition, short presentations will complement the program.

Without promising too much, the lectures will offer new insights into the mode of action of lasers concerning different tissue types and cell function.

At the DGL party on Saturday evening, certificates for the mastership course will be awarded to DGL and international students. Moreover, all of the major laser manufacturers will be exhibiting their products and offering workshops.

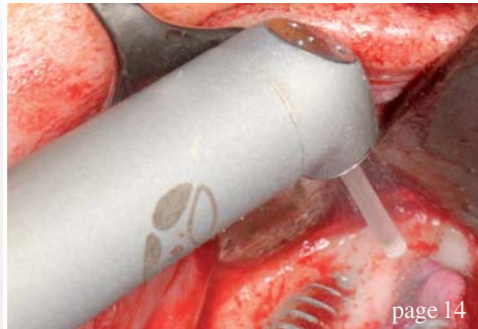It goes without saying that only through your participation at this year's international DGL conference can the association continue to achieve what distinguishes it: innovation, knowledge transfer, fellowship and friendship. Therefore, I would like to encourage all of you to not only participate in our congress in Berlin but also to warmly welcome our international guests to the event.

With warm regards,

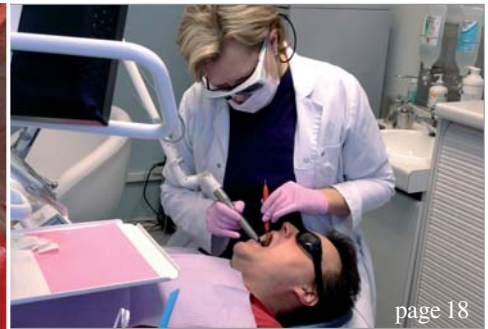Prof. Dr. Norbert Gutknecht
Editor-in-Chief



page 6



page 14



page 18

editorial

- 03 **Dear colleagues**
| Prof. Dr Norbert Gutknecht

research

- 06 **Use of the Er:YAG laser for initial treatment of chronic periodontitis**
| Prof. Ana Minovska *et al.*
- 12 **A simple vision test based on the speckle effect**
| Prof. Dr Axel Donges

case report

- 14 **Periimplantitis and Er:YAG laser**
| Dr Carole Leconte

industry report

- 18 **Laser snoring and sleep apnoea reduction**
| Dr Jaana Sippus
- 22 **Ablation of Dental Hard and Soft Tissue with 9.3 µm CO₂ Solea Laser**
| Dr Joshua P. Weintraub

practice management

- 28 **Eleven tips for success in your dental clinic—Part I**
| Dr Anna Maria Yiannikos

news

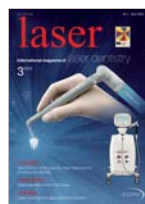- 26 **Manufacturer News international**
- 32 **News international**

DGL

- 35 **DGL – International**
| Prof. Dr. Norbert Gutknecht
- 36 **Abstracts zur 24. Jahrestagung der DGL in Berlin**
- 46 **News germany**

about the publisher

- 50 | imprint



Cover image courtesy of Syneron, www.synerondental.com



page 28



page 32



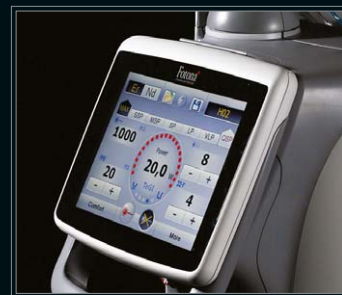page 46

The universe at your fingertips.

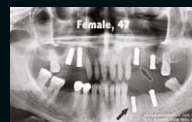TwinLight[®] Peri-implantitis Treatment

A simple and effective procedure that offers the power to treat peri-implantitis – an increasing threat to oral health.

- Minimally-invasive technique
- Fast regeneration/healing
- Reduced inflammatory response
- Highly effective treatment
- No antibiotics needed



Peri-implantitis treatment video

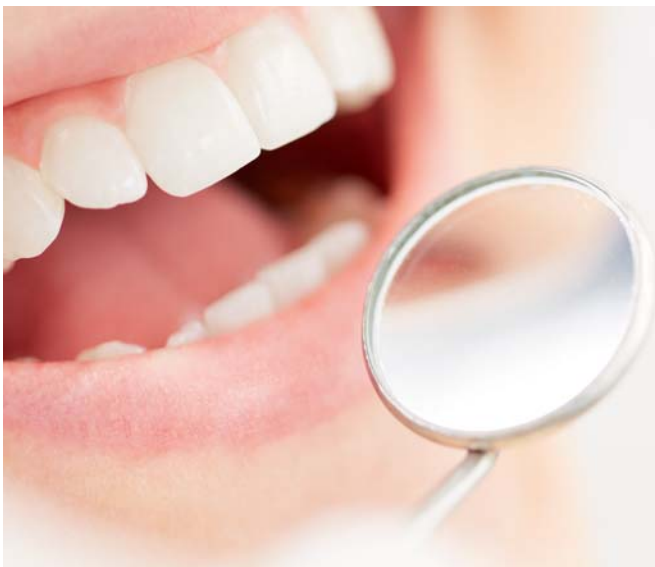

LightWalker[®]

www.lightwalkerlaser.com

Use of the **Er:YAG** laser for **initial treatment** of **chronic periodontitis**

Authors Prof. Ana Minovska, Macedonia; Dr Daniela Cvetanovska Stojceva, Macedonia; & Prof. Georgi Tomov, Bulgaria



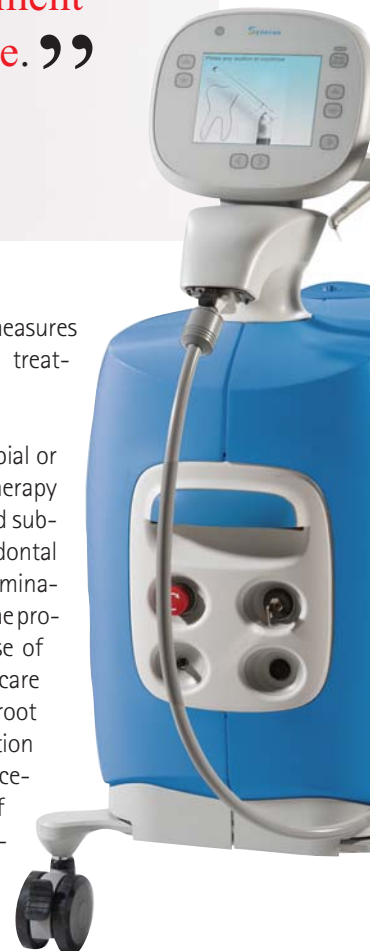“ **Periodontitis** denotes inflammatory **destruction** of the **periodontal ligament** and **supporting bone**. ”

Periodontitis denotes inflammatory destruction of the periodontal ligament and supporting bone. The course of periodontitis is characterised by intermittent exacerbations of the disease. Today, it is generally accepted that pathogenic bacterial plaque in the susceptible host triggers a complex inflammatory/immune response, which results in clinical inflammation and catabolic changes in the non-mineralised connective tissue and bone,¹ followed by progressive tissue destruction and pocket formation.

Based on these findings, strategies for the effective treatment of periodontal disease aim to arrest the inflammatory disease process by removal of the supra- and subgingival biofilm and to establish a local environment and microflora compatible with periodontal health. Reduction of probing pocket depth, maintenance or improvement of clinical attachment levels, and reduction in bleeding on probing are the

most common outcome measures used to determine whether treatment is successful.

Phase 1 causal, antimicrobial or non-surgical periodontal therapy refers to the initial supra- and subgingival treatment of periodontal disease.² After a thorough examination and accurate diagnosis, the protocol usually includes the use of antimicrobial agents, home-care instructions, and scaling and root planing, followed by evaluation of the need for surgical procedures. The gold standard of successful treatment is defined as maintenance or gain of clinical attachment.³



As lasers can achieve excellent tissue ablation with strong bactericidal and detoxification effects, they are one of the most promising new technological modalities for Phase 1 therapy.⁴ Over the last two decades, the use of different dental lasers has been included in the above regimen. Laser light is a unique, non-ionising form of electromagnetic radiation that can be employed as a controlled source for tissue cutting or ablation, depending on specific parameters. There are many different types of lasers, and each produces a specific wavelength of light.

Throughout the last decades, clinicians involved in the treatment of periodontitis have used different dental laser wavelengths. Each wavelength has a somewhat different effect on the dental and periodontal structures, owing to the specific absorption of that laser energy by the tissue. Of all lasers emitting in the near- and mid-infrared spectral range, erbium lasers are unique in that they are the only lasers that can cut both hard and soft tissue with minimal heat-related side-effects. It has been suggested that the erbium wavelengths present the broadest range of application for clinical dentistry and are likely the most suitable lasers for periodontal therapy.⁵⁻⁸

During Er:YAG laser irradiation, the laser energy is absorbed selectively by water molecules in biological tissue, causing evaporation of water and organic components, and thus resulting in thermal effects due to the heat generated by photothermal evaporation. Moreover, in hard-tissue procedures, the water vapour production induces an increase in internal pressure within the tissue, resulting in explosive expansion called "micro-explosion".⁹ These dynamic effects cause mechanical tissue collapse, resulting in thermomechanical or photomechanical ablation.¹⁰ This phenomenon has also been referred to as "water-mediated explosive ablation".^{11,12}

Laser treatment has the potential advantage of accomplishing soft-tissue wall treatment effectively along with root surface debridement. Aoki et al.¹³ and Keller and Hibst¹⁴ began to investigate the application of the Er:YAG laser to periodontal hard-tissue procedures, such as dental calculus removal and decontamination of the diseased root surface. A number of basic studies on Er:YAG laser application to root surface treatment have been reported in clinical studies on non-surgical pocket therapy using laser.¹⁵⁻¹⁷

Controlled clinical trials and case report studies have also indicated that non-surgical periodontal treatment with the Er:YAG laser leads to significant gain of clinical attachment.¹⁸⁻²⁰ Preliminary clinical results have also

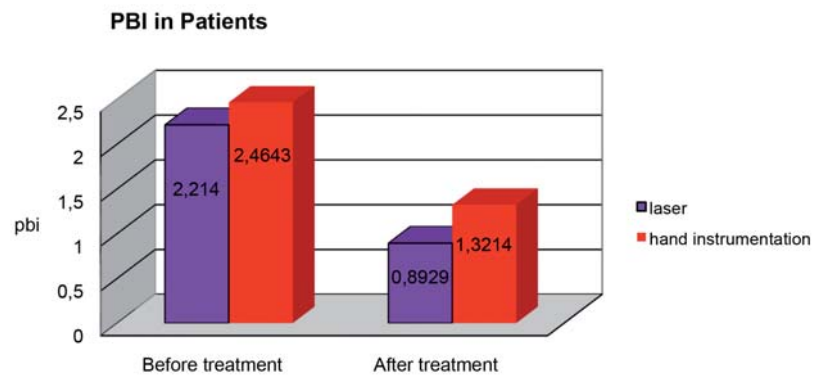


Fig. 1

indicated that this minimally invasive method may allow instrumentation of very deep pockets without leading to major trauma of the hard and soft tissue, that is, removal of tooth substance and an increase in gingival recession.^{17,19}

Figs. 1-5 Classical treatment versus laser treatment; results for PBI, PPD, CAL, GR and BL after three months.

The second phase of initial therapy entails closed debridement of periodontal pockets: debridement of root surfaces of plaque and calculus, detoxification of the root surfaces, root planing and gingival curettage. The removal of pocket epithelium and a portion of infected connective tissue has been a matter of debate,²¹ but current research results clearly demonstrate the possibility of bacterial colonisation of pocket epithelium and connective tissue.²²⁻²⁴

In our study, we compared gingival curettage and scaling and root planing using an Er:YAG laser versus conventional mechanical hand instrumentation according to clinical indicators of successful treatment and/or periodontal stability after non-surgical therapy of patients with chronic periodontal disease.

Materials and methods

Patient selection

After undergoing a comprehensive periodontal examination, 20 patients older than 35 years with

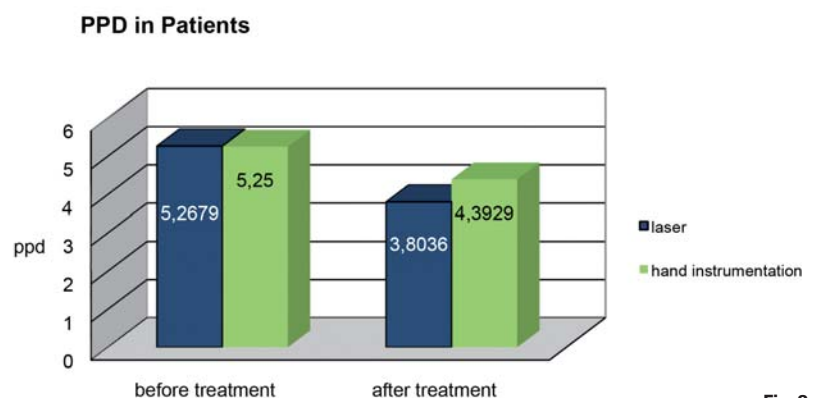


Fig. 2



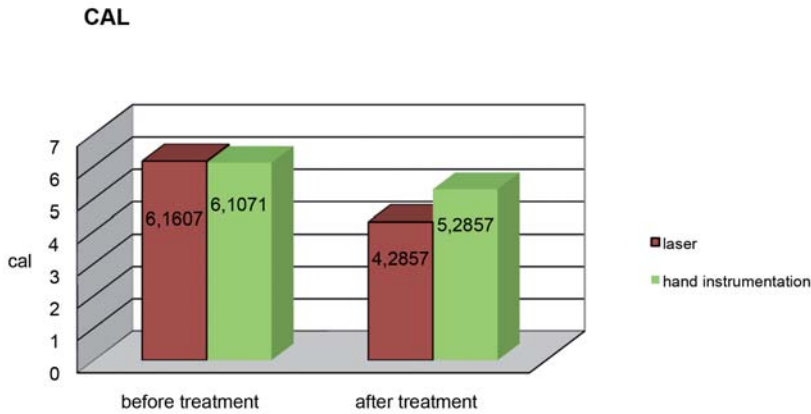


Fig. 3

generalised chronic periodontitis²⁵ were included in the study and gave their written informed consent. The study was conducted in accordance with the Declaration of Helsinki of 1975 as revised in 1983. The patient inclusion criteria were as follows: non-smokers, no periodontal treatment within the last 12 months, no systemic disease that could influence the outcome of therapy and no use of antibiotics prior to treatment.

Study design

For the purpose of the study, a split-mouth design was chosen. A total of 30 maxillary and 20 mandibular pairs of contralateral single- and multi-rooted teeth were included. Each tooth of each contralateral pair had to exhibit attachment loss of ≥ 5 mm at one aspect of the tooth. In each contralateral pair, one tooth was treated with closed curettage,²⁶ that is, gingival curettage followed by scaling and root planing using ultrasonic and hand instruments, while the other tooth was treated with laser-assisted gingival curettage, followed by laser-assisted scaling and root planing using an Er:YAG laser.

Clinical measurements

A meaningful comparison between various clinical studies or between laser and conventional therapy is difficult at best and likely impossible at the present. There are several reasons for this, including different laser wavelengths, wide variations in laser parameters, insufficient reporting of parameters

(which, in turn, does not allow calculation of energy density), differences in experimental design, lack of proper controls, differences in severity of disease and treatment protocol, and measurement of different clinical end-points.

Taking this into consideration, the protocol for clinical measurements was established as follows. The clinical parameters were assessed at the baseline visit and three months²⁷⁻²⁹ after therapy. The presence of dental plaque was determined according to Silness and L oe's plaque index (PI; 1964)³⁰ and the degree of inflammation was assessed using the papillary bleeding index (PBI) by Saxer and M uhlemann (1975).³¹ Bleeding was tested by careful insertion of a blunt probe to the bottom of the pocket and gentle movement laterally along the pocket wall. After 30 seconds, the intensity of bleeding was scored in four grades and recorded:

- (a) Grade 1: a single bleeding point
- (b) Grade 2: a fine line of blood or several bleeding points became visible at the gingival margin
- (c) Grade 3: the interdental space filled with blood to some extent
- (d) Grade 4: profuse bleeding.

Immediately after probing, the clinical attachment level (CAL)^{32, 33} was measured from the cemento-enamel junction to the point at which the probe tip stopped (PD fibres). Gingival recession (GR) was detected by measuring the distance from the cemento-enamel junction to the gingival margin. The periodontal probing depth (PPD)^{34, 35} or pocket depth was measured from the gingival margin to the point at which the probe tip stopped. The extent of bone loss was detected using transgingival probing³⁶ under local anaesthesia, confirmed and supported by direct digital (filmless) radiographs.³⁷

Oral hygiene programme

The oral hygiene programme was followed for four weeks prior to treatment, and consisted of supragingival tooth cleaning with an ultrasonic device, creation of conditions to enhance oral hygiene (if needed) and reinforcement of optimal personal oral hygiene³⁸ at two and four appointments. A PI score of < 1 was chosen as a criterion for good oral hygiene.³⁹

Treatment

In the control group, closed curettage was performed by scaling (with an ultrasonic device) and root planing (using Gracey curettes; Hu-Friedy),⁴⁰ gingival curettage,^{41, 42} and removal of the pocket epithelium and infiltrated subepithelial connective tissue using a complete set of Gracey curettes (Hu-Friedy).

GINGIVAL RESSION

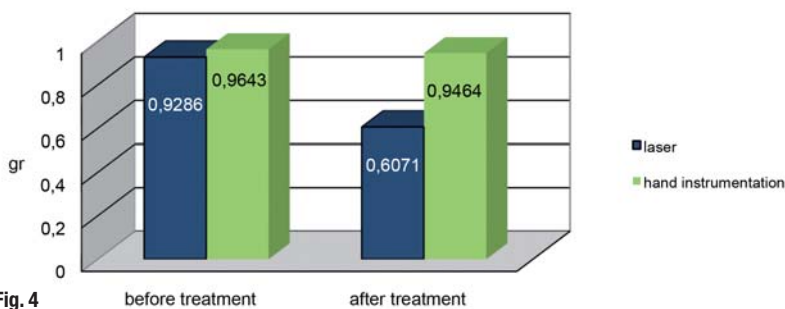


Fig. 4

In the test group, closed curettage was performed with the LiteTouch laser (Syneron Dental Lasers), which has a direct delivery system and the active medium is built into the handpiece base. For the purpose of the study, a regular handpiece and external water irrigation were used. Clinical parameters for low-energy settings (50 mJ–100 mJ) to improve inflammatory conditions by reducing the bacterial load and inflammatory tissue in the periodontal pocket were utilised.

Scaling and root planing were performed on the root surface and the laser was kept angled with an inclination of the fibre tip of 10–15 degrees to the vertical axis of the tooth. Instrumentation was performed from the coronal to the apical in parallel paths. The laser settings were as follows: hard tissue, chisel tip (0.5 mm × 1.4 mm) × 17 mm, water spray level 6, 100 mJ, 15 Hz, energy density of about 256 mJ/mm², power density of about 3.85 W/mm², and pulse width of about 170 ms. The instrumentation with both hand instruments and laser was performed until the operator felt that the root surfaces had been adequately debrided and planed. The laser-assisted periodontal pocket debridement (gingival curettage) was performed on the soft tissue with the laser kept at a 20-degree angle between the laser tip and the vertical axis of the tissue with parallel movement along the pocket wall, starting from the bottom of the pocket. The laser parameters were as follows: soft tissue, non-contact mode (performed at a distance of 1–2 mm between the tip end and the tissue), 50 mJ, 30 Hz, tip of 0.6 mm × 17 mm, energy density of about 178 mJ/mm², power density of about 5.35 W/mm², and pulse width of about 290 ms.

Statistical analysis

The difference between the two groups (test and control) over the study period was analysed using the Mann–Whitney U test and the Wilcoxon signed-rank test.

BONE LEVEL

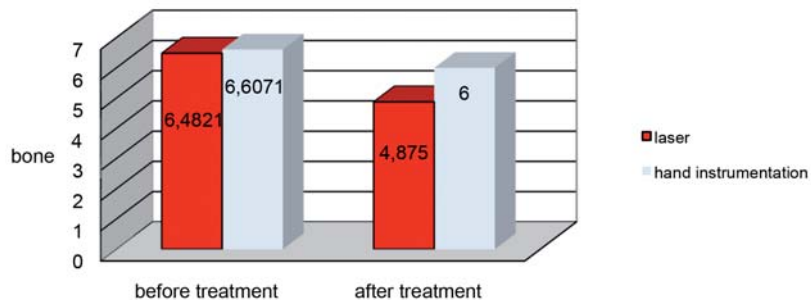


Fig. 5

Results

Clinical data was collected at baseline and three months after treatment. PI, PBI, PPD, CAL, GR and bone level (BL) were measured and analysed. There were no statistically significant differences in the data at baseline between the two groups in any of the examined parameters according to the Mann–Whitney U test ($p > 0.05$).

After three months, an iterative comparison of the data was performed, again using the Mann–Whitney U test. The results showed highly statistically significant differences in PBI, PPD, CAL, GR and BL between patients treated classically with mechanical debridement and those treated with laser ($p < 0.01$; Figs. 1–5). For PI, there was no statistically significant difference between the tested groups after three months ($p > 0.05$; Fig. 6).

Furthermore, the Wilcoxon signed-rank test was used to analyse the data obtained for the laser-treated group at baseline and after three months. The results showed highly statistically significant differences for all parameters ($p < 0.01$). The same test (Wilcoxon signed-rank test) was used to analyse

Difference -before and after treatment

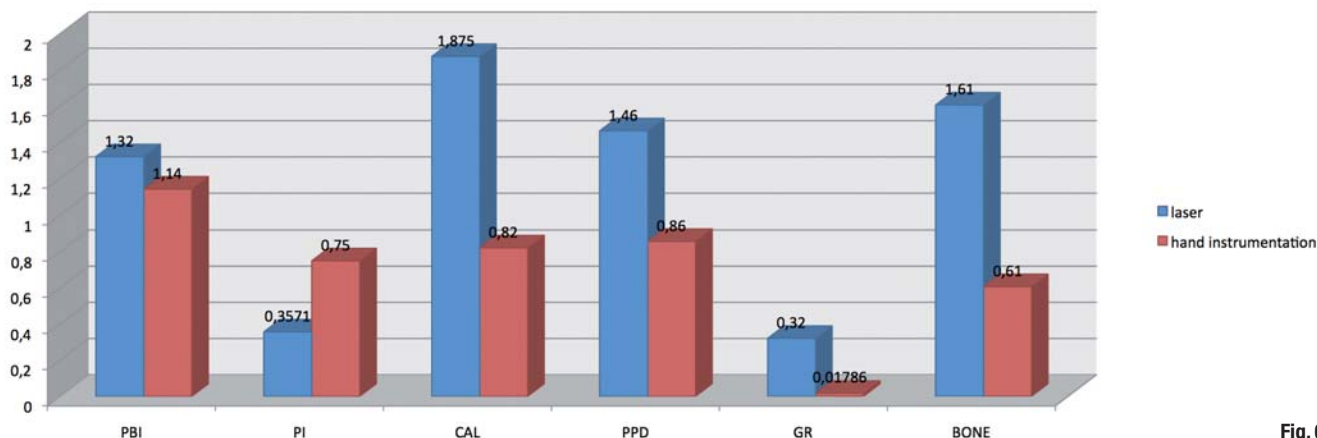


Fig. 6