

# roots

international magazine of endodontology

4<sup>2011</sup>

| **case report**

Minimally invasive crown lengthening

| **practice management**

The passive income practice


| **meetings**

Ten years of DGEndo and the launch of DGET





Simplicity is the real innovation



wave•one™

- Only one sterile NiTi instrument per root canal in most cases
- Decreases the global shaping time by up to 40%
- Reciprocating technology respecting the root canal anatomy
- Single use as new standard of care



# Dear Reader,

**The single most important development** that was a giant leap for endodontics is micro-computed tomography, which gives us a 3-D view. Without this technology, the basis for many endodontic procedures was just empirical, like enlarging the root canal three sizes beyond the first file that binds during hand instrumentation, or arbitrarily deciding the final apical size with tapered rotary use.

Prof Marco Versiani's root-canal anatomy project on micro-CT study guide has demystified many old concepts. Now we know that all root canals are curved, apical diameters are not as small as perceived, and root canals do not have large tapers.

Regenerative endodontics, though in the infant stage, can hold significant implications for the management of necrotic immature teeth. These treatment protocols can result in radiographic and clinical evidence of healing and subsequent root development. Tyler Lovelace *et al.* have demonstrated that the evoked-bleeding step in regenerative procedures triggers a significant accumulation of undifferentiated stem cells in the canal space, leading to the regeneration of pulpal tissues. Future developments may see wider application of these tissue-engineering principles, revolutionising the field of endodontics.

The use of lasers in endodontics may be common procedure soon with a number of applications in access preparation, root-canal shaping, and decontamination of the root-canal system. The improved technology has introduced endodontic fibres and tips of a calibre and flexibility that permit insertion up to 1 mm from the apex. Laterally emitting conical fibre tips were found to be safe under defined conditions for intra-canal irradiation without harmful thermal effects on the periodontal apparatus.

The EndoVac irrigation system (SybronEndo) is one of the best things that has happened to endodontics in recent years. While sodium hypochlorite significantly eliminates the biofilm associated with endodontic infections, it can cause catastrophic tissue damage when extruded. With EndoVac, fortunately, it can now be safely delivered to full working length. Research shows that EndoVac usage can result in a significant reduction of post-operative pain levels in comparison with conventional needle irrigation.

Micro-CT studies show that the apical thirds are not cleaned with tapered systems of small tip size. In addition, they showed that instruments with a flat widened tip determine apical diameter better than round tapered instruments. The coming years are bound to see an increased acceptance of LightSpeed LSX instruments (SybronEndo) to obtain biologically optimal preparations.

At a time when dental professionals have a choice between root-canal treatment and implant placement after extraction, it is heart-warming to see that recent developments in endodontics, if incorporated into the surgery, can maintain the tooth in a functional state for many years.

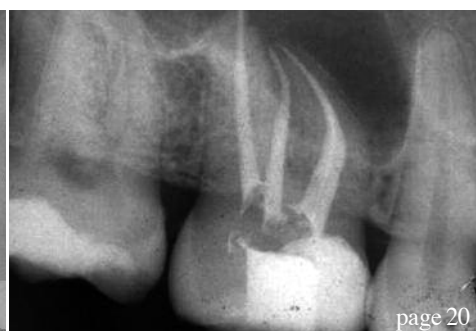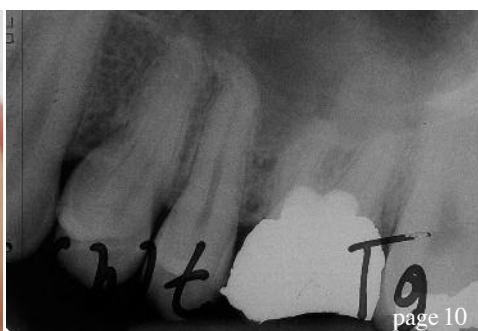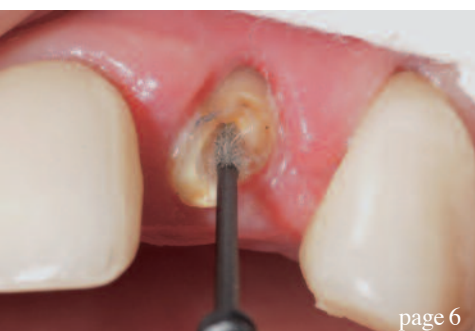Yours faithfully,



Prof Beena Rani Goel  
President of the International Academy for Rotary Endodontics



Prof Beena Rani Goel



## editorial

- 03 **Dear Reader**  
| Prof Beena Rani Goel, Guest Editor

## case report

- 06 **Minimally invasive crown lengthening as an alternative to implant treatment**  
| Prof Marcel Wainwright

## research

- 10 **Vital amputation** of permanent teeth  
| Dr Robert Teeuwen

## practice management

- 18 **The passive income** practice  
| Dr Phillip Palmer

## opinion

- 20 **Critical thinking:**  
**The missing link in endodontic education**  
| Dr Barry Lee Musikant
- 24 **Rubber dam hazards?**  
| Dr Kenneth S. Serota

## news

- 26 **Dental X-rays** can predict fractures

## feature

- 28 An interview with **Dr Emanuele Ambu**

## industry news

- 32 **FKG Dentaire** introduces *iRaCe* and *Scout-RaCe*  
| FKG


## meetings

- 34 **Dental symposium at home? AMED goes virtual**  
| Dr Terrell F. Pannkuk
- 36 **Ten years of DGEndo** and the launch of **DGET**  
| Oscar von Stetten

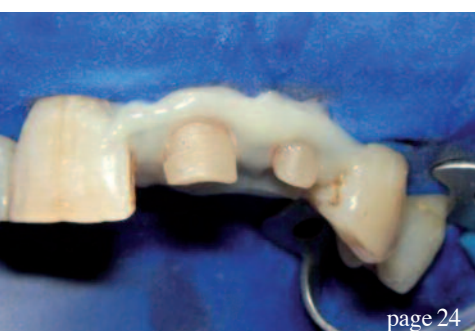
- 40 **International Events**

## about the publisher

- 41 | submission guidelines  
42 | imprint



Cover image courtesy of  
Produits Dentaires SA.



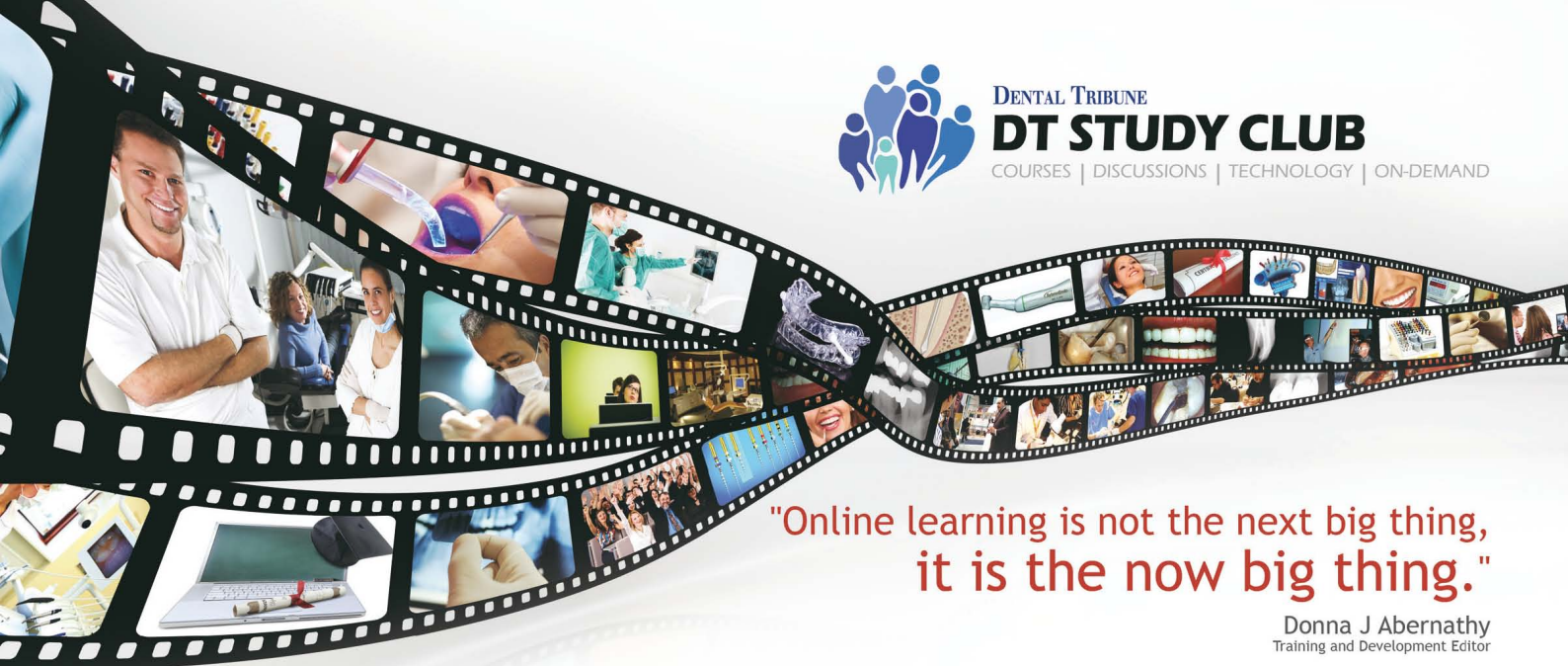



DENTAL TRIBUNE

**DT STUDY CLUB**

COURSES | DISCUSSIONS | TECHNOLOGY | ON-DEMAND



**"Online learning is not the next big thing,  
it is the now big thing."**

Donna J Abernathy  
Training and Development Editor

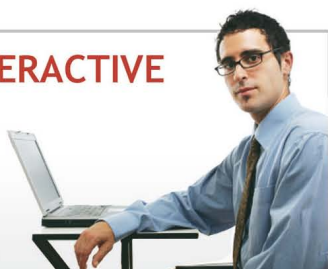## DTSC - COURSES, COMMUNITY, TECHNOLOGY, ON-DEMAND

The DT Study Club makes all of this is possible from the comfort of your own computer and without travel expenses. In other words, welcome to the community!

The purpose of this study club is to provide practitioners like yourself an opportunity to learn and network with like-minded colleagues in a friendly, non-threatening environment. We encourage you to take advantage of Dental Tribune's global outreach to access a variety of fresh perspectives and cultures, enhancing your educational mix.

### 24/7 LIVE AND INTERACTIVE ONLINE COURSES

Fulfill your yearly CE requirements with our growing list of archived ADA CERP approved courses.



### DISCUSSION FORUMS

focused on helping today's practitioners to stay up to date. Networking possibilities that go beyond borders to create a truly Global Dental Village



### VIDEO REVIEWS OF PRODUCTS

Our opinion leaders unveil new products, services, and give you their first impressions of the industry's hottest topics.



### PEER REVIEWED CASE STUDIES

Upload, comment, participate. We encourage you to share your cases for review with like-minded practitioners.



**REGISTER FOR FREE ON [WWW.DTSTUDYCLUB.COM](http://WWW.DTSTUDYCLUB.COM)**

**CONTESTS WITH CHANCES TO WIN FREE TUITION FOR ADA/CERP C.E. ACCREDITED WEBINARS**

SPONSORSHIP AND SPEAKING INQUIRIES:

JULIA WEHKAMP, [J.WEHKAMP@DTSTUDYCLUB.COM](mailto:J.WEHKAMP@DTSTUDYCLUB.COM), (416) 907-9836.

**ADACERP**  
CONTINUING EDUCATION RECOGNITION PROGRAM



PRACTICE MANAGEMENT



GENERAL DENTISTRY



COSMETICS



ENDODONTICS



IMPLANTOLOGY



PERIODONTICS



ORTHODONTICS



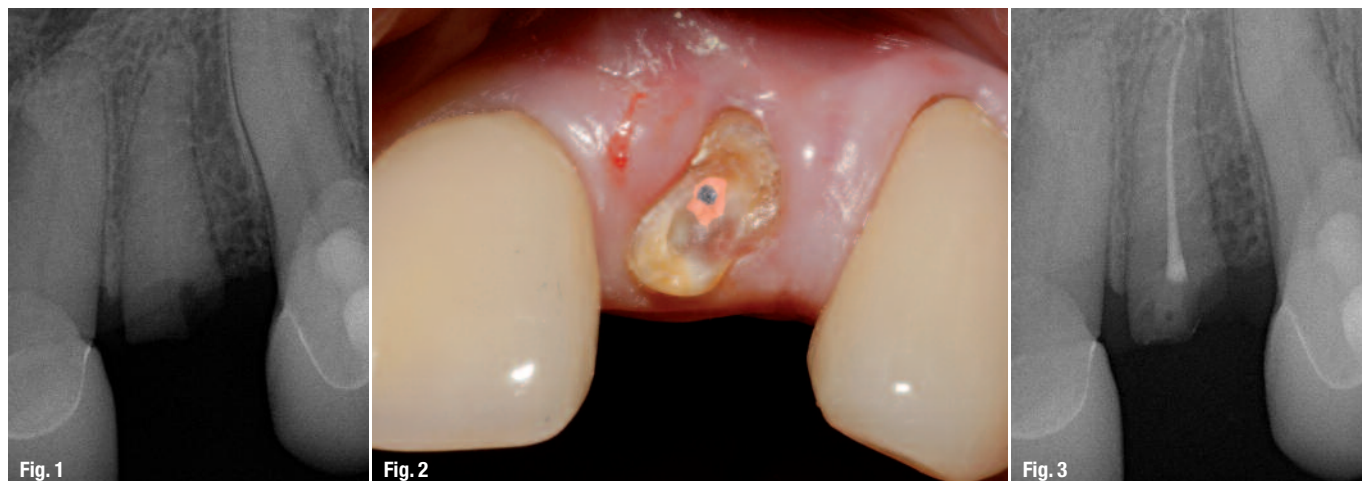
DENTAL HYGIENE

**[WWW.DTSTUDYCLUB.COM](http://WWW.DTSTUDYCLUB.COM)**



# Minimally invasive crown lengthening as an **alternative to implant treatment**

**Author\_** Prof Marcel Wainwright, Germany



**Fig. 1\_** Single-tooth radiograph showing the fractured tooth #22.

**Fig. 2\_** Thermoplastic root filling in tooth #22.

**Fig. 3\_** Radiograph of the orthograde root filling, found to be *leige artis*.

**\_Crown fractures frequently force** the treatment provider to make a clear-cut treatment choice between tooth preservation and dental implant treatment. Speakers at implantological congresses tend to present impressive implant/prosthetic solutions for anterior fracture cases, to the point where the audience could be tempted to believe that this was the only appropriate treatment alternative. The following case report documents a tooth preservation option that is simple to perform, minimally invasive and successful.

## **\_Case report**

A 66-year-old male patient presented at our office with a fractured upper left lateral incisor (tooth #22). The clinical crown of this tooth had fractured in the marginal region, with the pulp of the tooth slightly exposed in one location; the pulp tissue vitality test showed a weak positive result. The patient was completely free of pain symptoms. There was no root mobility. Available treatment options were discussed with the patient based on a single-tooth radiograph (Fig. 1). The neighbouring teeth #21 and 23 had been

restored with all-ceramic crowns two years previously. However, a three-unit fixed prosthetic denture was rejected by the patient, as was surgical treatment with immediate implant placement following extraction.

Conservative tooth preservation was therefore the treatment of choice for patient and treatment provider alike. The patient was informed that tooth preservation could only be successful if the required orthograde root-canal instrumentation was possible, the tooth was symptom free and biological width could be restored prior to the fabrication of a crown restoration. If these requirements turned out not to be met, an implant/prosthetic solution would have to be resorted to as an alternative.

## **Treatment sequence**

Following extensive patient education and pre-therapeutic discourse, the patient received local anaesthesia, and tooth #22 was instrumented. This was initially difficult, as the root canal turned out to be slightly obturated. Following instrumentation



to ISO 20, the tooth was prepared for a root filling. Instrumentation to more than ISO 20 did not appear advisable, as the reduced diameter of tooth #22 already constituted an increased fracture hazard during preparation of the endodontic post or in the presence of lateral forces. At the same visit, an ortho-grade endodontic filling was placed using a thermo-plastic restorative technique (Thermafil; DENTSPLY DeTrey) and Sealapex (SybronEndo; Fig. 2). The control radiograph showed that the root-canal filling had been placed *lege artis* (Fig. 3).

Surgical crown lengthening was planned for four weeks later. Like all surgical interventions at our clinic, this crown lengthening was performed using ultrasonic surgical instruments (Acteon). In this protocol, the surgeon employs a surgical kit containing multiple calibrated diamond instruments (Fig. 4). A minimal circumferential incision was performed under local anaesthesia, completely dispensing with extensive flap elevation procedures or relieving incisions. The marginal bone was prepared approximately 2 mm farther apically to provide sufficient biological width for a subsequent crown (Berglundh 1992). The use of ultrasonic surgical instruments allows the surgeon to proceed quickly while protecting the tissue, as these instruments help reduce the risk of iatrogenic damage to the root dentine, a risk that is elevated when using conventional rotary instruments (Fig. 5). The site was sutured closed using a synthetic monofilament thread (Trofile 8-0, Stoma; Fig. 6). Microsurgical suturing is indispensable in the anterior region. If it is neglected, this will result in tissue recession and impaired aesthetics.

The sutures were removed one week later. Wound healing was uneventful, and the patient was completely free of pain and other symptoms throughout the entire treatment. After an additional week, a post-and-core build-up was performed using the Fibrapost and Sealacore system (Produits Dentaires; Fig. 7). The root canal was prepared with reamers, which are available in four different diameters (Fig. 8). The option to use the depth stop to pre-calibrate the reamer to the desired length was helpful, not least



Fig. 4

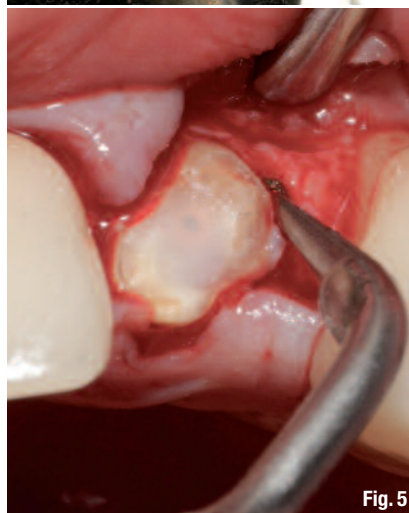

Fig. 5

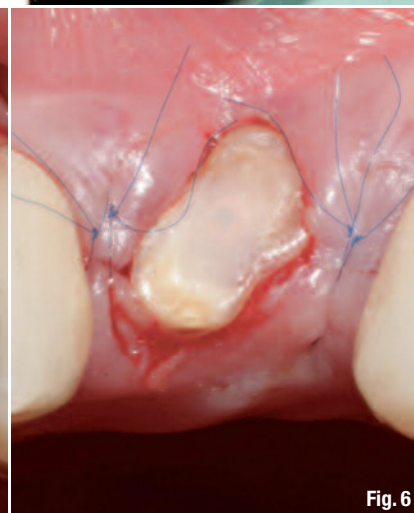


Fig. 6

as a precaution against excessive preparation depths (Figs. 9 & 10).

The root canal was prepared under copious irrigation and conditioned with a self-etching bonding system (Sealacore; Fig. 11). The UDMA-based resin cement (Sealacore) was introduced into the root canal with a syringe and application tip (Fig. 12). The Fibrapost is a fibreglass-reinforced resin endodontic post (Fig. 13) with retentive grooves. Our clinic uses metal-free endodontic post systems exclusively, as their biomechanical properties are clearly superior to those

**Fig. 4** Crown lengthening kit (Acteon).

**Fig. 5** Ultrasonic crown lengthening of tooth #22 using minimally invasive incisions.

**Fig. 6** Microsurgical 8-0 suture.

**Fig. 7** Fibrapost and Sealacore system.

**Fig. 8** Endodontic reamers.

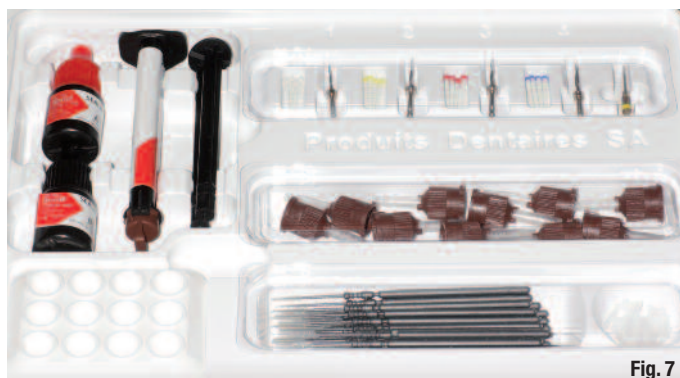

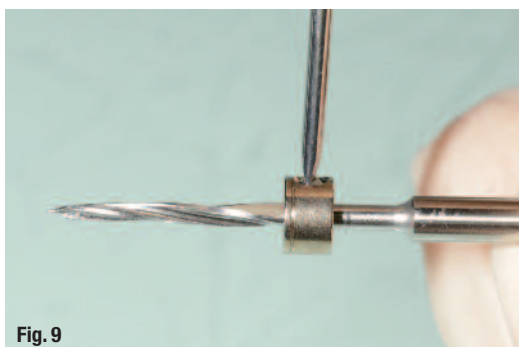
Fig. 7

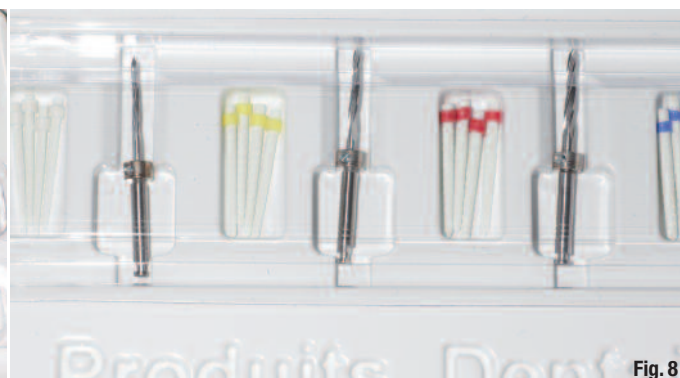
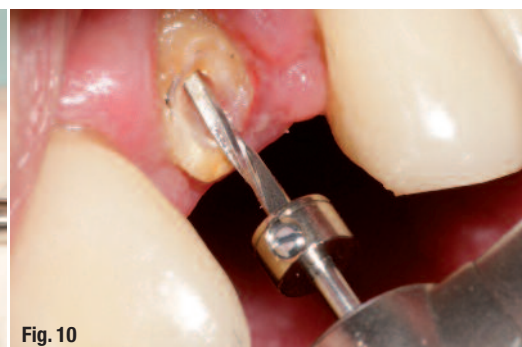
Fig. 8

**Fig. 9**\_Defining preparation depth using the adjustable stop.

**Fig. 10**\_Endodontic preparation using a reamer.

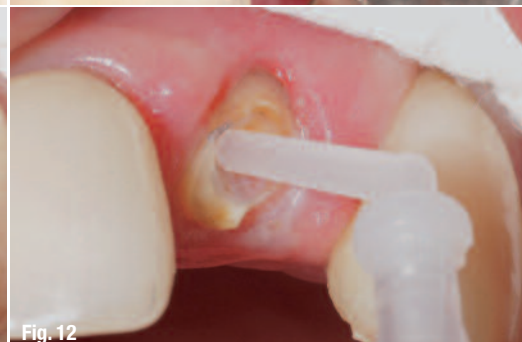
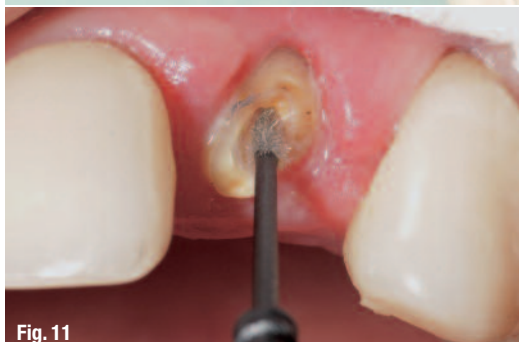
**Fig. 9**

**Fig. 10**

**Fig. 11**\_Conditioning the lumen of the root canal for accepting the endodontic post.

**Fig. 12**\_Applying the resin cement.



**Fig. 11**

**Fig. 12**

of metal posts. One important aspect is the absorption of the vertical lateral masticatory forces, which is better for the resin posts than for the metal posts because the former have material characteristics resembling those of natural dentine. In addition, the optical properties of the system (translucency, transparency) facilitate highly aesthetic anterior solutions while eliminating the risk of corrosive discolouration.

Following core shaping and preparation (Fig. 14), a polyether impression was taken for an all-ceramic crown (e.max, Ivoclar Vivadent). The definitive crown was delivered a week after tooth preparation and cemented with a dual-curing self-adhesive cement (RelyX Unicem, 3M ESPE; Fig. 15).

**Fig. 13**\_Fibrapost with retention groups.

**Fig. 14**\_Core placement and preparation.

**Fig. 15**\_All-ceramic crown *in situ*. Note the healthy and complete papillae and periodontal tissues.

## \_Summary

When the clinical crown of a tooth is lost due to fracture, surgical crown lengthening and tooth restoration based on a post and core is a viable alter-

native to implant/prosthetic treatment, provided that the tooth is free of pain, that the preconditions for endodontic treatment are met, and that the root is stable. Today's post-and-core systems are expected to be metal free and to offer easy handling and aesthetic long-term results. Our experience with the Fibrapost and Sealacore system has been positive throughout; they have produced excellent results and suit our procedures well.

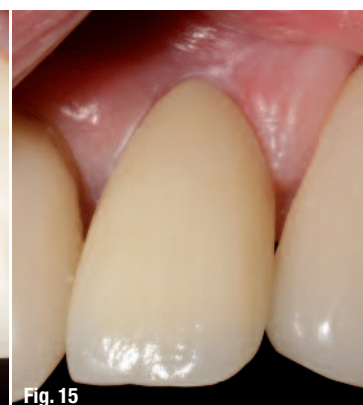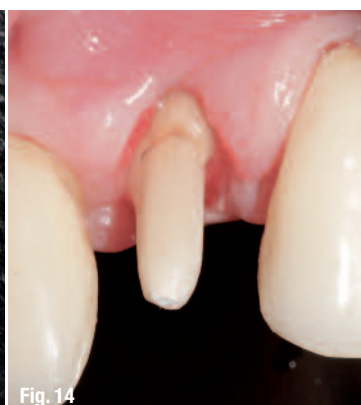## \_contact

## roots

### Prof Marcel Wainwright

Dental Specialists and White Lounge Kaiserswerth  
Kaiserswerther Markt 25–27  
40489 Düsseldorf  
Germany

[www.dentalspecialists.de](http://www.dentalspecialists.de)



**Fig. 13**

**Fig. 14**

**Fig. 15**



# Dental Tribune for iPad – Your weekly news selection

Our editors select the best articles and videos from around the world for you every week. Create your personal edition in your preferred language.

[ipad.dental-tribune.com](http://ipad.dental-tribune.com)

