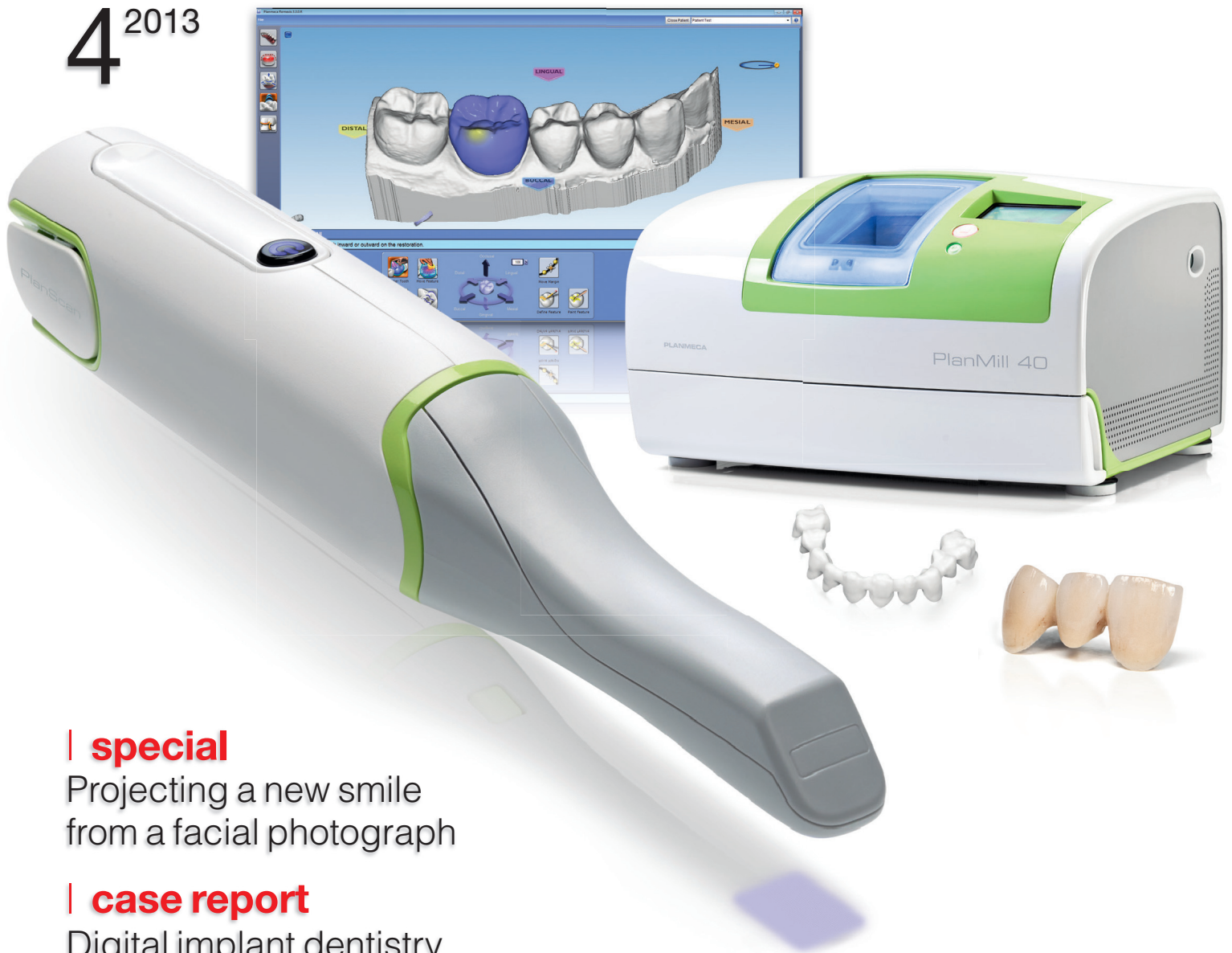

# CAD/CAM

international magazine of digital dentistry

4<sup>2013</sup>



**| special**

Projecting a new smile from a facial photograph

**| case report**

Digital implant dentistry —a workflow in five steps

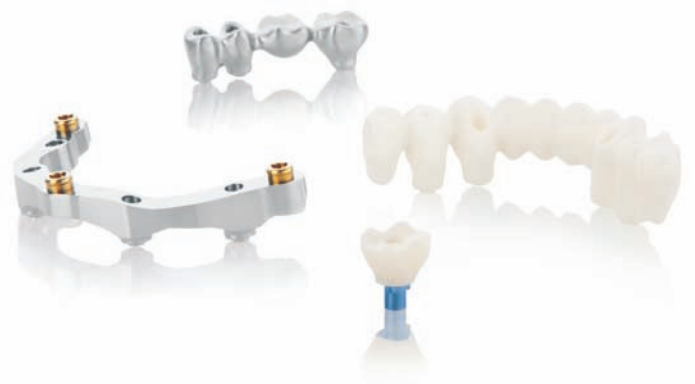**| industry report**

Diode laser application optimises the clinical outcomes of digital workflow



GMT 32583 GE 307 © Nobel Biocare Services AG, 2013. All rights reserved. Nobel Biocare, the Nobel Biocare logotype and all other trademarks are, if nothing else is stated or is evident from the context, in a certain case, trademarks of Nobel Biocare. Product images are not necessarily to scale. Disclaimer: Some products may not be regulatory cleared/released for sale in all markets. Please contact the local Nobel Biocare sales office for current product assortment and availability.

Gain direct access to unrivaled products.




Be more efficient in your work with the new NobelProcera 2G Scanner. Ultimate precision enables you to process even advanced cases with confidence.

Learn more  
[nobelbiocare.com/2G](http://nobelbiocare.com/2G)



# Digital dentistry, our future?



Dr Scott D. Ganz

**What does the term "digital dentistry" mean for the future of dentistry today?** In my opinion, digital dentistry has become all-encompassing and without question represents the most important technology that will drive our industry for the next 25 years. Many clinicians think of digital dentistry only as the ability to create a virtual model of a patient's dentition with an intra-oral scanner. While intra-oral scanning was one very important innovation, it is not new, having been developed and utilised for more than 25 years already!

Perhaps other clinicians relate the term "digital dentistry" to restorations that are fabricated utilising CAD/CAM technology rather than conventional techniques in laboratory-intensive wax-ups and casting, whether for natural teeth or for dental implants. Certainly, this methodology has also been around for many, many years. As machining technologies have improved, software applications have become exponentially more powerful and equipment costs have declined. Most major dental laboratories now speak the language of digital workflow and have invested in the proper hardware, software, and training to deliver CAD/CAM restorations for their clinician clients.

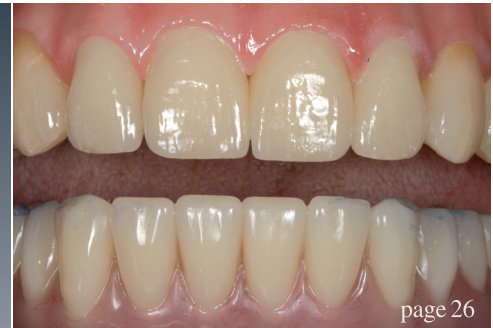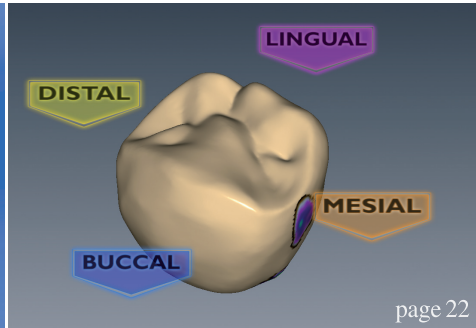
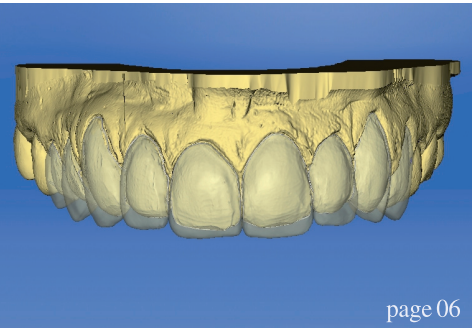
Yet, perhaps we are just discovering what digital dentistry really means and the way in which technology will continue to be fuelled by innovation. The advent of computed tomography, and now cone-beam computed tomography, scan devices has allowed clinicians an unparalleled ability to visually inspect a patient's individual 3-D anatomy, yielding information that can be utilised for preoperative diagnosis and treatment planning. The uses are limited only by our imagination. Patients who require orthognathic surgery, bone grafting, dental implants, third molar extractions, orthodontic intervention or endodontic therapy will all benefit from a more complete and accurate assessment of bone, soft tissue and adjacent vital structures, all provided by digital information.

Can we create a synergy between all facets of digital dentistry? As an example, intra-oral optical scanning data can now be merged with 3-D CBCT data, allowing dental implants to be planned with greater precision through interactive treatment planning software applications. The concepts of virtual teeth, virtual occlusion, virtual articulation and implant planning can now be directly married to CAD/CAM of custom abutments and restorations in zirconia, titanium or other materials. The same technology is now being applied to bone grafting through rapid prototyping manufacturing by creating either an anatomical model or virtual model of the defect, and milling or printing the donor graft from a variety of biocompatible materials.

Just as the smartphone revolutionised the manner in which we communicate, the digital workflow will serve as the foundation for improved methods to treat our patients. The industry is now moving toward a common vision, but we are only at the tip of the iceberg in our use of digital technology worldwide currently. Publications such as this provide a valuable service by showcasing the manner in which all phases of digital dentistry will continue to evolve and affect our industry in the next 25 years.

Keep reading these pages to witness the continued evolution!

Dr Scott D. Ganz



**| editorial**

03 **Digital dentistry, our future?**  
| Dr Scott D. Ganz

**| special**

06 **Projecting a new smile from a facial photograph:**  
**A new way to plan multidisciplinary dental treatments**  
| Drs Marco Del Corso, Italy, & Alain Méthot, Canada

12 **CAD/CAM dentistry and the laboratory technician:**  
**Partners in success**  
| Lee Culp, USA

**| case report**

16 **Digital implant dentistry—a workflow in five steps**  
| Dr Tim Joda & Prof. Daniel Buser, Switzerland

22 **Restoring implants using lithium-disilicate,**  
**CAD/CAM fabricated restorations**  
| Dr Walter G. Renee, USA

**| industry report**

26 **The finesse of the pink and the power of IPS e.max**  
| Rafael Santrich & Dr Larry Grillo, USA

32 **Diode laser application optimises the clinical outcomes**  
**of digital workflow**  
| Drs Frank Liebaug & Ning Wu, Germany

**| industry news**

36 **MIS Dental Implants:**  
**When virtual becomes reality with the MGUIDE MORE**  
| MIS

38 **New open CAD/CAM solutions for dentists and**  
**dental laboratories from Planmeca**  
| Planmeca

40 **Compact 5 axis table-top machines for milling metal,**  
**zirconium dioxide, acrylics and wax**  
| Schütz Dental

42 **Straumann presents data and innovations that**  
**may change paradigms in implant dentistry**  
| Straumann

**| meetings**

44 **Dublin conference discussed future concepts**  
**in dental implant rehabilitation**

46 **5<sup>th</sup> International CAMLOG Congress**  
**—the first CAMLOG Congress**  
**based on the new Consensus Reports**

48 **International Events**

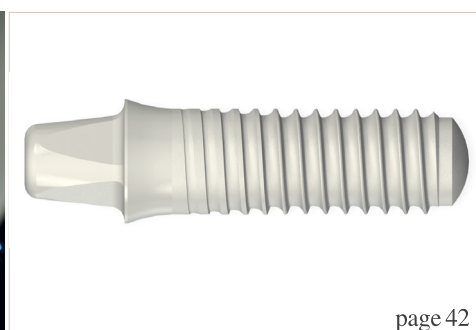
**| about the publisher**

49 | submission guidelines

50 | imprint



Cover image courtesy of Planmeca ([www.planmeca.com](http://www.planmeca.com)).



# Planmeca's open CAD/CAM solutions

## Your ideal combination

Scan.

Planmeca PlanScan™  
Planmeca PlanScan™ Lab

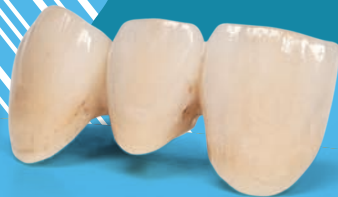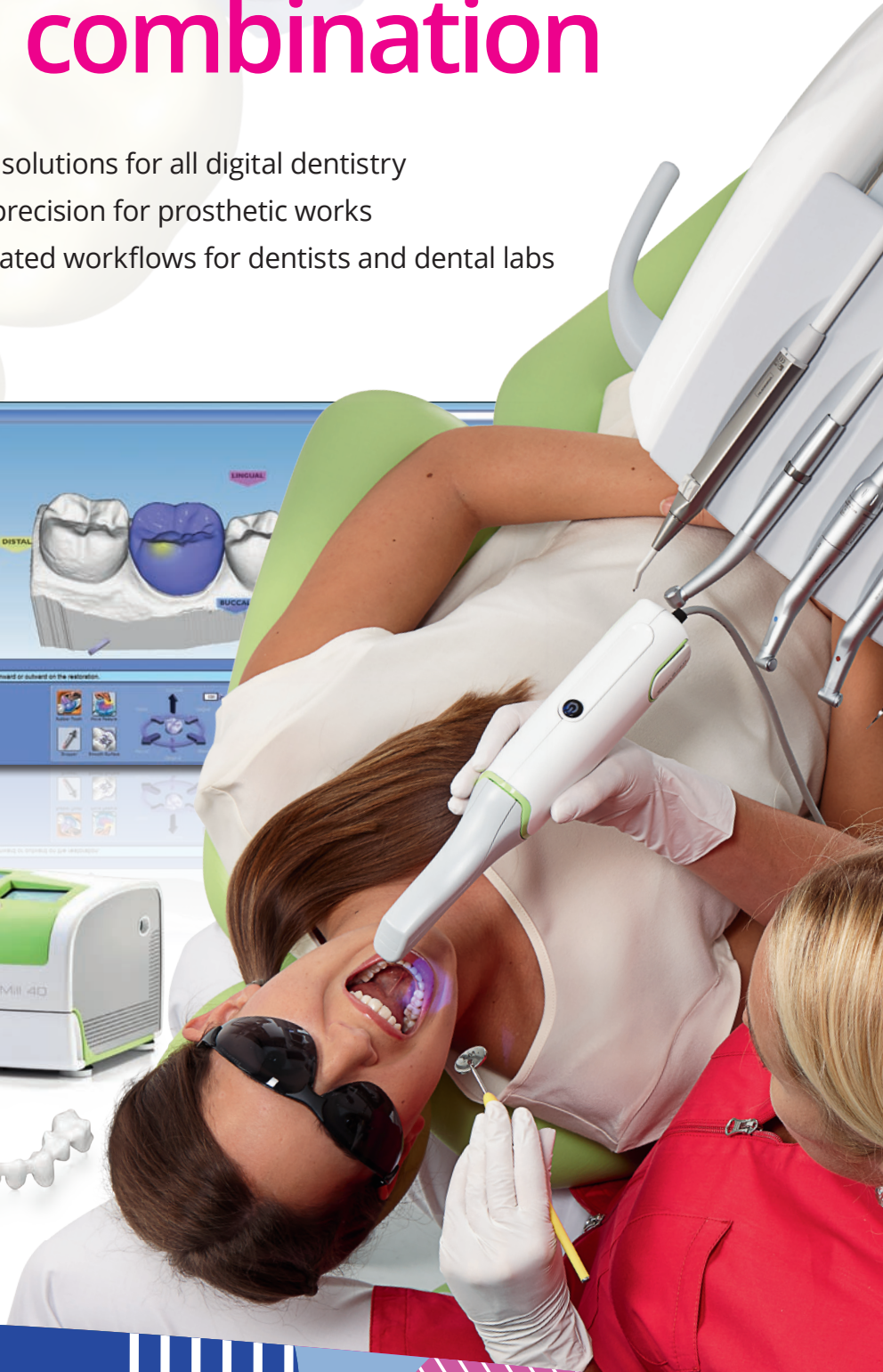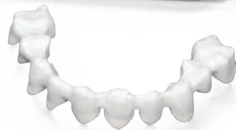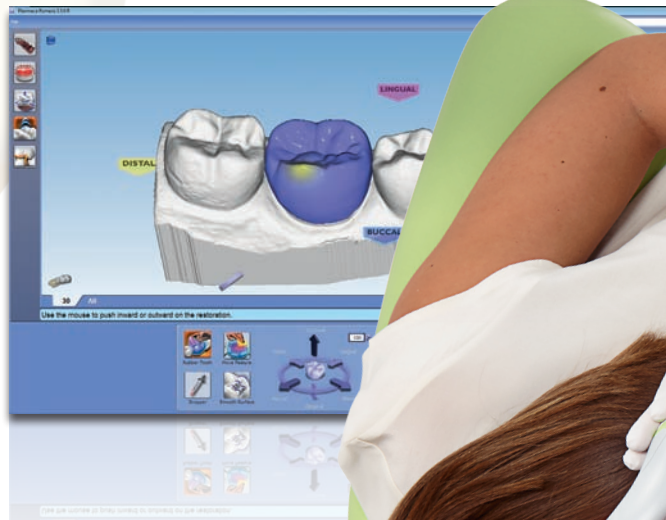
- Open solutions for all digital dentistry
- High precision for prosthetic works
- Integrated workflows for dentists and dental labs

Design.

Planmeca PlanCAD™ Easy  
Planmeca PlanCAD™ Premium

Manufacture.

Planmeca PlanMill™ 40  
Planmeca PlanMill™ 50  
PlanEasyMill™



Find more info and your local dealer  
[www.planmeca.com](http://www.planmeca.com)




# PLANMECA

Planmeca Oy Asentajankatu 6, 00880 Helsinki, Finland  
Tel. +358 20 7795 500, fax +358 20 7795 555, sales@planmeca.com

# Projecting a new smile from a facial photograph: A new way to plan multidisciplinary dental treatments

**Authors** \_ Drs Marco Del Corso, Italy, & Alain Méthot, Canada



**Fig. 1** \_ An example of a smile design simulated in a few minutes and shown to the patient using Dental GPS software.

## \_Introduction

Aesthetic dentistry relies on professional trust, traditional wax-ups and artistic modifications of provisional restorations in the mouth to achieve the desired final result. Many of the published articles in aesthetic dentistry discuss the same principles in smile design: Golden Proportion, gingival architecture, emergence profile, and shape related to facial anatomy.<sup>1-3</sup> These principles have been followed

without any significant advances in technique or case presentation.


Many options are now available to predesign the most appropriate smile for the patient, such as computer imaging, diagnostic wax-ups on models or simply drawing on a patient photograph.<sup>4</sup> For decades, dentists have been using various forms of software to preview, predict, and plan aesthetic procedures. Many of these programs lapsed into obsolescence because it took too long to develop proper diagnostic marketing or clinical guides.

In this article, we demonstrate the use of Dental GPS software, developed and proven over the last five years.<sup>5</sup> The system uses the parameters captured by one digital preoperative full-face photograph to help clinicians with aesthetic diagnosis and automatically generates the best smile virtual wax-ups in only minutes. The smile prescription is then sent to the laboratory for technicians to create or transform a new aesthetic smile with precision (Fig. 1).

## \_From diagnosis to the smile project

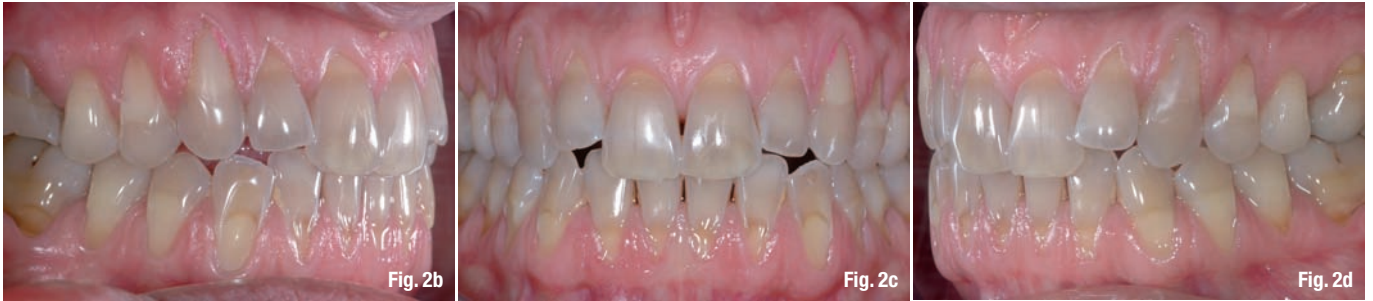The system generates the virtual wax-up and laboratory prescription within minutes with the digital facebow, which captures the exact position of the dental and facial midline with the occlusal plane to prevent canting and shifting of patient cases. The diagnosis and treatment planning system also uses the M Ruler, an algorithm that analyses the best position of all maxillary teeth on a digital image to design the smile.<sup>5</sup> Compared with the Golden Proportion, which offers only one ratio, 1 : 618, the M Ruler determines the patient's own unique ratio for smile design.

The program is used for diagnosing, planning and executing changes in the position, shape, di-



**Fig. 2a** \_ Clinical case: A young female patient previously suffering from gastric reflux came to the clinic with enamel erosion, gingival recession and aesthetic demands.

**Figs. 2b-d** \_ The restoration of both maxillary and mandibular arches aimed at preserving tissue and improving the aesthetic outcome.



mension, and proportion of the teeth. The first advantage of this tool is the rapidity in sharing the aesthetic proposal with the patient, making him or her an active participant in the treatment plan. The precision in transferring all the co-ordinates of the computer-simulated 2-D proposal into a 3-D wax-up allows the lead dentist, all associated specialists and the laboratory technician to access and share information regarding the treatment plan, ongoing procedural status, and the final results of the case. Should any midstream correction be necessary, it is relatively simple to inform and receive consent from all involved.

### \_Diagnosis

Diagnosis is simply achieved by importing a facial photograph into the GPS software and the program then establishes the best smile parameters for the patient.

A full-face photograph of the patient is taken directly from the front by placing the lens in line with the patient's nose (Fig. 2a). The facial photograph is taken with the patient's Frankfurt horizontal plane parallel to the floor. The inter-pupillary line is not important in this process because often one eye is lower than the other. The long axis of the face and the upper lip line are the reference planes for diagnosis and treatment planning.

The digital facebow provided by the software is adjusted by the operator to fit along the incisal edges and the dental midline of the patient. Then, the digital facebow is rotated to fit the long axis of the face on the vertical axis and the upper lip on the horizontal aspect (Fig. 3).

The photograph is automatically zoomed out to place the M Ruler over the face. This helps the clinician to diagnose facial or maxillary asymmetries,

**Fig. 3** The digital facebow of the program is adjusted to fit along the incisal edges and the dental midline of the patient.

**Fig. 4** When the digital facebow has been set, the system automatically zooms in on the mouth with the M Ruler over the patient's teeth.

**Fig. 5** The M Ruler helps to diagnose facial and dental asymmetries to provide the most aesthetic tooth position, shape, and smile design for the patient's facial frame.

**Fig. 6** The M Ruler guides the clinician in creating a virtual wax-up for the best smile design using specific libraries. The result is precise because the image is calibrated to maxillary incisors dimensions.

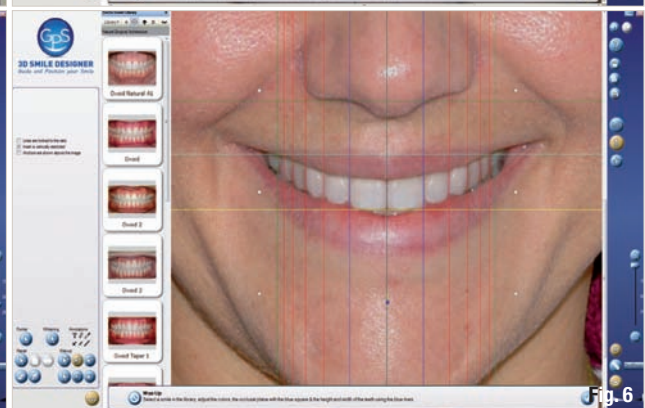
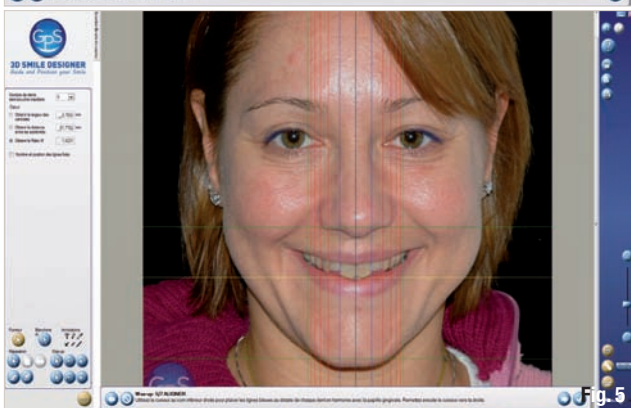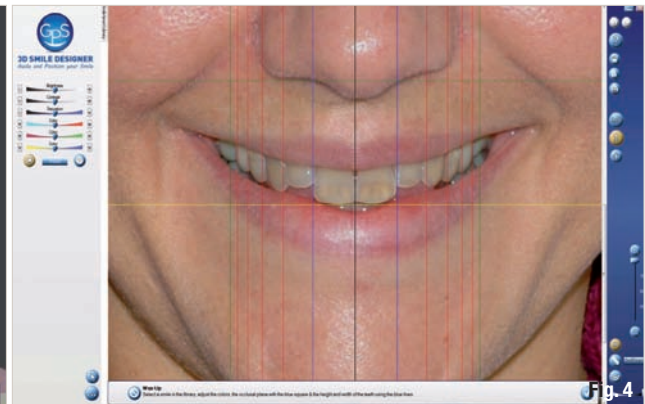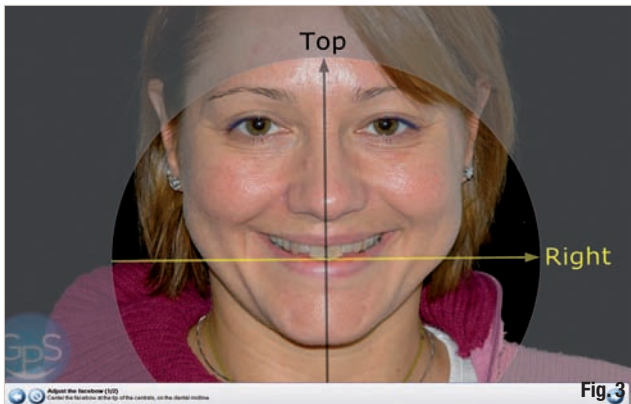
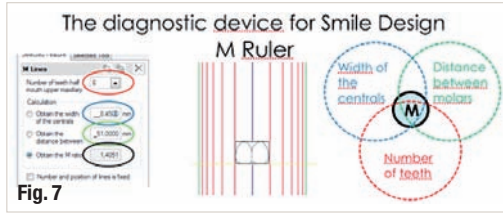


Fig. 7\_The M Ruler.



malpositioned teeth, gingival architecture discrepancies, improper axial inclination, dental midline deviation, or indications for maxillofacial surgery and/or orthodontic treatment (Fig. 4).

Without the patient's facial data, it is impossible to evaluate the smile and its harmony within the patient's face properly. As part of the diagnosis, it is necessary to evaluate facial and dental asymmetries. As practitioners, we need to keep global aesthetics in mind by using a full facial view in the laboratory (Fig. 5). Close-up photographs of the patient's smile aid smile design, but the complete facial photograph is required to evaluate the smile on the patient's face.<sup>6</sup>

**\_Simulation**

Computer software creates a simulation as a virtual wax-up. The practitioner uses the virtual wax-up in the diagnostic process to determine the treatment options appropriate for the patient, such as orthodontics, crowns, implants, bridges, or full or partial dentures. This process aids the practitioner in presenting and discussing different options with the patient during a consultation (Fig. 6).

The diagnosis and treatment planning use the M Ruler. This diagnostic tool for smile design uses an algorithm based on maxillary central incisors width and the width of the patient's maxillary arch to display an ideal arrangement of all the teeth shown in the smile (Fig. 7). Each patient has a unique maxillary arch width and upper central width. Maxillary teeth best position should be disposed between those lines in respect of the width of the upper arch and the width of the central incisors.

These vertical lines guide professionals in determining the best position of the maxillary arch and teeth in relation to the patient's face and in relation to the patient's lips and gingiva for smile design.

The computer software simulation or virtual wax-up can be generated within minutes, and helps (or guides) the clinician in determining treatment options, which can be discussed with the patient during the same consultation.

In this particular clinical case, the simulation suggested longer central incisors to create a smile line that would follow the lower lip and lend a more pleasing proportion to the smile. Tooth whitening was also indicated (Fig. 8).

**\_Communicating with the laboratory**


After the virtual diagnostic wax-up, the patient was informed of the treatment options, including no treatment at all, and the risks, benefits, and costs of treatment. Informed consent was obtained for the treatment, which entailed placing ten veneers from the second premolar to the opposite second premolar on the maxillary arch and ten veneers on the mandibular arch.

Once the simulation (Fig. 8) had been accepted by the patient, alginate impressions of the maxillary and mandibular arches were poured with white stone and sent to the laboratory with a bite registration<sup>6, 7</sup> taken using LuxaBite (DMG America). The aesthetic prescription was sent to a certified dental laboratory, which mounted the 3-D model on to an articulator in accordance with the GPS smile prescription and waxed up the final work following the future smile line (Figs. 9a & b). Because of the image's calibration, the wax-up coordinates are very precise (Fig. 10).

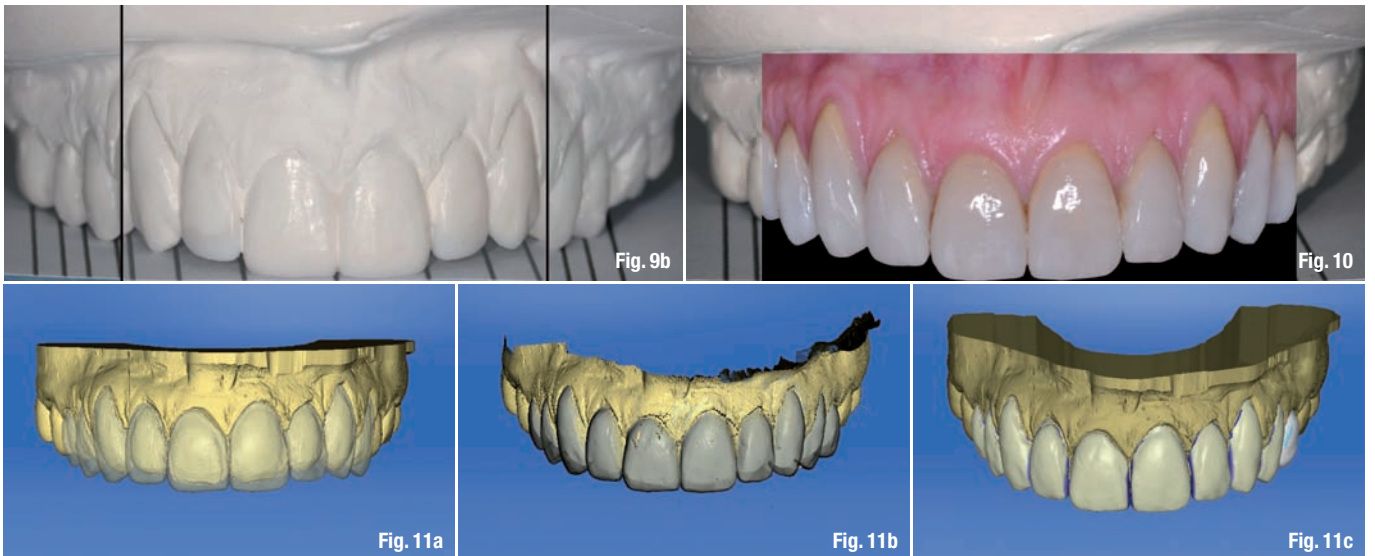
Laboratory communication is a critical factor in the development of a diagnostic wax-up. In order to reproduce the simulation (virtual wax-up), the laboratory technician requires the position of soft

Fig. 8\_The before and after simulation usually shown to the patient at the end of the first consultation.

Figs. 9a & b\_The prescription resulting from the software (a) gives the laboratory the co-ordinates necessary to mount the model on to the articulator and to wax up the final work. Specific guidelines help the technician to create a very precise wax-up of the future smile (b).







tissue on the articulator. After simulating the final outcome with respect to the rest of the face, the GPS digital facebow will position the maxillary cast on the articulator with the exact pitch, yaw and row of the photograph to reproduce the virtual wax-up on provisional and final restorations. The M ruler guides the wax-up of the future smile. This process is actually the easiest way to transmit the entire aesthetic data concerning the facial soft tissue to the laboratory.

### Project realisation

The model's wax-up was used to fabricate a preparation guide<sup>8</sup> to perform minimally invasive preparation, controlling ceramic thickness and maintaining the structural integrity of the tooth.<sup>8,9</sup> A silicone impression of the wax-up was taken with Sil-Tech Putty (Ivoclar Vivadent) and the impression was filled with Luxatemp provisional material in shade A2 (Luxatemp, DMG, USA) and then relined to the prepared teeth in order to create a mock-up.

Once the wax-up had been used to create a precise mock-up, the mock-up was scanned and constituted the ghost guide for the CEREC system (Sirona) to project (Figs. 11a–c) and produce chairside ten maxillary and mandibular veneers using IPS Empress CAD blocks (Ivoclar Vivadent). The final restorations were successively stained, glazed and cemented with shade A3 Variolink (Ivoclar Vivadent; Figs. 12a & b).

At the end of treatment, the smile line had been corrected to follow the lower lip line contour, and the final smile results were in harmony with the patient's face. Both maxillary central incisors were dominant and had been designed to the specific width and length by the GPS program to suit the

patient's face. The final aesthetic outcome fulfilled the patient's expectations, and an improved smile and facial appearance were achieved (Figs. 13a & b).

### Discussion

By using a simple preoperative facial photograph of the patient, the dental practitioner can diagnose, create a treatment plan, and produce with precision a virtual wax-up and laboratory prescription in less than 10 minutes. The software in this case uses the M Ruler to determine the best smile for the patient.

The Golden Proportion Rule, or Divine Rule, represents a ratio of 1:1.618. This ratio has been used in a multitude of applications for many years, and is well known in the arts and architecture, dating back many centuries. Over the course of time, this Golden Proportion Rule has been applied to facial aesthetics and dentistry to provide mathematical guidelines for the creation of pleasing and aesthetic smiles by the determination of the appropriate proportions of the central and lateral incisors, and the canines in the smile. However, many authors have observed that natural teeth do not follow the Golden Proportion Rule for the display of teeth<sup>8,10,11</sup> and this rule cannot be universally applied to all patients. In order to achieve a good aesthetic result, the ratio of the Golden Proportion Rule must be changed or adapted for each patient.

This modified Golden Proportion Rule is achieved by application of a mathematical formula relating to the inter-molar distance of each patient, representing the width of the arch and the width of the central incisors to determine the correct balance for the teeth displayed within that arch to create a pleasing smile.<sup>5</sup>

**Fig. 10** Once the wax-up has been calibrated to the 2-D virtual simulation, the realisation of the project is very easy and will respect the preprogrammed aesthetics. Individualization of the final ceramics is possible.

**Figs. 11a–c** Prepared teeth and project (a) are scanned using the chairside CEREC Software 4.2. The wax-up (b) is scanned and used in "ghost" modality to guide the creation of the definitive restorations (c). These are milled with the CEREC MC XL milling unit.