

laser

international magazine of laser dentistry

3²⁰¹⁰




| **research**
Frenectomy review

| **interview**
“A man alone cannot do anything”

| **social news**
AALZ Greece successfully established

0277113



When I bought my Fidelis my colleagues told me Fotona never stops innovating. They never stop pushing the boundaries of laser dentistry. How right they were! I've just started working with my new set of **Preciso endodontic and Varian periodontic** fiber tips. Both are fully compatible with the **AT/HT Fidelis Er:YAG laser**. I can now choose from almost 20 fiber tips to make my hard and soft tissue treatments less invasive, more effective and to reduce my patients' chair time.



Fotona user since 2000

NEW

Fotona
choose perfection

AT Fidelis Highest Performance in Dental Care

Revolutionizing Dentistry

The AT Fidelis is Fotona's newest generation in dental laser systems. With dentistry's two best lasers in one system, you can provide the ultimate in dental care! AT Fidelis' Er:YAG, the world's fastest drilling, hard tissue laser, features broadened soft tissue surgery capabilities with the finest low pulse, high repetition rates. Its top-of-the-line Nd:YAG laser provides trouble-free endodontic, surgical and aesthetic procedures. Both lasers feature VSP technology, enabling controlled and constant laser intensities, in an unprecedented five, selectable pulse duration modes.

Convenience and Safety First

The AT Fidelis includes the newest Comfort Mode touch screen navigation system. Its pre-set treatment programs and data storage facility offer ultimate treatment management. Selecting the right treatment settings has never been easier!

Its Advanced Mode enables users to quickly fine-tune procedures through its all-encompassing interface. The AT Fidelis offers the industry's only Tissue effect Graphical Interface (TeGI) which provides precise graphical representations of laser-tissue effects as treatment settings are changed. For improved user comfort, the AT Fidelis features a wireless footswitch. While ESC Technology allows you to perfect water and air spray mixes, the AT Fidelis does not require external air or water sources, making it uniquely mobile.

Unlimited Possibilities!

Apart from providing the widest range of hard and soft tissue dental treatments, you can also upgrade your system with aesthetic upgrade packages. This enables you to provide aesthetic treatments ranging from facial laser hair removal and rejuvenation treatments to facial vascular treatments.



The Highest Performance, Best Made Laser Systems in the World

Put a smile on your patients' faces!
Visit www.fotona.com now!



Prof Dr Norbert Gutknecht
WFLD President
Editor-in-Chief

Laser—useful and reasonable

„Laser is not only an expert medical or dental discipline, but also a technology which, thanks to its versatility, can be applied on its own or in addition to other treatments for a variety of different medical and dental purposes. Moreover, there is not just "the one and only laser", but lasers of different wavelengths. Since students do not learn anything about laser application during their studies, e.g. that laser application is based on biophysical light-tissue interactions, it is highly important for every responsible dentist to acquire the necessary knowledge about lasers.

Integrative laser technology, applied in responsible dentistry, is a useful and reasonable complement to treatment of patients in most other disciplines, and it often leads to a less painful, minimally invasive and all-round more successful treatment.

Prof. Dr. Norbert Gutknecht
-President of DGL-

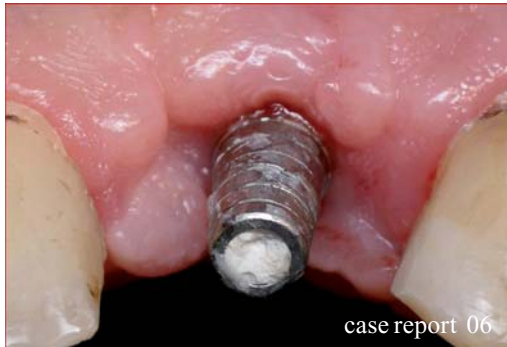AD

LASER...INNOVATION
MADE IN GERMANY

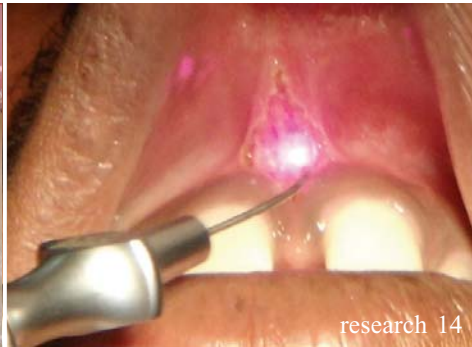The new **FOX**

- > Endodontics
- > Periodontics
- > Implantology
- > Surgery
- > Whitening
- > Biostimulation

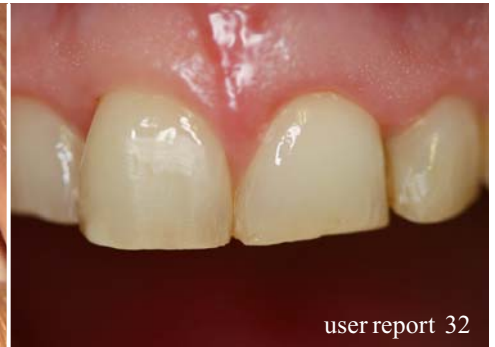www.arclaser.de



case report 06



research 14



user report 32

| editorial

- 03 **Laser**—useful and reasonable
| Prof Dr Norbert Gutknecht

| laser

- 32 “A man alone cannot do **anything**”
| Kristin Urban

| case report

- 06 **The use of the Er:YAG in laser-assisted broken abutment screw treatment**
| Avi Reyhanian, Steven Parker, Joshua Moshonov, Natan Fuhrman
- 12 **Laser phototherapy in Bell’s palsy**
| Prof Aparecida Maria Cordeiro Marques, Luiz Guilherme Pinheiro Soares, Dr Cristina Maria do Nascimento, Alberto de Aguiar Pires Valença Neto, Roberta Cordeiro Marques, Dr Antonio Luiz Barbosa Pinheiro

| social news

- 34 **2010—A breakthrough for Laser Supported Dentistry in Sweden**
| Dr Peter Fahlstedt
- 36 **AALZ Greece successfully established**
| Dimitris Strakas, Dominique Vanweersch

| research

- 14 **Frenectomy review**
| Dr M. L. V. Prabhuji, Prof Dr Madhu Preetha, Dr Ameya G. Moghe

| meetings

- 38 **International events 2010–2012**
- 40 **XIIth International Congress of the WFLD in Dubai**
| Prof Toni Zeinoun
- 44 **Laser dentistry and Implantology Symposium in Gaziantep a great success!**
| Leon Vanweersch
- 46 **“Tomorrow’s dentistry today”**
| Ralf Borchert

| user report

- 20 **The minimalinvasive laser surgical crown lengthening**
| Dr Thorsten Kuypers
- 24 **The clinical use of the Er,Cr:YSGG laser in endodontic therapy**
| Justin Kolnick
- 28 **Er,Cr:YSGG laser assisted GTR in periodontal surgery**
| Dr Elena Speranza Moll

| news

- 48 **Manufacturer News**

| about the publisher

- 49 | submissions
- 50 | imprint



social news 38



meetings 44



meetings 46



Just 115 x 90 x 28 mm: the claros pico®

“elexxion’s latest development is absolutely brilliant.

It’s exactly what practitioners like us need!“

It’s here! elexxion, the global technology leader for high-quality dental lasers, is presenting the claros pico® for professionals.

The claros pico® is an absolutely full-featured, professional-standard dental laser that comfortably fits in one hand. With its lithium ion technology, it offers all the mobility that modern practices demand.

What does that mean for you on the front line? With the claros pico® you´ll be getting a diode laser that opens up new treatment possibilities in endodontics, periodontics and soft tissue surgery at the "push of a button". You´ll be able to treat numerous indications more effectively - and give your practice a new competitive edge in the process. And, needless to say it boasts a laser bleaching function that your assistants can use on their own.

For more information about the brand new claros pico® please visit our website.

elexxion AG
Schützenstrasse 84
78315 Radolfzell
Germany

www.elexxion.com

elexxion AG

Dental-Laser

The use of the Er:YAG in laser-assisted **broken** abutment screw treatment

Authors _Avi Reyhanian, Israel, Steven Parker, United Kingdom, Joshua Moshonov, Israel, Natan Fuhrman, Israel

Abstract

Dental implants are a functional and aesthetic solution to partial and total edentulism. Although the overall success rate of implant dentistry is very high, over 90% of the treatment modality is not free of complications and dental implants occasionally fail. The chronic loosening or fracturing of implant screws continue to be a problem in restorative practices and generally are challenging to remove. This report describes and demonstrates the management and technique used for the removal of fractured screw fragments and the successful utilization of the Er:YAG laser as an important auxiliary tool.

Introduction—the problem

Success in implant-supported prosthetic replacement of teeth will be due to a combination of appropriate placement criteria (receptor site quality, implant stability, osseointegration), appropriate (non-excessive) loading and prevention of bacterial contamination. The failure of dental implants is due not only to biological factors, such as unsuccessful osseointegration or the development of peri-implantitis, but it may also result from technical complications.^{1,2} Den-

tal implant complications may be considered under the following main categories:

Early

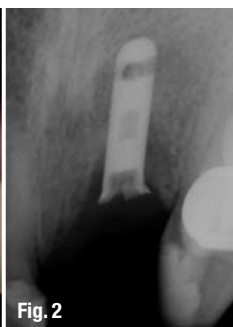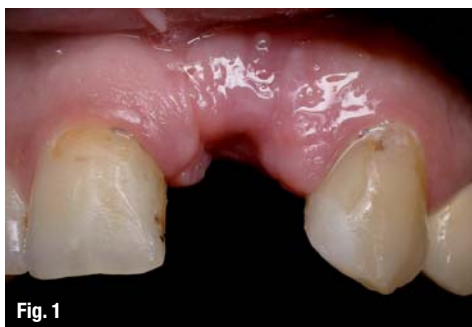- _ Failure/inadequate surgical preparation.
- _ Failure of osseointegration.
- _ Peri-surgical infection.

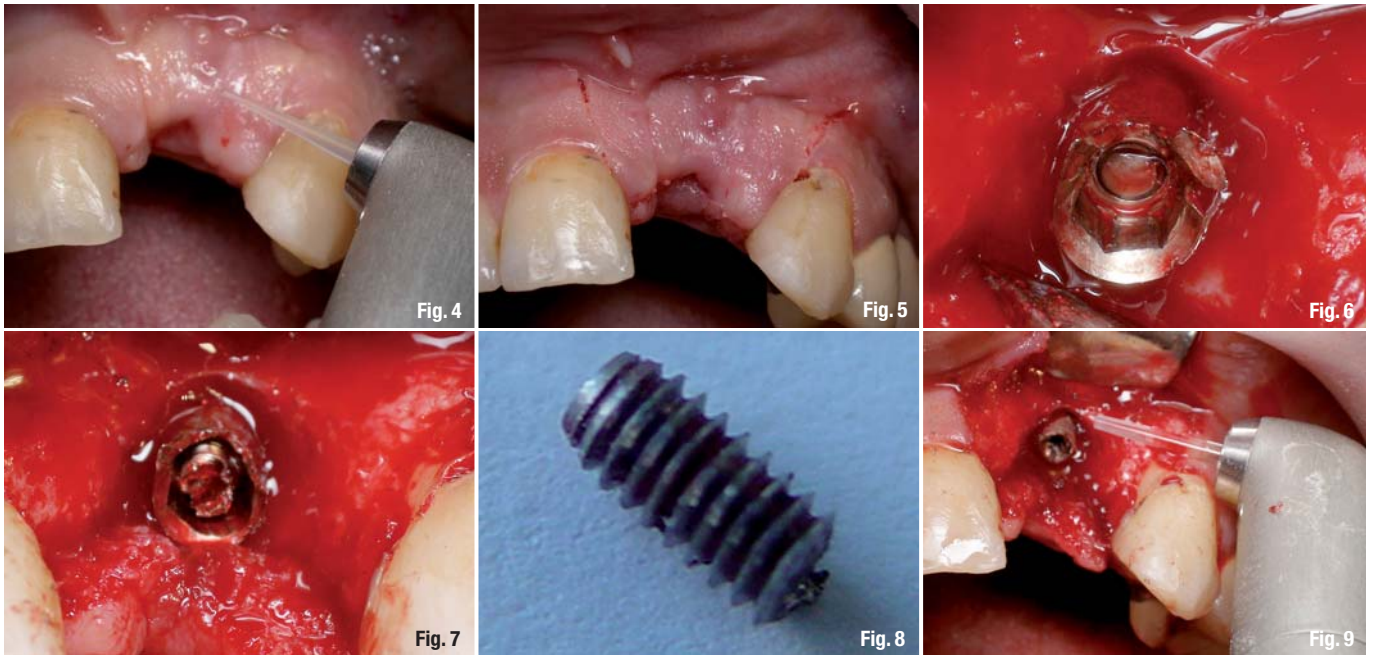
Late

- _ Implant overloading, leading to bone loss.
- _ Peri-implantitis.
- _ Soft tissue complications.
- _ Fracture of mechanical components and aesthetic/phonetic considerations.

Failures of implant-supported restorations result from technical problems and can be divided into two groups: those relating to implant components, and those relating to the prosthesis.^{3,4,5,6,7,8,9,10,11} Technical problems related to implant components include abutment screw fracture.^{8,12}

The abutment screw fracture presents a rare, but quite unpleasant failure and can be a serious problem^{13,14}, as the fragment remaining inside the implant may prevent the implant from functioning efficiently





as an anchor.¹⁵ The primary reason for screw fracture is undetected screw loosening which can be due to bruxism, an unfavorable superstructure, overloading^{16,17} or malfunction.^{10,11,18,19} Fractures of the implant abutment or of the abutment screw have been observed as a consequence of screw loosening and undetected micro-movements of the abutment under functional loading²⁰ and consequently, it is advised that the repeated loosening of an abutment screw should alert the clinician to possible significant contributing causes.

However, the behavior of the implant/abutment joint components with respect to critical bending force is still unclear.^{20,21} Studies show that implant abutment failure occurs when lateral forces exceed 370 Newtons for abutment with a joint depth of at least 2.1 mm and 530 Newtons with a joint depth of at least 5.5 mm.⁷

Preventive recommendations

- The number, position, dimension and design of implants, as well as the design of the prosthesis are critical factors to be considered during the treatment planning phase.^{11,12,13,22,23} To withstand high bending stresses, implants should be as long and as wide as possible, used in adequate numbers, and be positioned such as to allow axial loading.^{13,20,24,27} Implant components are known to fracture more frequently in the posterior region and in partially dentate patients compared to completely edentulous patients.^{5,6,9,11,12,19,23,25}
- Retightening an abutment screw ten minutes after the initial torque applications should be routinely performed, and increasing the torque value for abut-

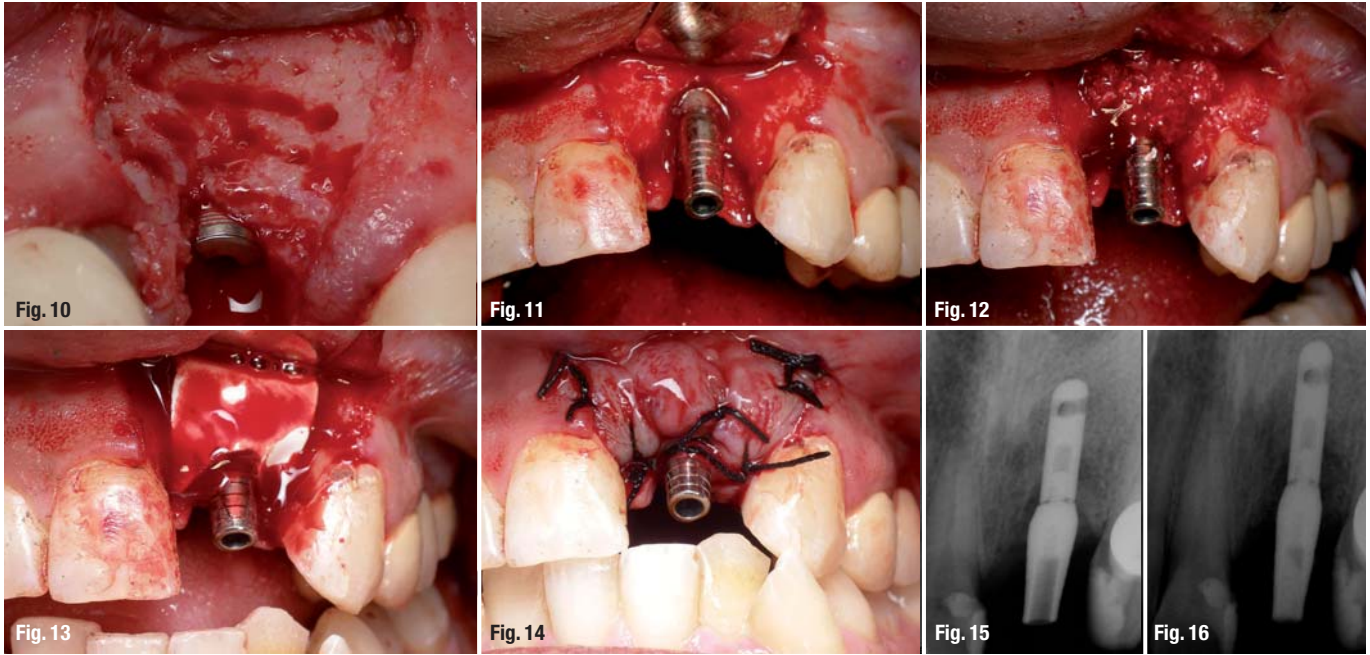
ment screws above 30 Newtons can be beneficial for the abutment, implant stability and to decrease the possibility of the screw becoming loose.²⁵

- Proper case selection, excellent surgical technique, placing an adequate restoration on the implant, educating the implant patient as to the importance of maintaining meticulous oral hygiene, and evaluating the implant both clinically and radio-graphically at frequent recall visits²⁶; reinforcing periodic maintenance.
- A procedure for using dimples inside the abutment screw cylinder above the screw, and filling the holes with elastomeric impression material will prevent the screw-retained prosthesis from loosening.²⁷
- Using the correct fixation screw.
- Replacing loose screws instead of retightening them.
- Immediate investigation; looseness of the prosthesis is detected by the clinician or patient.^{28,29}

Fragment retrieval methodology

The methods employed to grasp the broken fragments or screw are determined according to the location of the fracture abutment—above or below the head of the implant. If an abutment screw fractures above the head of the implant, an explorer, a straight probe or haemostats³⁰ might be successful. The tip of the instrument is moved carefully in a counter-clockwise direction over the surface of the screw segment until it loosens.¹ If the screw fracture occurs below the head of the implant, other methods are required. There are several available implant repair kits:

- ITI® Dental Implant System (Institut Straumann AG, Switzerland), consists of drills, two drill guides and six manual tapping instruments.⁸



- _ IMZ®TwinPlus Implant System¹ (DENTSPLY Friadent, Germany)
- _ Screw Removal Kit Replace (Nobel Biocare™, Yorba Linda, California, USA)
- _ Certain®-Screw Removal Kit (Biomet 37™, Florida, USA³)

The application of these systems is to permit a hole to be drilled into the centre of the broken screw and drive a removal wedge into the hole that engages the broken screw when reverse torque is applied by removing the instrument.

If no thread damage has occurred and the screw has not "bottomed out" or torqued into a seating stop, then the force necessary to remove the screw may be minimal.⁸ If none of these systems is available, another method for broken screw retrieval involves the following procedure: after the prosthesis or abutment is removed, the screw hole is vigorously flushed with an air/water spray from a 3-way syringe. Pressurized air is applied to dry the screw hole, and a drop of mineral oil (delivered on the tip of an explorer) is introduced into the screw hole. A sharp 1/4-round bur in a high-speed handpiece is activated and lightly applied to the exposed side of the fractured screw. The objective is to have the spinning bur's blades contact the metal surface of the screw so that the screw will spin itself out of the hole. When repeated several times, the screw can be backed out and retrieved easily with forceps.⁸

If this technique fails, a slot can be created using a surgical drill, on the head of the fractured screw, and then a screwdriver is used to back out the broken abutment screw. Sometimes just a gentle touch with

the drill to the head of the broken screw will be enough to back it out. If the hexagonal head of the screw is stripped, it should be filed away completely using a round carbide bur or heatless stone, the head of the implant should be straightened, and a new abutment may be rotated into the implant.

Case study

This clinical report describes a situation in which a fractured implant abutment screw was successfully retrieved by using the Er:YAG laser as an auxiliary tool, and the advantages of this 2,940 nm wavelength versus conventional methods.

Examination

A 36-years-old male presented for treatment, reporting the detachment of an implant-supported crown in the region of the upper left central incisor. The patient stated that the implant and crown had been placed four years earlier and that looseness of the crown had occurred on two occasions during this period. On both occasions, the screw had been re-tightened with no further investigation.

Clinical examination of the patient revealed a missing tooth at the location of #9 with no sign of an implant (Fig. 1). The patient brought the abutment, crown and broken screw with him (Fig. 3). Radiographic examination of the area showed the presence of a root-form cylindrical implant, consistent in appearance with a 13 mm long, 3.75 mm diameter abutment with an internal hex. The apical part of the screw remained threaded into the implant, but had fractured at the level of the hexagonal lock. Although

Introducing iLase™

The next instrument for your tray.



Powerful.
Affordable.
Beyond Portable.



Actual Size

iLase™ gives Biolase the most complete family of dental laser solutions, to match the needs of you and your patients perfectly as you expand your laser applications:



iLase™

The Personal Laser, for everyday soft-tissue procedures.



ezlase™

The Total Diode Laser Solution, including whitening and pain relief.



waterlase™ MD TURBO™

Best-of class soft and hard tissue laser for common and advanced restorative, periodontics, endodontics, cosmetic, surgical and pediatric procedures.