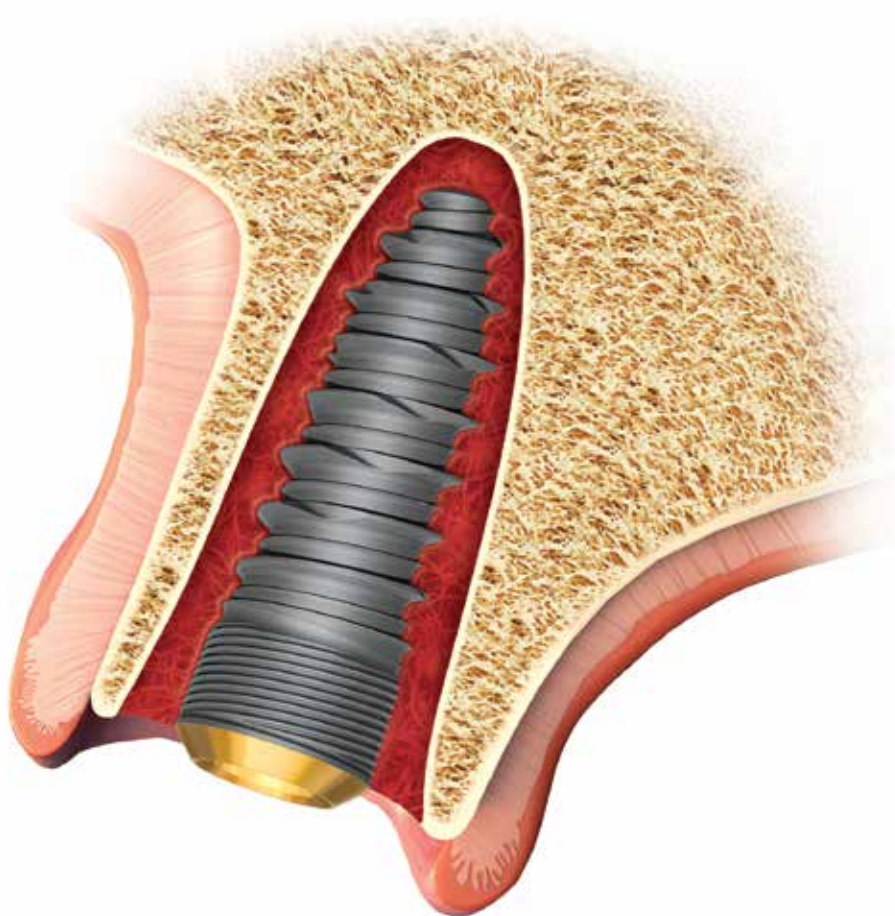


# implants

the international C.E. magazine of oral implantology

2<sup>2017</sup>

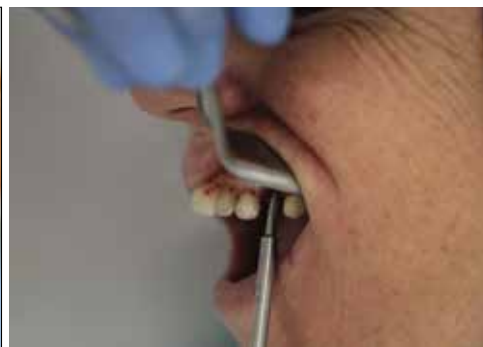
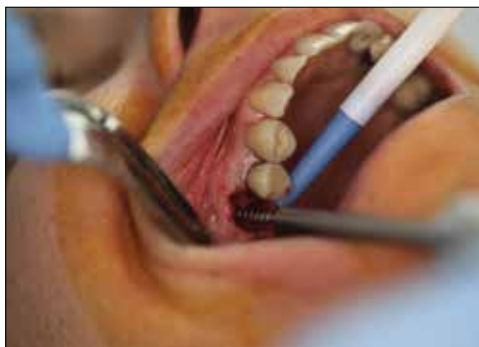

## **\_c.e. article**

Minimally invasive implant placement without the use of biomaterials

## **\_case study**

The synergetic effect: L-PRF and OSSEAN implant surface



### | c.e. article

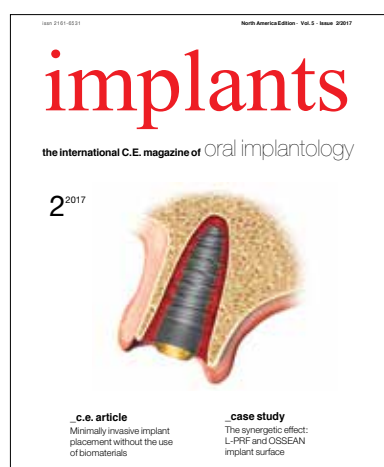
- 04 Minimally invasive implant placement without the use of biomaterials **using the bone-expansion technique**  
\_ Gilles Chaumanet, DMD, MSc

### | case study

- 10 The synergetic effect: **L-PRF and OSSEAN implant surface**  
\_ Robert J. Miller, MA, DDS, FACD

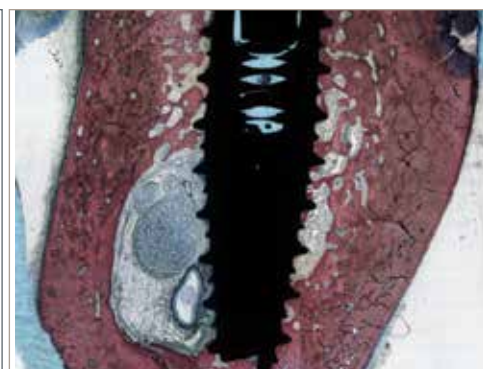
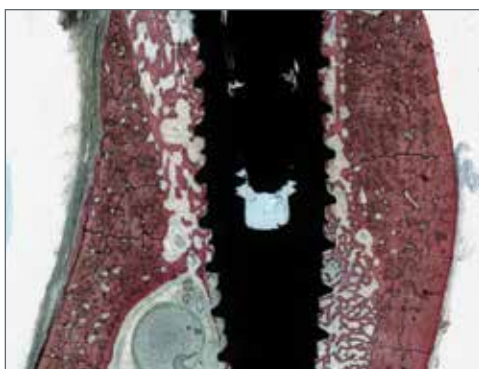
### | about the publisher

- 14 Imprint



### | on the cover

*Cover image provided by Intra-Lock.  
To learn more about this technology,  
see page 10.*





Dentsply Sirona does not waive any right to its trademarks by not using the symbols "®" or "™". 32670860-US-002 © 2016 Dentsply Sirona. All rights reserved.

Simplant®

my practice is thriving.  
mySimplant® is why!

mySimplant is a digital treatment planning service for guided surgery that enables you to treat more patients with enhanced safety, and predictability. The user-friendly interface eliminates the need acquire costly planning software or spend valuable hours learning how master it.

Our Simplant technicians will prepare an implant planning proposal which you can review and approve on your own time. Digital flexibility is readily available, enabling you to deliver better, safer and faster implant treatment.

Go to [mySimplant.com](http://mySimplant.com), check out the intuitive online system, and get started today!

[www.dentsplysirona.com](http://www.dentsplysirona.com)





# Minimally invasive implant placement without the use of biomaterials using the bone-expansion technique

Author\_Gilles Chaumanet, DMD, MSc

## \_c.e. credit

This article qualifies for C.E. credit. To take the C.E. quiz, log on to [www.dtstudyclub.com](http://www.dtstudyclub.com). Click on 'C.E. articles' and search for this edition (Implants C.E. Magazine — 2/2017). If you are not registered with the site, you will be asked to do so before taking the quiz. You may also access the quiz by using the QR code below.



The success rate in implantology is close to 96 percent. Thanks to well-established implant placement protocols, with a few differences according to the implant system used, the predictability of the result under optimum tissue conditions is quite significant. It is very different when these conditions do not meet the recognized standards in terms of volume and quality for reproducibility in implantology. For example, thin ridges, which are frequent occurrences, will require a long and costly process for patients because they entail bone augmentation or possibly support tissue grafts.

Is there a minimally invasive alternative for these patients that allows them to be treated without these problems? One line of thinking is to stop the systematic practice of implantology as subtractive at the tissue level, but rather to transfer these volumes and thereby ensure a minimally invasive procedure. This implies reviewing all the biomechanical principles of implantology, not only in terms of the implant structure and design but also in relation to peri-implant tissue.

The general surgical principle of modern implantology since Brånemark has been bone preparation,

called osteotomy, as close as possible to the dimensions of the implant that will be placed. This principle is still widely prevalent.

However, soft-tissue management has evolved, and the trend the past few years has been to manage soft tissue from the first surgical step. With the arrival of self-tapping conical implants, a new technique was developed that enables lateral as well as vertical bone compressing, condensing or expanding. Additionally, in 1994, Summers, practicing his crestal sinus lift technique with careful choice of conical taps, was the first to demonstrate the capacity of cancellous bone to be modeled (Fig. 1).

Through two clinical cases, we will see it is possible to be minimally invasive, precise and also avoid the use of biomaterials simply by exploiting the biomechanical properties of bone tissue and its capacity to regenerate. Respecting guided regeneration principles, which means the implementation of physical barriers to isolate the epithelial and connective tissue cells from the operating site, enables regeneration of the different tissues.

These principles are (Fig. 2):

- Primary closure of the surgical site to enable

**Fig.1** \_Original explanatory sketch of Summers' technique.  
(Photos/Provided by Dr. Gilles Chaumanet)

**Fig. 2** \_Bone expansion through the septum with the use of osteotomes (2a, 2b). Choice of healing screw that enables primary closure of soft tissue (2c, 2d).

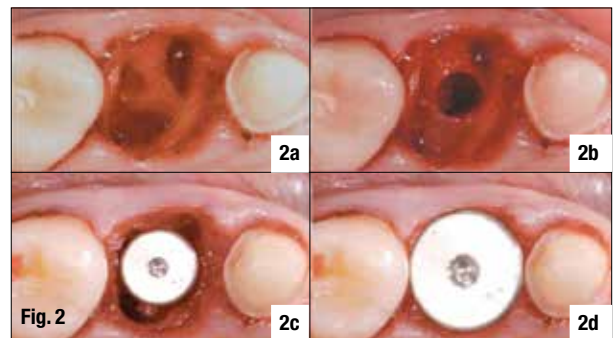

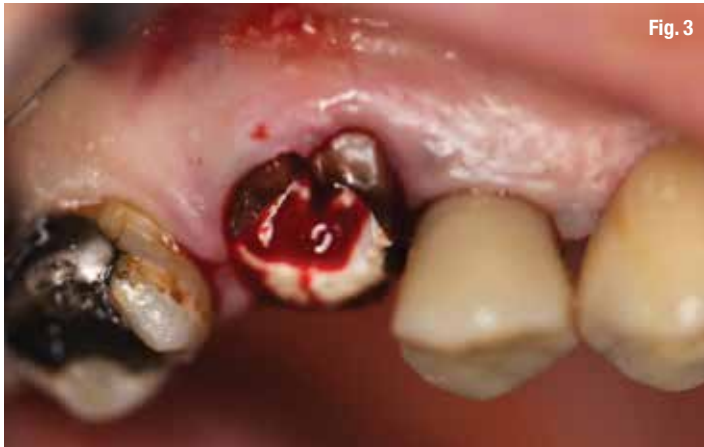



Fig. 3

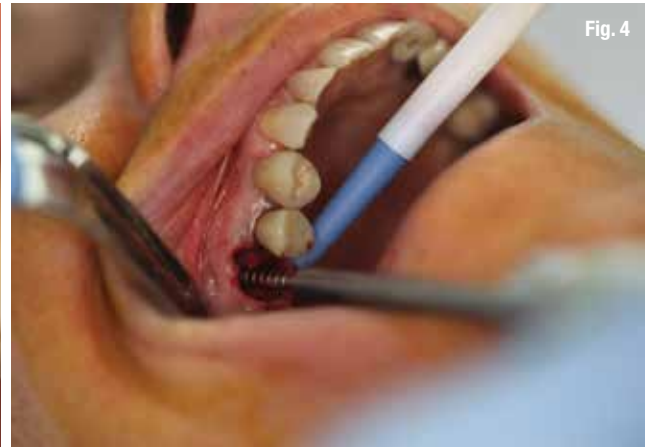

Fig. 4



Fig. 5

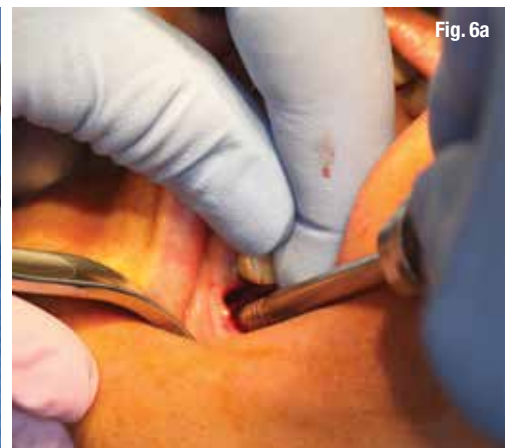


Fig. 6a

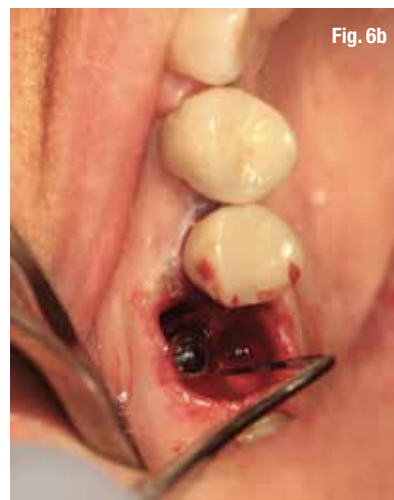

Fig. 6b

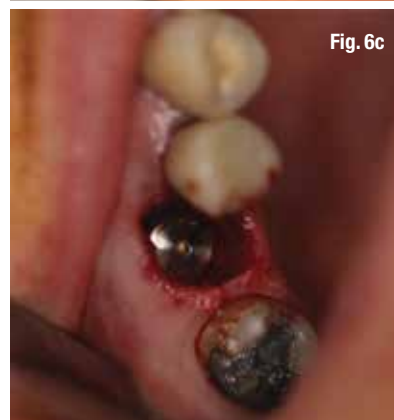

Fig. 6c

undisturbed and uninterrupted healing.

- Completion of the best possible angiogenesis to provide the required vascularisation and undifferentiated mesenchymal cells.
- Creation and maintenance of a space to facilitate bone formation inside this space.
- Stabilization of the surgical site to induce blood clot formation and facilitate healing.

Thanks to the careful choice of the healing screw or the implant abutment/temporary crown pair, these two entities with different regeneration potentials can be hermetically sealed, thereby avoiding cell competition, which we know contributes to the growth of epithelial cells that develop more rapidly.

### Case No. 1

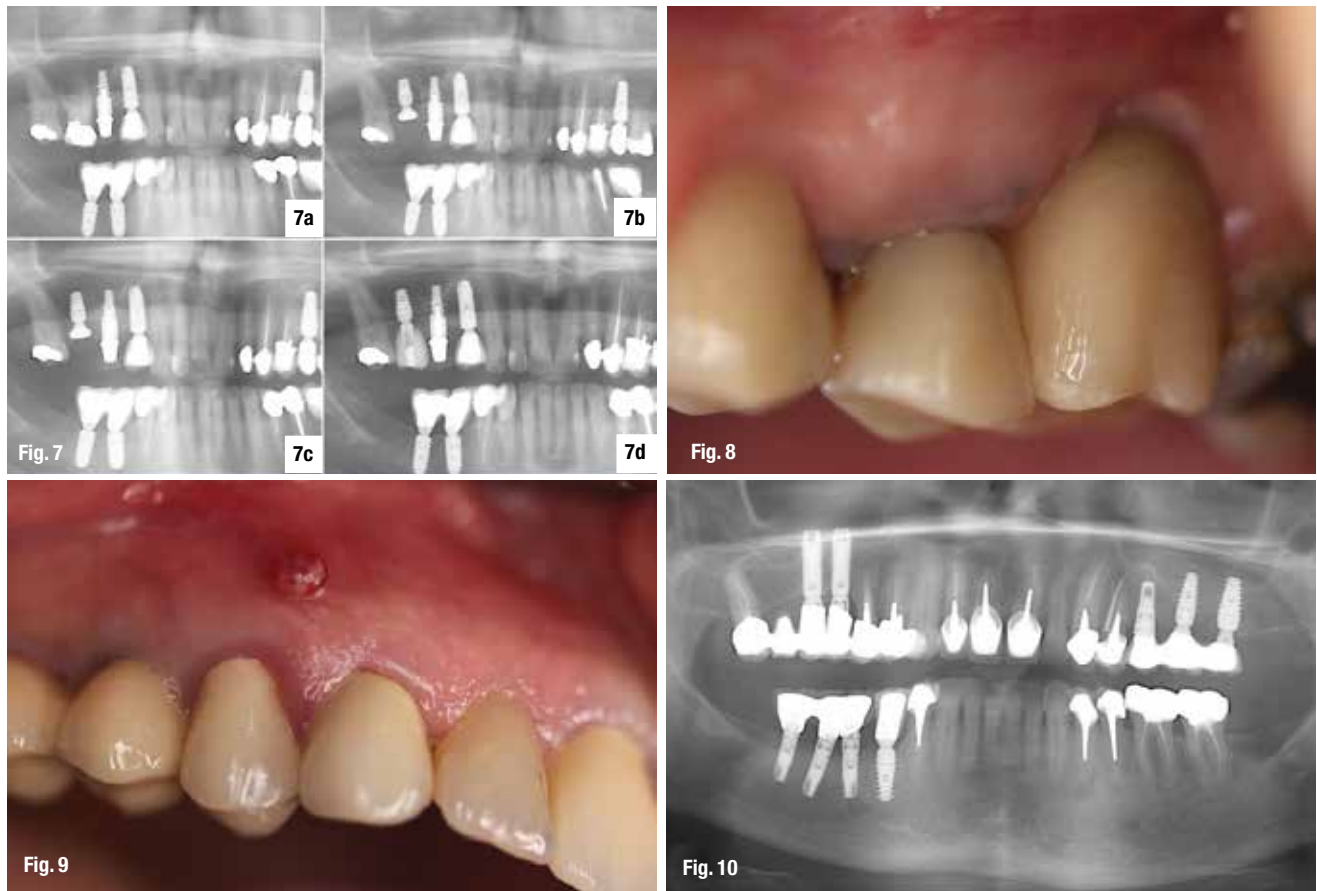
The patient presented with a fracture of #16 (Fig. 3) and periapical cysts. With the patient's consent, the decision was made to perform an extraction, debridement, socket decontamination and immediate placement of a non-submerged implant (implant and healing screw) using Summers' method (crestal sinus lift). The patient was on standard premedication with amoxicillin and corticosteroids. The #16 was carefully extracted by radicular separation to avoid bone fracture especially in the vestibule where

**Fig. 3\_**Preoperative clinical view of #16 fractured and infected.

**Fig. 4\_**Use of Osteo Safe.

**Fig. 5\_**Complete Osteo Safe Kit.

**Fig.6\_**Bone expansion (6a), positioning of the implant (6b) and choice of the healing screw (6c).



**Fig. 7\_Panoramic views:**  
(7a) Pre-op, (7b) Post-op,  
(7c) three months,  
(7d) follow-up at one year.

**Fig. 8\_Control at six months.**

**Fig. 9\_Case No. 2.**  
Pre-operative view of  
fistula on #24.

**Fig. 10\_Panoramic view with**  
gutta-percha cone inserted in  
the fistula that reaches  
the apex.

the cortical bone is very thin. The lamina dura, which enables the attachment of collagen and Sharpey's fibres, presents a high potential for contamination. Consequently, a light manual curettage of the socket was carried out, followed by a superficial debridement (vaporisation) of the entire "lamina dura" with an Erbium laser (2,870 nm) followed by decontamination with a diode laser (940 nm).

This was a flapless surgery. The expansion osteotomy was performed through the inter-radicular septum. It was initiated with a very thin manual bone tap (pointed), and then an automatic mechanical osteotome (Figs. 4, 5) (Osteo Safe® Anthogyr) was used. The use of convex inserts in the beginning enables lateral expansion of the native or healed bone, and then concave inserts during the breaking of the last sub-sinus millimeter enables lateral bone recovery of this bone socket while projecting it apically.

During sinus progression, PRF membranes (or native collagen membranes) are placed in the osteotomy opening to fill the intra-sinus space that is thereby gained (they also provide protection of the sinus membrane).

The Erbium laser is again passed through the osteotomy socket to vaporize the bone debris and sludge along the walls of this osteotomy. The implant is placed according to the manufacturer's recommen-

dations but with an even slightly higher torque if the titanium grade so allows. A healing screw that fits the diameter and height of the residual gap to be closed is carefully chosen (Fig. 6).

If the healing screw does not enable primary closure of soft tissue, PRF membranes are used to fill the gap. If this gap is too big, a mucoperiosteal detachment of 6-10 mm and then a horizontal incision of the periostium of 6-8 mm are made. This technique serves to pull the gum around the healing screw by maintaining it with two sutures. The control X-rays clearly showed good osseointegration of the implant, significant filling and regeneration in only three months, and then perfect filling and regeneration four months after surgery.

The bone remodeling around and above the implant neck also seemed to be well executed. The cone-beam 3-D imaging in the first place showed a healthy sinus without inflammation or infection as well as bone remodelling at the apex and around the implant (Figs. 7, 8).

In the case of a trans-alveolar sinus lift combined with the placement of an implant by bone expansion, convex-tipped inserts should be used first to enable lateral expansion, and then concave inserts enable scraping of the bones of the lateral walls of the osteotomy to enable apical projection after breaking the



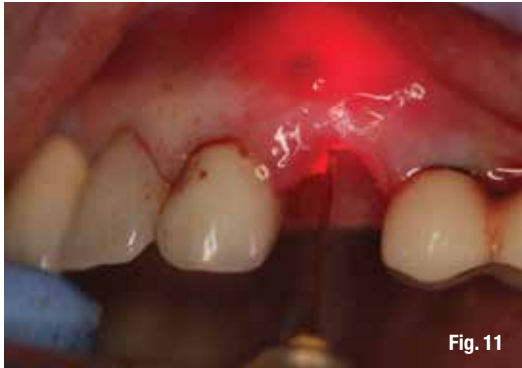

Fig. 11

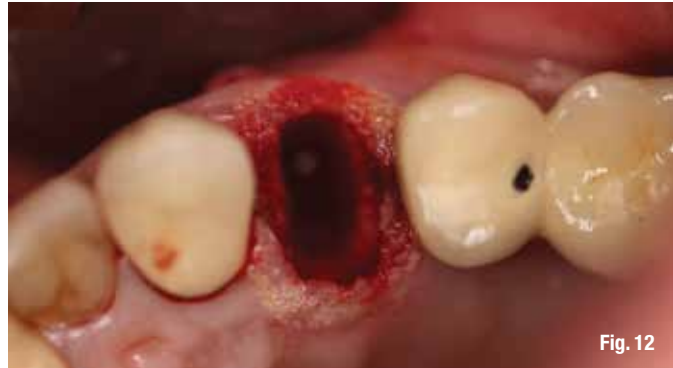

Fig. 12

last millimeter under the sinus floor. If a maxillary implant is to be placed completely in native bone, convex inserts suffice. The last insert that is placed is smaller in diameter than the implant that is chosen.

The advantage of this technique was noted starting in 1996 by Summers himself with the use of conical osteotomes as opposed to cylindrical osteotomes, which were all that were available up until then. The idea was actually to enable lateral peri-implant bone condensing in order to increase notably the primary stability and compensate for the lack of vertical dimension of the sub-sinus native bone.

The objective of this technique is to maintain, if possible, the entire maxillary bone by laterally pushing back the bone with minimal trauma while creating a precise osteotomy that breaks the last millimeter of the sinus floor while protecting the sinus membrane. The consequence is the notable increase in peri-implant bone density with a high elevation of BIC (bone implant contact) and, therefore, bone stability.

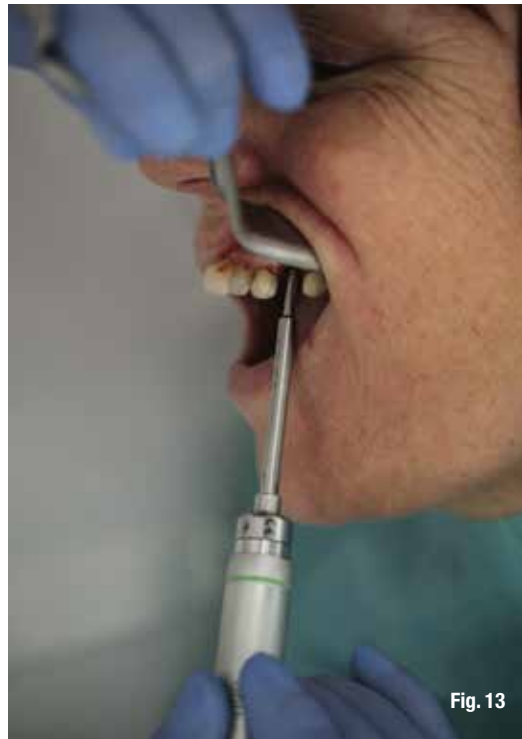

Fig. 13

Fig. 11\_Laser decontamination.

Fig. 12\_Laser degranulation.

Fig.13\_Use of Osteo Safe in the extraction socket after debridement and decontamination.

## \_Case No. 2

The patient presented with a fracture of #24 with significant periapical infection (Figs. 9,10).

It was decided that an extraction would be performed with immediate placement and loading of an implant after complete decontamination of the extraction socket using lasers (Figs. 11, 12). Next, Osteo Safe was used (Fig. 13) to enable gentle trabecular expansion and placement of a self-tapping conical implant (Axiom PX® Anthogyr).

In this case, where bone recovery along the osteotomy walls was not necessary, only convex inserts were used. The palatal and subcrestal position of the implant is respected (Fig. 14). The gap between the implant and the vestibular cortical bone is not filled. Careful choice of the implant abutment enables an ideal emergence both in terms of hard tissue and soft tissue. The temporary crown is thereby shaped in such a way that it closes the gap by slightly compressing the marginal gum (Fig. 15).

It is mounted out of functional occlusion. Of course, the patient was advised to avoid voluntary chewing on this implant and only use local cleaning with cotton soaked in Chlorhexidine.

Following verification of the osseointegration (Fig. 16), the impression was made eight to 10 weeks after surgery, followed by placement of the permanent prosthesis (Fig. 17).

## \_Conclusion

The implant placement technique with the use of osteotomes is not a new concept. On the other hand, using an automatic osteotome provides a better view of the site and makes it possible to practice flapless surgery, to position more precisely and obtain more homogeneous progression, in comparison to using bone taps with a surgical mallet. From the patient's perspective, surgical comfort is significant and very noticeable.

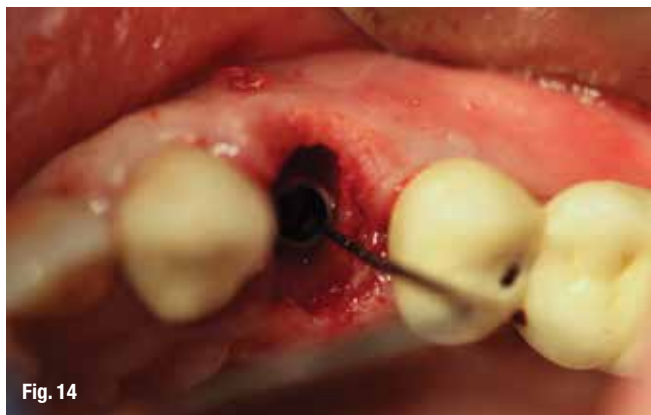

Fig. 14

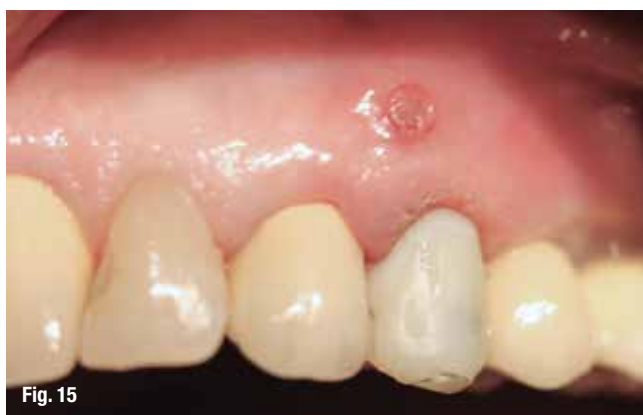

Fig. 15

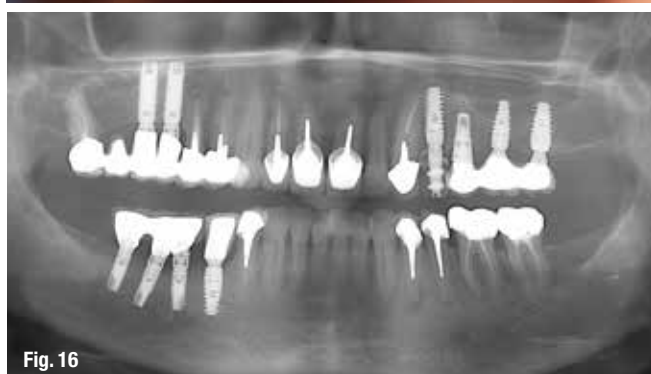

Fig. 16

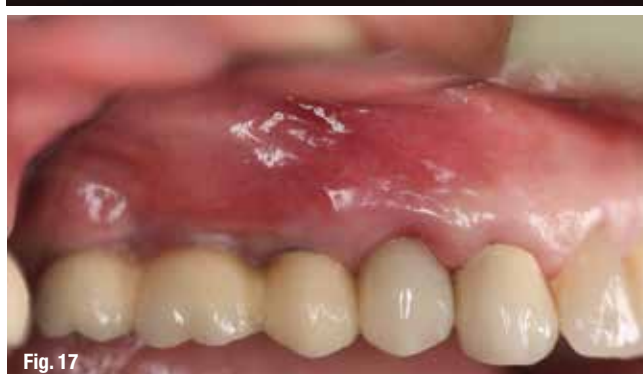

Fig. 17

**Fig. 14\_**Positioning of the implant.

**Fig. 15\_**Immediate implant placement with temporary crown.

**Fig. 16\_**Control panoramic view at two months.

**Fig. 17\_**Permanent crown at three months.

It should be kept in mind that if you want to avoid using filling materials, tissue must be conditioned to enable its regeneration. For immediate post-extraction implant placement, lasers are of unrivalled usefulness because they enable socket decontamination and induce bone regeneration. If the basic principles of this bone regeneration are respected, the conditions are adequate enough to enable bone growth without the use of biomaterials.

These advantages are decisive during preparations such as alveolar sinus lifts as well as "split crest" where the buccal cortical bone is generally very fragile.

Vital importance is attributed to the closure of soft tissue during implant placement, either by carefully choosing the healing screw (the height and diameter) or the implant abutment, enabling slight compression of soft tissue and providing the implant/prosthetic connection system with a "barrier" that enables the regeneration of the two families of tissues.

These minimally invasive techniques still require many improvements and more widespread validation. However, for ethical and safety reasons, the practitioner should always suggest the least invasive technique that contributes to, guides and induces this tissue regeneration for which, most of the time, we have the matrix around these traumatized zones.

*References are available upon request from the publisher.*

## \_about the author

Dr. Gilles Chaumanet graduated from the University of Nantes in 1983. He has worked in more than 15 different countries on four continents. Since 2000, the practice of laser in his field has



revolutionized his procedures. His practice is limited to oral surgery and implantology in Paris and Verona, Italy. He holds different masters and post-graduates in laser, periodontology, implant therapy, oral surgery, anatomy and radiology. He is president of SOLA France (Society for Oral Laser Application), ambassador of Global Oral Implant Academy (GOIA), active member of CENALOS, member of French Society of Medical Laser (SFLM), member of International Academy of Periodontology (IAP), member of Italian Society of Oral Surgery (SICO) and member of AGLZ Academy. He lectures widely in Europe, America and the Middle East. He is in private practice in Villeneuve-Loubet (France) and Verona (Italy). To learn more, visit [www.drchaumanet.com](http://www.drchaumanet.com).



# STRUGGLING TO STAY AFLOAT?

DEBT

INSURANCE

## FIND OUT WHY LVI IS YOUR LIFE SAVER.

Register Now For CORE I **Advanced Functional Physiologic Dentistry**

888.584.3237 • [www.lviglobal.com](http://www.lviglobal.com) • [concierge@lviglobal.com](mailto:concierge@lviglobal.com)



Approved PACE Program Provider  
FAGD/MAGD credit. Approval does  
not imply acceptance by a state or  
provincial board of dentistry or AGD  
endorsement. 06-01-15 to 5-31-19.  
Provider ID# 208412

**CHANGING DENTISTRY.  
CHANGING LIVES.**

Las Vegas Institute for Advanced Dental Studies, LVI Global  
is an ADA Recognized Provider  
ADA CERP is a service of the American Dental Association  
to assist dental professionals in identifying quality providers  
of continuing dental education. ADA CERP does not approve  
or endorse individual courses or instructors, nor does it imply  
acceptance of credit hours by boards of dentistry.  
Concerns or complaints about a CE provider may be  
directed to the provider or to the Commission for Continuing  
Education Provider Recognition at [ADA.org/CERP](http://ADA.org/CERP).  
**ADA CERP** Continuing Education  
Recognition Program