

DENTAL TRIBUNE

The World's Dental Newspaper • Middle East & Africa Edition

PUBLISHED IN DUBAI

www.dental-tribune.me

March-April 2019 | No. 2, Vol. 9

ENDO TRIBUNE

Minimally invasive root canal shaping – A new protocol

►A1-4

LAB TRIBUNE

Cherry on top in complete denture prosthetics: individuality and naturalness

►B1-4

HYGIENE TRIBUNE

Interview: World Oral Health Day with FDI President Dr Kathryn Kell

►C1-4

IMPLANT TRIBUNE

Digitalisation of the gold standard of implantology

►D1-4

ORTHO TRIBUNE

Interview: "Our practice has doubled since implementing the Insignia system..."

►E1-8

IDS reaffirms its leading position as global dental trade fair

See the latest innovations at the 14th CAD/CAM & Digital Dentistry Conference & Exhibition on 12-13 April 2019 in Dubai, UAE

By Dental Tribune International

COLOGNE, Germany: The International Dental Show (IDS), which took place in Cologne from 12 to 16 March, fulfilled the high expectations of the global industry and once again underlined its position as the leading trade fair. With 2,327 companies from 64 countries participating, this year's event welcomed 20 more exhib-

itors compared with two years ago, as well as 160,000 trade visitors from 166 countries. The overall number of visitors rose by 3.2 per cent (about 5,000 more people) and the number of foreign trade visitors by 6.0 per cent.

Gerald Böse, CEO of Koelnmesse, which stages the show, said: "IDS is a trade fair in a class of its own and always sets new benchmarks. It

AD

NextDent
by 3D SYSTEMS

middle east
3D PRINTING THE FUTURE

Multi-Award Winning

3D Printing Industry Awards 2019
Best of Class Technology Award 2019

Redefining Digital Dentistry

Visit us at IDS 2019 Hall 4.1-booth F-098
IDS 2019 12.-16.3.2019

Visit us at Booth 41 at 14th CAD/CAM Digital Dentistry Conference CAPP 12-13.04.2019

NextDent™ 5100

High-speed dental 3D Printer revolutionizing dental applications with NextDent biocompatible materials

- Denture 3D+**
3D print resin for the manufacturing of removable denture bases
- C&B MFH**
Micro filled hybrid 3D print resin for the manufacturing of long-term temporaries
- Try-In**
3D print resin for the manufacturing of try-in devices
- Tray**
3D print resin for the manufacturing of individual impression trays
- SG (Surgical Guide)**
3D print resin for the manufacturing of dental surgical guides
- Model 2.0**
3D print resin for the manufacturing of prosthodontic and orthodontic models
- Gingiva Mask**
3D print resin for the manufacturing of gingiva masks on dental models
- Ortho Rigid**
3D print resin for the manufacturing of dental splints
- Ortho IBT**
3D print resin for the manufacturing of indirect bonding trays
- Cast**
3D print resin for the manufacturing of castable parts

3D SYSTEMS
DISTRIBUTOR | Middle East & North Africa

www.3d-me.com | +97144433938 | info@3d-me.com | Facebook.com/3dMiddleEast



The 2019 International Dental Show exceeded the results of the previous event and the organisers attained their goals of greater internationality and higher quality in supply and demand, boosting the satisfaction of both exhibitors and attendees.

manages to surpass the already excellent results of the previous event every time." Both visitors and exhibitors are impressed by IDS: it is only here that one encounters supply and demand of such an extent, quality and level of internationality. "IDS is the undisputed leading global trade fair for the dental industry," he continued.

The official figures confirm the high level of internationality at IDS: 73 per cent of the exhibitors and 62 per cent of the visitors came from 166 foreign countries, including Argentina, Australia, Brazil, Canada, Chile, Egypt, Japan, Korea, New Zealand, South Africa and the US. Regarding the 6 per cent increase in foreign visitors, IDS 2019 recorded significant growth in the number of visitors from Asia (+23.1 per cent), eastern Europe (+19.6 per cent), Africa (+17.0 per cent), Central and South America (+14.6 per cent) and North America (+5.3 per cent) specifically.

An independent visitors' survey reported that the largest groups of visitors came from the dental industry. Schools and universities were strongly represented too. Almost 80 per cent of those who completed the survey stated they were satisfied or highly satisfied with the range of exhibition offerings. More than 93 per cent said that they would recommend visiting IDS, and 70 per cent of the respondents were already planning to visit the next IDS, in 2021.

Dr Markus Heibach, Executive Director of the Association of the German Dental Industry, which is involved in organising the event, was also pleased with the outcome of the trade fair:



The 2019 International Dental Show exhibition

"The high level of satisfaction of our trade visitors and exhibitors is for us impressive confirmation of our efforts to make our guests' stay as pleasant and successful as possible by offering them a cosmopolitan, hospitable and perfect service."

IDS offered the ideal business platform, especially for new companies on the dental market seeking to establish themselves with high-quality innovations, such as those for improved digital workflows and additive production, new prophylactic formulas and filling materials, pioneering intra-oral scanners and implant designs, as well as flexible workflows for management of the laboratory.

The 39th IDS is scheduled to take place from 09 to 13 March 2021. [DT](#)

Interview: "...for us it is important to improve the day-to-day work in practices and labs..."

By Dr Dobrina Mollova, DTMEA

Dr Dobrina Mollova from Dental Tribune Middle East & Africa interviewed Dr Frank Thiel, Vice President Global Research and Development CAD/CAM and Orthodontics at Dentsply Sirona at the Product Launch & Press Conference 2019 in Frankfurt, Germany on the 1st of February 2019.

Dr. Frank Thiel, you began working in the CAD/CAM business unit at Dentsply Sirona 15 years ago. At around that same time, the Centre for Advanced Professional Practices (CAPP) organised the first CAD/CAM and Digital Dentistry Conference and Exhibition in Dubai. Could you share your first experience with CAD/CAM and digital dentistry and your views on its significance today with our readers for the upcoming 14th year of this conference and exhibition?

Digital technologies and CAD/CAM systems in dentistry have undergone a long development. At Dentsply Sirona, we consider ourselves pioneers in this field, as we introduced CEREC to the market more than 30 years ago. Through our own initiative and further development of both the hardware and the software, we were responsible for making intraoral scanners popular in the first place. We have always been convinced that digital impressioning is the way forward.

Now, digital impressions are widely accepted, and competition has become stiffer. So this makes us even prouder that we are able to bring a solution to the market that underscores our pioneering spirit and allows us to provide a solution to an important issue in practices – faster, precise impression taking – which is easy to manage in the usual practice environment, which is reliable, which delivers clinically flawless results, and which is simply fun to use.

And since you asked about the significance of digital technologies in dentistry – for us it is important to improve the day-to-day work in practices and labs. Digital technologies help us do this by enabling predictable treatment outcomes for many indications. Of course, the competence and skill of dentists and dental technicians will always be important – with our solutions, we want to satisfy both the practitioner and the patient and ensure sustainable success.

Dentsply Sirona is starting a new era in digital dentistry with the introduction of the new intraoral scanner Primescan. What makes this product a technological milestone and how will Primescan change how dentists work? Is it correct that Primescan is easier, faster, and more accurate than any other intraoral scanner on the market? Why is that?

Primescan is an intraoral scanner that perfects digital dentistry. We base this on four important points: (1) A scan made with Primescan is extremely accurate. Up to 1 million 3D data points are captured per second. With optical high-frequency contrast



VISIT
DENTSPLY SIRONA
AT 14TH CAD/CAM &
DIGITAL DENTISTRY
EXHIBITION
DUBAI, UAE
12-13 APRIL 2019



Dr Frank Thiel, Vice President Global Research and Development CAD/CAM and Orthodontics at Dentsply Sirona

analysis, they can now be calculated more accurately than ever before. A recent study by Prof. Albert Mehl from Zürich confirms that Primescan yields by far the best results with respect to accuracy and precision of 3D measurements. With such a high level of accuracy, you can produce precisely fitting restorations without needing to rework them.

(2) Scans can be made very quickly with Primescan. Upper and lower jaws can be scanned in less than one minute, including bite. The data is calculated rapidly and displayed on the monitor in high resolution. Practitioner and patient benefit equally from this speed.

(3) Primescan is very easy to handle and can be quickly learned. Users do not need to follow a prescribed scanning protocol, but can scan intuitively and rescan certain areas easily and quickly. The touch interface makes the software easy to use. Artificial intelligence results in a high level of automation of the individual processes.

(4) There is a very good hygiene solution for Primescan. All surfaces are smooth and easy to clean. Primescan is an intraoral scanner that can be subjected to all necessary hygienic reprocessing (wipe disinfection, autoclaving, hot air sterilisation, high-level disinfection). This is made possible by three sleeve concepts (stainless steel sleeve, stainless steel sleeve with disposable window, disposable sleeves).

For this reason, we think that we have an absolute premium product that really offers more than other intraoral scanners.

Does the new product have the flexibility and freedom to be used in addition to filling material in various dental treatments? What kind of treatments?

You are asking about what indications Primescan can be used for. Our testers answered, "While we used to ask what indications it could really be used for, today we ask what can it not be used for?" And in fact, the range of indications makes Primescan a special intraoral scanner. Examples include conventional restorations, such as crowns and bridges, inlays

and onlays, and there is also the option of supporting implant planning with an intraoral scan and the corresponding restoration proposal – you can plan the outcome.

Primescan scans to a depth of up to 20 millimeters. Is Primescan more than just an intraoral scanner and if so, why?

In the past, dentists were justified in questioning the scanning quality when the patient has quite long crowns or the dentition has exposed root areas. These difficult-to-reach places can easily be captured with Primescan, without the user having to make too much effort with the scanner. This is a real advantage.

Does Primescan fulfill the dream of a precise full arch scan?

The study at the University of Zürich I mentioned before showed that Primescan also had the best results with respect to the accuracy of full arch scans. The scan requires no more effort than with partial arch scans.

All processes that use Primescan are validated. Why is that so special?

The entire system has been extended by validated interfaces to external partners. Validation makes the system so special – users are assured that the transmission will be implemented completely and securely. The respective portals can also be reached with just a few clicks.

This is special because most dentists do not want to have to deal intensively with interfaces or with data transmission technology in general. They want it to work quickly, reliably, and at any time. Predictable, reproducible. This is exactly what we offer with our internal interfaces (seamless) and the validated processes with our partners. In addition, there is still the option of an open STL export.

Are you convinced that Primescan is the starting point for other digital processes in dentistry? Why?

We just touched on this briefly before – the range of indications for 3D intraoral scanners is now wider than ever before. We still see a lot of potential especially in orthodontics and implantology.

The question of conventional versus digital impressions has been discussed for more than 30 years. Where are we today?

We already know that digital impressions are at least as good as conventional ones and also deliver very good clinical results. This has been substantiated in studies. It has never been easier for dentists to choose digital impressions. Therefore, our aim is to develop digital impressions into the preferred process because they have many advantages for everyone involved – for dentists, their partners, and the patients. Discussions with our customers have revealed that, besides the many technical advantages of scanning, it is also a whole lot of fun.

What feedback on Primescan have you had from customers regarding user friendliness and hygienic safety?

The initial feedback from users has made us very optimistic. We have received a lot of compliments for the usability and convenience, which is also experienced by the patients. We have also heard that the hygienic safety of Primescan is perceived very positively.

What might your customers expect from you in the near future regarding the development in the area of digital dentistry?

For digital processes, many things are certainly possible. I addressed monitoring previously. With Primescan, there is no effort required for progress monitoring, for example, to see whether and how the teeth have moved since the last check and how the gums have changed. All of this can be documented easily and reliably.

The second point is artificial intelligence. The intraoral scan yields a lot of useful data from which to develop solutions, for instance to specifically optimise treatment workflows. We already use learning algorithms in our programs today, and this will be increased even more in the future of digital dentistry. In any event, Primescan is a fundamental step in this direction. [DT](#)

IMPRINT

**PUBLISHER/
CHIEF EXECUTIVE OFFICER**
Torsten R. OEMUS

CHIEF FINANCIAL OFFICER
Dan WUNDERLICH

DIRECTOR OF CONTENT
Claudia DÜSCHEK

CLINICAL EDITORS
Nathalie SCHÜLLER
Magda WOJTKIEWICZ

EDITOR & SOCIAL MEDIA MANAGER
Monique MEHLER

EDITORS
Franziska BEIER
Brendan DAY
Luke GRIBBLE
Kasper MUSSCHE

COPY EDITOR
Ann-Katrin PAULICK
Sabrina RAAFF

**BUSINESS DEVELOPMENT & MARKETING
MANAGER**
Alyson BÜCHENAU

DIGITAL PRODUCTION MANAGER
Tom CARVALHO
Hannes KUSCHICK

PROJECT MANAGER ONLINE
Chao TONG

IT & DEVELOPMENT
Serban VERES

GRAPHIC DESIGNER
Maria MACEDO

E-LEARNING MANAGER
Lars HOFFMANN

EDUCATION & EVENT MANAGER
Sarah SCHUBERT

**PRODUCT MANAGER SURGICAL TRIBUNE
& DDS, WORLD**
Joachim TABLER

SALES & PRODUCTION SUPPORT
Puja DAYA
Hajir SHUBBAR
Madleen ZOCH

EXECUTIVE ASSISTANT
Doreen HAFERKORN

ACCOUNTING
Karen HAMATSCHEK
Anita MAJTENYI
Manuela WACHTEL

EXECUTIVE PRODUCER
Gernot MEYER

ADVERTISING DISPOSITION
Marius MEZGER

DENTAL TRIBUNE INTERNATIONAL
Holbeinstr. 29, 04229 Leipzig, Germany
Tel.: +49 341 48 474 302
Fax: +49 341 48 474 173
www.dental-tribune.com
info@dental-tribune.com

DENTAL TRIBUNE ASIA PACIFIC LTD.
Room A, 20/F
Harvard Commercial Building
105-111 Thomson Road, Wanchai, HK
Tel.: +852 3113 6177
Fax: +852 3113 6199

THE AMERICA, LLC
116 West 23rd Street, Ste. 500, New York
N.Y. 10011, USA
Tel.: +1 212 244 7181
Fax: +1 212 244 7185

**DENTAL TRIBUNE MEA EDITION EDITORIAL
BOARD**

Dr. Aisha SULTAN ALSUWAIDI, UAE
Prof. Paul TIPTON, UK
Prof. Khaled BALTO, KSA
Dr. Ninette BANDAY, UAE
Dr. Nabeel HUMOOD ALSABEEHA, UAE
Dr. Naif Almosa, KSA
Dr. Mohammad AL-OBAIDA, KSA
Dr. Meshari F. ALOTAIBI, KSA
Dr. Jasim M. AL-SAEEDI, Oman
Dr. Mohammed AL-DARWISH, Qatar
Dr. Dobrina MOLLOVA, UAE
Dr. Ahmed KAZI, UAE
Dr. Munir SILWADI, UAE
Dr. Khaled ABOUSEADA, KSA
Dr. Rabih ABI NADER, UAE
Dr. Ehab RASHED, UAE
Aiham FARRAH, CDT, UAE
Retty M. MATTHEW, UAE

PARTNERS

Saudi Dental Society
Saudi Ortho Society
Lebanese Dental Association
Lebanese Orthodontic Society
Qatar Dental Society
Oman Dental Society
Kuwait Dental Association
American Academy of Implant Dentistry
International Federation of Dental Hygienist
British Academy of Restorative Dentistry
British Academy of Dental Implantology
AALZ - Aachen Dental Laser Center
Singapore Dental Association

DIRECTOR OF mCME
Dr. Dobrina MOLLOVA
mollova@dental-tribune.me
Tel.: +971 50 42 43072

DIRECTOR
Tzvetan DEYANOV
deyanov@dental-tribune.me
Tel.: +971 55 11 28 581

PRINTING HOUSE & DISTRIBUTION
Al Nisr Printing
P. O. Box 6519, Dubai, UAE
800 4585/04-4067170

©2018, Dental Tribune International GmbH. All rights reserved. Dental Tribune International makes every effort to report clinical information and manufacturer's product news accurately, but cannot assume responsibility for the validity of product claims, or for typographical errors. The publishers also do not assume responsibility for product names or claims, or statements made by advertisers. Opinions expressed by authors are their own and may not reflect those of Dental Tribune International.

» Accuracy is what I want.
And Primescan is my answer.«

Martin Wohanka, Hardware Engineer



Primescan

Engineered for superior performance.

Innovation requires commitment to ambition: Primescan sets new standards in dental technology, making scanning more accurate, faster and easier than ever. It is engineered to enable all kind of treatments, from single tooth to full arch. Due to the innovative Smart Pixel Sensor, Primescan processes more than 1.000.000 3D points per second and therefore produces highly accurate and photorealistic data with great dimensional depth – even for very steep surfaces. With Primescan, intraoral scanning is as accurate as never before.

Enjoy the scan.

Learn more at: dentsplysirona.com/primescan

Overcoming the myths of bulk fill composite materials

Bulk fill composite materials were introduced for restorations more than a decade ago; however, many dentists were reluctant to try them due to the limitations and performance of earlier bulk filling materials.

By 3M Oral Care

In addition, most dentists were trained to use incremental filling materials that require a layering technique in order to minimize stress/shrinkage; achieve proper adaptation and eliminate voids; and achieve proper depth of cure. Because of this, many dentists find it difficult to trust or incorporate bulk fill materials that seemingly contradict their training.

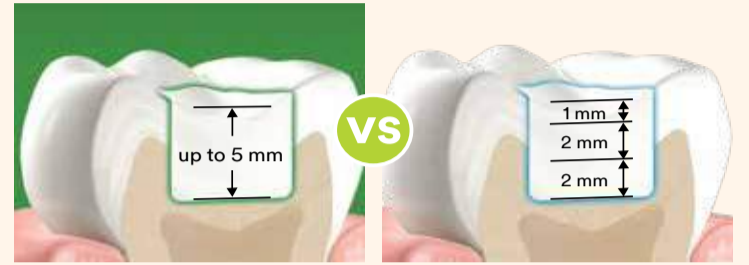
Older composite resin chemistries feature monomers that need to be

layered in 2 mm increments to minimize shrinkage. This traditional layering technique requires more steps and means dentists spend more time working in a patient's mouth.

Using a traditional layering technique requires multiple steps of packing, layering, and curing, which could increase the potential for voids and/or poor adaptation with each layer. The amount of time that this layering technique requires could also increase the potential to introduce contamination from blood or saliva.

"Since the introduction of bulk fill materials, a significant amount of technology has been dedicated to addressing shrinkage stress, but depth of cure issues persisted for some time," says 3M Advanced Product Development Specialist Tim Dunbar, Ph.D. "Significant advances in materials science and chemistry in the past decade enable more translucent composites that allow curing light to penetrate to a depth of 5 mm with low shrinkage stress."

3M™ Filtek™ One Bulk Fill Restorative is designed for the posterior so dentists don't need to sacrifice wear resistance, strength



and handling. It also has opacity equivalent to many typical universal composite materials used today, so dentists don't need to sacrifice esthetics while working quickly and efficiently.

Unfortunately, despite the great advances made over the last few years,

myths about bulk fill materials continue to persist. Let's take a closer look at the science of Filtek One Bulk Fill Restorative – and break down the myths of bulk fills. [DT](#)

MYTH 1

Bulk fill materials are not aesthetic enough (too translucent).

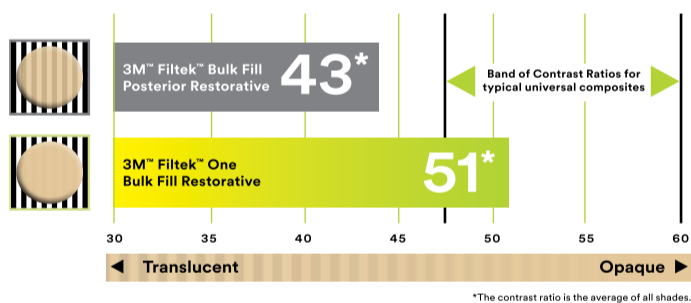
In the past, bulk fill materials needed a relatively high amount of translucency (low opacity) in order to fully cure in a 4-5 mm increment. The concept is quite simple – if the composite needs to cure all the way through 4-5 mm of material, then it needs to allow the light to penetrate to a greater degree.

In the decade or so since the introduction of the first bulk fill composites, the field of materials science has exploded. Research and development efforts in the past 5-10 years have yielded bulk fill composites that

no longer require a choice between fast and effective depth-of-cure and esthetics. 3M designed Filtek One Bulk Fill Restorative with unique optical properties and improved opacity to provide the simplicity of one-step placement up to 5 mm, without compromising esthetic results.

3M leveraged its nanotechnology expertise to increase opacity without reducing depth of cure. In its cured state, Filtek One Bulk Fill Restorative has a higher opacity than other leading bulk fill restoratives, resulting in improved esthetics. 3M's nanofiller technology also provides superior wear resistance and excellent polish retention.

Contrast Ratio



MYTH 2

It's necessary to layer bulk fill materials in order to minimize stress/shrinkage.

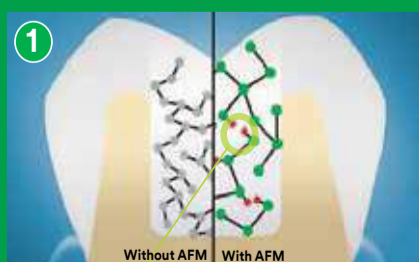
Stress is the amount of force exerted on a tooth due to polymerization shrinkage as it cures. This stress can break the adhesive bond, crack enamel and allow leakage at the margins. The amount of stress is determined by the shrinkage of the material and its stiffness.

3M™ Filtek™ One Bulk Fill Restorative exerts less or equivalent stress on a tooth than some common incrementally placed universal composites, because it uses two new

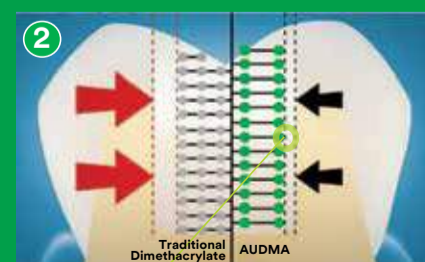
resin components to reduce polymerization stress.

One resin component is an addition-fragmentation monomer (AFM). During polymerization, the central group can fragment to relieve stress and the fragments can then re-polymerize in a lower stress state.

The other resin component is aromatic urethane dimethacrylate (AUDMA). Because this is a larger monomer than found in traditional dimethacrylates, it limits the number of shrinkage zones. This helps reduce the amount of shrinkage and stress that occurs during polymerization.



The innovative component of the first resin is an addition-fragmentation monomer (AFM). The unique feature of this resin is that, during polymerization, the central group can fragment to relieve stress. The fragments can then re-polymerize in a lower stress state.



The other resin component is aromatic urethane dimethacrylate (AUDMA). Because it's a larger monomer than found in traditional dimethacrylates, it limits the number of shrinkage zones. That helps reduce the amount of shrinkage and stress that occurs during polymerization.



MYTH 3

It's necessary to layer filling materials in order to achieve proper adaptation and eliminate voids.

For many decades, the incremental placement of composite has been the prevailing technique, in part because this was thought to minimize the potential for introducing voids. However, studies have shown that the opposite is true when compared to using an effective bulk fill composite.

Extruding 3M™ Filtek™ One Bulk Fill Restor-

ative material out of its newly designed unit dose capsule creates the necessary conditions for shear thinning. This means the viscosity of the material temporarily decreases and the material flows into the cavity prep, resulting in excellent adaptation, as well as fewer defects (voids).

In an in-vitro simulated operatory test with 79 dentists, restorations placed with Filtek One Bulk Fill Restorative in 5 mm deep class II cavities had fewer defects compared to restorations made using incrementally placed composites.

MYTH 4

A bulk fill placed in a 5 mm increment won't achieve the proper depth of cure.

Methacrylate-based dental composites have the ability to achieve a very high depth-of-cure, but this has often come at the price of lowered opacity/esthetics (see myth 1). In order to achieve a high depth-of-cure while maintaining a tooth-like opacity, we must look at the interaction of light between the filler particles and the matrix.

If the optical properties (refractive index) of the filler and matrix do not match closely, light is scattered within the composite resulting in higher opacity. This will limit the depth of penetration of the curing light to effectively enable bulk curing. If the optical properties match closely, light penetrates more effectively without the scattering resulting in more translucency. This will allow for greater penetration of the curing light and allow for bulk curing. Traditionally, this resulted in more translucent restorations.

By manipulating the base chemistry that controls this behavior, we can control the

stages at which the material looks opaque and translucent. The end result is a composite with the depth-of-cure required for bulk placement, and a final opacity that is closer to the natural tooth.


3M™ Filtek™ One Bulk Fill Restorative utilizes the science described above to achieve a uniform cure even at the bottom of 5 mm cavity, without sacrificing esthetics.

"We have data and peer-reviewed literature that indicate 3M's bulk fill materials work as intended," says Senior Technical Service Engineer Joe Edgington. "Bulk fills have been around for 10 years and many concerns and challenges have been worked out thanks to advances in materials science and chemistry."

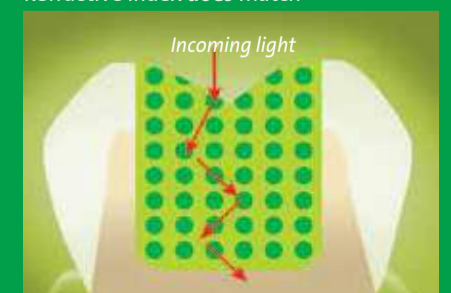
"With fewer defects, fewer voids, less chance of contamination, and less time than universal composites, dentists can make quality restorations with 3M's bulk fill composites," adds Dunbar.

For more information, contact your 3M Oral Care sales representative.

Refractive index does not match



Refractive index does match

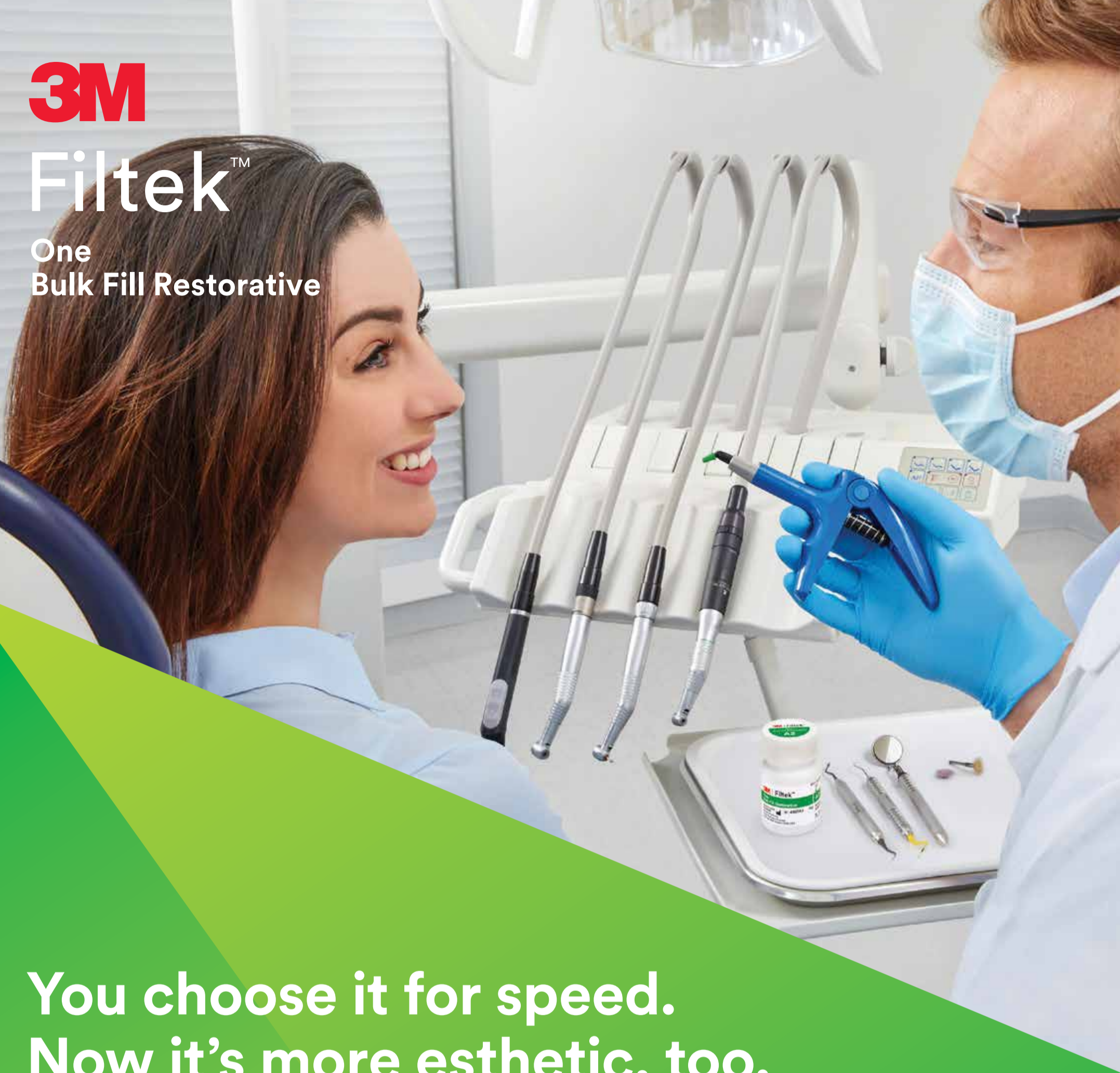

If the filler and the resin DO have matching optical properties (bottom diagram), as is the case with 3M™ Filtek™ One Bulk Fill Restorative, then the light will not be significantly bent, and the light will be successfully transmitted through the materials, which increases the material's depth of cure.

3M

Filtek™

One Bulk Fill Restorative

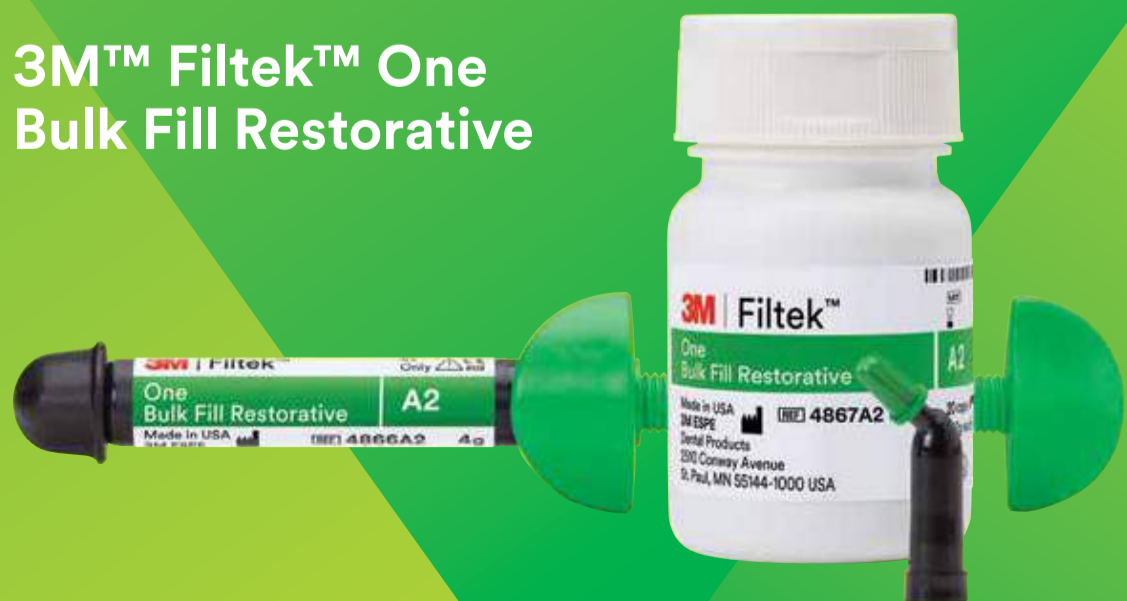

You choose it for speed. Now it's more esthetic, too.

You choose time-saving materials to be more efficient. But, as you know, while patients appreciate shorter appointments, their top concern when it comes to a restoration is how it looks—even in the posterior area. That's why 3M created 3M™ Filtek™ One Bulk Fill Restorative. Designed for posterior restorations, it gives you the simplicity and speed of bulk placement up to 5 mm ... without compromising esthetic results. Now efficient restorations can be esthetic, too.

www.3M.com

3M™ Filtek™ One Bulk Fill Restorative



3M and Filtek are trademarks of 3M or 3M Deutschland GmbH. Used under license in Canada. © 3M 2016. All rights reserved.

Intraoral welding and lingualised (lingual contact) occlusion: a case report

mCME articles in Dental Tribune have been approved by: DHA awarded this program for 1 CPD Credit Points

ADA C-E-R-P® Continuing Education Recognition Program
Centre for Advanced Professional Practices (CAPP) is an ADA CERP Recognized Provider. ADA CERP is a service of the American Dental Association to assist dental professionals in identifying quality providers of continuing dental education. ADA CERP does not approve or endorse individual courses or instructors, nor does it imply acceptance of credit hours by boards of dentistry.
CAPP designates this activity for 1 CE Credits

By Dr Luca Dal Carlo, Dr Franco Rossi, Dr Marco E. Pasqualini, Dr Mike Shulman, Dr Michele Nardone, MD, Dr Tomasz Grotowski and Dr Sheldon Winkler

Intraoral welding was developed by Pierluigi Mondani¹ of Genoa, Italy, in the 1970s to permanently connect submerged implants and abutments to a titanium wire or bar by means of an electric current (Fig. 1). The current is used to permanently fuse the titanium to the abutments in milliseconds, so the heat generated does not cause any pathology or patient discomfort.

If possible the implants are placed without flaps. The titanium wire or bar is bent and aligned passively to the contour of the labial and lingual surfaces of the implants before applying the electric current to permanently connect titanium implants.

The technique follows a strict surgical and prosthodontic protocol, which includes using a number of implants as close as possible to the number of teeth to be replaced, achieving primary stability by engaging both cortical plates (bicorticalism), immediate splinting of the implants utilizing intraoral welding and immediate insertion of a fixed provisional prosthesis with satisfactory occlusion. The technique provides for immediate loading and

does not jeopardize the integration process.²

Although intraoral welding has been used successfully in Europe, especially Italy, for many years, it has yet to achieve everyday use in the United States.

Members of the Italian affiliate of the American Academy of Implant Prosthodontics, NuovoGISI, have long and successful experiences with immediate loading of maxillary implants connected together by intraoral welding.²

By inserting the prosthesis with adequate retention and stability the same day as the surgery, patient complaints and discomfort can be avoided or substantially reduced. The instantaneous stability that results from the splinting can reduce the risk of failure during the healing period. Intraoral welding can also eliminate errors and distortions caused by unsatisfactory impression making, as the procedure is performed directly in the mouth.

Intraoral welding can fulfil a great need for business and socially active persons, as the surgical and prosthodontic procedures are accomplished on the same day. Patients can leave the dental office with a stable, esthetic and retentive prosthesis.

►Page 7

mCME SELF INSTRUCTION PROGRAM

CAPPmea together with Dental Tribune provides the opportunity with its mCME – Self Instruction Program a quick and simple way to meet your continuing education needs. mCME offers you the flexibility to work at your own pace through the material from any location at any time. The content is international, drawn from the upper echelon of dental medicine, but also presents a regional outlook in terms of perspective and subject matter.

Membership

Yearly membership subscription for mCME: 1,100 AED
One Time article newspaper subscription: 250 AED per issue. After the payment, you will receive your membership number and allowing you to start the program.

Completion of mCME

- mCME participants are required to read the continuing medical education (CME) articles published in each issue.
- Each article offers 2 CME Credit and are followed by a quiz Questionnaire online, which is available on www.cappmea.com/mCME/questionnaires.html.
- Each quiz has to be returned to events@cappmea.com in three months from the publication date.
- A minimum passing score of 80% must be achieved in order to claim credit.
- No more than two answered questions can be submitted at the same time
- Validity of the article – 3 months
- Validity of the subscription – 1 year
- Collection of Credit hours: You will receive the summary report with Certificate, maximum one month after the expiry date of your membership. For single subscription certificates and summary reports will be sent one month after the publication of the article.

The answers and critiques published herein have been checked carefully and represent authoritative opinions about the questions concerned.

Articles are available on www.cappmea.com after the publication. For more information please contact events@cappmea.com or +971 4 347 6747

FOR INTERACTION WITH THE AUTHORS FIND THE CONTACT DETAILS AT THE END OF EACH ARTICLE.

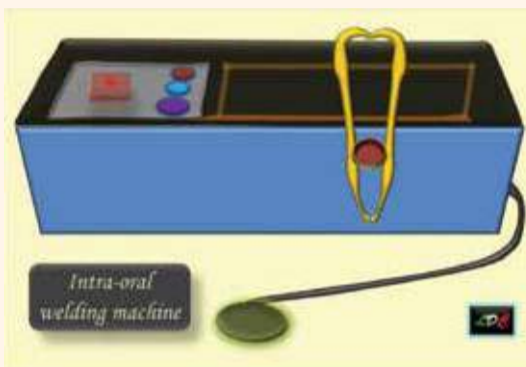


Fig. 1. Schematic drawing of Mondani intraoral solder unit

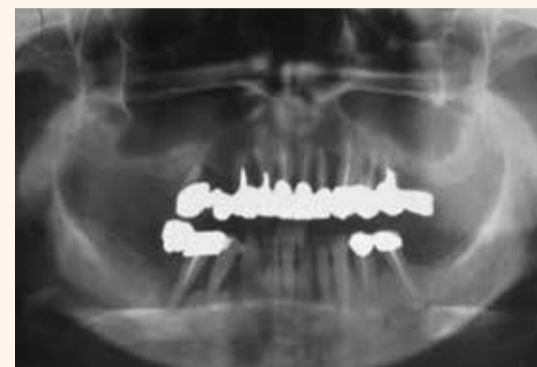


Fig. 2. Preoperative panoramic radiograph of 50-year-old caucasian woman

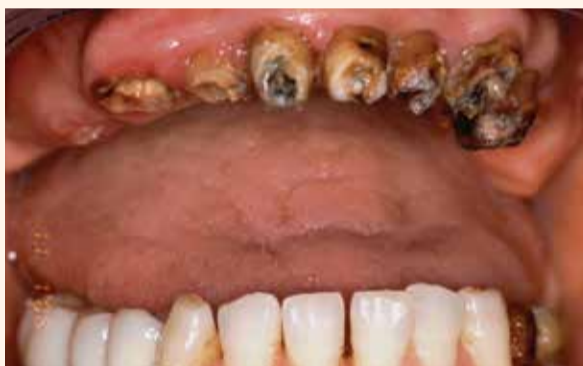

Fig. 3. Nonrestorable teeth visible after removal of the patient's prosthesis

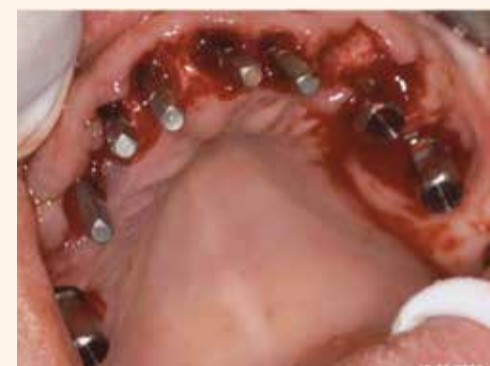

Fig. 4. Eight titanium one-piece implants are inserted.

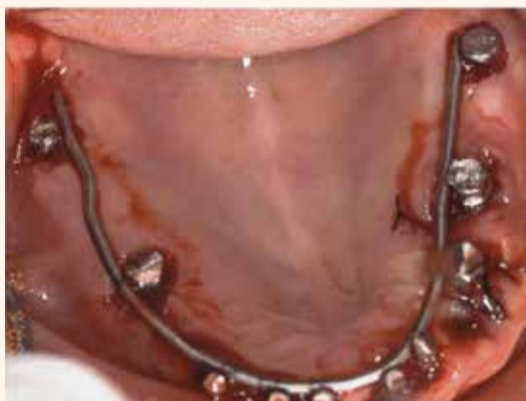

Fig. 5. Immediate stabilization of the eight implants and two additional implants previously inserted in the posterior regions, by welding each implant to a 1.5 mm supporting titanium bar

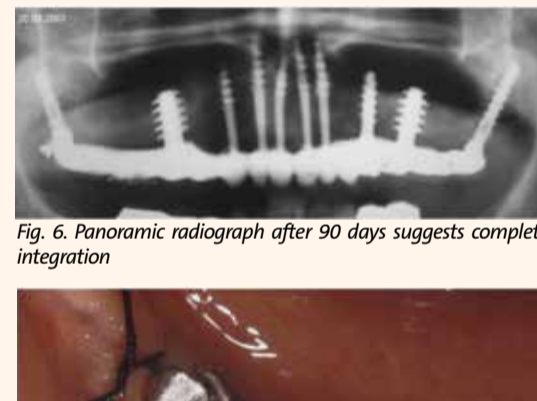


Fig. 6. Panoramic radiograph after 90 days suggests complete integration

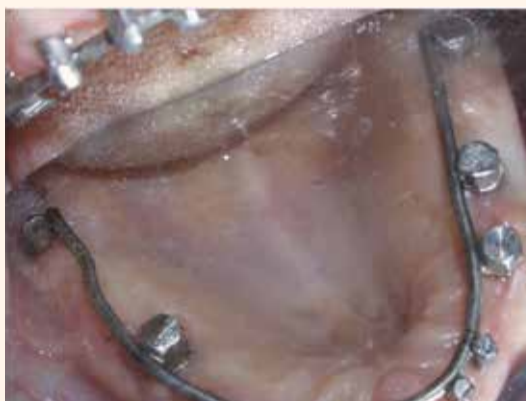

Fig. 7. Healthy gingiva was observed after 90 days

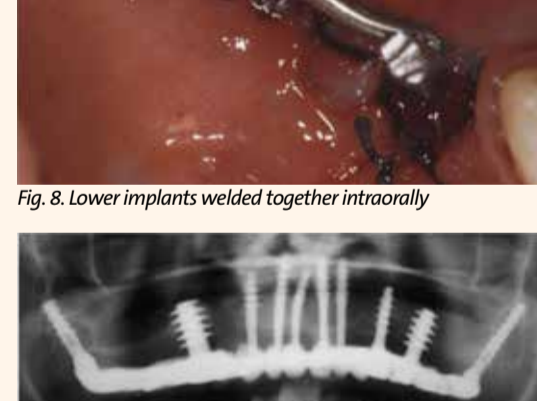


Fig. 8. Lower implants welded together intraorally

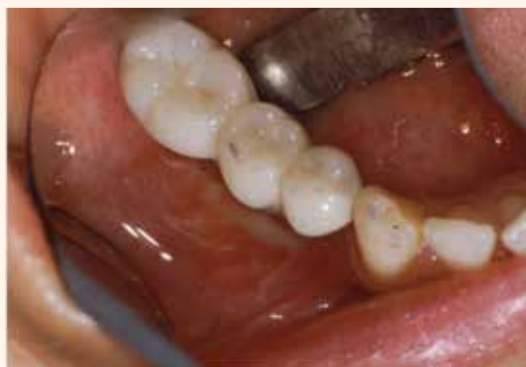

Fig. 9. Three-tooth mandibular fixed prosthesis

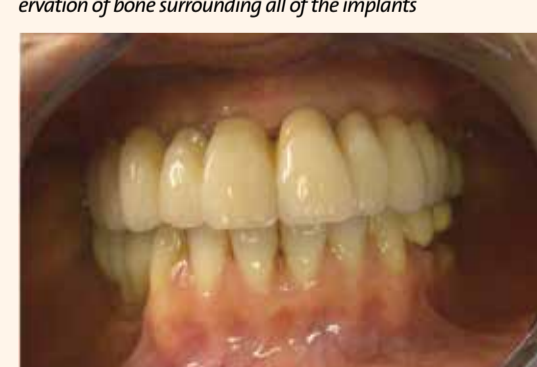

Fig. 11. Intraoral photograph of the definitive prosthesis shows healthy gingiva

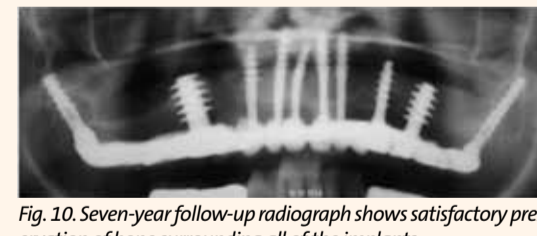


Fig. 10. Seven-year follow-up radiograph shows satisfactory preservation of bone surrounding all of the implants

◀Page 6

The flapless technique, first proposed by Tramonte³, can be performed when the bony crest is wide and an adequate amount of attached gingiva is present. The technique allows for uneventful healing, a reduction of postsurgical inflammation and only moderate inconvenience for the patient, who can eat efficiently the same day.

Provisional prosthesis and tooth arrangement

During the surgical session a temporary resin prosthesis is inserted. Occlusal plane height must be correct. A lingualized (lingual contact) scheme of occlusion is recommended. The upper anterior teeth are best arranged without any vertical overlap. The amount of horizontal overlap is determined by the jaw relationship. A vertical overlap for appearance can be used, provided that an adequate horizontal overlap is included to guard against interference within the functional range.⁴

Lingualized (lingual contact) occlusion

Lingualized (lingual contact) occlusion maintains the esthetic and food penetration advantages of anatomic teeth while maintaining the mechanical freedom of nonanatomic teeth. Among the advantages of a lingualized occlusion are occlusal forces centered over the ridge crest in centric occlusion, masticatory force is effectively transferred more "lingual" to the ridges during working side excursions, the "mortar and pestle" type of occlusion minimizes the occlusal contact area providing for more efficient food bolus penetration and elimination of the precise intercuspation that can complicate the arrangement of anatomic denture teeth.

Lingualized occlusion also prevents cheek biting by holding the buccal mucosa off the food table by eliminating occlusal contacts on the maxillary buccal cusps, minimizes occlusal disharmonies created from errors in jaw relationships, denture processing changes and settling of the denture base, and simplifies setting of denture teeth, balancing the occlusion and any subsequent occlusal adjustment procedures.⁵

Clinical report


A healthy 50-year-old caucasian woman presented for treatment at the office of one of the co-authors (LDC) with a mobile, painful, 12-tooth semiprecious alloy-ceramic fixed prosthesis (Fig. 2). The prosthesis was removed and all of the remaining abutment teeth were found to be nonrestorable with extraction indicated (Fig. 3). After removal of the retained teeth, eight titanium one-piece implants were inserted in one session (Fig. 4).

Immediate stabilization of the eight implants and 2 additional implants that were previously inserted in the posterior regions was achieved by welding (Acerboni Intraoral Welding Unit, Casargo, Italy) each implant to a 1.5 mm supporting titanium bar (Acerboni, Casargo, Italy), which previously had been bent to fit passively on the palatal mucosa (Fig. 5). A provisional resin prosthesis was inserted, which provided an acceptable vertical dimension and lingual contact occlusion. Oral hygiene procedures were demonstrated to the patient and reviewed at all future appointments.

After 90 days, a panoramic radiograph suggested complete integration (Fig. 6) and a healthy mucosa was observed. (Fig. 7). The definitive

full-arch gold-ceramic maxillary prosthesis was inserted, which greatly pleased the patient and her family.

In the lower arch, the right first and second bicusps were extracted and implants placed in the first bicuspid and first molar regions. The implants were welded together intraorally (Fig. 8), followed by the fabrication and cementation of a three-tooth fixed prosthesis (Fig. 9).

A 7-year follow-up radiograph (Fig. 10) shows satisfactory preservation of bone surrounding all of the implants. An intraoral photograph of the definitive prosthesis shows healthy gingival tissue (Fig. 11). 

References

1. Mondani PL, Mondani PM. The Pierluigi Mondani intraoral electric solder. Principles of development and explanation of the solder using syncrystallization. Riv Odontostomatol Implantoprotesi. 1982;4:28-32.
2. Rossi F, Pasqualini ME, Dal Carlo L, Shulman M, Nardone M, Winkler S. Immediate loading of maxillary one-piece screw implants utilizing intraoral welding: a case report. J Oral Implantol (in press).
3. Tramonte, S. A further report on intraosseous implants with improved drive screws. J Oral Implant Transplant Surg. 1965;11:35-37.
4. Winkler S, ed. Essentials of Complete Denture Prosthodontics. 3rd

ed. Delhi, India: AITBS Publishers; 2015.

5. Lang BR, Lauciello FR, McGivney GP, Winkler S. Contemporary Complete Denture Occlusion, revision 4. Amherst, NY: Ivoclar Vivadent, 2012.

Editorial note:

This article was originally published in implants – the international magazine C.E. of oral implantology, Issue 2/2015.

Dr. Luca Dal Carlo and Dr. Franco Rossi are in private practice in Venice, Italy.

Dr. Marco E. Pasqualini is in private practice in Milan, Italy.

Dr. Mike Shulman is in private practice in Clifton, N.J., and adjunct associate professor at the School of Oral Health Sciences, Kingston, Jamaica.

Dr. Michele Nardone is with the Ministry of Public Health, Rome, Italy.

Dr. Sheldon Winkler is adjunct professor at Midwestern University College of Dental Medicine, Glendale, Ariz., and School of Oral Health Sciences, Kingston, Jamaica.

Dr. Tomasz Grotowski is in private practice and professor at the School of Minimally Invasive Implantology, Szczecin, Poland.

AD

14th edition

CAD/CAM & Digital Dentistry Conference

Madinat Jumeirah Conference Centre | Dubai | UAE

WhatsApp Enquiry
+971 50 2793711

Final Programme Day 1 | 12 April 2019

<div style="display: flex; align-items: center; margin-bottom: 10px;">  <div style="margin-left: 10px;"> <p>09:00 - 09:45 Prof Tim Joda, Switzerland Dual Presentation: Monolithic Implant Reconstructions – The Keystone to Advances in CAD/CAM Technologies</p> </div> </div>	<div style="display: flex; align-items: center; margin-bottom: 10px;">  <div style="margin-left: 10px;"> <p>13:45 - 14:45 Dr Jan Paulics, Sweden Mastering the Art of Digital Impressions</p> </div> </div>
<div style="display: flex; align-items: center; margin-bottom: 10px;">  <div style="margin-left: 10px;"> <p>09:00 - 09:45 Vincent Fehmer, MDT, Switzerland Dual Presentation: Monolithic Implant Reconstructions – The Keystone to Advances in CAD/CAM Technologies</p> </div> </div>	<div style="display: flex; align-items: center; margin-bottom: 10px;">  <div style="margin-left: 10px;"> <p>14:45 - 15:30 Dr Dimitris Strakas, Greece Lasers - Cutting Edge Technology for the Modern Dentist</p> </div> </div>
<div style="display: flex; align-items: center; margin-bottom: 10px;">  <div style="margin-left: 10px;"> <p>09:45 - 10:30 Dr Bart Vandenberghe, Belgium Pitfalls in 3D CBCT Imaging</p> </div> </div>	<div style="display: flex; align-items: center; margin-bottom: 10px;">  <div style="margin-left: 10px;"> <p>16:00 - 16:45 Lt Dr Nawaf Al-Dousari, Kuwait Custom Made Artistic Smile (Mix of CAD/CAM & Press)</p> </div> </div>
<div style="display: flex; align-items: center; margin-bottom: 10px;">  <div style="margin-left: 10px;"> <p>10:45 - 11:30 Prof Goran Urde, Sweden Implant Dentistry "It was Better Before"</p> </div> </div>	<div style="display: flex; align-items: center; margin-bottom: 10px;">  <div style="margin-left: 10px;"> <p>16:45 - 17:30 Dr Daz Singh, UK Aesthetically Focused Multi-Disciplinary Treatment Planning with Aligners</p> </div> </div>
<div style="display: flex; align-items: center; margin-bottom: 10px;">  <div style="margin-left: 10px;"> <p>11:30 - 12:15 Dr Martin Lebeda, Czech Republic Aesthetics with CEREC – Design of Digital Wax-Up, Guided Implant Surgery, No-Prep Veneer Case</p> </div> </div>	<div style="display: flex; align-items: center; margin-bottom: 10px;">  <div style="margin-left: 10px;"> <p>17:30 - 18:00 Dr Eduardo Mahn, Chile How to Choose the Most Appropriate CAD/CAM Material for Modern Indications</p> </div> </div>

Final Programme Day 2 | 13 April 2019

<div style="display: flex; align-items: center; margin-bottom: 10px;">  <div style="margin-left: 10px;"> <p>09:00 - 09:45 Dr Manol Ivchev, Bulgaria 3D Function in Occlusion – A Key for Orthodontics</p> </div> </div>	<div style="display: flex; align-items: center; margin-bottom: 10px;">  <div style="margin-left: 10px;"> <p>14:15 - 15:00 Dr Isabelle Savoye, Belgium The Full Digital Orthodontic Patient and the 3D Application</p> </div> </div>
<div style="display: flex; align-items: center; margin-bottom: 10px;">  <div style="margin-left: 10px;"> <p>09:45 - 10:30 Prof Tim Joda, Switzerland Complete Digital Workflow for Single-Unit Implant Restorations</p> </div> </div>	<div style="display: flex; align-items: center; margin-bottom: 10px;">  <div style="margin-left: 10px;"> <p>15:00 - 15:45 Dr Anoop Maini, UK Cost Effective Chairside Dentistry Utilising a Fully Open Platform</p> </div> </div>
<div style="display: flex; align-items: center; margin-bottom: 10px;">  <div style="margin-left: 10px;"> <p>10:30 - 11:15 Dr Hao-Wei Tsao, Taiwan Clinical Application in Chair-side CAD/CAM</p> </div> </div>	<div style="display: flex; align-items: center; margin-bottom: 10px;">  <div style="margin-left: 10px;"> <p>16:15 - 17:00 Germen Versteeg, NL +1000 Digital Dentures Later. A Huge Improvement in Quality and How it Changes your Business Model</p> </div> </div>
<div style="display: flex; align-items: center; margin-bottom: 10px;">  <div style="margin-left: 10px;"> <p>11:30 - 12:00 Dr Munir Silwadi, UAE Restoration of Endodontically Treated Teeth with Chair Side Partial Crowns</p> </div> </div>	<div style="display: flex; align-items: center; margin-bottom: 10px;">  <div style="margin-left: 10px;"> <p>17:00 - 17:45 David Claridge, IDDA, UK Scanomics – The Economics of Intraoral Scanning</p> </div> </div>
<div style="display: flex; align-items: center; margin-bottom: 10px;">  <div style="margin-left: 10px;"> <p>12:00 - 12:45 Dr Adam Nulty, IDDA, UK FULLYDIGITAL: Prosthetic Driven Implant Planning</p> </div> </div>	

Accreditation:
DHA 12.75 CME

CAPP **ADA C-ERP** Continuing Education Recognition Program

Centre for Advanced Professional Practices (CAPP) is an ADA CERP Recognized Provider. ADA CERP is a service of the American Dental Association to assist dental professionals in identifying quality providers of continuing dental education. ADA CERP does not approve or endorse individual courses or instructors, nor does it imply acceptance of credit hours by boards of dentistry. CAPP designates this activity for 14 CE Credits

www.cappmea.com/digital-dentistry-2019-conference

New PIEZOSURGERY® inserts for sinus lift by lateral approach

By Mectron S.P.A.

After 15 years, Mectron re-defines the sinus lift technique by lateral approach launching on the market 5 new PIEZOSURGERY® inserts developed in collaboration with Professor Tomaso Vercellotti, Italy.

Thanks to the new inserts shapes, the revisited protocol makes the technique even safer, minimizing the risk of membrane perforation.

Particularly:

- the new SLC insert allows to perform the osteoplasty of the sinus vestibular wall with maximum safety and unparalleled intra-operative control;
- the new high-efficiency SLO-H insert permits to execute the osteotomy procedures with the maximum safety
- the new thin SLS membrane separator is more efficient in comparison

with the old generation "elephant paw shape".

• the new elevators SLE1 and SLE2, the first one to start the sinus membrane elevation from the sinus floor and the second one to finalize the sinus membrane elevation from the palatal wall, are featured by a sharp terminal part allowing to cut Sharpey's fibers from the endosteum with the maximum safety, protecting it thanks to the convexity of the tips.

The precision and the maximum evidence-based safety guaranteed by these piezoelectric inserts make this kit a wonderful addition to the surgical armamentarium for to both novice and expert surgeons.

The inserts will be available separately as well as in a Kit with all five inserts dedicated to sinus lift by lateral approach. [DT](#)

For more information contact:

mectron S.P.A.
Via Loreto, 15/A
16042 Carasco (GE) - Italy
Tel: +39 0185 35361
Fax: +39 0185 351374
E-mail: mectron@mectron.com
Web: www.mectron.com



Fig: Surgical kit sinus

© Mectron S.P.A.

Flow variations – The flow variant of the universal composite BRILLIANT EverGlow makes filling extremely simple



By COLTENE

Undercuts, sharp angles or cervical bevels present particular challenges when placing conventional composites. Therefore clinicians will benefit substantially from an innovative dental material with an optimal thixotropic property and allows effortless positioning. The flowable consistency is particularly suited for treating areas with difficult access and saves valuable treatment time.

Rapid, voidless fillings

To complete the classical presentation form, the Swiss dental specialist COLTENE now additionally offers its BRILLIANT EverGlow submicron universal composite in a flowable variant. The low viscosity filling material combines convenient application with high stability. Among other things, BRILLIANT EverGlow Flow is ideally suited for filling areas with difficult access as well as for sealing fissures. Due to its flow properties, the restorative material fully comes into its own when filling cavity linings. The flow variant can

be applied directly from the syringe to the bonded surface which saves material and time. The composite, which flows under pressure, can then be comfortably brought into the required position until curing. The exceptionally smooth consistency of BRILLIANT EverGlow high performance composite has already captivated many clinicians. Owing to its sophisticated composition of special fillers, the pliable material can be applied easily into all classes of cavities without sticking to the instrument. Not only that, it has long gloss stability and excellent polish-

ability. BRILLIANT EverGlow Flow, a user-friendly and highly aesthetic flowable, rounds off the programme. Depending on the indication, dentists can in future choose a suitable variant from the extended product range.

Find out more

BRILLIANT EverGlow Flow, the versatile filling material, is available from dental wholesalers in a 2g syringe. Next to six universal shades, the flowable variant will also be available in a translucent enamel shade

and an opaque material in shade A2. As usual, the assortment includes shades in the sophisticated "Duo Shade" system which cover two classical VITA shades in one, ranging from A1/B1 to A4/C4. [DT](#)

For further information, please contact:

Coltene/Whaledent AG
Feldwiesenstrasse 20
9450 Altstätten SG
Switzerland

ONE COAT 7 UNIVERSAL All-purpose universal bond

By COLTENE

State-of-the art, self-etching adhesive systems are easy to apply and boost the success rate significantly, especially within restorations in the posterior area. Simultaneously they stand for predictable results, independent of the applied basis or the preferred application technique of the dentist. Coming to reliability and user-friendliness, research and development has now set new material standards:

Reliably adhesive agent on dentin and enamel

The new ONE COAT 7 UNIVERSAL was developed on the basis of the favored ONE COAT 7.0, and is a reliable All-in-One Bond for every indication. Whether self etch, selective enamel etch or total etch technique, a single drop bonds light-curing filling materials easily, quickly and is long-lasting. ONE COAT 7 UNIVERSAL is an excellent adhesion promoter on enamel and dentin, thus is a guarantee for safe restorations even in ex-

traordinary cases. With only a single bonding layer it provides consistently high bonding strength, excellent marginal sealing and excellent marginal integrity. These exceptional clinical values are convincing, even when compared with conventional system adhesives.

In conjunction with ONE COAT ACTIVATOR it is optionally also possible to use a chemically cured product. You will always be making the right choice with the light-curing single-

component adhesive ONE COAT 7 UNIVERSAL!

Ergonomic triangular bottle and single dose – Safe and easy

The universal bonding agent also comes with a new presentation form. The special triangular bottle, with its excellent ergonomic handling, lies comfortably in the hand and the precision dropper allows precise and economical working.

ONE COAT 7 UNIVERSAL is available as introductory kit with a 5ml bond bottle including etch gel and accessories. There are also practical single dose units for one-off use. These are also offered as refill packs in addition to the 5ml bond bottle. [DT](#)



WhatsApp
Enquiry
+971502793711

08–09 NOVEMBER 2019
INTERCONTINENTAL HOTEL
DFC, DUBAI, UAE

11TH DENTAL FACIAL COSMETIC CONFERENCE & EXHIBITION

Joint Meeting with
**DENTAL HYGIENIST SEMINAR
TRAINING AT THE EXHIBITION
POSTER PRESENTATION**

ADA CERP® | Continuing Education
Recognition Program

Centre for Advanced Professional Practices (CAPP) is an ADA CERP Recognized Provider. ADA CERP is a service of the American Dental Association to assist dental professionals in identifying quality providers of continuing dental education. ADA CERP does not approve or endorse individual courses or instructors, nor does it imply acceptance of credit hours by boards of dentistry.

CAPP designates this activity for 14CE Credits

ORGANISED BY

CAPP

www.cappmea.com/aesthetic