

## Computer planned and guided implant surgery

By Pankaj P. Singh, DDS,  
Diplomate ICOI and ABOI/ID

The use of three-dimensional radiography and imaging (Computed Tomography {CT}, Magnetic Resonance Imaging {MRI}) has been used for more than four decades in medicine.

It has aided in increasing the accuracy of identification of vital anatomic structures and the pathologies associated within them.

This advanced technology has also prompted the development of protocols whereby surgical intervention can be planned on three-dimensional virtual computer animation or physical anatomic models. Today, computer-guided and robotic surgery in the most dangerous parts of the body such as the brain, spine and heart are routinely performed with great success and predictability.

In dentistry, the introduction of 3-D radiography more than a decade ago has made it easier for the clinician to identify, study and plan a course of therapy to treat the area of disease or defect with increased precision (Fig. 1).

In addition, the introduction of office-based cone beam volumetric tomographic (CBVT) machines in 1999 came together with the advances in surgical planning software. This software comes either as a third party or as native to the image acquisition and viewing software included with the imaging hardware and has made implant therapy predictable and accurate (Fig. 2).

Traditional model-based surgical

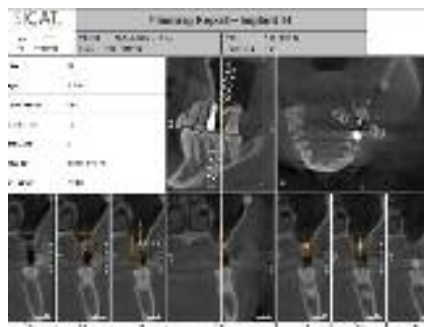


Fig. 1: Cross-section view #14 site demonstrating the need for a sinus lift.



Fig. 2: Galileos by Sirona used to acquire the scan for implant planning with the patient wearing the scan stent.

guides provide a reasonable estimation of the implant position for the prosthetic rehabilitation. The major limitations of these surgical guides was the surgery was often accom-

→ IT page 6

## ICOI in Philadelphia



In May, the ICOI and Temple University College of Dentistry will co-host a spring implant symposium at the Downtown Marriott Hotel in Philadelphia.

### Event to focus on 'Implant Restorative Science: The Good, The Bad, The Beautiful'

From May 7-9, the International Congress of Oral Implantologists (ICOI) and Temple University College of Dentistry will co-host a spring implant symposium at the Downtown Marriott Hotel in Philadelphia.

The theme for this meeting, as designed by Dr. John T. Green of Dayton, Ohio, is "Implant Restorative Science: The Good, The Bad, The Beautiful." The symposium is also being hosted by ICOI's Component Auxiliary Society, the Association of Dental Implant Auxiliaries (ADIA).

Topics to be covered in the general session are: how to manage the gap; minimally invasive surgery; analysis of tooth size; space size issues; gingival architecture solutions; improvement of doctor/patient/lab communications; implant maintenance issues; i-Cat analysis; treatment for peri-implantitis; ortho-implant realities; immediate provisionalization; CAD/CAM realities; occlusion; abutment selections and complications.

Here are some highlights of the program:

- Dr. William Becker: Implant Restorative
- Dr. Ernesto A. Lee: Implant Supported vs. Tooth Supported

→ IT page 24

AD

Dental Tribune America  
213 West 35th Street  
Suite #801  
New York, NY 10001

PRSRST STD  
U.S. Postage  
PAID  
Permit #198  
Mendota, IL

# AAID hails Florida court verdict allowing advertising of bona fide dental credentials

A Florida judge has ruled that a state law restricting how dentists can advertise credentials issued by bona fide professional organizations is unconstitutional and violates the First and Fourteenth Amendments of the U.S. Constitution.

The American Academy of Implant Dentistry (AAID) said today the verdict is a victory for consumers evaluating the qualifications and experience of dentists who perform implant procedures and for practitioners entitled to promote their credentials to the public.

"We are very pleased with this decision recognizing the rights of dentists with bona fide credentials to advertise them to the public without negative disclaimers and offer consumers valid information from which they can evaluate qualifications of dentists in their communities," said AAID President Beverly Dunn, DDS. "Also, the decision noted that AAID and other dental organizations provide substantial training that enhances proficiency and competency and benefits consumers as well."

At issue was a Florida statute pre-

venting advertising of membership in or credentials earned from any dental organization not recognized by the Florida Board of Dentistry (FDB). Florida's dental board only recognizes specialty credentials issued by the American Dental Association (ADA).

Therefore, implant dentists who wanted to advertise their AAID credentials had to include an onerous disclaimer that implant dentistry is not a recognized specialty of ADA or the FDB and that AAID is not a recognized specialty accrediting organization.

The case stemmed from multiple challenges to the constitutionality of the Florida statute by dentists with credentials from AAID, the Academy of General Dentistry and the American Academy of Cosmetic Dentistry. Circuit Court Judge Frank E. Sheffield ruled in favor of the plaintiffs on April 3.

"The Court found that these advertising restrictions were unconstitutional on many grounds. They violated the Florida constitution's guarantee of the right to be rewarded for industry or professional

achievement and First and Fourteenth Amendment rights of free speech and equal protection of the law," said Frank R. Recker, DDS, JD, AAID's chief counsel.

Dunn added that the Florida decision establishes a strong precedent that could form the basis for challenging advertising restrictions in other states, if necessary.

"Demand for dental implants is rising, and more dentists need comprehensive training to become highly skilled at implant procedures," Dunn said. "Attending a weekend course isn't enough. There is a higher level of risk with the procedure if the dentist has limited experience."


AAID offers a rigorous implant dentistry credentialing program that requires at least 300 hours of post-doctoral instruction in implant dentistry, passing a comprehensive exam and presenting to a group of examiners successful cases of different types of implants.

It is one of the most comprehensive credentialing programs in dentistry.

(Source: AAID)

AD

## DENTATUS NARROW DIAMETER IMPLANTS




### ATLAS®

#### DENTURE COMFORT

Designed to stabilize, cushion and retain mandibular dentures.

Unique Tuf-LINK™ silicone reline material retains dentures without housings, o-rings or adhesives. The entire procedure is performed in a single chairside visit, is minimally invasive & extremely economical.




### ANEW®

#### FITS WHERE NO OTHERS CAN

The Anew one-piece, screw retained implants are a major advance in implantology. Designed for immediate provisionalization at time of placement so patients never have to go without teeth. Provide economical and diverse services to your patients, ideal for:

- replacement of single teeth & congenitally missing laterals
- thin ridges, limiting spaces & converging roots,
- maintenance of soft tissue architecture, &
- immediate provisionalization during grafting procedures

Dentatus Atlas & Anew implants are available in diameters of 1.8, 2.2 & 2.4mm with thread lengths of 7, 10 & 14mm. Made of Grade V Titanium-Alloy and delivered sterile. The Atlas & Anew implants restorative protocol was developed by Dentatus in conjunction with the Department of Implant Dentistry, New York University College of Dentistry.


Dentatus USA, Ltd. 800-323-3135
www.dentatus.com
© 2009 Dentatus USA, Ltd. - Patent Pending

## Tell us what you think!

Do you have general comments or criticism of a Dental Tribune America publication you would like to share? Is there a particular topic you would like to see more articles about? Let us know by e-mailing us at [feedback@dtamerica.com](mailto:feedback@dtamerica.com). If you would like to make any change to your subscription (name, address or to opt out) please send us an e-mail at [database@dtamerica.com](mailto:database@dtamerica.com) and be sure to include which publication you are referring to. Also, please note that subscription changes can take up to six weeks to process.

## IT Corrections

Implant Tribune strives to maintain the utmost accuracy in its news and clinical reports. If you find a factual error or content that requires clarification, please report the details to Managing Editor Sierra Rendon at [s.rendon@dtamerica.com](mailto:s.rendon@dtamerica.com).

## IMPLANT TRIBUNE

The World's Newspaper of Implantology - U.S. Edition

**Publisher**  
Torsten Oemus  
[t.oemus@dtamerica.com](mailto:t.oemus@dtamerica.com)

**President**  
Peter Witteczek  
[p.witteczek@dtamerica.com](mailto:p.witteczek@dtamerica.com)

**Chief Operating Officer**  
Eric Seid  
[e.seid@dtamerica.com](mailto:e.seid@dtamerica.com)

**Group Editor**  
Robin Goodman  
[r.goodman@dtamerica.com](mailto:r.goodman@dtamerica.com)

**Editor in Chief**  
Sascha A. Jovanovic, DDS, MS  
[sahara@jovanoviconline.com](mailto:sahara@jovanoviconline.com)

**Managing Editor/Designer**  
Sierra J. Rendon  
[s.rendon@dtamerica.com](mailto:s.rendon@dtamerica.com)

**Managing Editor Endo Tribune & Online**  
Fred Michmershuizen  
[f.michmershuizen@dtamerica.com](mailto:f.michmershuizen@dtamerica.com)

**Managing Editor Ortho Tribune**  
Kristine Colker  
[k.colker@dtamerica.com](mailto:k.colker@dtamerica.com)

**Account Manager**  
Humberto Estrada  
[h.estrada@dtamerica.com](mailto:h.estrada@dtamerica.com)

**Marketing Manager**  
Anna Wlodarczyk  
[a.wlodarczyk@dtamerica.com](mailto:a.wlodarczyk@dtamerica.com)

**Marketing & Sales Assistant**  
Lorrie Young  
[l.young@dtamerica.com](mailto:l.young@dtamerica.com)

**C.E. Manager**  
Julia Wehkamp  
[j.wehkamp@dtamerica.com](mailto:j.wehkamp@dtamerica.com)

**Design Support**  
Yodit Tesfaye  
[y.tesfaye@dtamerica.com](mailto:y.tesfaye@dtamerica.com)

Dental Tribune America, LLC  
215 West 55th Street, Suite 801  
New York, NY 10001  
Phone: (212) 244-7181, Fax: (212) 244-7185



Published by Dental Tribune America

© 2009, Dental Tribune International GmbH. All rights reserved.

Dental Tribune makes every effort to report clinical information and manufacturer's product news accurately, but cannot assume responsibility for the validity of product claims, or for typographical errors. The publishers also do not assume responsibility for product names or claims, or statements made by advertisers. Opinions expressed by authors are their own and may not reflect those of Dental Tribune International.

## Editorial Advisory Board

**Dr. Sascha Jovanovic, Editor in Chief**

Dr. Bernard Touati

Dr. J.T. Krauser

Dr. Andre Saadoun

Dr. Gary Henkel

Dr. Doug Deporter

Dr. Michael Norton

Dr. Ken Serota

Dr. Axel Zoellner

Dr. Glen Liddelow

Dr. Marius Steigmann



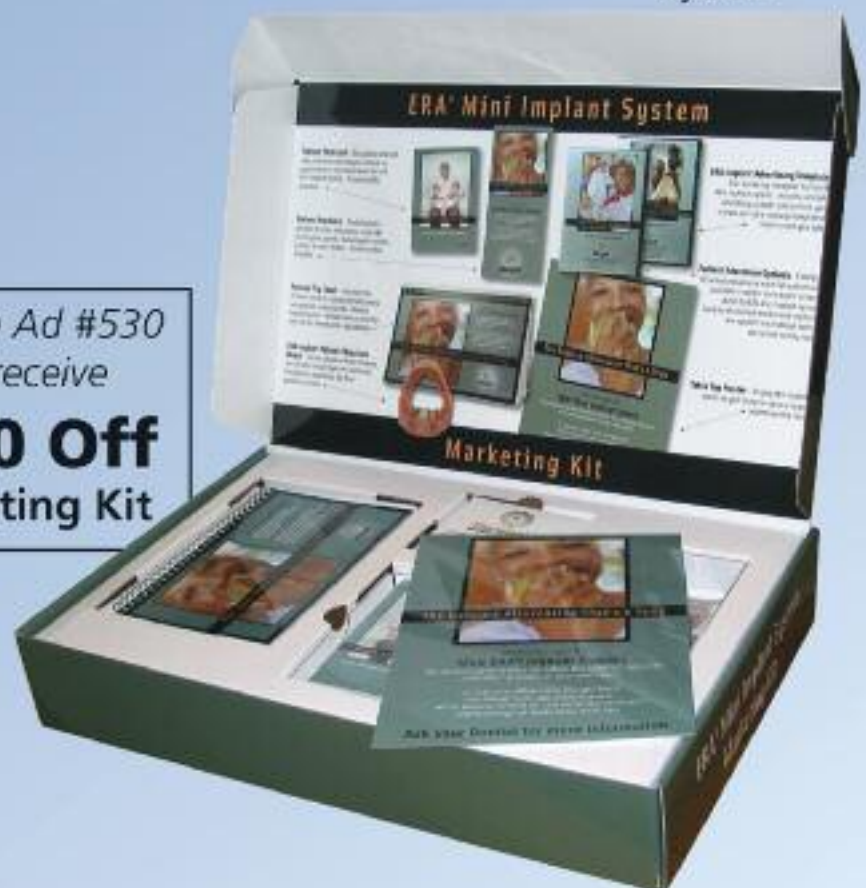## The Standard of Care for Implant Supported Overdentures



- ◆ Approved for Permanent Application
- ◆ True Vertical Resiliency
- ◆ Corrects Misalignment of Implants
- ◆ 20 Years of ERA Clinical Success
- ◆ Mentor Program Available
- ◆ Educational Opportunities

The  
**ERA** <sup>implant</sup>  
System

Mention Ad #530  
and receive  
**\$100 Off**  
Marketing Kit



23 Frank Mossberg Drive • Attleboro, MA 02703-0967

**800-243-9942 • 508-226-5660**

Order online at [www.sterngold.com](http://www.sterngold.com)

ERA Marketing Kit

## Iacono heads slate of AO's newly-elected officers

Vincent J. Iacono, DMD, Stony Brook, N.Y., was elected president of the Academy of Osseointegration (AO) during the organization's annual business meeting in San Diego. He succeeds former Academy President Steven G. Lewis, DMD, Cincinnati.

Newly elected members of the AO Board of Directors with Dr. Iacono are:

- **President-elect:** Peter K. Moy, DMD, Los Angeles;
- **Vice president:** Kenneth F. Hinds, DDS, Laguna Niguel, Calif.;
- **Secretary:** Stephen L. Wheeler, DDS, Encinitas, Calif., and;
- **Director:** Jay P. Malmquist, DMD, Portland.

Dr. Iacono is distinguished service professor and chairman, Department of Periodontology, School of Dental Medicine, Stony Brook University. He is also director of the school's Advanced Education Program in Periodontics, and associate dean of Postgraduate Programs.

Iacono co-chaired the academy's landmark 2006 Workshop on the State of the Science of Implant Dentistry. He has served on the Board of Directors since 2000, including terms as AO president-elect, vice president and secretary.

Iacono had been active on many AO committees, including the Council on Research and the Predoctoral Education Forum Committee. He also served on the Osseointegration Foundation



Vincent J. Iacono

Board of Directors. In addition, Iacono is former president of the American Academy of Periodontology (AAP).

Iacono completed his dental degree and earned a certificate in periodontology and oral medicine at Harvard University School of Dental Medicine. He then received a certificate in immunology from the Forsyth Institute, Boston.

With more than 6,000 members in 70 countries around the world, the AO is the world's leading dental implant organization.

Its goal is to advance the field of osseointegrated implants by fostering collaboration between representatives of different dental disciplines — oral surgery, periodontics, prosthodontics and general practice — through clinical and evidence-based research and education.

For more information, visit [www.osseo.org](http://www.osseo.org).

(Source: Academy of Osseointegration)

## Prosthodontist William Laney receives 2008 Nobel Biocare Brånemark Osseointegration Award

William R. "Bill" Laney, DMD, MS, of Rio Verde, Ariz., received the Nobel Biocare Brånemark Osseointegration Award during the 2009 Annual Meeting of the Academy of Osseointegration (AO) Feb. 26, at the San Diego Convention Center.

The award recognizes an individual's impact on, and leadership in, the field of osseointegration. It is presented by the Osseointegration Foundation — AO's charitable wing — and funded by a five-year, \$2.5 million donation by Nobel Biocare.

"The foundation is proud to present this award recognizing Dr. Laney for his outstanding educational research contributions, international clinical leadership, and distinguished character," Foundation President Dr. Fraya Karsh, New York, N.Y., explained.

"The Nobel Biocare Brånemark Osseointegration Award is the highest honor bestowed by the foundation. It is fitting that Bill Laney, considered by many to be the pre-eminent prosthodontist of his generation, is this year's recipient," said Dr. Steven E. Eckert, former AO president and editor in chief of AO's journal, The International Journal of Oral & Maxillofacial Implants (IJOMI).

Laney played an essential role in the Academy's founding in the mid-1980s. Members elected him AO's first president in 1986, and he is the only academy member to serve two

terms at the helm. He was named AO's first Fellow in 1991, and was presented with the Distinguished Service Award — AO's highest honor — in 2006.

"The academy was a group effort. That said, Bill Laney pulled it together," recalled Dr. Charles L. Berman, co-founder of the study group that would become the AO. "The academy would never have happened without his cohesive leadership."

Laney was also the first editor in chief of IJOMI, a position he held for 20 years.

In addition to his service to AO, Laney also served as president of the Federation of Prosthodontic Organizations, the Academy of Prosthodontics, the American Board of Prosthodontics, the American Academy of Maxillofacial Prosthetics and the American Cleft Palate Association.

Laney earned his dental degree from the University of Oregon Dental School, Eugene, Ore., a certificate in prosthodontics from the VA Medical Center, Iowa City, Iowa, and a master's of science degree from the University of Iowa.

Recipients of the Nobel Biocare Brånemark Osseointegration Award are selected by a committee composed of the immediate past presidents of both the Academy and Osseointegration Foundation, and osseointegration pioneer Dr. Per-Ingvar Brånemark, Göteborg, Sweden, after whom the award is named.



William R. 'Bill' Laney

AD

### The Ultimate in Patient Comfort

**Crescent Headrest, Backrest, Knee Support and Bodyrest**  
Bring your patients comfort with memory foam cushions for their neck, back and entire body. The Knee Rest will provide your patients with pressure relief in the lower back and hips.

Available in Gray, Beige and Teal

### Your Complete Source for Patient Comfort!

**Crescent Osteo Headrest**  
The Osteo Pillow will gently cushion the head and neck and offer support to the patient who has difficulty bringing their head to a reclined position.

**Crescent Child Booster Seat**  
The Crescent Child Booster Seat is the ultimate seat to have in your practice to assist in the positioning of children in the dental chair.

[www.crescentproducts.com/dental.htm](http://www.crescentproducts.com/dental.htm)

To Order Call! Toll-Free: (800) 989-8585

# Instant Gratification for Denture Patients

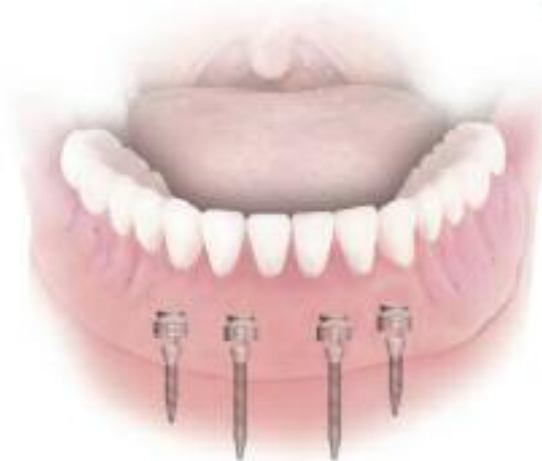

## IMTEC MDI Minimally Invasive Implant System

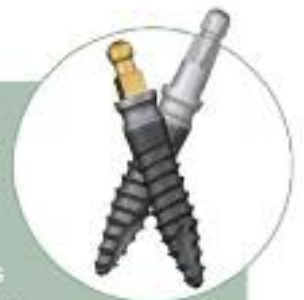IMTEC's Sendax MDI® Implant System offers a revolutionary one-hour, one-stage solution for long-term denture stabilization. This immediate loading, minimally invasive system utilizes a patented, flapless placement protocol and works with the patient's existing denture. The versatile MDI implant family includes the 1.8 and 2.1mm implants for dense bone and the 2.4 and 2.9mm implants for softer bone.



2.1mm Collared O-Ball



## MDI Hybrid Implant 2.9mm Implant System



Your MDI treatment opportunities have just been expanded! The new MDI 2.9mm Hybrid Implant offers treatment plans for single tooth replacement in small spaces and denture stabilization in soft bone. The Hybrid can be placed with a minimally invasive procedure using MDI instrumentation, making adoption of the 2.9mm Hybrid simple and cost effective.

## Train Now!

### IMTEC MDI Certification Seminar Schedule

- May 8 - ADL Lab - Louisville, KY
- May 13 - da Vinci Dental - West Hills, CA
- May 15 - Sundance Dental - Scottsdale, AZ
- May 16 - Denver, CO
- May 29 - Sherer Dental Lab - Rock Hill, SC
- May 30 - Charlotte, NC
- May 30 - San Antonio, TX
- June 6 - Boston, MA
- June 6 - Chicago, IL
- June 13 - Atlanta, GA
- June 13 - Salt Lake City, UT

### MDI University Training

University of Oklahoma - July 18 & 19  
Oklahoma City, OK

Call 866-946-1375 for your free MDI Technique CD or visit [www.imtec.com/implants](http://www.imtec.com/implants)

← II page 1

plished with flaps and the surgeon didn't have an accurate estimation of the hard tissue present, especially the width, until the bone was exposed during surgery. This often led to surprises for both the surgeon and the patient, resulting in implants being placed that were under-engineered for the load or implants that later could not be restored esthetically, leading to compromised results (Figs. 3-7).

Computer-based implant planning and placement allows for creation of an exact replica of the jawbone on the computer screen, allowing visualization of all the vital structures such as nerves, sinuses, nasal floor, proximal teeth and concavities like the one below the mylohyoid ridge in the posterior mandible (Figs. 8a, b). Thus, practitioners can safely avoid these structures when planning and ultimately placing the implants using CAD/CAM generated surgical guides (Figs. 9-11).

With computer-guided placement of dental implants, there is no guesswork or surprises and most surgeries can be performed with a flapless technique (Figs. 12a-c). In case augmentation procedure has to take

place, flaps can be reflected to access those sites and the implants provisionally placed immediately (Figs. 13a-c). This conservative approach drastically diminishes postoperative pain, recuperation and healing time. The patient leaves the surgeon's office esthetically restored and pleased with the ease at which such a complicated surgery was accomplished.

The guided surgical treatment is based on guided keyhole surgery that is minimally invasive. This reduces pain and swelling considerably for the patient compared to conventional treatment. This technique also reduces the number of appointments and chair time for the patient.

For many patients this means a considerable time and cost savings. The combination of immediate esthetic rehabilitation and function with temporary or final prosthesis ready at surgery radically shortens the overall treatment time and inconvenience to the patient. The computer-based surgical guides allow the implant surgeon to implement the planning with high precision and predictability. The use of a drilling template saves valuable chair time, and is a significant cost savings to the patient. The precision of a drilling template cannot be

→ II page 8

AD

**Always in control**

**SimPlant® CompatAbility**

- Accurate and predictable implant treatment
- Cost-effective and highly profitable
- User-friendly
- Compatible with all implant brands and scanners

simple • compatible • unique

www.materialisedental.com

Materialise Dental

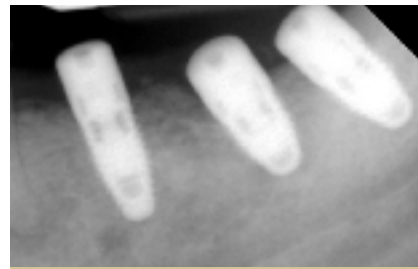


Fig. 3: Three short Nobel Biocare implants in the posterior mandible placed freehand. The patient was referred to our practice for the restoration of these implants.

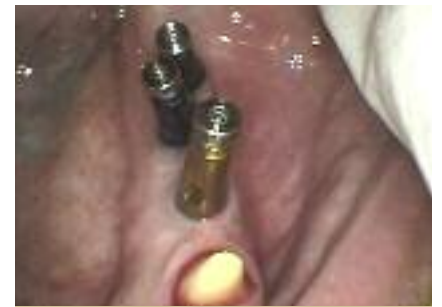

Fig. 4: Occlusal view of the impression copings attached to the malaligned implants.



Fig. 5: Frontal view of the impression copings.

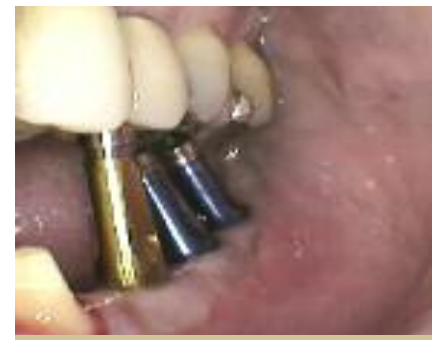

Fig. 6: Buccal view of the lingual inclination of the two posterior implants.

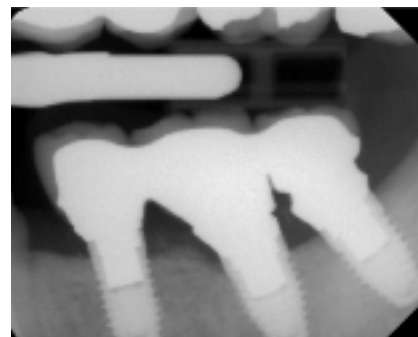


Fig. 7: Radiograph of the finished prosthesis. Because of the severe misangulation of the individual implants as well as in relationship to each other, margins couldn't be closed.

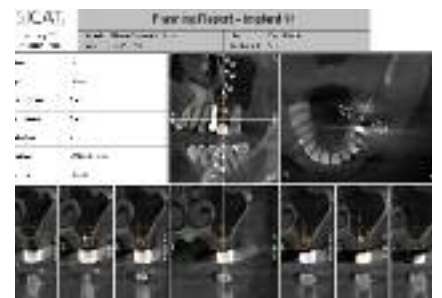


Fig. 8a: Implant planning report generated by Galileos Implant, which can be communicated and shared with the entire implant team as well as with the patient. It effectively communicates the rationale for augmentation procedures and the anatomy involved.

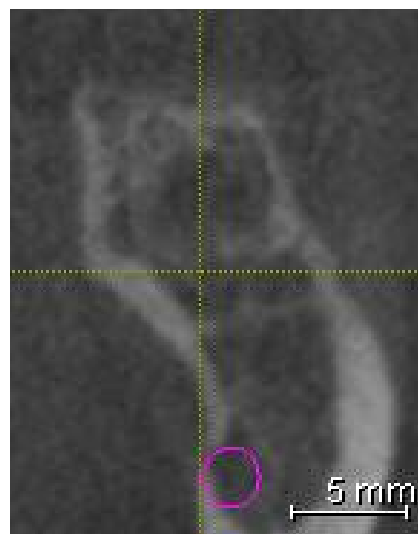


Fig. 8b: Cross section of the posterior mandible showing the mylohyoid ridge and the lingual concavity and the thin buccal alveolar cortex and atrophy.

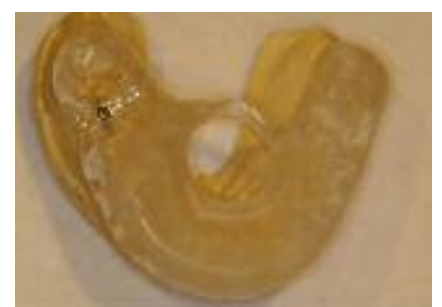

Fig. 9: Surgical Guide fabricated by SiCat for a single implant.

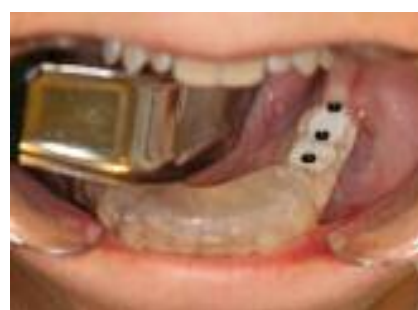

Fig. 10: Galileos surgical guide for multiple implants for a partially edentulous site.

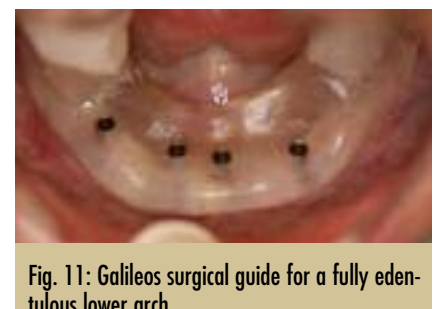

Fig. 11: Galileos surgical guide for a fully edentulous lower arch.

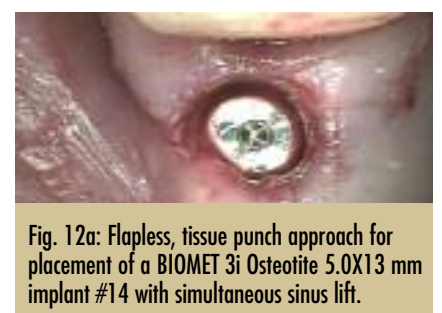


Fig. 12a: Flapless, tissue punch approach for placement of a BIOMET 3i Osteotite 5.0X13 mm implant #14 with simultaneous sinus lift.

# Natural Tapered Implant

Primary Implant Stability Starts With  
The BIOMET **3i** Tapered Implant System



*"BIOMET 3i's Tapered Implant provides for primary stability through its macrogeometric design.  
This Tapered Implant is by far the most widely used implant in my clinical practice."*

*-Dr. Markus Hürzeler, Germany*

To Find Out How You Can Achieve Primary Implant Stability With BIOMET 3i's Tapered Implant System,  
Contact Your BIOMET 3i Representative Today. In the USA: 1-800-342-5454 • Outside the USA: +1-561-776-6700  
or visit us online at [www.biomet3i.com](http://www.biomet3i.com)

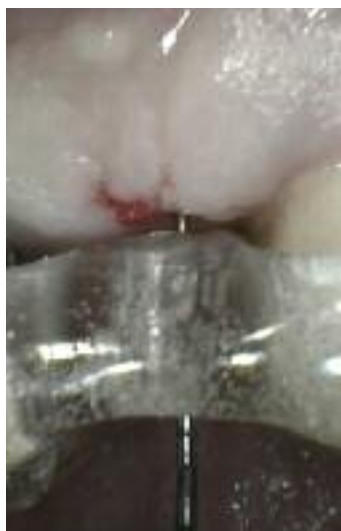

Fig. 12b: Periodontal probe used to mark the center for the tissue punch needed to expose the osseous crest.

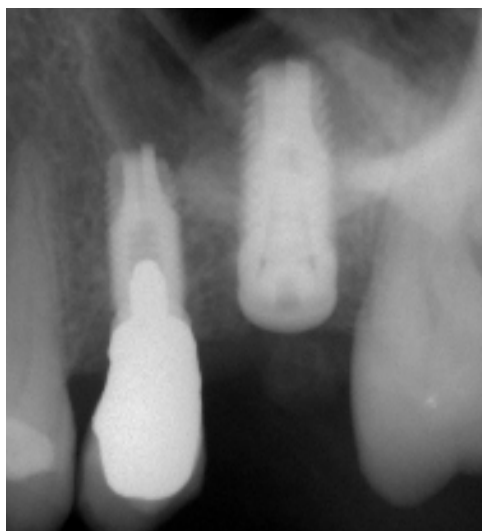


Fig. 12c: Flapless approach to placement of implant #14 and an internal socket sinus elevation with Cerasorb-alloplast grafting material mixed with PRP.

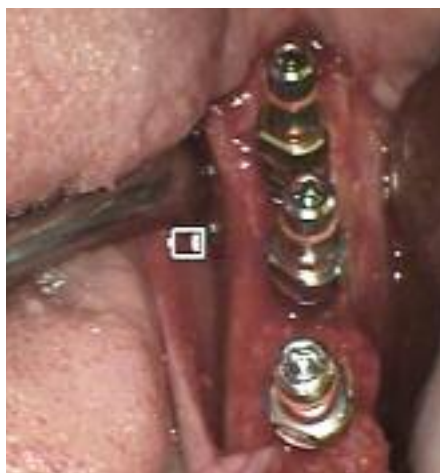

Fig. 13a: Three Camlog implants were used to replace missing teeth #18,19. The placement was guided but flaps were reflected to augment the buccal ridge around the two distal implants using Cerasorb alloplast and Epiguide membrane.

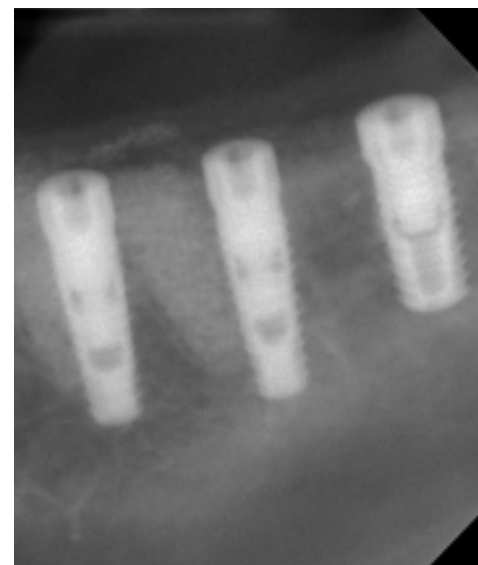


Fig. 13b: Radiograph of the Camlog implants confirming their position.

AD

**38<sup>th</sup> ANNUAL MEETING**  
OF THE ORDRE DES DENTISTES DU QUÉBEC

**MONTREAL CANADA**

**CANADA'S LARGEST ANNUAL SCIENTIFIC AND DENTAL EXHIBITION**  
MAY 23 – 26, MONTREAL, QUÉBEC, CANADA **2009**

**FEATURING**

- Over 75 scientific sessions in English and in French presented by top clinicians from around the world
- Over 240 exhibitors occupying more than 475 booths representing Canada's largest dental trade event
- Hands-on workshops and seminars covering all aspects of dentistry on May 23 and 24
- All scientific sessions and access to the exhibit floor included in one low registration fee on May 25 and 26
- CERP approved continuing dental education credits for all sessions
- Class reunions of the Quebec Dental Faculties
- and much more

*All this under one roof at the Palais des congrès de Montréal in the heart of downtown Montréal*



**Journées dentaires internationales du Québec**

For more information, please contact:  
Journées dentaires internationales du Québec  
15-625, boul. René-Lévesque Ouest, Montréal, QC H3B 1R2  
Tel: 514 875-0511 #2222 • Fax: 514 875-1561  
E-mail: congres@odc.qc.ca • Website: www.odc.qc.ca

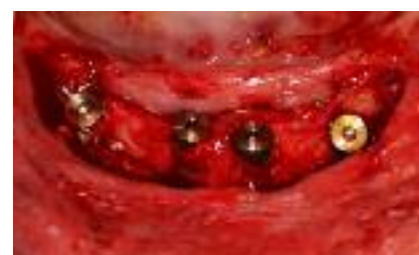

Fig. 13c: Four Neoss Implants were placed using a surgical guide; flap was reflected for guided bone regeneration using Cerasorb alloplast and Inion membrane to augment the ridge around the implants.

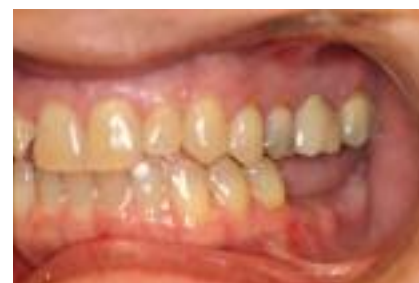

Fig. 14a: Physical examination to evaluate for prosthetic restorability and health of the surrounding area.

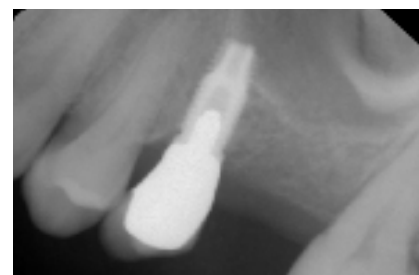

Fig. 14b: Intra-oral radiographs help rule out any pathologies present and preliminary space analysis for implant placement.

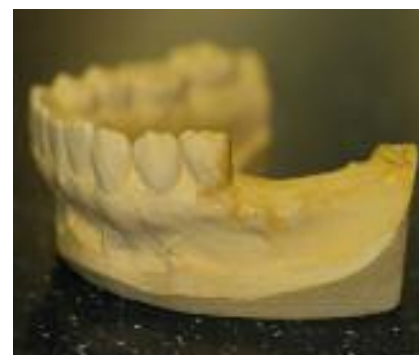

Fig. 15a: A stone model of the partially edentulous mandible.

Please send me more information

Name \_\_\_\_\_

Address \_\_\_\_\_ City \_\_\_\_\_ State \_\_\_\_\_

Zip, Country Code \_\_\_\_\_ Telephone \_\_\_\_\_ E-Mail \_\_\_\_\_



← II page 8

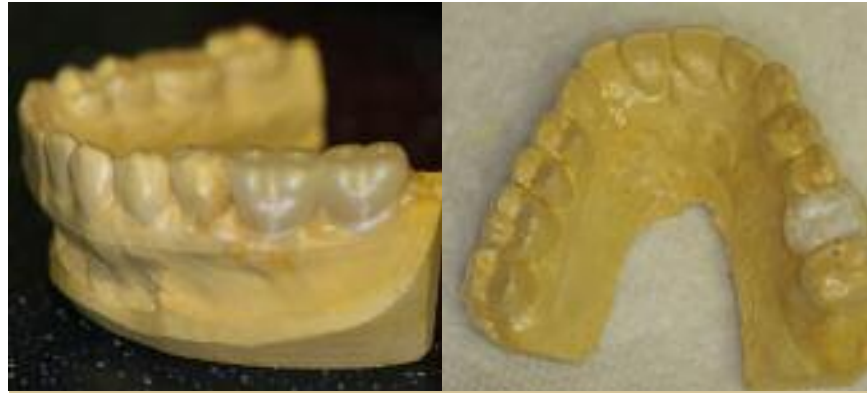reproduced with the freehand method whether the task involves restorations of individual teeth or more extensive and elaborate implant planning.

Obtaining maximum certainty and safety through exact planning and precise implementation with a computer-based keyhole drilling template is both judicious and good patient care.

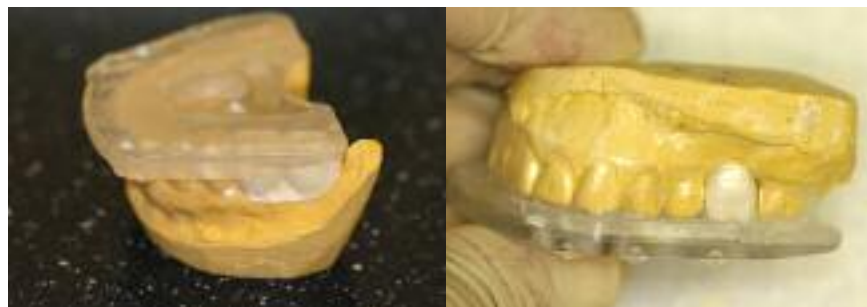There are several implant planning software programs available, including: Galileos Implant from SiCat of Sirona, Procera from Nobel-Biocare and SimPlant from Materialise Dental, among others. All systems utilize a double scan technique for the evaluation of the implant site, planning the surgery and fabrication of the surgical guides.

When the patient consents to implant therapy, the restorative or surgical doctor first clinically evaluates the surgical area (Figs. 14a, b) and then refers the patient. If the clinician feels that there is adequate bone volume present to place the implant/implants in the proper position for acceptable esthetic and functional load, then an initial scan is not required.

Once the scan has been acquired, the preliminary implant planning



Figs. 15b, c: Prosthetic mockup in acrylic mixed with 25 percent barium sulfate of a partially edentulous mandible (left) and a single tooth edentulous site (right).



Figs. 15d, e: Radiographic scan guide for implant planning of a partially edentulous mandible (left) and a single tooth edentulous site (right).

can begin. The scan will aid in determining the amount of bone volume present to achieve primary implant stability, and the grafting required to augment the surgical site at the time

of surgery. The implant planning can be easily shared with the entire implant team, including the patient, with the visual aid of the scan and computer. If it is determined from

the scan that there is not enough bone volume to place the implant, then significant alteration in the existing anatomy is required prior to implant placement.

After implant planning, the patient is ready for a workup for the surgical guide fabrication. Study models are made (Fig. 15a) and the prosthetic laboratory will wax-up anatomically accurate teeth or a prosthesis as per the treatment plan. The technician will then convert the wax-up into an acrylic prosthetic replica of the final restoration made of a 25 percent barium sulfate and acrylic mixture and embed the replica in a clear retainer (Figs. 15b, c) attached to a scan template (radiographic or scan guide) (Figs. 15d, e) to be worn by the patient during a scan to be used for the final implant planning (Fig. 16a).

The scan template has fiducial radiopaque markers that allow for accurate mounting of the stone model with the scan guide into the CAD/CAM milling machine that marks, drills and inserts the key hole sleeves into the scan guide, converting it into a surgical guide (Fig. 16b).

Following the simple process of marking the nerve canal and identifying vital proximal structures, the

→ II page 10

AD

## Benex® - Control Professional

Root Extraction Systems developed with Dr. Syle



Art.-No. BE001230001

- Safe and simple extraction of roots
- Maximal protection of the tooth socket
- Possibility of drilling even if minute root fragments or foreign bodies are present in the root
- Possibility of drilling independently of anatomic root canal



MEISINGER

GERMANY / USA



**Meisinger USA, L.L.C.**  
 7442 South Tucson Way • Suite 130 • Centennial • Colorado 80112 • USA  
 Tel.: +1 (303) 268-5400 • Fax: +1 (303) 268-5407 • E-Mail: info@meisingerusa.com  
 www.meisingerusa.com • www.bone-management.com • www.occlusalrouter.com