

# IMPLANT TRIBUNE

The World's Dental Implant Newspaper · U.S. Edition

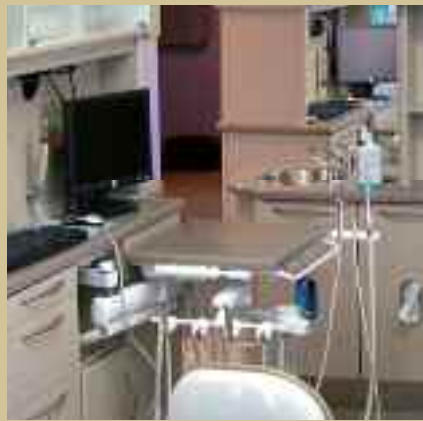JANUARY 2009

www.implant-tribune.com

VOL. 4, No. 1

## Inside this issue

### Run another practice?



What would you say if someone asked you to run two dental practices? Guess what? You already do! This article explains why implant dentistry is essentially an entirely separate practice within your practice.

Page 14

### Osteogenics event



Soak up the sun, the sights and new skills at Osteogenics Biomedical's first ever Global Bone Grafting Symposium in Scottsdale, Ariz.

Page 20

## AO in San Diego next month

2009 annual meeting to serve as testing ground for new treatments

The Academy of Osseointegration's 2009 Annual Meeting will offer attendees an intensive three-day scientific program that taps the expertise of renowned international speakers and serves as a testing ground for a range of new implant therapy technologies.

It will take place Thursday, Feb. 26 through Saturday, Feb. 28, at the San Diego Convention Center.

The meeting's theme, "A New Wave in Implant Therapy," reflects the program committee's goal of presenting a world-class program that offers new evidence for contemporary treatment, Program Chair-

→ **II** page 22



Picturesque San Diego is the site of the Academy of Osseointegration's February meeting.

## The Ankylos-SynCone Overdenture System: the biology, diagnosis and treatment

By David P. DiGiallorenzo, DMD

The SynCone Over Denture System is one restorative implant-supported removable option within the Ankylos Dental Implant System. The SynCone Over Denture System refers to the unique abutment-retainer design (Figs. 1, 1a).

SynCone has been developed for mandibular dentures with acceptable esthetics, phonetics and vertical dimension to be relined immediately and loaded at implant placement.<sup>1,2,18-21</sup>



Fig. 1: Syncone abutments.

However, a delayed approach can be utilized if needed and SynCone can be utilized on the maxillary arch as well.

The protocol utilizes four implants inserted between the men-

tal foreman. The technique is cost-effective and can be completed in a single visit. This is extremely advan-

→ **II** page 6

AD

Experience  
**EXCELLENCE**  
IN COSMETIC DENTISTRY 2009  
www.aacd.com • 800.543.9220  
21st Anniversary AACD Scientific Session  
Monday, April 27 - Friday, May 1, 2009 • Honolulu, Hawaii  
AMERICAN ACADEMY  
OF COSMETIC DENTISTRY  
CELEBRATING 25 YEARS OF EXCELLENCE

PRSRT STD  
U.S. Postage  
PAID  
Permit # 306  
Mechanicsburg, PA

# JOP study indicates oral cancer patients could be diagnosed earlier

Worldwide, more than 500,000 new cases of cancer of the mouth are diagnosed each year. The majority of these cancers are found too late, causing many people to die within five years of finding out they have cancer.

There exists much information addressing issues related to the patient who has undergone surgery or chemotherapy, but little information related to early diagnosis and referral.

In a new article in the *Journal of Prosthodontics*, researchers led by Michael A. Siegel, DDS, MS, FDS, RCSEd, describe the epidemiology of oral cancer and the diagnostic tools currently available to prosthodontists to ensure that their patients are diagnosed at the earliest possible time.

Although the need for prosthodontics was expected to decline with the promotion of preventive measures, it is actually increasing with

the aging population.

The highest risk of developing oral cancer is in adults older than 40 who use both tobacco and alcohol. However, these cancers can develop in anyone, so annual prosthodontist visits are increasingly important.

The majority of oral, head and neck cancer are initially diagnosed in a late stage, which has a five-year prognosis of less than 50 percent. If these tumors are found in their earliest stage, the five-year prognosis is 95 percent.

All dentists, including prosthodontists, are specifically trained to detect these tumors in an early stage. Only 28 percent of patients reported ever having had an oral cancer examination.

Patients who have lost their teeth must be specifically counseled about returning for prescribed, regular recall examinations. They may incorrectly believe that, as they do

not have all or any of their teeth, they do not need to be regularly followed by a prosthodontist.

Recently, several companies have marketed simple tests intended to aid the dentist in the early detection and diagnosis of oral lesions even before they turn into cancer; these tests are painless and relatively inexpensive. Any sore, lump, or bump in the mouth that bleeds, is enlarging or will not heal should be evaluated at the earliest possible time.

"If prosthodontists, and other dentists, are more vigilant in performing oral cancer screening examinations on all of their patients, the quality of life and survivability from these cancers will be greatly improved, whereby morbidity and mortality will be greatly reduced," the researchers conclude.

(Source: *The Journal of Prosthodontics*)

# New study on doctor-patient relationships shows technology impacts patient perceptions

## Groundbreaking survey of 23,000 dental patients by Sesame Communications confirms connection

Sesame Communications, provider of online software and services to the dental industry, released results from a new survey that revealed that the use of Internet technology greatly influences patient perceptions, among other findings.

Patients associate their doctor's adoption of the latest online technologies and tools with advanced clinical skills, treatment methods, materials, and procedures.

These findings, along with other results and insights, are summarized in a new whitepaper titled "Technology Meets Tradition."

The findings and content are based on more than 23,000 dental patient surveys submitted January through October 2008, across the United States and Canada.

Believed to be the largest study of its kind ever conducted, the whitepaper is now available for free download at [www.sesamecommunications.com](http://www.sesamecommunications.com).

"Patients have spoken, and they're online," said Frith Maier, CEO and founder of Sesame Communications. "Patients are demanding online access and interaction on their terms. Doctors risk being left behind unless they get online."

Other findings in the "Technology

Meets Tradition" whitepaper include:

- **E-mail trumps phone calls.** Patients expressed an overwhelming preference for e-mail as they increasingly manage their health and dental care online. E-mail was preferred by more than 3:1 over traditional phone calls for appointment reminders and other communication.

- **Financial visibility and online payment embraced by patients.** More than 80 percent of patients surveyed expressed comfort with making payments online and more than 40 percent enthusiastically endorsed it.

"Being a great dentist means a lot more than being an expert on teeth. A truly great dentist must also be a good communicator," said Dr. Larry Emmott, president of Emmott on Technology. "This study clearly shows that now more than ever before, being online is critical to enhancing communication and building the doctor-patient relationship."

### About Sesame Communications

Sesame Communications is a premier provider of online products and services for the dental industry. Sesame supports the largest online channel in dentistry, with nearly 2 million patients logging on for information and electronic alerts from their dental professionals.

Sesame delivers a comprehensive solution, which enables doctors to enhance patient relationships and practice profitability by improving staff productivity, enhancing practice marketing and increasing patient referrals. More than 15,000 dental

providers are registered for Sesame Interactive, which streamlines communications between dentists and specialists and improves treatment planning.

Sesame is privately held and headquartered in Seattle, Wash., and can be found at [www.sesamecommunications.com](http://www.sesamecommunications.com) or by calling (877) 633-5195.

## Tell us what you think!

Do you have general comments or criticism you would like to share? Is there a particular topic you would like to see more articles about? Let us know by e-mailing us at [feedback@dtamerica.com](mailto:feedback@dtamerica.com). If you would like to make any change to your subscription (name, address or to opt out) please send us an e-mail at [database@dtamerica.com](mailto:database@dtamerica.com) and be sure to include which publication you are referring to. Also, please note that subscription changes can take up to six weeks to process.

### IT Corrections

Implant Tribune strives to maintain the utmost accuracy in its news and clinical reports. If you find a factual error or content that requires clarification, please report the details to Managing Editor Sierra Rendon at [s.rendon@dtamerica.com](mailto:s.rendon@dtamerica.com).

## IMPLANT TRIBUNE

The World's Newspaper of Implantology - U.S. Edition

**Publisher**  
Torsten Oemus  
[t.oemus@dtamerica.com](mailto:t.oemus@dtamerica.com)

**President**  
Peter Witteczek  
[p.witteczek@dtamerica.com](mailto:p.witteczek@dtamerica.com)

**Chief operating officer**  
Eric Seid  
[e.seid@dtamerica.com](mailto:e.seid@dtamerica.com)

**Group Editor**  
Robin Goodman  
[r.goodman@dtamerica.com](mailto:r.goodman@dtamerica.com)

**Editor in Chief**  
Sascha A. Jovanovic, DDS, MS  
[sahara@jovanoviconline.com](mailto:sahara@jovanoviconline.com)

**Managing Editor/Designer**  
Sierra J. Rendon  
[s.rendon@dtamerica.com](mailto:s.rendon@dtamerica.com)

**Managing Editor Endo Tribune**  
Fred Michmershuizen  
[f.michmershuizen@dtamerica.com](mailto:f.michmershuizen@dtamerica.com)

**Managing Editor Ortho Tribune**  
Kristine Colker  
[k.colker@dtamerica.com](mailto:k.colker@dtamerica.com)

**Account Manager**  
Humberto Estrada  
[h.estrada@dtamerica.com](mailto:h.estrada@dtamerica.com)

**Marketing Manager**  
Anna Wlodarczyk  
[a.wlodarczyk@dtamerica.com](mailto:a.wlodarczyk@dtamerica.com)

**Marketing & Sales Assistant**  
Lorrie Young  
[l.young@dtamerica.com](mailto:l.young@dtamerica.com)

**C.E. Manager**  
Julia Wehkamp  
[j.wehkamp@dtamerica.com](mailto:j.wehkamp@dtamerica.com)

**Design Support**  
Yodit Tesfaye  
[y.tesfaye@dtamerica.com](mailto:y.tesfaye@dtamerica.com)

Dental Tribune America, LLC  
215 West 35th Street, Suite 801  
New York, NY 10001  
Phone: (212) 244-7181, Fax: (212) 244-7185



Published by Dental Tribune America

© 2008, Dental Tribune International GmbH. All rights reserved.

Dental Tribune makes every effort to report clinical information and manufacturer's product news accurately, but cannot assume responsibility for the validity of product claims, or for typographical errors. The publishers also do not assume responsibility for product names or claims, or statements made by advertisers. Opinions expressed by authors are their own and may not reflect those of Dental Tribune International.

### Editorial Advisory Board

**Dr. Sascha Jovanovic, Editor in Chief**

Dr. Bernard Touati

Dr. J.T. Krauser

Dr. Andre Saadoun

Dr. Gary Henkel

Dr. Doug Deporter

Dr. Michael Norton

Dr. Ken Serota

Dr. Axel Zoellner

Dr. Glen Liddelow

Dr. Marius Steigmann



SURGICAL SUPPLY CO., INC.

# A POWER TRIO

FOR ALL YOUR GRAFTING NEEDS



Power-up your  
in-office performance  
with an ACE seminar!

## ADVANCED TISSUE GRAFTING

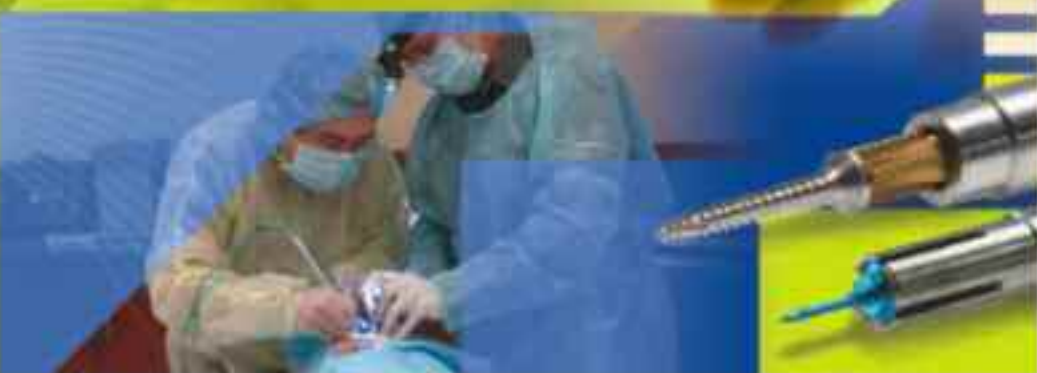2-DAY HANDS-ON CADAVER WORKSHOP

**ORLANDO, FL**  
April 25-26, 2009

**Featured Speakers:**  
Ron Grotzer, PhD, DGS, FRCGS, FRCR

**Course Location:**  
Walt Disney World Swan and Dolphin

**Course Registration:**  
[www.acesurgical.com/cadaver.html](http://www.acesurgical.com/cadaver.html)



800.441.3100

[www.acesurgical.com](http://www.acesurgical.com)

ACE Surgical Supply Company, Inc.  
1000 Peachtree Street, Suite 500, Atlanta, GA 30309

# A new twist on surgical guides

## Dr. Bavar presents new technique in *Journal of Oral Implantology*

Surgical guides have long been used to help dentists record implant locations and angulations for dentures and bridges.

With the advent of computer-assisted tomography (CT), dentists can map the patient's available bone, placement of prosthetic teeth and bite impression and produce a surgical guide before the patient undergoes any procedure. However, currently available surgical guide techniques have certain shortcomings: some require multiple guides for different-sized drilling, are unstable or do not record the rota-



Dr. Trevor Bavar

tional position of implants, whereas others have accounted for these issues but do not allow custom molds and abutments to be made, resulting in inaccurate or poorly fitting prostheses.

In the latest issue of the *Journal of Oral Implantology*, Trevor Bavar, DDS, presents a new technique that

resolves these deficiencies. This technique uses a single guide with reduction sleeves to accommodate different-sized drilling, records implant positioning and angles on the guide and creates an index, generates custom copings and abutments and replaces an acrylic temporary yet aesthetic bridge in one visit. Using the custom measurements from the index and bite registration, the final prosthetic can be created and the completed bridge can be installed in just three noninvasive follow-up visits.

Using this index and guide system, surgical specialists and restorative dentists can work separately or as a team to address aesthetic, prosthetic and implant needs simultaneously.

To read the entire study, go to: <http://www.allenpress.com/pdf/ORI>

*M34.610.15631548-1336-34.6.pdf*

The *Journal of Oral Implantology* is the official publication of the American Academy of Implant Dentistry and of the American Academy of Implant Prosthodontics.

It is dedicated to providing valuable information to general dentists, oral surgeons, prosthodontists, periodontists, scientists, laboratory owners and technicians, manufacturers and educators. Implant basics, prosthetics, pharmaceuticals, the latest research in implantology, implant surgery and advanced implant procedures are some of the topics covered.

For more information, visit <http://www.joionline.org/orimonline/?request=index-html>.

(Source: *Journal of Oral Implantology*)

## 'The Stealth Killer: Is Oral Spirochetosis the Missing Link in the Dental-Heart Disease Labyrinth?'

By William D. Nordquist, BS, DMD, MS

The discovered relationship between dental and heart disease announced by the United States surgeon general in 2000 has necessitated a unique cooperation between dentistry and medicine.

Patients who have systemic diseases, such as heart disease, diabetes, and other chronic diseases, such as Alzheimer's disease also have multiple missing teeth. As a result of the missing teeth, these are the patients who require the services of implant dentists. Implant dentistry then requires dentists to understand these diseases and the many medicines that these patients are taking to treat their many ailments.

Scientific studies have definitely shown a relationship between periodontal disease and heart disease. With this new understanding, the dentist's role in medicine has been dramatically elevated. Dentists are now responsible for diagnosing and treating gum disease because it is related to diseases that affect other parts of the body, not just the mouth. Is there a cause and effect; dental disease causing heart disease? Are bacteria that cause periodontal disease also causing heart disease? That seems to be the case.

The recently released book by William D. Nordquist, "The Stealth Killer: Is Oral Spirochetosis the Missing Link in the Dental-Heart Disease Labyrinth?", connects the dots from 100-plus years of dental and medical research to establish a compelling hypothesis to explain



the missing link between dental and systemic disease. These are serious questions and they greatly increase the responsibility of dentists for their patients who need dental implants

An extensive review in the medical and dental literature, plus eight years of microscopic investigation in Nordquist's laboratory, reveals some very important clues in the search for the relationship between dental and heart disease.

Some important facts are:

- Both periodontal disease and heart disease are in epidemic proportions in the modern age, especially after World War II.
- More people die of heart disease than all other diseases combined.
- By the time most people reach a "ripe old age," they have some form of heart disease.
- Seventy-five to seventy-eight percent of people have some form

of gum disease.

Even though dental disease has been prevalent since the recording of history, it took a very virulent turn in World War I with the disease Vincent's infection (trench mouth), named after its discoverer.

Vincent's disease is primarily a spirochete bacterial infection. Spirochetes are involved with gum disease today. Spirochetes cause other serious diseases such as, Lyme disease, syphilis and stomach ulcers, as well as other lesser known debilitating diseases. Microscopic research on syphilis in the early 1900s revealed that syphilis has a unique "life cycle."

When the bacteria are treated with an antibiotic or the immune system itself attacks it, the bacteria undergo a morphogenic change and become a "spore." The disease is almost impossible to completely eradicate. It has also been reported in the older literature that oral

### Information

The book will be available toward the end of January at:

[www.lymbook.com](http://www.lymbook.com)  
[www.amazon.com](http://www.amazon.com)

Dr. Nordquist's research blog with videos of figures and other resource information is located at:

[www.lymebook.com/nordquist](http://www.lymebook.com/nordquist)



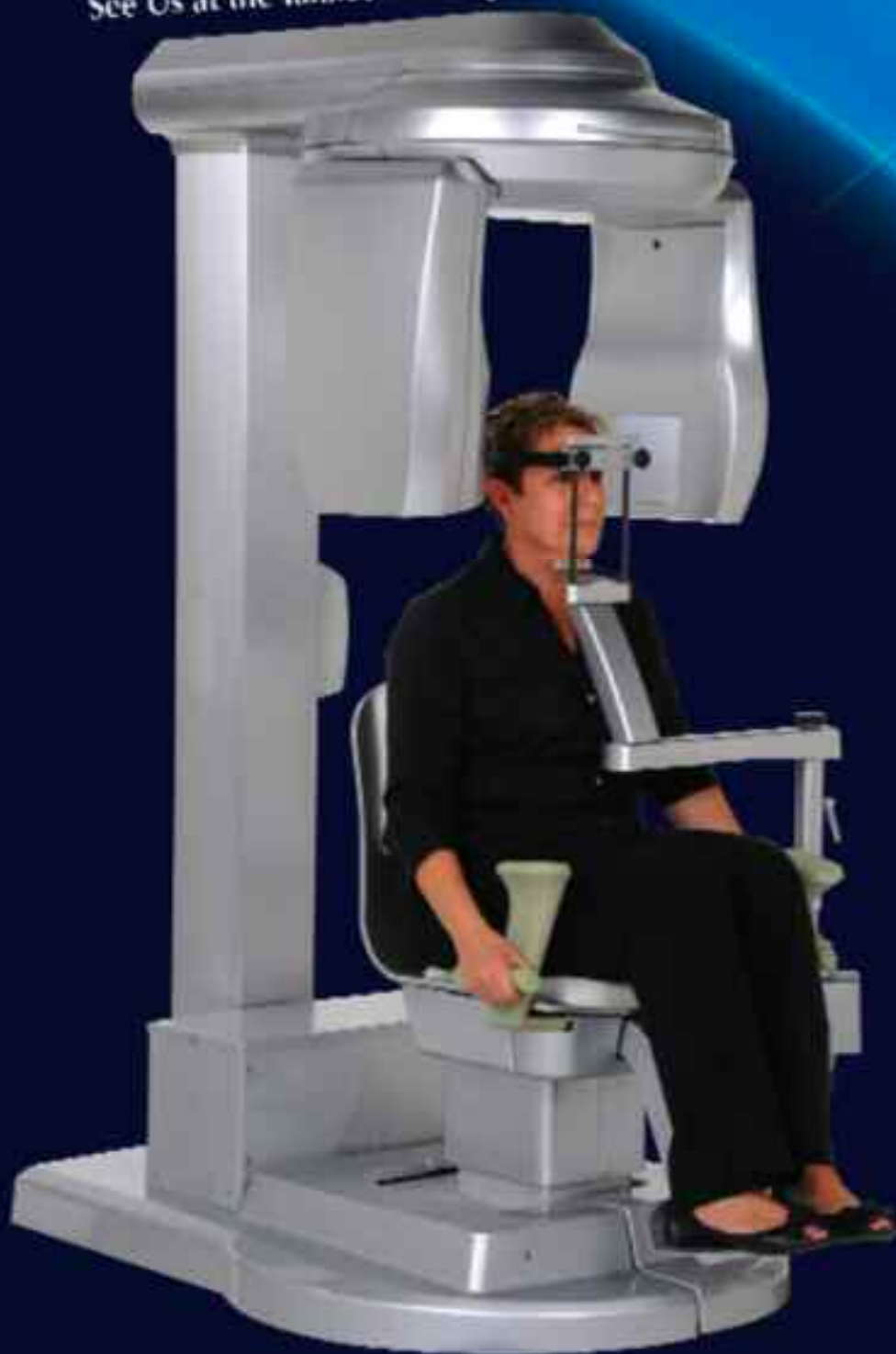spirochetes also produce these "spores." Research has shown that the Lyme disease *Borrelia spirochete* also has a similar "life cycle" and produces "spores" and "cysts" forms.

This life cycle of oral bacteria makes the treatment of gum disease very difficult, if not impossible. Once periodontal surgery is completed, if not done on highly compliant patients, it usually returns and additional surgeries are required, but the surgeries rarely ever cure the disease. Could oral spirochetes and their unique life cycles have something to do with heart disease? Almost certainly.

Research is now being initiated on a grand scale into this relational problem between dental and heart disease. Many more theories and solutions will be reported as dentists and doctors work together to better understand and treat this problem.

# 30 Seconds To A Perfect Solution

See Us at the Yankee Meeting: Booth #1410



The PreXion 3D Dental Cone Beam Scanner processes images *in only 30 seconds.*

Additional benefits include:

- Highest resolution of any Cone Beam System
- More detail through proprietary XTrillion Processor
- Powerful Diagnostic 3D Planning Tools
- **NEW** Four different scanning modes
- Ideal for Implant Planning
- Available FOV 8cm x 8cm or 5cm x 5cm
- Small Foot Print of only 39" x 59" fits anywhere

Please ask us about  
Below Prime Financing or  
6 Month No Payments

## PreXion

Call us today for an in-office demonstration at (650) 212-0300  
info@prexion3d.com • www.prexion3d.com

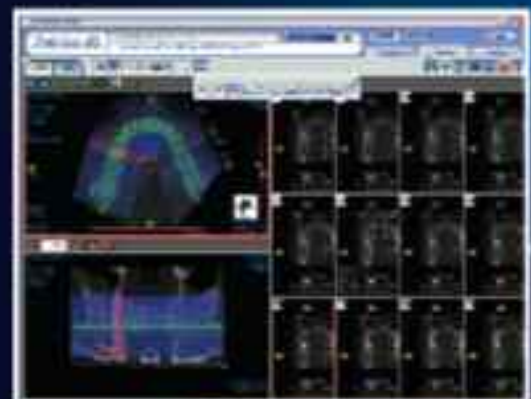
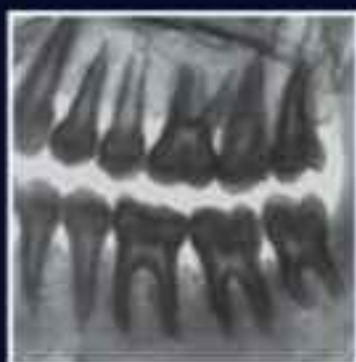
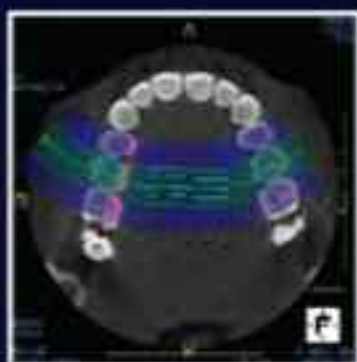
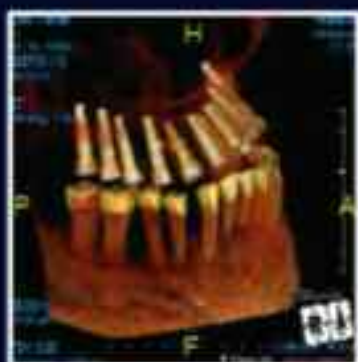

Fig. 1a: SynCone retainers and abutments.

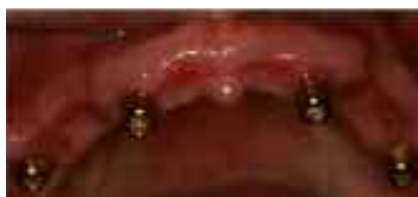

Fig. 2: Locators attachments.

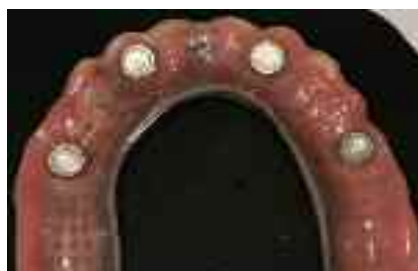

Fig. 3: Horseshoes Flangeless Ovate Pontic Locator retained.

← **II** page 1

tageous for the baby boomer and elderly population, where immediacy is important.

The SynCone system relies on a unique stock pre-machined titanium abutment, which comes in either a 4- or 6-degree taper. The abutments come in a 15-degree angle correction if needed and can be rotated 360 degrees for precise alignment. The corresponding gold retainers come in either a 4- or 6-degree matching taper (Fig. 1a). The unique fit of the gold retainers on the titanium abutments ensures an unimpeded fit. A settling phenomenon improves the retention as the patient functions over time.

Patient selection should include healthy patients with adequate bone quality and quantity, healthy tissues and a stable existing denture and therapeutic occlusion.

Preoperative assessments must include bone quality, quantity, occlusion and keratinized tissue location on the residual ridge crest. If the existing denture is going to be used for the immediate chairside relined, then there must be enough room for the abutment and retainer height of 5 mm, otherwise a new denture must be fabricated. If this is the case, then a delayed approach is prudent. Another option, when there is limited space within the denture, would be to use a locator attachment on the Ankylos implant, which will require only 3.14 mm of height. This becomes important when utilizing a maxillary flangeless ovate pontic design horseshoe denture (Figs. 2, 3).

If conventional radiography is used, the existing denture or a duplicate denture can be used as a surgical guide. A crestal incision will be indicated. Splitting the mucosa on the ridge crest may be indicated to create a broader zone of keratinized tissue on the facial or lingual.

Moreover, consideration should be given to allowing the ridge to granulate in by secondary intention to create a broader zone of keratinized tissue when there is lack of peri-implant keratinized tissue. Without a CAT scan, surgical visualization and identification of the mental foramen is crucial at surgery through full thickness blunt dissection (Fig. 4). This will reduce any chance of paresthesia. Implant placement should begin 5 mm anterior to the neurovascular bundle and proceed forward from this implant (Fig. 5). Early cadaver and CT scanning studies have indicated an anterior loop of the neurovascular bundle in a small percentage of the population.<sup>22</sup>

CT scanning technology such as SimPlant (Materialise Dental) is the preferred option for treatment planning. Here you have a choice of either a tissue-supported surgical guide or bone-supported surgi-

AD

# ACHIEVE

# TOTAL IMPLANT SUCCESS™

## DESPITE TODAY'S ECONOMY

1. You must have a proven referral marketing program for your practice to grow.
2. Your implant practice is your best investment.
3. Strong, documented systems will position your implant practice for greater success in this economy.
4. Levin Group systems increase profitability.
5. The Levin Group Method™ will grow your best investment.

Don't Wait—We Have The Answers!

**Las Vegas, NV**  
February 18 - 19, 2009

**Chicago, IL**  
April 15 - 16, 2009

**Nashville, TN**  
June 10 - 11, 2009

REGISTER NOW!

for an upcoming  
**Total Implant Success™ Seminar!**

Limited Seating Available

Levin Group Inc.

Implant Division

www.levingroupimplant.com

888.973.0000

→ **II** page 8

# OSTEOGENICS' 2009 GLOBAL BONE GRAFTING SYMPOSIUM

WESTIN KIERLAND RESORT & SPA :: SCOTTSDALE, ARIZONA :: APRIL 3-4, 2009

## SYMPOSIUM HIGHLIGHTS:

*Latest research*

*World-renowned speakers*

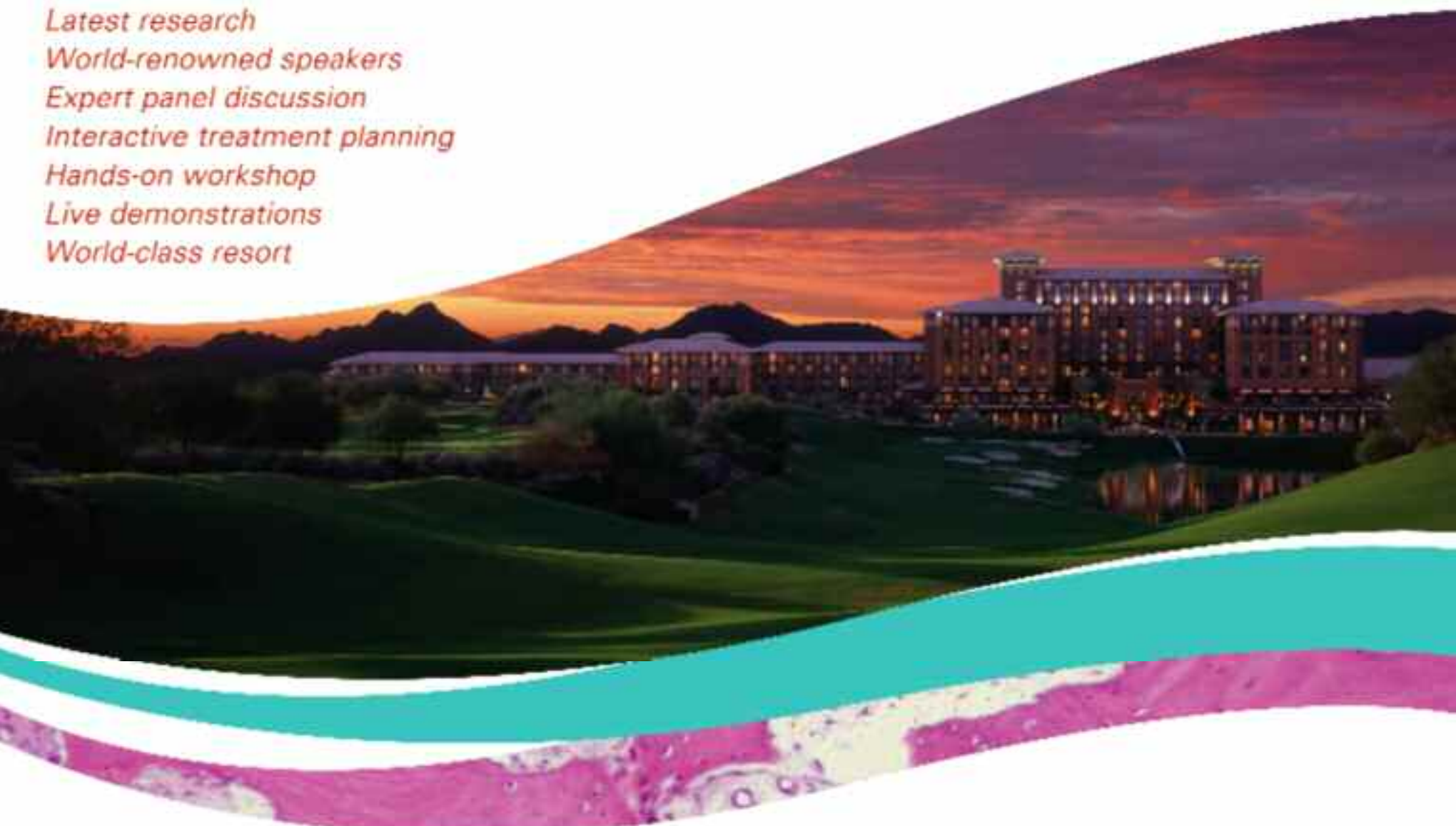*Expert panel discussion*

*Interactive treatment planning*

*Hands-on workshop*

*Live demonstrations*

*World-class resort*



**BARRY BARTEE,  
DDS, MD**

*Ridge Preservation  
After Extraction:  
Myths and Reality*



**HENRY GREENWELL,  
DMD, JD, MSD**

*A Comparison of Techniques  
and Predictability of  
Ridge Preservation and  
Ridge Augmentation Procedures*



**EIJI FUNAKOSHI,  
DDS, MSD**

*Socket Preservation and  
Ridge Augmentation  
Utilizing Open Barrier  
Membrane Technique*



**DANIEL CULLUM,  
DDS**

*Ridge Expansion in the  
Regenerative Treatment  
Paradigm*



**JEFFREY LEMLER,  
DDS**

*Horizontal and Vertical Alveolar  
Ridge Augmentation: Advanced  
Techniques to Enhance Function  
and Esthetics*

## SYMPOSIUM REGISTRATION

**\$595 :: REGISTER BY MARCH 3, 2009 (NONREFUNDABLE AFTER MARCH 3, 2009)**

**ASSISTANTS AND OFFICE PERSONNEL ARE WELCOME AT \$150/PERSON**

**CALL 1.888.796.1923 TO REGISTER**

FOR MORE INFORMATION CALL 1.888.796.1923

**OSTEOGENICS**  
CLINICAL EDUCATION

← **II** page 6

guide. With this software, virtual placement of the implants and development of the surgi-guide will ensure a precise understanding of implant angulation, available bone, regenerative needs and abutment selection (Fig. 6). When diagnosed, incision-less techniques can be utilized. Because alignment must be within 5 degrees with the SynCone technique, a surgi-guide will ensure success (Fig. 7).

Preoperative medications include amoxicillin 500 mg one day prior and then every six hours and Motrin 800 mg beginning the day of procedure and additionally as needed. Finally, Peridex rinses three times daily until wound closure or complete healing. A Medrol Dose Pack can be considered as well.

**Case 1**

This edentulous 60-year-old female presented with a chief complaint: "I cannot eat; my lower denture moves during function" (Fig. 7a). After bilateral mandibular blocks and localized infiltration, a crestal incision is extended on the edentulous ridge. The residual alveolar ridge is leveled utilizing piezosurgery to create a broad flat ridge to begin the initial osteotomies (Figs. 7b, 7c).

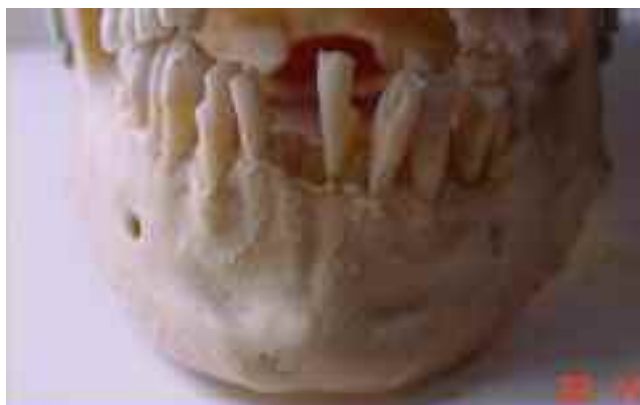

Fig. 4: Cadaver view of mental foremen.

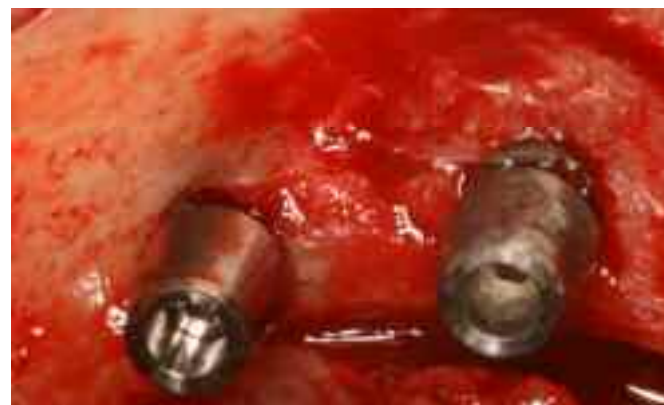

Fig. 5: Place first implant 5 mm anterior to mental foremen.



Fig. 6: SimPlant software.



Fig. 7: SimPlant Surgi-guide Bone Supported.

The optimal configuration is four implants placed from mental foreman to foremen (Fig. 8). Four 3.5 mm diameter by 11 mm high are a minimum requirement for the SynCone technique. If 14 mm implants are possible, this is ideal, as most of the early fixation is mechanical in nature. A longer and/or wider

implant will provide more primary stability reducing any chance of excessive micro-movement at the bone implant interface as secondary biologic fixation occurs.

The unique surgical protocol is to place the Ankylos implant 1 to 2 mm below the crest of bone<sup>1,2</sup> (Fig. 9). The unique sub-crestal positioning

is possible as a result of horizontal and vertical room created by the medialized implant abutment connection. This offset creates the necessary room for the soft tissue to reattach. Thus, there is a supra-cre-

→ **II** page 10

AD

## Benex® - Control Professional

Root Extraction Systems



Art.-No. 8E00(23000)

- Safe and simple extraction of roots
- Maximal protection of the tooth socket
- Possibility of drilling even if misrouted root fragments or foreign bodies are present in the root
- Possibility of drilling independently of anatomic root canal

MEISINGER

GERMANY / U.S.





**Meisinger USA, L.L.C.**  
 2442 South Tower Way • Suite 130 • Colorado • Colorado 80112 • USA  
 Tel.: +1 (303) 266-9400 • Fax: +1 (303) 266-9407 • E-Mail: info@meisingerusa.com  
 www.meisingerusa.com • www.meisingergermany.com • www.meisingerusa.com



# VANCOUVER, CANADA

August 20-22, 2009 ❖ Vancouver Convention Centre

## ICOI World Congress XXVI 12<sup>th</sup> Annual IPS Symposium and 12<sup>th</sup> Congress of the Asia Pacific Section



For more information please contact the ICOI Central Office  
at (973) 783-6300 or visit our website at [www.icoi.org](http://www.icoi.org)

**ADAC·E·R·P**  
Continuing Education Recognition Program

The ICOI is an ADA CEIOT  
recognized provider.

ACEP - Accepted Program Provider  
FACET MAGAZINE Credit, CEIOT - CEIOT

Sponsored by:



Photo Credit: Tourism Vancouver