

# ENDO TRIBUNE

The World's Endodontic Newspaper · U.S. Edition

NOVEMBER 2008

www.endo-tribune.com

VOL. 3, No. 11

## Inside this issue

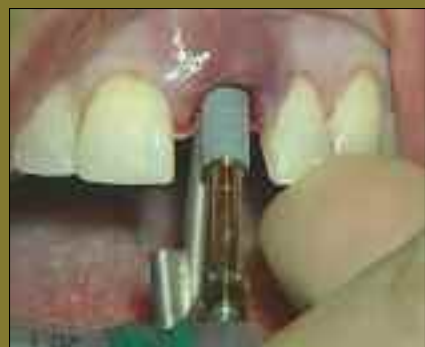Berlin Masters  
is June 26–27



Berlin Masters — featuring the annual Roots Summit and Implants Summit — will be held in Berlin June 26 and 27, 2009. Both summits, which will run parallel to one another, will feature hands-on training and lectures from the top names in dentistry worldwide.

Page 2

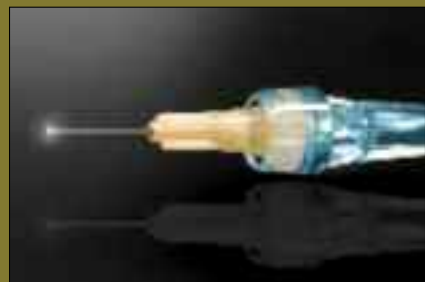## The emergency implant procedure



Sometimes patients present with unscheduled emergency conditions that require immediate tooth removal. Unrestorable crown and root fractures are often ideal clinical scenarios for immediate implant placement.

Page 7

## Profound anesthesia with the STA System



Thanks to the Computer Controlled Local Anesthesia Delivery System (CCLAD) known as the STA Anesthesia System by Milestone Scientific, endodontic procedures can be stress-free for practitioners and their patients.

Page 10

# Treatment planning for optimal endodontic results

*Dr. Mounce will perform a live endodontic demonstration at the Greater New York Dental Meeting on Dec. 2 and 3. He has written an introductory piece to discuss some of the exciting technology (the Twisted File and the RealSeal One Bonded Obturator, SybronEndo, Orange, Calif.) that attendees will see in the demonstrations.*

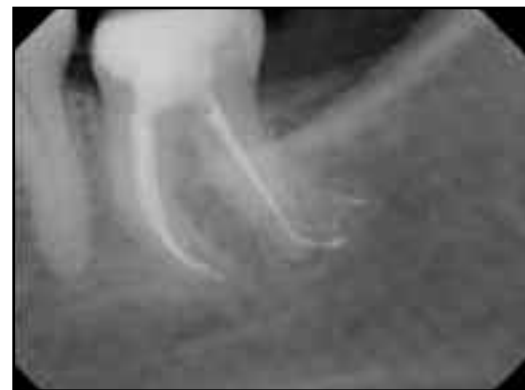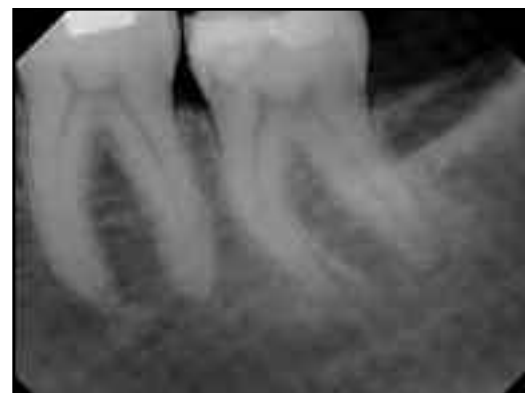By Richard E. Mounce, DDS

It has always been a strong bias of mine that great endodontic results are the outcome of a process that is planned and well organized from the start. Planning in this context includes assessing that the given clinician is the best person to tackle the case at hand and bring the needed experience, equipment, training and time to the case. As part of the needed preoperative planning, prior to starting any endodontic procedure, the case should be carefully assessed for iatrogenic risk factors and strategies should be developed to avoid these possible problems.

For example, an examination of the case shown in Figure 1a (#18), demonstrates a risk of perforation on the mesial root, though not an extreme one. The mesial root is also at risk of rotary nickel titanium file

fracture, especially if a large rotary nickel titanium instrument is inserted into the root with too much force in the absence of an adequate glide path. Figure 1b shows the completion of treatment.

All treatment should be carried out under the rubber dam after profound anesthesia has been obtained. Access should be straight line with the cervical dentinal triangle removed. All unsupported tooth structure is removed and all canals located before proceeding below the orifice. Ideally, treatment is performed under a surgical operating microscope (SOM) (Global Surgical, St. Louis, Mo.) for not just optimal visualization but optimal tactile control over the treatment process.



Figs. 1a, 1b: The clinical case mentioned.

The choice of a rotary nickel titanium file (brand, design, taper, tip

→ **ET** page 4

# Take a bite of New York's education apple

By Robin Goodman, Group Editor

Get ready to sink your teeth into the Big Apple in a way that only the Greater New York Dental Meeting can provide.

With a myriad of new programs on and off the exhibit floor as well as seminars and workshops, you'll want to plan your time carefully.

You definitely won't want to miss the first Dental Tribune Symposia, to be held from Sunday, Nov. 30, to Wednesday, Dec. 3, where you can learn all you need to know about "getting started in" endodontics, implantology, cosmetic dentistry or digital dentistry.

You can also witness "Live Dentistry" on the exhibition floor, where you can watch procedures that showcase the latest in dental technologies and materials. Also on

the exhibit floor, in glass-enclosed areas, you can attend workshops that will present a broad spectrum of up-to-date, hands-on procedures. You can even earn one hour of C.E. credit for walking the expanded exhibition floor, home to more than 1,500 booths overflowing with information and demonstrations on the latest innovations in dentistry.

Dental Tribune America is the official media partner of the meeting, so look for our show daily editions as you enter the convention center from Nov. 30 to Dec. 3.

For more information about the offerings of the Dental Tribune Symposia, please look inside this issue of Endo Tribune.

Illustration by Yodit Tesfaye Walker



PRSRT STD  
U.S. Postage  
PAID  
Permit # 506  
Mechanicsburg, PA

# Dental Tribune to hold Berlin Masters

Dental Tribune recently announced that Berlin Masters — featuring the annual Roots Summit and Implants Summit — will be held in Berlin on June 26 and 27, 2009.

As the cultural hub of modern Germany, Berlin ranks with London, New York and Paris as one of the great cities of the world. Berlin is one of the most important cities in Europe and can cater to the most diverse tastes during the day and certainly provide enough highbrow entertainment to fully justify indulging in the city's nightlife later. Also ranking among the worldwide top international conference locations, Berlin will be the perfect destination for dentists to enjoy the tradition of the Summit. Located in the center of the city, the event will take place in the Hotel Palace Berlin, one of the most renowned



hotels in the German capital.

Both the Roots Summit and the Implants Summit, which will run parallel to one another, will feature hands-on training as well as lecture presentations from the top names in dentistry worldwide.

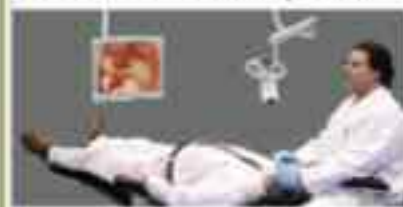Dental Tribune International invites you to join clinicians from all over the world as they come together

and learn about the latest techniques, products and innovations in the fields of endodontics and implantology.

Program details will follow in future issues of Endo Tribune.

In the meantime, if you have any questions, please contact Julia Wehkamp at (416) 907-9836 or [j.wehkamp@dtamerica.com](mailto:j.wehkamp@dtamerica.com).

## Enhancing your dentistry: Get out of dentistry alive!



Don't miss Randy Donahoo's lecture at the Dental Tribune Symposia during the Greater N.Y. Dental Meeting at 1:30-2:30 p.m. on Dec. 2.

This course will provide you with an opportunity to see for yourself how the benefits of "treating up" dentistry can enhance your practice. Experience first hand the Dental Procedure Scope, a life-changing device that provides increased magnification, superior lighting and improved ergonomics all in one device. The lecture will provide an overview of how Dental Procedure Scopes work, their capabilities and the ease of which they can be incorporated into your daily routine. Learn how they can enhance your practice and put the fun back into dentistry. It's just a wonderful way to spend your day!

**MagnaVu**  
Original Video Dentistry

## Minimally invasive dentistry in rapid-fire fashion



Don't miss Dr. Jesse's and Dr. Kaminer's lecture at the Dental Tribune Symposia during the Greater N.Y. Dental Meeting at 3-4 p.m. on Dec. 1.

Topics to be discussed include the following: caries management by risk assessment; current concepts in cariology; minimally invasive endodontics; bonded fiber posts; dental lasers; minimally invasive periodontics; current advances in tooth whitening; bonding agents; separating the truth from the hype; and much more. This program will introduce concepts that will change the way you practice forever.

**ULTRADENT**  
PRODUCTS, INC.

## Using 3-D X-ray imaging and planning to increase patient treatment acceptance



Catch Dr. Patel's lecture at the Dental Tribune Symposia during the Greater N.Y. Dental Meeting at 10 a.m.-1 p.m. on Dec. 1.

Dr. Patel will share a practical perspective of cone beam technology and its multiple uses in "real world" private practice. He will shed light on what the future has to offer and give insight into the impact CBCT technology can have from a business standpoint — return on investment (ROI)! By the end of the presentation, attendees should:

- ▶ Understand how 3-D technology can benefit the modern dental practice.
- ▶ Learn how state-of-the-art 3-D digital dentistry is being done today.
- ▶ Acquire the tools for implementing 3-D X-ray imaging and software in their practice.

**sirona**  
THE DENTAL COMPANY

**Earn C.E. credits! Attendance is free for all GNYDM visitors!**

For more information and registration, please contact Julia Wehkamp: [j.wehkamp@dtamerica.com](mailto:j.wehkamp@dtamerica.com).

## ET Corrections

Endo Tribune strives to maintain the utmost accuracy in its news and clinical reports. If you find a factual error or content that requires clarification, please report the details to Fred Michmershuizen, managing editor, at [f.michmershuizen@dtamerica.com](mailto:f.michmershuizen@dtamerica.com).

## Tell us what you think!

Do you have general comments or criticism you would like to share? Is there a particular topic you would like to see more articles about? Let us know by e-mailing us at [feedback@dtamerica.com](mailto:feedback@dtamerica.com). If you would like to make any change to your subscription (name, address or to opt out) please send us an e-mail at [database@dtamerica.com](mailto:database@dtamerica.com) and be sure to include which publication you are referring to. Also, please note that subscription changes can take up to 6 weeks to process.

## ENDO TRIBUNE

The World's Endodontic Newspaper - U.S. Edition

**Publisher**  
Torsten R. Oemus  
[t.oemus@dtamerica.com](mailto:t.oemus@dtamerica.com)

**President**  
Eric Seid  
[e.seid@dtamerica.com](mailto:e.seid@dtamerica.com)

**Group Editor**  
Robin Goodman  
[r.goodman@dtamerica.com](mailto:r.goodman@dtamerica.com)

**Editor-in-Chief Endo Tribune**  
Frederic Barnett, DMD  
[BarnettF@einstein.edu](mailto:BarnettF@einstein.edu)

**International Editor Endo Tribune**  
Prof. Dr. Arnaldo Castellucci

**Managing Editor Endo Tribune**  
Mr. Fred Michmershuizen  
[f.michmershuizen@dtamerica.com](mailto:f.michmershuizen@dtamerica.com)

**Managing Editor Implant Tribune**  
Sierra Rendon  
[s.rendon@dtamerica.com](mailto:s.rendon@dtamerica.com)

**Managing Editor Ortho Tribune**  
Kristine Colker  
[k.colker@dtamerica.com](mailto:k.colker@dtamerica.com)

**Product & Account Manager**  
Humberto Estrada  
[h.estrada@dtamerica.com](mailto:h.estrada@dtamerica.com)

**Marketing Manager**  
Anna Wlodarczyk-Kataoka  
[a.wlodarczyk@dtamerica.com](mailto:a.wlodarczyk@dtamerica.com)

**Marketing & Sales Assistant**  
Lorrie Young  
[l.young@dtamerica.com](mailto:l.young@dtamerica.com)

**C.E. Manager**  
Julia Wehkamp  
[j.wehkamp@dtamerica.com](mailto:j.wehkamp@dtamerica.com)

**Design Support**  
Yodit Tesfaye  
[y.tesfaye@dtamerica.com](mailto:y.tesfaye@dtamerica.com)

Dental Tribune America, LLC  
215 West 55<sup>th</sup> Street, Suite #801  
New York, NY 10001  
Tel.: (212) 244-7181  
Fax: (212) 244-7185



Published by Dental Tribune America  
© 2008, Dental Tribune America, LLC.  
All rights reserved.


Dental Tribune America makes every effort to report clinical information and manufacturer's product news accurately, but cannot assume responsibility for the validity of product claims, or for typographical errors. The publishers also do not assume responsibility for product names or claims, or statements made by advertisers. Opinions expressed by authors are their own and may not reflect those of Dental Tribune America.

## Editorial Advisory Board

Frederic Barnett, DMD (*Editor-in-Chief*)  
Roman Borczyk, DDS  
L. Stephen Buchanan, DDS, FICD, FACD  
Gary B. Carr, DDS  
Prof. Dr. Arnaldo Castellucci  
Joseph S. Dovgan, DDS, MS, PC  
Unni Endal, DDS  
Fernando Goldberg, DDS, PhD  
Vladimir Gorokhovskiy, PhD  
Fabio G.M. Gorni, DDS  
James L. Gutmann, DDS, PhD (honoris causa), Cert Endo, FACD, FICD, FADI  
William "Ben" Johnson, DDS  
Kenneth Koch, DMD  
Sergio Kuttler, DDS  
John T. McSpadden, DDS  
Richard E. Mounce, DDS, PC  
John Nusstein, DDS, MS  
Ove A. Peters, PD Dr. med dent., MS, FICD  
David B. Rosenberg, DDS  
Dr. Clifford J. Ruddle, DDS, FACD, FICD  
William P. Saunders, PhD, BDS, FDS, RCS Edin  
Kenneth S. Serota, DDS, MMSc  
Asgeir Sigurdsson, DDS  
Yoshitsugu Terauchi, DDS  
John D. West, DDS, MSD

## Exclusively from Ultradent...

The world's smallest cannula reaches more intricate canal spaces while sideports enable safe delivery of irrigants.



### Ultradent NaviTip® 31ga Sideport Irrigator Tip

**SAFE:** Sideports allow irrigants to flow out of the side of the cannula, limiting the possibility of any chemicals being expressed past the apex.

**PRECISE:** The narrow 31ga cannula enters smaller places and navigates tight canals better than larger tips for the most precise treatment available.

800.552.5512 [ULTRADENT.COM](http://ULTRADENT.COM)

© 2008 Ultradent Products, Inc. All rights reserved.



**SAVE 25% ON YOUR FIRST PURCHASE OF A 20 OR 50 PACK**

LIMITED TIME OFFER ENDS DECEMBER 31, 2008 • LIMIT OF 10 • MENTION SOURCE CODE 8K02

**ULTRADENT**  
PRODUCTS, INC.

*Improving Oral Health Globally*

# Treatment planning

← ET page 1

size, etc.) for any given tooth should be made with the following considerations, among others:

- Final apical taper size, which can be created to the apex.
- Flexibility.
- Cutting ability.
- Resistance to fracture.
- Centering ability, lack of transportation.
- Final master apical diameter, which can be created.
- Ease of sequencing.
- Tactile control (lack of screwing in being one measure of tactile control).

With regard to the final criterion, I have selected the Twisted File (TF) (SybronEndo, Orange, Calif.) as my RNT file. It possesses the ability to:

- Instrument approximately one third of the canals encountered with a single file.
- Instrument approximately one third of the canals encountered with

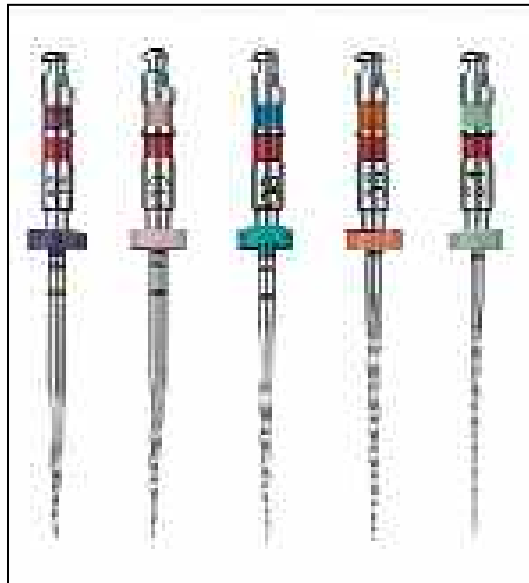

Fig. 2: The Twisted File (SybronEndo, Orange, Calif.)

two single TFs.

- Instrument the remaining cases, other than those above, generally with three TFs.

• Create greater tapers than ever before to the apex. Clinically, the mesial root of a lower molar can easily be enlarged to a 0.08 taper from the orifice to the apex. Even the most severe 90-degree curvature can be treated to a minimum 0.06 taper, and likely a 0.08 taper, if done correctly.

- Perform the above functions without clinically relevant trans-



Fig. 3: The RealSeal One Bonded Obturator (SybronEndo, Orange, Calif.)

portation and with excellent tactile control and minimal insertions per canal, usually three to four.

The TF is simple to use and master. There are five files — 0.12, 0.10, 0.08, 0.06 and 0.04, with a fixed #25 tip size (at this time, larger sizes are planned for introduction). The TF is used after the achievement of patency in the given portion of the canal being enlarged and after a glide path is created. A glide path means that the canal has been enlarged to a minimum #15 hand K-file. The TF is used crown down from larger TFs to smaller. The TF is inserted to resistance in a single continuously controlled insertion that usually takes two to three seconds. The TF is never pumped up and down in the canal. Irrigation and recapitulation should be carried out after every TF insertion. The TF is rotated at 500 to 900 rpm, with higher speeds used for retreatment, 1,200 rpm or higher. The TF can remove the plastic carriers of warm carrier-based obturation techniques easily and rapidly. If the clinician wishes to create larger apical diameters than a #25, he or she may do so any way desired with additional files. It should be remembered that the final prepared taper with a TF is usually 0.08 or higher, and this mitigates to some extent the #25 tip size if larger apical diameters are not created.

In my empirical opinion, canal preparation should be taken to the minor constriction (MC) of the apical foramen. The position of the MC can be determined and verified precisely by the following means:

- Electronic apex locator.
- Bleeding point determination.
- Confirmation with a tactile pop of a hand file as it passes out of the MC.

Irrespective of whether the canal is prepared to larger apical diameters or not, the correct size of the

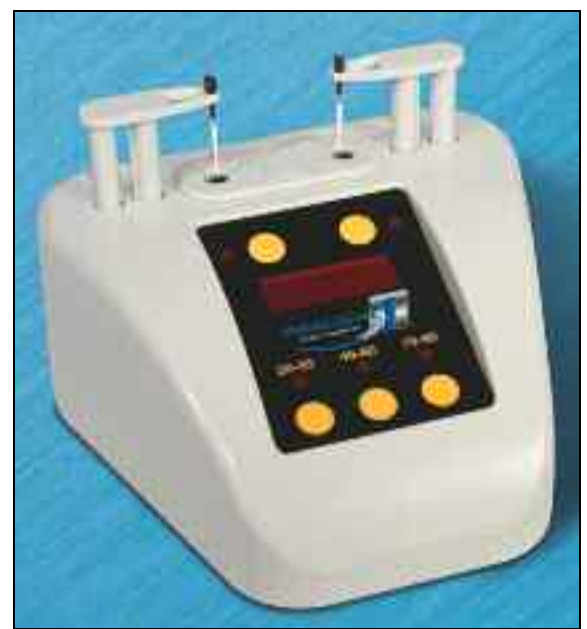

Fig. 4: The RealSeal One Bonded Obturator Oven (SybronEndo, Orange, Calif.)

RealSeal One Bonded Obturator (RS1) that will be used to obturate the canal can be selected with an RS1 size verifier before obturation. The RS1 technique allows the clinician to obturate canals efficiently and predictably with a warm obturation technique using a carrier that is dissolvable in chloroform as well as easily removed with the TF. More importantly, the RS1 can create a bonded obturation from orifice to apex as described below.

RS1 obturators:

- Are available in 0.04 taper and tip sizes of 20-90.
- Are used with a chemically compatible sealer. There are methacrylates in the RealSeal core material as well as the sealer. There is a chemical coupling of the methacrylates between the core filling material (i.e., the RealSeal) and the self-etching RealSeal sealer. Obturation with either RealSeal master cones or RS1 obturators allows impregnation of the tubules with sealer. The hybrid layer that is created in this process reduces coronal leakage relative to gutta-percha in a statistically significant manner giving it clinical significance.

AD



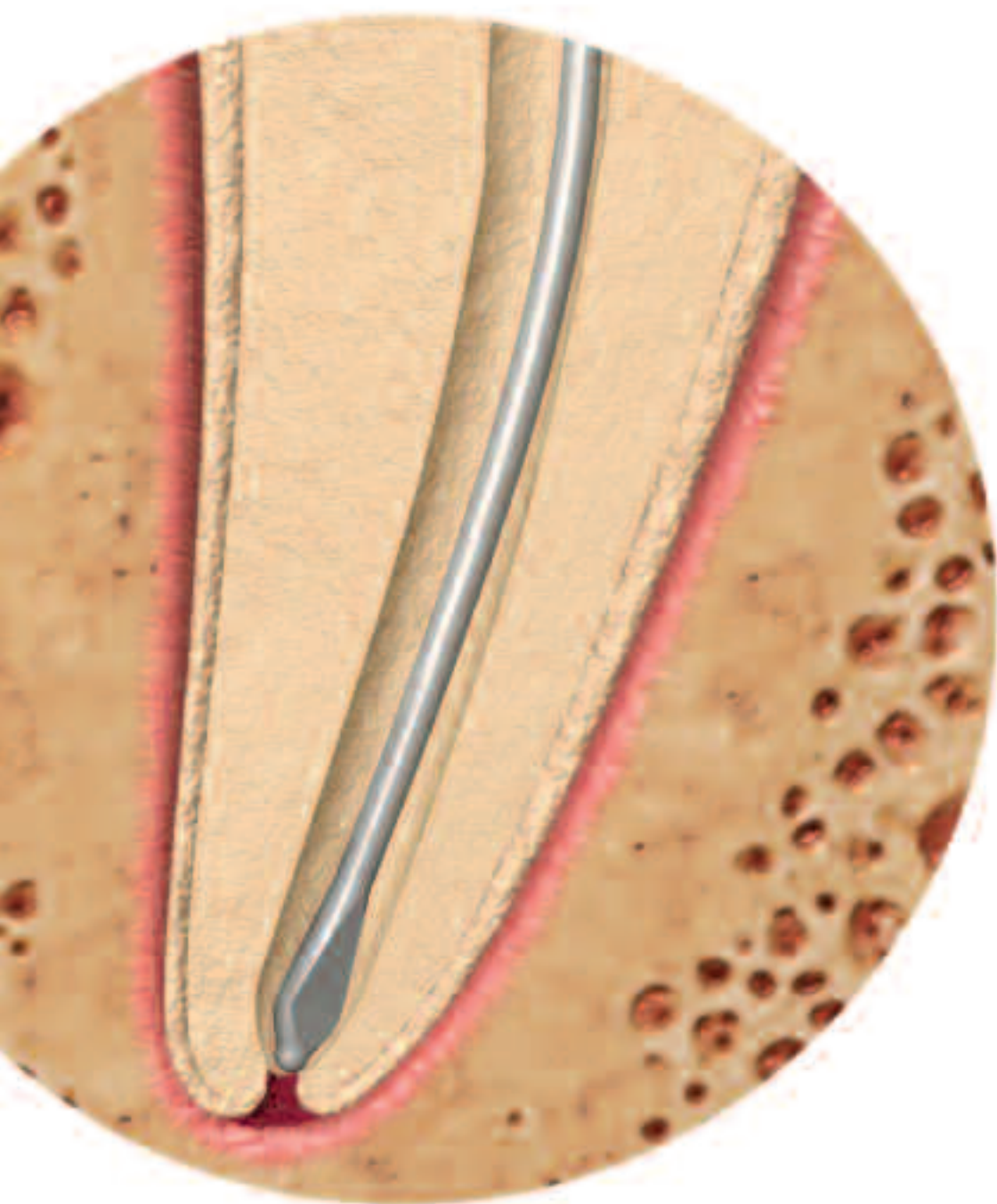
Sign me up for Endo Tribune!

<input type="checkbox"/> I'm a GP <input type="checkbox"/> I'm a specialist	<input type="checkbox"/> please send Dental Tribune every other week (free!) <input type="checkbox"/> please send Dental Tribune every week for \$99/year and one free speciality: <input type="checkbox"/> Endo Tribune <input type="checkbox"/> Implant Tribune <input type="checkbox"/> Ortho Tribune <input type="checkbox"/> please send the monthly newspaper for my speciality (free!) <input type="checkbox"/> please send a monthly newspaper for a different speciality @ \$59/year <input type="checkbox"/> Endo Tribune <input type="checkbox"/> Implant Tribune <input type="checkbox"/> Ortho Tribune
Name _____	Phone _____
Address _____	E-mail _____
City, State & Zip _____	Signature _____
Date _____	
Payment via: <input type="checkbox"/> Check <input type="checkbox"/> Mastercard <input type="checkbox"/> Visa <input type="checkbox"/> AMEX	Please remit payment to: Dental Tribune America LLC 713 W. 35th Street, Ste. 801 New York, NY Tel. (212) 244-7181 Fax (212) 244-7185
For more information, please contact us at <a href="mailto:database@dtamc.com">database@dtamc.com</a>	
For a free online subscription to the newspaper of your choice, please provide a valid e-mail address. Subscribers will occasionally receive e-mail newsletters filled with info about events, products, technology and general news.	

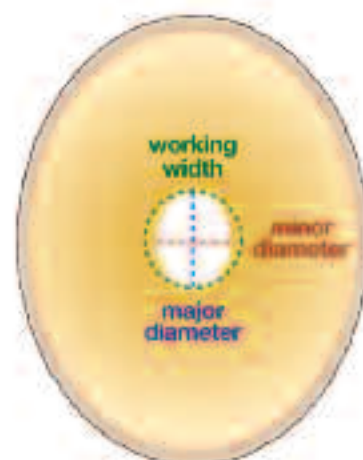
→ ET page 6

# 360° clean. 100% confidence.

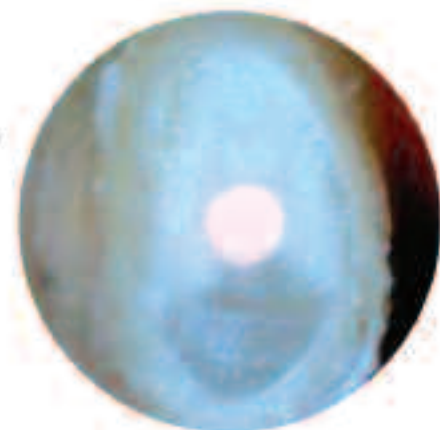
Biologically Optimal Preparations™  
that are safe, conservative and predictable.



Canals are oval,  
not round.  
LightSpeedLSX™  
addresses  
working length  
and  
working width...  
mastering the  
apical third.



The result:  
A Biologically  
Optimal Preparation.™  
Note the perfectly  
round shape,  
complete absence  
of necrotic debris,  
and abundance  
of healthy dentin  
surrounding it.



cross-section 1mm from the apex

Call for your  
demonstration today:

**800-817-3636**

[www.discusdental.com/endo](http://www.discusdental.com/endo)

**LightSpeedLSX™**

## EndoPAL™



Powerful and  
long-lasting.  
The cordless  
EndoPAL™  
handpiece delivers  
optimal speed and  
torque for LSX  
instrumentation.

## EndoVac™



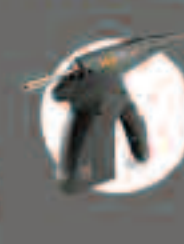True apical  
negative  
pressure.  
EndoVac™ is the  
only endodontic  
root canal  
irrigation system  
that can safely  
and abundantly  
deliver irrigant to  
the apical 1mm.

## SimpliFill™



The ideal  
apical seal.  
Each 5mm  
SimpliFill™ Apical  
Plug perfectly fits  
its corresponding  
LSX preparation  
size. Optimized  
by design and  
available in  
Gutta Percha &  
Resilon®.

## HotShot™



Cordless. Clean.  
Thermoprotected.  
Maximize your  
degrees of freedom  
with the HotShot™  
gun – the ultimate  
in backfill obturation.

**Smart  
ENDODONTICS™**

DISCUS DENTAL

← **ET** page 4

#### RS1 Clinical Application:

1) After TF preparation, a plastic size verifier is used to determine the correct RS1 size.

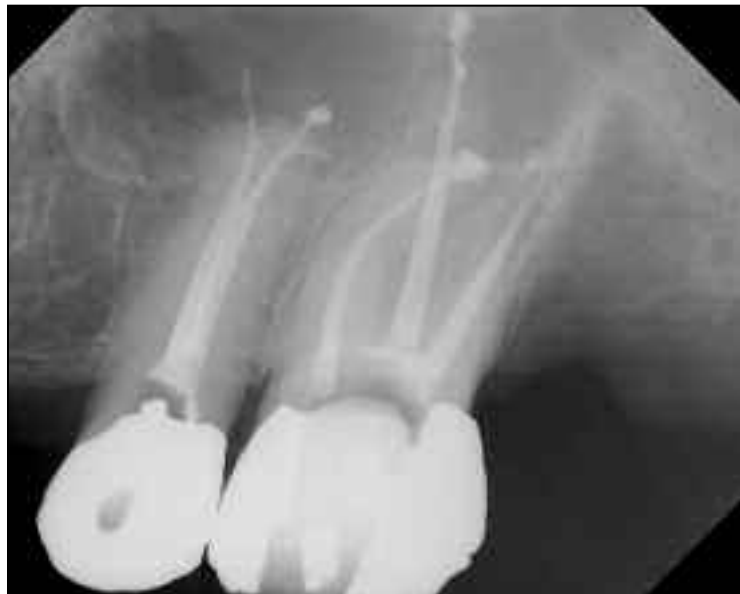2) RealSeal self-etching sealer is then applied.

3) The RS1 is heated in a RS1 oven and placed to length within six seconds to the true working length.

4) After placement, the RS1 can be cut off at the orifice with a heat source, such as the Elements Obturation Unit (SybronEndo, Orange, Calif.)

5) The RealSeal system is a dual cure system. The sealer will self-cure in approximately 40 minutes or the obturation can be cured in the coronal third with a light. Post space can be made using a post drill after first curing the obturation with a light and again curing the preparation after post space preparation.

A common question is asked with regard to matching the RS1, which is 0.04 taper, and the TF canal preparation, which is 0.08 or 0.10. Much as a smaller cup fits into a



**Figs. 5, 6: Clinical cases treated with the Twisted File and RealSeal One Bonded Obturators.**

larger cup and both are tapered, a smaller taper (smaller cup) fits into a larger taper (larger cup). Any discrepancy of taper size between the RS1 and the taper of the prepared canal is filled with the RealSeal material around the obturator core. It is noteworthy that the

RealSeal material physically adheres to the obturator core and that gutta-percha does not adhere to any significant degree to the plastic core of other warm carrier-based devices. This adherence of RealSeal to the core can only improve the hydraulics of the movement of the RealSeal into the narrowing cross-sectional diameters of the prepared canal.

The clinical case (#18) shown in Figure 1b was obturated with RS1 in canals that had been prepared with a TF. The final taper of both roots was 0.08. Due to the enhanced taper of the preparation relative to that which might have been created with ground files, it is a consistent finding that the 0.08 and 0.10 TF preparations consistently require a #55 obturator.

Past objections to warm carrier-based products were related to a lack of bonding, difficulty in retreatment and cost. Aside from cost, these objections have been overcome. Aside from bonding, which could not be accomplished with past warm carrier-based devices, RS1 obturators are dissolvable in chloroform and also can be removed very easily with the TF at higher rotational speeds, such as 1,200 rpm and above (Figs. 2-6).

#### About the author



**Richard E. Mounce, DDS**

Dr. Richard E. Mounce lectures globally and is widely published. He is in private practice in endodontics in Vancouver, Wash. He offers intensive customized endodontic single-day training programs in his office for groups of doctors.

For more information, contact Dennis at (360) 891-9111 or [RichardMounce@MounceEndo.com](mailto:RichardMounce@MounceEndo.com).

## Increase Your Endodontic Efficiency

Presented by **Richard Mounce, DDS**  
at the **Greater New York Dental Meeting**  
**Live Dentistry Theater**

**Tuesday, Dec. 2 and Wednesday, Dec. 3, 2008, 2-5 p.m.**


This multi-media LIVE patient demonstration is designed for general practitioners to improve their daily endodontic skills. Topics include: diagnosis, case selection, the latest endodontic instrumentation, and the cleansing, shaping and packing of the root canal system in three dimensions with warm bonded obturation techniques. The program also includes an introduction to the surgical operating microscope as well as discusses the importance of coronal seal and the role of endodontics in treatment planning.

Attendees will learn the following:

- The biologic objectives of root canal therapy.
- The importance and methods of effective biomechanical cleansing of the root canal system.
- Endodontic diagnostic decision making, case selection and organization of armamentarium
- Optimal obturation of root canal systems with warm filling techniques

*All equipment and supplies are provided courtesy of SybronEndo and the Greater New York Dental Meeting.*

AD



**Come Aboard and Experience In-Depth Endodontic Education**

Boston Convention & Exhibition Center


January 28 - February 1, 2009 • Exhibits January 29 - 31, 2009

**Chart a New Course for Learning and Discovery in Dentistry**

- Earn CEUs from Top Clinicians
- Learn new paradigms in endodontic dentistry
- Master state-of-the-art techniques

- Engage with 29,000+ Dental Professionals
- Explore 500+ Educational Exhibits

**Endodontic Specialty Symposium • Saturday, January 31, 2009**



**Mahmoud Torabianjazi, DMD**

**ROOT CANAL OR IMPLANT? CLINICAL APPLICATIONS OF MTA**

- Review the effects of new advances in dental implants in dentistry
- Discuss factors affecting outcomes of root canal treatment and single-tooth implants
- Identify the causes of success and failure of non surgical and surgical root canal treatments
- Compare and contrast the characteristics of currently used repair materials with those of MTA for pulp capping

Thanks to Dentistry Today Dental Specialists for its support.

Designed by  
Spears & Associates

**Register Now!**

[www.yankeedental.com](http://www.yankeedental.com)

800-342-8747 (MA)

800-943-9200 (Outside MA)

# Emergency dental implant procedures

By Drs. Nicholas Caplanis and Jaime Lozada

Patients often present to the office with unscheduled emergency conditions that require immediate tooth removal.

These situations have become increasingly complex to deal with given the myriad available treatment options, which impact the treatment approach and methodology of both tooth extraction as well as provisionalization.<sup>1</sup>

Unrestorable crown and root fractures are often ideal clinical scenarios for immediate implant placement given the frequent lack of overt infection and alveolar bone damage, which is often associated with other emergency conditions such as endodontic and periodontal abscesses. Failure to perform immediate implant placement or site preservation during the emergency visit often leads to a loss of alveolar bone, which greatly impacts dental implant treatment success. When comparing the excellent long-term success rates of implants with the guarded long-term prognosis of a badly fractured tooth requiring endodontic treatment, crown lengthening surgery, and a post and core buildup, extraction and site preservation or immediate implant placement is frequently the ideal treatment approach.

A clinical study of 534 fractured teeth reported a 20 percent failure rate when conventional therapy was performed, specifically, endodontic treatment, post and core buildup and a tooth-supported crown.<sup>2</sup> Immediate implant placement following an emergency extraction should therefore be an integral part of emergency treatment.

Strategies to manage the extraction defect have been previously published providing algorithms to help guide implant treatment procedures, including immediate implant placement following tooth extraction.<sup>3</sup> Guidelines for predictable immediate provisionalization of immediate implant have also been previously established.<sup>4</sup>

A one-year prospective study reported a 100 percent implant success rate and also suggested improved esthetic outcomes are achieved following this approach when compared to extraction alone without implant placement.<sup>5</sup> The ability to quickly and effectively treat these emergency scenarios improves patient satisfaction, facilitates patient management and is a tremendous clinical service.

Therefore, the dental office and team should be well-equipped, or referral guidelines be effectively established, to allow for efficient and predictable dental implant placement during these types of emergency appointments. The following two clinical

case reports describe a simple and effective process to treat hopelessly fractured teeth using dental implants and either a bonded restoration as a provisional or a provisional placed immediately on the implant.

## Patient 1

A 65-year-old Asian female presents for a new patient emergency exam, with an oblique crown and root fracture affecting her maxillary right central incisor. The fracture occurred spontaneously while eating, involved the entire facial surface of the tooth and extended

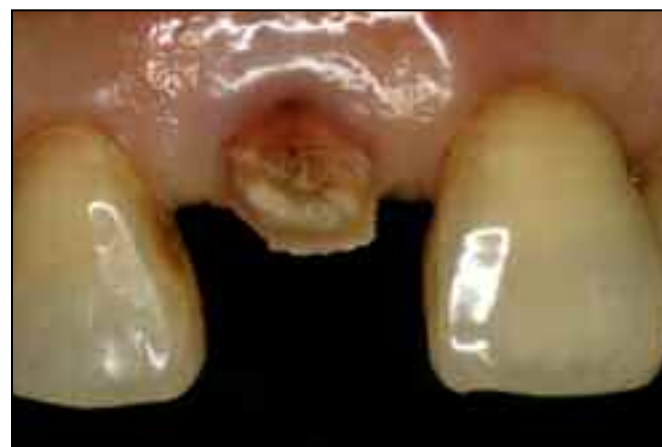

Fig. 1a: Emergency presentation of unrestorable crown and root fracture of tooth #8.

to the alveolar crest (Figs. 1a, 1b). The clinical crown exhibited severe mobility and was painful upon palpation and percussion.

AD

**TUFF**  
ULTRASONIC DIAMOND INSTRUMENTS

Now Break Resistant  
**Ultrasonic Instruments**

◆ **DOUBLE DIAMOND** ◆

*TUFF™ Ultrasonic Instruments have been designed for multiple clinical applications. Our double diamond coating provides superb cutting efficiency and is resistant to Sodium Hypochlorite (NaOCl).*

*"Extremely helpful in locating the elusive MB2 canal. The durable and efficient TUFFs are the best tips to hit the market in my 20 years as an endodontist."*

*Michael Spitzler, D.D.S., M.S.*

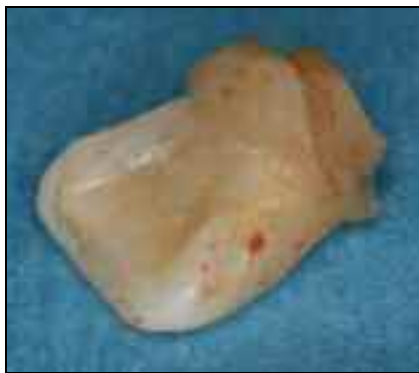**SAN DIEGO SWISS MACHINING INCORPORATED**

Call Direct Toll Free: (866) 737-8477  
Manufactured in the U.S.A. by San Diego Swiss Machining, Inc.  
TUFF™ is a trademark of San Diego Swiss Machining, Inc.  
Palmdale, California

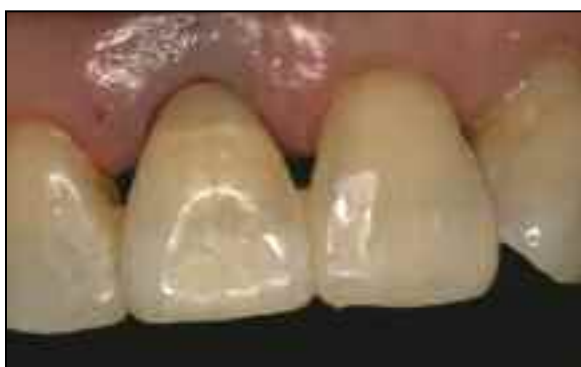TO ORDER ON LINE: [www.scdswiss.com](http://www.scdswiss.com)



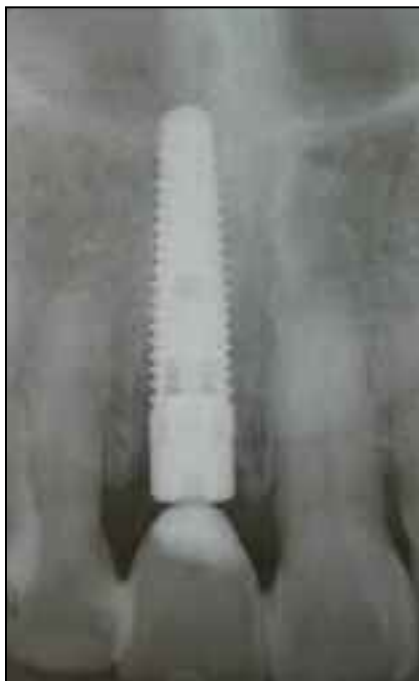**Fig. 1b:** Radiograph of oblique crown and root fracture tooth #8.



**Fig. 1c:** Intact clinical crown to be used as bonded provisional.



**Fig. 1d:** Fractured crown bonded to adjacent dentition serving as primary provisional.



**Fig. 1e:** Radiograph of immediate implant in place with bonded provisional.

The prognosis was poor and extraction was advised.

Treatment options to replace the tooth were discussed and included a fixed partial denture as well as an implant supported crown. Given the excellent condition of the adjacent teeth as well as the patient's prior history of having successful dental implant-supported restorations, she elected to have an implant placed.

The crown portion of the tooth was easily removed and, given its excellent condition, was retained to be used as a bonded provisional (Fig. 1c). The tooth root was extracted atraumatically without flap elevation and the socket debrided, irrigated and evaluated with a periodontal probe. The extraction defect had minor horizontal bone loss associated with a reduced periodontium secondary to a prior history of periodontitis, but the adjacent socket walls including the buccal crest were otherwise intact. Therefore the defect appeared amenable for immediate implant placement. A 4.5 x 16 mm Replace® Select implant (Nobel Biocare™) was placed and utilized the entire length of the alveolus and engaged the nasal floor, in order to achieve effective primary stability (Fig. 1e). After implant placement, the residual socket defect was grafted with a composite anorganic bovine bone matrix (Bio-Oss® Osteohealth®) and a demineralized cortical bone allograft (OraGraft® LifeNet®). Composite was bonded to

the fractured surface of the clinical crown in order to develop an ovate surface to maintain soft tissue esthetics. The modified clinical crown was then bonded to the adjacent teeth and served as a primary provisional restoration (Fig. 1d). The patient was then referred back to her restorative dentist the next day to fabricate an immediate provisional supported by the implant. The emergency

appointment including the extraction, placement of the implant, grafting of the residual socket defect and bonding of the primary provisional restoration took approximately one hour of clinical time.

#### Patient 2

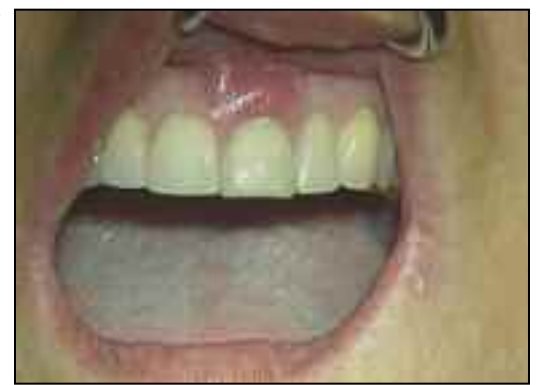A 35-year-old female presented at the emergency clinic of Loma

Linda University School of Dentistry and was immediately referred to the Center for Implant Dentistry. She complained of trauma to her maxillary anterior dentition after an alleged assault, a "blow to the face," two days previously. Upon examination, the maxillary left central incisor was partially fractured at mid root and exhibited grade III mobility (Fig. 2a). The left lateral incisor was tender to percussion and exhibited grade 1 mobility, but it recorded a negative response with ethyl chloride and electronic pulp testing.

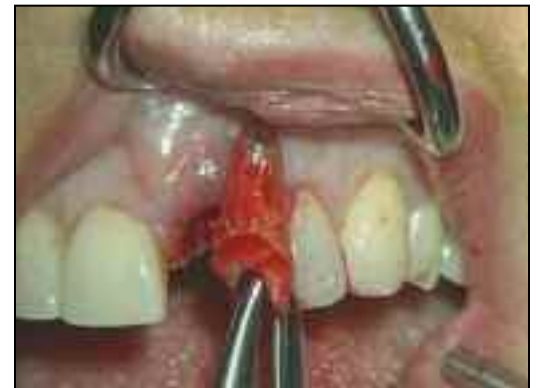The patient was then scheduled to undergo an emergency procedure at the clinic consisting of atraumatic extraction of the affected tooth and immediate implant placement with immediate provisionalization. The fractured tooth was extracted and the remaining root fracture was removed utilizing a periosteal instrument (Fig. 2b). The alveolus was curetted and no bone fenestration was noted. A Nobel Active dental implant was used to replace the extracted tooth (Fig. 2c). The osteotomy was performed palatal to the alveolus in order to obtain maximum stabilization for the implant.

The implant was seated at 35 nc stability, which made the clinical situation viable for immediate provisionalization. A prefabricated abutment was placed and hand torqued to provide the support for the acrylic resin restoration. The provisional crown was then relieved from all occlusal contacts (Fig. 2d). Intraoperative radiographs revealed adequate position of the implant in relation to the adjacent dentition and bone implant level.

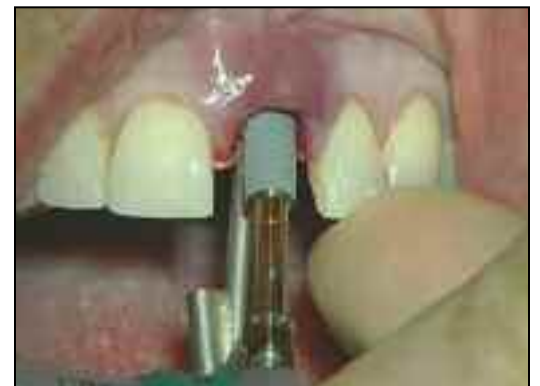The emergency dental implant procedure should be considered a viable and often preferable treatment approach to treat emergency situations that ultimately lead to tooth loss such as root fractures. When appropriate, immediate pro-



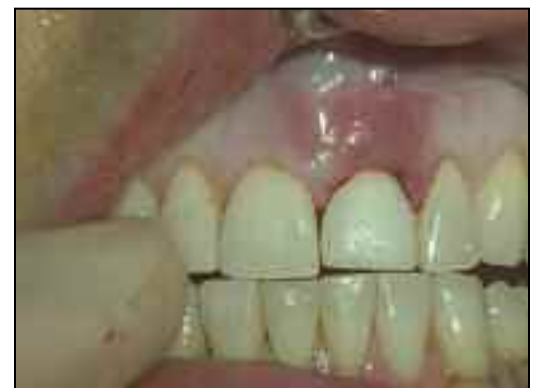**Fig. 2a:** Trauma to the maxillary left central incisor with horizontal root fracture.



**Fig. 2b:** Periotome and forceps extraction of fractured root.



**Fig. 2c:** Immediate implant is placed achieving excellent primary stability.



**Fig. 2d:** An immediate acrylic restoration is used as a provisional.

visionalization or bonding of the fractured crown can be used as a provisional restoration.

## References

1. Iasella JM et al. Ridge preservation with freeze-dried bone allograft and a collagen membrane compared to extraction alone for implant site development: A clinical and histologic study in humans. *J. Periodontol* 2003 74(7): 990-9.
2. Cvek M, Tsilingaridis G, Andreasen JO. Survival of 534 incisors after intra-alveolar root fracture in patients aged 7-17 years. *Dent Traumatol*. 2008 Aug; 24(4):379-87.
3. Caplanis N, Kan J, Lozada JL. Extraction defect assessment, classification and management. *Journal of the California Dental Association*. 2005; 33(11): 853-863.
4. Wöhrle PS. Single-tooth replacement in the aesthetic zone with immediate provisionalization: fourteen consecutive case reports. *Pract Periodont Aesthet Dent*. 1998 Nov-Dec.; 10(9):1107-14.
5. Kan JY, Rungcharassaeng K, Lozada J. Immediate placement and provisionalization of maxillary anterior single implants: 1-year prospective study. *Int J Oral Maxillofac Implants*. 2003 Jan-Feb; 18(1):31-9.



About the authors



**Dr. Nick Caplanis**

Dr. Nick Caplanis is an assistant professor and part-time faculty member within the graduate program in implant dentistry at Loma Linda University School of Dentistry. Caplanis has a unique background with formal residency training in the inter-related fields of implant surgery, prosthodontics and periodontics. He is board certified and a diplomate of both the American Board of Periodontology and the American Board of Oral Implantology and is a fellow of the American Academy of Implant Dentistry. He was also the general meeting chairman for the 57th annual meeting of the AAID, which was held in San Diego from Oct. 29–Nov. 1. Caplanis maintains a full-time private practice limited to periodontics and dental implant surgery, in Mission Viejo, Calif.



**Dr. Jaime Lozada**

Dr. Jaime Lozada is the director of the graduate program in implant dentistry and a professor at Loma Linda University School of Dentistry. Lozada has been involved with implant dentistry for more than 20 years. He completed his residency in implant dentistry in 1987 and his graduate prosthodontics certificate in 1997. Lozada has trained hundreds of residents and fellows in the latest techniques in oral implant surgery and prosthodontics. Lozada is a fellow and past president of the American Academy of Implant Dentistry and a diplomate of the American Board of Implant Dentistry. He is well-published and lectures nationally and internationally on implant dentistry and maintains a faculty practice limited to implant dentistry and prosthodontics at the Loma Linda University School of Dentistry.

## Tissue care in the maxillary anterior: Ankylos — a new paradigm

Catch Dr. DiGiallorenzo's lecture at the Dental Tribune Symposia at the Greater N.Y. Dental Meeting at 1:30–2:30 p.m. on Dec. 1.

This lecture will provide a systemic, biologic and evidence-based approach to ensure success in the class 1 to class 4 case utilizing the "Tissue Care Concept by Ankylos," PRGF, lasers and piezo surgery. Learn about:

- Diagnosis of patient biotypes and its affect on treatment decisions.
- Immediate or staged?
- Surgical management: incisions, atraumatic extraction, periodontal plastics, bone grafting (PRGF), overcorrection, site preparation, and 3-D implant placement.
- Prosthetic management: abutment selection, provisionalization, restorative materials and methods.

Earn C.E. credits! Attendance is free for all GNYDM visitors!

For more information and registration, please contact Julia Wehkamp at [j.wehkamp@dtamerica.com](mailto:j.wehkamp@dtamerica.com).



DENSPLY  
TULSA DENTAL  
SPECIALTIES

AD

GOLDEN MISCH  
**physics**  
forceps  
simple • predictable • more efficient

TOP 100  
PROFESSORS 2007

TOP 100  
PROFESSORS 2008

Take advantage of our  
**90 day trial period**

Visit us at the  
Greater New York Dental  
Meeting Booth # 3431 for a  
Free DVD and convention  
special offers.

\*ORDERS NOW BEING ACCEPTED FOR  
OUR NEW 3RD MOLAR INSTRUMENTS

learn more about the physics forceps at  
**GOLDENMISCH.COM**  
1 877 987 2284

ADVANCEMENTS IN DENTISTRY

### Supporting Comments for the New Extraction Forceps



**Anthony S. Fock, DMD**

I have never looked forward to doing extractions in my practice. It can take just a few minutes or more than half an hour if I hear that dreaded 'cracking' sound indicating I have broken a crown or a root. Since using the Physics Forceps that sound is a thing of the past. These new forceps don't rely on brute force, but rather, use the simple concept of leverage. Instead of grasping, pushing, twisting and pulling the clinical crown, this technique employs a slow, steady rotational force that literally rolls the tooth free from the PDL. Seldom do new innovations come along that truly revolutionize the way a dentist approaches a service — this is one!



**Louis Malcmacher, DDS, MAGD**

Faster, easier and better — these are the three magic attributes that I look for whenever I evaluate new products. The GoldenMisch Physics Forceps are by far one of the greatest advancements I have seen in extraction in my 28 year career. Using these unique instruments greatly reduces buccal bone loss during the extraction, making implant support and esthetic success much more predictable. The amount of time, effort and frustration saved is incredible, especially with challenging teeth. The Physics Forceps are an absolute must for every dental practice and I highly recommend them in my lectures.