

OCTOBER 2009

www.implant-tribune.com

VOL. 4, No. 10



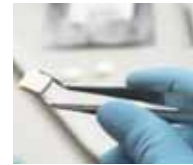**AAP names new officers**  
Dr. Low and others will be leading perio group this year

▶Page 2



**Orientation is key**  
What you need to do to ensure a good transition for new hire

▶Page 11



**New technology**  
Zimmer introduces product for oral wound care

▶Page 22

## With implants, needs of aging population trump recession

Tooth loss among the elderly population will create some growth in the \$3 billion global dental implant market despite the recession, according to "Implant-Based Dental Reconstruction: World Dental Implant and Bone Graft Market, 3rd Edition" by life sciences market research publisher Kalorama Information, though not the impressive double digit growth rates of prior years.

"The numbers so far suggest that basic restorative work, preventive, day-to-day procedures will continue unabated by the economic downturn, though teeth-whitening and purely cosmetic dentistry will suffer," said Bruce Carlson, analyst for Kalorama Information. "These are big purchases and in a recession, tenta-

→ page 2

## New opportunities in implant dentistry at AAID annual meeting

More than 1,600 dentists, allied staff and exhibitors are expected to attend the American Academy of Implant Dentistry's (AAID) annual scientific conference from Nov. 11-15 in New Orleans. The event is highly regarded in the dental profession as an innovative and valuable opportunity for continuing education, product demonstrations and networking.

The theme for the AAID meeting, to be held at the Hilton New Orleans Riverside hotel, is "New Opportunities in Implant Dentistry," and the comprehensive scientific program will showcase an international cast of speakers and offer as many as 24 hours of comprehensive dental implant continuing education. The schedule of presentations along with abstracts and registration is avail-

→ page 14



New Orleans is the site of the 2009 annual meeting for AAID.

PRSTRT STD  
U.S. Postage  
PAID  
Permit # 506  
Mechanicsburg, PA

Dental Tribune America  
215 West 55th Street  
Suite #801  
New York, NY 10001

## Latch-head hex tool guided implant uncovering using the punch technique

By William E. Mason DDS, MS, PC

Dental implants are considered a highly predictable and accepted technique for the replacement of lost teeth.<sup>1-5</sup>

Brånemark and coworkers proposed the original osseointegrated implant technique.<sup>4-6</sup> This involved a healing period of three to six months before the implants were surgically exposed and restored.<sup>4-8</sup>

It has been demonstrated since that a "one-stage" approach with or without immediate loading is a predictable technique.<sup>9-15</sup> However, in cases where extensive guided bone regeneration is necessary or there is inadequate initial implant stability, a "two-stage" approach is recommended.<sup>9</sup>

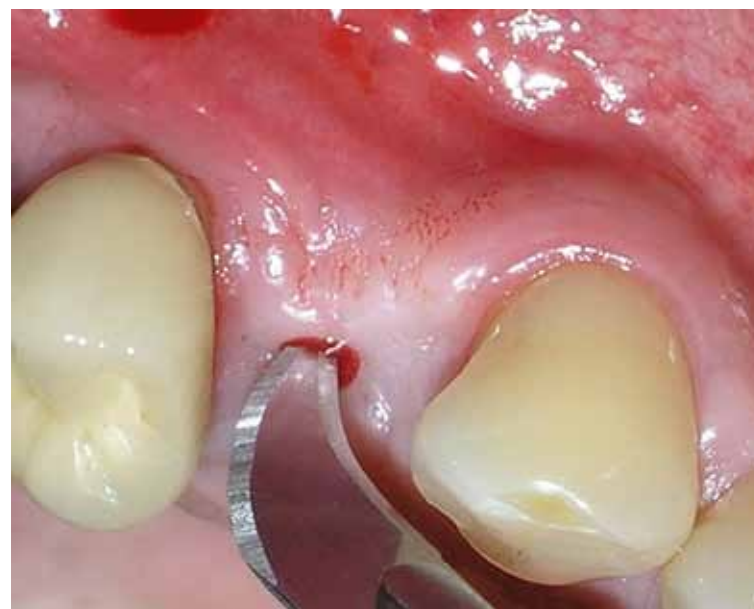

Fig. 1: #12 scalpel is used to locate the hex depression in the center of the cover screw.

→ page 4

# Dr. Samuel Low elected president of the AAP

Samuel Low, DDS, MS, of Gainesville, Fla., was installed as president of the American Academy of Periodontology Board of Trustees during its 95th Annual Meeting, held Sept. 12–15 in Boston.

Low is associate dean and professor of periodontology at the University of Florida College of Dentistry in Gainesville, Fla. He is also an advisory faculty member to the Pankey Institute for Advanced Dental Education, a dental school that focuses on hands-on educational experiences and a highly developed dental curriculum.

An AAP member since 1975, Low served on the Board of Trustees as the academy's president elect in 2009. Previously he served as vice president in 2008, and secretary/treasurer in 2007. Low follows outgoing President David Cochran, who will assume the role of immediate past president and will support the academy in the coming year as a member of the Board of Trustees.

"Dr. Low's diverse background will be very valuable during his tenure as president. His experience within the AAP, as well as with the American Dental Association and in academia will help Dr. Low successfully lead the academy throughout the next year and into the future," said Cochran, 2009 AAP president.

"I am honored to start my year as president of the American Academy of Periodontology," Low said. "I am anticipating a very busy and successful year for the academy, which will include advancing the science of periodontology, conducting both public and professional outreach on



Dr. Samuel Low

the importance of periodontal health, and strong leadership to further the specialty."

As well as serving on the AAP's Planning Committee, Education Committee and participating in multiple World Workshops in Periodontics sponsored by the AAP, Low has been involved in all levels of organized dentistry. In addition to being a trustee at the American Dental Association, Low is a consultant to the Council on Dental Practice.

Low received his dental degree, specialty training in periodontics and master's of science in biomedical science from University of Texas Dental Branch at Houston, and his master's of education from University of Florida College of Education.

In addition to Low, Pamela McClain, DDS, of Aurora, Colo., was installed as vice president and Nancy Newhouse, DDS, of Lee's Summit, Mo., was installed as secretary/treasurer.

A former dental hygienist, McClain

maintains a full-time private practice limited to periodontics in Aurora, Colo., and is a part-time clinical assistant professor at the University of Colorado School of Dentistry.

An AAP member since 1985, McClain previously acted as the Board of Trustees secretary/treasurer during 2009 and has also served on a variety of academy committees, including chairing the Continuing Education Oversight Committee, Strategic Planning Committee and the Annual Meeting Committee. McClain has been a diplomate of the American Board of Periodontology since 1992.

"Dr. McClain has had an outstanding year on the Executive Committee, and in this new position as vice president I am sure that she will continue to help guide both the AAP and periodontal profession toward the future," Low said.

In addition to running a private practice in Independence, Mo., Newhouse is also an assistant professor at the University of Missouri — Kansas City School of Dentistry. She has been a diplomate of the American Board of Periodontology since 1989.

A member of the AAP since 1985, Newhouse has previously been active in many committees including the Executive Committee, American Dental Association Liaison Committee, Task Force on Membership Value, Finance Committee, Planning Committee and Awards Committee. She has also served on the Board of Trustees since 2002. ■

(Source: American Academy of Periodontology)

## ← IT page 1

tive spending is contagious. That will taper the kind of fast growth we've seen here."

Simple demographics will force some growth in the market — the U.S. elderly population that is projected to be twice as large in 2050 as it was in 2000 — and tooth loss rates are high among this population, but there will still be customers who will have to

put off implants. Economic problems are often compounded because many older Americans do not have dental insurance. Financing dental care for those elderly on a fixed income is particularly difficult compared with other age groups, and less than a quarter of older persons are covered by private dental insurance.

The recession is expected to pose a challenge for future sales of dental implants because the dental implant industry relies heavily on the ability

of patients to pay for treatments out of their disposable income. Equally impacted is the bone graft market, which has a growth trajectory proportional to the implant market.

This study provides a detailed view of these changes and the state of the dental implant market today. For more information, visit [www.kaloramainformation.com/redirect.asp?programid=71621&productid=2284095](http://www.kaloramainformation.com/redirect.asp?programid=71621&productid=2284095). ■

(Source: Kalorama Information)

## IMPLANT TRIBUNE

The World's Newspaper of Implantology · U.S. Edition

**Publisher & Chairman**  
Torsten Oemus  
[t.oemus@dental-tribune.com](mailto:t.oemus@dental-tribune.com)

**Vice President Global Sales**  
Peter Witteczek  
[p.witteczek@dental-tribune.com](mailto:p.witteczek@dental-tribune.com)

**Chief Operating Officer**  
Eric Seid  
[e.seid@dental-tribune.com](mailto:e.seid@dental-tribune.com)

**Group Editor & Designer**  
Robin Goodman  
[r.goodman@dental-tribune.com](mailto:r.goodman@dental-tribune.com)

**Editor in Chief**  
Sascha A. Jovanovic, DDS, MS  
[sascha@jovanoviconline.com](mailto:sascha@jovanoviconline.com)

**Managing Editor/Designer**  
**Implant & Endo Tribunes**  
Sierra Rendon  
[s.rendon@dental-tribune.com](mailto:s.rendon@dental-tribune.com)

**Managing Editor/Designer**  
**Ortho Tribune & Show Dailies**  
Kristine Colker  
[k.colker@dental-tribune.com](mailto:k.colker@dental-tribune.com)

**Online Editor**  
Fred Michmershuizen  
[f.michmershuizen@dental-tribune.com](mailto:f.michmershuizen@dental-tribune.com)

**Account Manager**  
Humberto Estrada  
[h.estrada@dental-tribune.com](mailto:h.estrada@dental-tribune.com)

**Marketing Manager**  
Anna Wlodarczyk  
[a.wlodarczyk@dental-tribune.com](mailto:a.wlodarczyk@dental-tribune.com)

**Marketing & Sales Assistant**  
Lorrie Young  
[l.young@dental-tribune.com](mailto:l.young@dental-tribune.com)

**C.E. Manager**  
Julia Wehkamp  
[j.wehkamp@dental-tribune.com](mailto:j.wehkamp@dental-tribune.com)

Dental Tribune America, LLC  
213 West 35th Street, Suite 801  
New York, NY 10001  
Phone: (212) 244-7181, Fax: (212) 244-7185



Published by  
Dental Tribune America

© 2009, Dental Tribune International GmbH. All rights reserved.

Dental Tribune makes every effort to report clinical information and manufacturer's product news accurately, but cannot assume responsibility for the validity of product claims, or for typographical errors. The publishers also do not assume responsibility for product names or claims, or statements made by advertisers. Opinions expressed by authors are their own and may not reflect those of Dental Tribune International.

## Editorial Advisory Board

**Dr. Sascha Jovanovic, Editor in Chief**

Dr. Bernard Touati

Dr. Jack T. Krauser

Dr. Andre Saadoun

Dr. Gary Henkel

Dr. Doug Deporter

Dr. Michael Norton

Dr. Ken Serota

Dr. Axel Zoellner

Dr. Glen Liddelow

Dr. Marius Steigmann

**Tell us what you think!**

Do you have general comments or criticism you would like to share? Is there a particular topic you would like to see more articles about? Let us know by e-mailing us at [feedback@dental-tribune.com](mailto:feedback@dental-tribune.com). If you would like to make any change to your subscription (name, address or to opt out) please send us an e-mail at [database@dental-tribune.com](mailto:database@dental-tribune.com) and be sure to include which publication you are referring to. Also, please note that subscription changes can take up to 6 weeks to process.

## IT Corrections

Implant Tribune strives to maintain the utmost accuracy in its news and clinical reports. If you find a factual error or content that requires clarification, please report the details to Managing Editor Sierra Rendon at [s.rendon@dental-tribune.com](mailto:s.rendon@dental-tribune.com).



# Osteocele®

*The Future Is Now.*

For more information or to place an order call **800.441.3100**

**www.acesurgical.com**

ACE Surgical Supply Company, Inc. • 1034 Pearl Street, Brockton, MA 02301

## A Bone Matrix Product Containing Stem Cells.

### The Properties of Autograft without Associated Risks

The proprietary processing technology that produces Osteocele® results in a viable bone matrix product that preserves the native stem cells found in marrow rich bone. It is the only product available today that has the desired beneficial properties of autograft - osteoconduction, osteoinduction and osteogenesis — and that allows surgeons to provide their patients with optimal bone growth conditions without the added risk and cost of a secondary procedure.

### Low Immunogenicity

Mesenchymal stem cells are IMMUNE-PRIVILEGED cells that do not stimulate a cellular immune response. Osteocele does not activate T cell proliferation, as shown *in vitro* from Mixed Lymphocyte Reaction (MLR) testing.

### Histologic Evidence

Positive clinical use of Osteocele since 2005 demonstrates bone-forming ability. Histology from a human sinus augmentation study using Osteocele shows substantial vital bone content at 16 weeks, with very low residual graft material.<sup>1</sup>

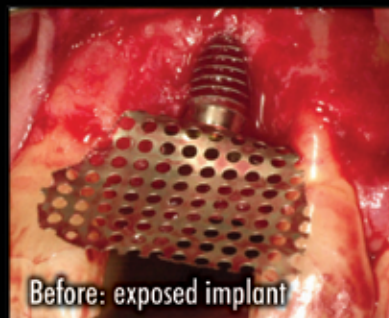### Bone Formation

Stem cells contained in Osteocele are capable of differentiating into bone cells. Every lot of Osteocele is tested for bone forming potential.

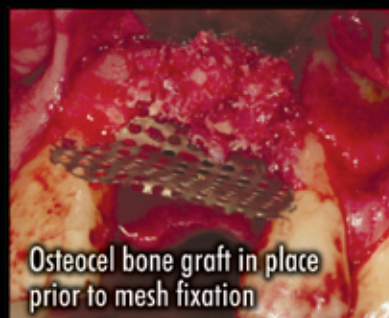### Viable Cell Content

The osteogenic potential arises from the stem cells in Osteocele. Following processing of marrow-rich bone, release testing demonstrates osteogenic potential according to the following criteria:

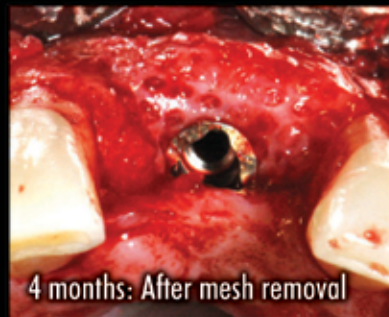- Rich supply of stem cells: Greater than 50,000 cells/cc
- Viability: Greater than 70% cell viability
- Positive osteogenesis: In vitro cell culture assay



Before: exposed implant



Osteocele bone graft in place prior to mesh fixation



4 months: After mesh removal

Ridge Augmentation clinical case.

<sup>1</sup> Histologic Evaluation of a Stem Cell Based Sinus Augmentation Procedure: A Case Series. — McAllister, Haghghat, Gonshor. — Journal of Perio., April 2009

## ADVANCED TISSUE GRAFTING 2-DAY HANDS-ON CADAVER WORKSHOP



For more details or to register go to [www.acesurgical.com/cadaver.html](http://www.acesurgical.com/cadaver.html)  
Limited availability. Last 2 courses sold out! Reserve your space by registering today.

**LAS VEGAS Dec 5-6, 2009**





Fig. 2: The driver handle (Zimmer Dental).

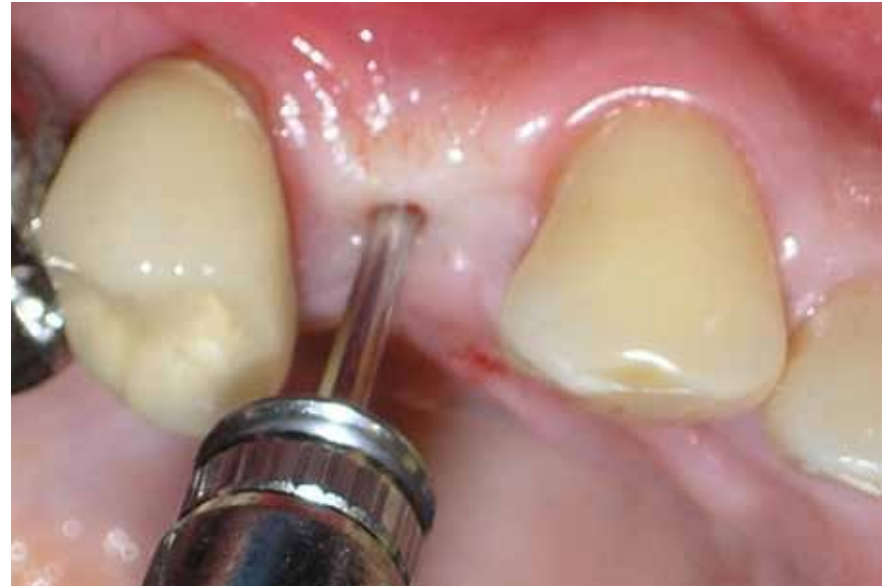

Fig. 3: The driver handle or a similar device is used to apply pressure to the hex driver to force it into the cover screw.

AD

Enter to win an **iPod Touch** in a daily drawing when you participate in a free demo

**PreXion**  
The World's Best Image Quality

**Quality Leader in 3D CBCT Imaging**

Visit us at AAID Booth #400

The PreXion 3D Dental CBCT Scanner has the highest resolution of any Cone Beam System. Additional benefits include:

- **New:** Upgraded panoramic view
- Generate more revenue
- Four different scanning modes
- User-friendly controls and software
- Powerful diagnostic 3D planning tools
- Proprietary XTrillion processor
- Ideal for implant planning
- Small foot print fits anywhere

Contact us today for an in-office demonstration at (650) 212-0300 | info@prexion.com | www.prexion.com

← **IT** page 1

In these situations, the implant is allowed to integrate while submerged. The “second stage” is a minor surgical procedure in which the head of the implant is surgically exposed and a temporary healing abutment or temporary restoration is placed to begin to establish the correct emergence profile. Definitive restorative treatment is then initiated after adequate soft-tissue healing.

The recommended technique for this second-stage surgery is an incision around the implant head to surgically remove the soft tissue.<sup>14</sup>

Sometimes, a full thickness muco-periosteal flap is raised to access the head of the implant. The attached gingiva covering and just lingual to the implant head can be mobilized and moved buccally to form an adequate band of attached gingiva around the buccal surface of the implant.

A punch technique has been suggested to leave a smooth even incision around the implant head and bordering the healing abutment. *The punch technique is only indicated when there is an adequate amount of attached gingiva over the head of the implant.*

If alveolar mucosa covers or is adjacent to the head of the implant, and the punch technique is used, alveolar mucosa will be adjacent to the final restoration. This will result in an inadequate gingival seal adjacent to the restoration, allowing plaque accumulation, inflammation and an unesthetic result.

The punch technique requires that the implant position be accurately located so that no bone is exposed by a punch that is off center.

Sometimes, the implant can be visualized through the soft tissue, but many times locating the exact position of the implant head is difficult. The surgical stent can be an aid in locating the head of the implant also. The mesio-distal position can be determined from periapical radiographs; however, bucco-lingual position is more difficult to determine.

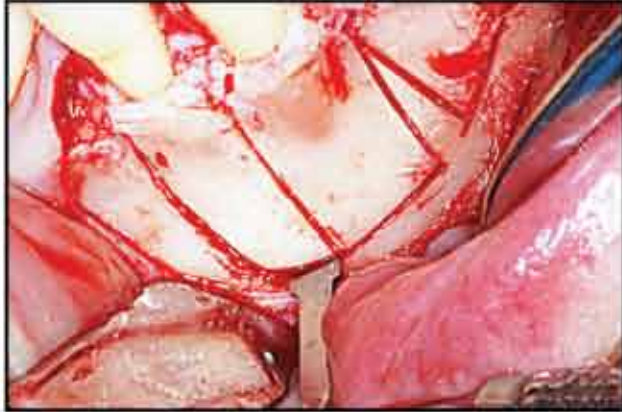→ **IT** page 6



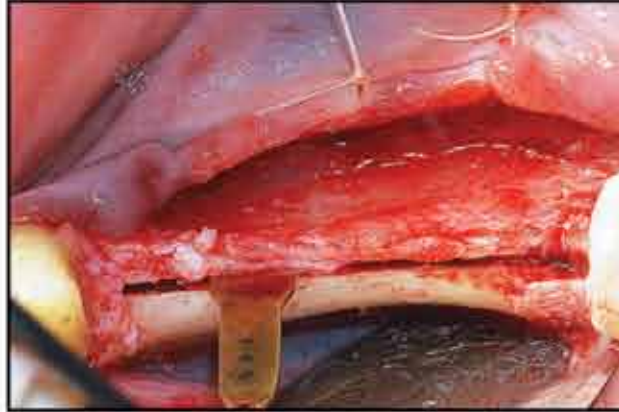
# PIEZOSURGERY<sup>®</sup> by mectron

“PIEZOSURGERY<sup>®</sup> MAKES IT SO MUCH EASIER, BEING MORE GENTLE WITH TEETH AND HARD TISSUE THAT PATIENTS HEAL BETTER WITH LESS SWELLING AND TRAUMA FOR A MORE OVERALL BENEFICIAL RESULT”

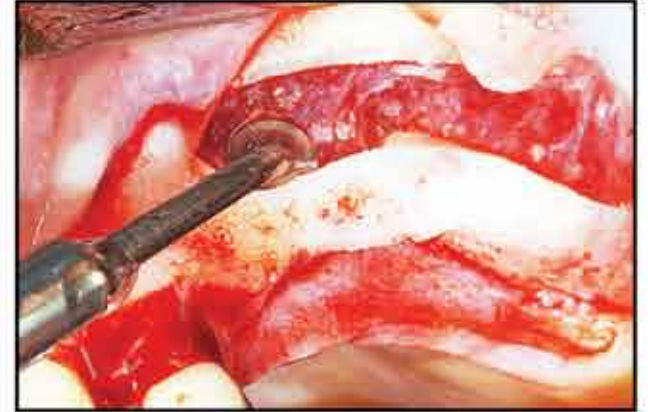- Dr. Joel Rosenlicht



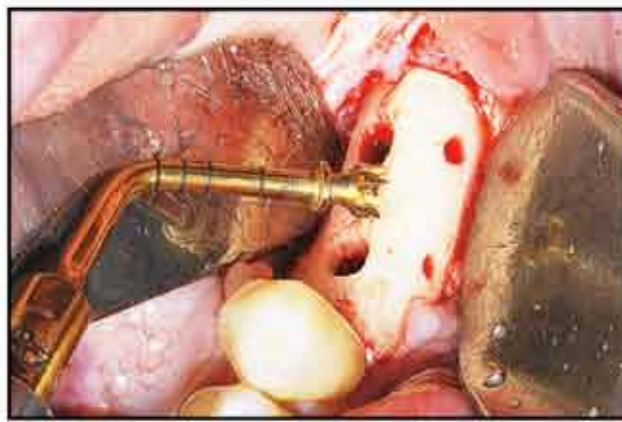
*ORTHODONTIC MICROSURGERY*



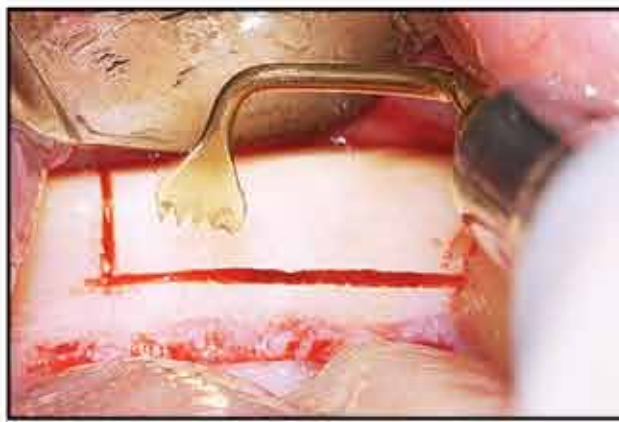
*RIDGE EXPANSION*



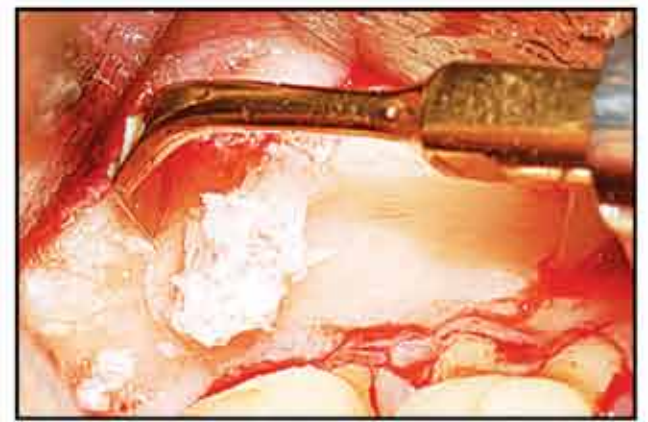*SINUS LIFT*



*IMPLANT SITE PREPARATION*

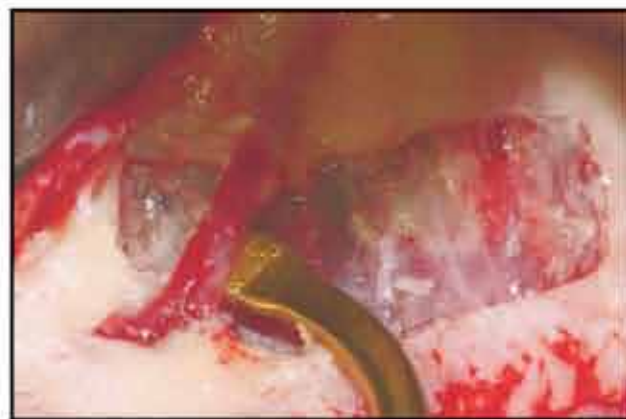

*BONE BLOCK HARVESTING*

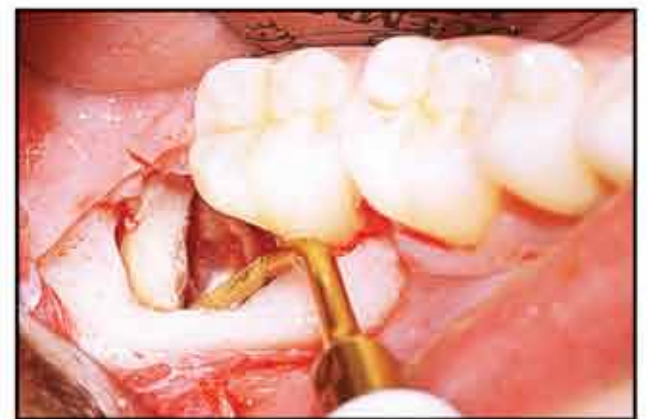

*BONE CHIP HARVESTING*

VISIT US AT  
**AAID**  
BOOTH  
#401/403

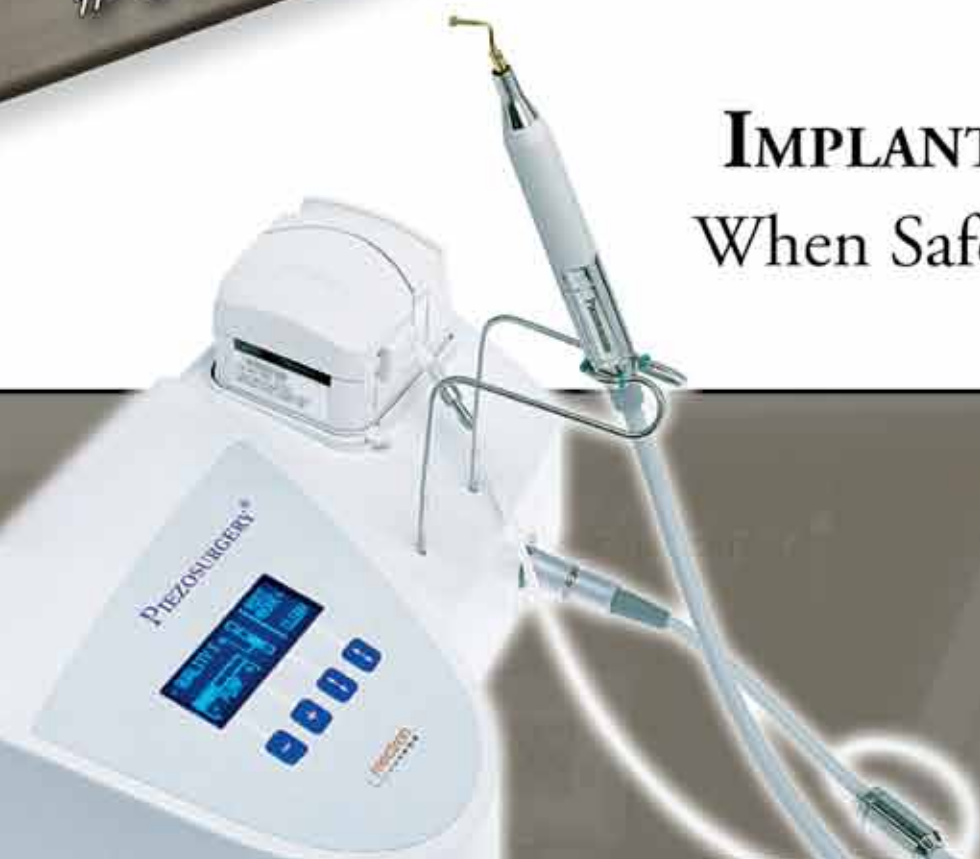


*SELECTIVE CUTTING ACTION*



*ATRAUMATIC TOOTH EXTRACTION*

Ask about our ***NEW***  
**IMPLANT SITE PREPARATION PRO KIT!**  
When Safety, Precision and Healing Matter...  
**PIEZOSURGERY<sup>®</sup>!**



**CALL TODAY!**  
**1.888.87.PIEZO**  
7 4 3 9 6  
[www.piezosurgery.us](http://www.piezosurgery.us)



← **IT** page 4

A technique developed by the author allows accurate locating of the implant head and positioning of the punch, and therefore accurate removal of the overlying soft tissue.

The technique is described as *Latch-Head Hex Tool Guided Implant Uncovering Using The Punch Technique*.

A #12 scalpel is used to locate the hex depression in the center of the cover screw (Fig. 1). A mesio-distal incision approximately 2 mm long is made over the hex depression so the latch-head driver can be inserted into the hex.

The driver handle (Zimmer Dental) (Fig. 2) or a similar device, is used to apply pressure to the hex driver to force it into the cover screw (Fig. 3). The cover screw can be unwound a few turns to blanch the gingiva, allowing the position of the implant head to be better visualized. A slow-speed round bur may be needed if bone is covering some of the cover screw. The desired diameter punch biopsy instrument is selected; they are available in 3.5 mm, 4.0 mm and 5.0 mm diameters (Ace Surgical) (Fig. 4). The latch-head driver is inserted into the cover screw (Fig. 5) and the punch biopsy instrument is inserted over the latch end of the driver (Fig. 6).

This guides the punch to accurately-



Fig. 4: Diameter punch biopsy instruments are available in 3.5 mm, 4.0 mm and 5.0 mm diameters (Ace Surgical).

ly incise the attached gingiva, which is directly over the head of the implant (Fig. 7). The hollow cutting end of the punch biopsy instrument may need to be widened inside the plastic handle area with a long thin acrylic bur to allow the latch end of the latch-head driver to not interfere with complete seating of the cutting end over the implant head. With the latch head driver in position, not only is the location of the implant head determined, but also the angle of the implant as it emerges from the edentulous ridge is indicated (Fig. 5).

With this technique, there is accurate location of the implant head and accurate and circular removal of the soft tissue over the implant with no exposed bone (Fig. 8). It is recommended to use the smallest diameter punch allowing the temporary heal-

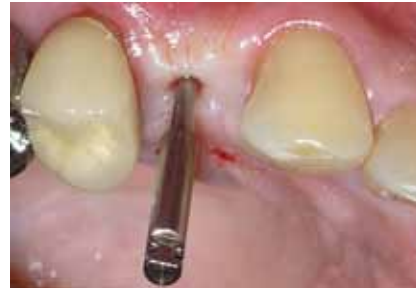

Fig. 5: The latch-head driver is inserted into the cover screw.

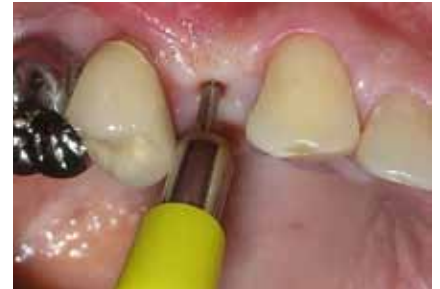

Fig. 6: The punch biopsy instrument is inserted over the latch end of the driver.

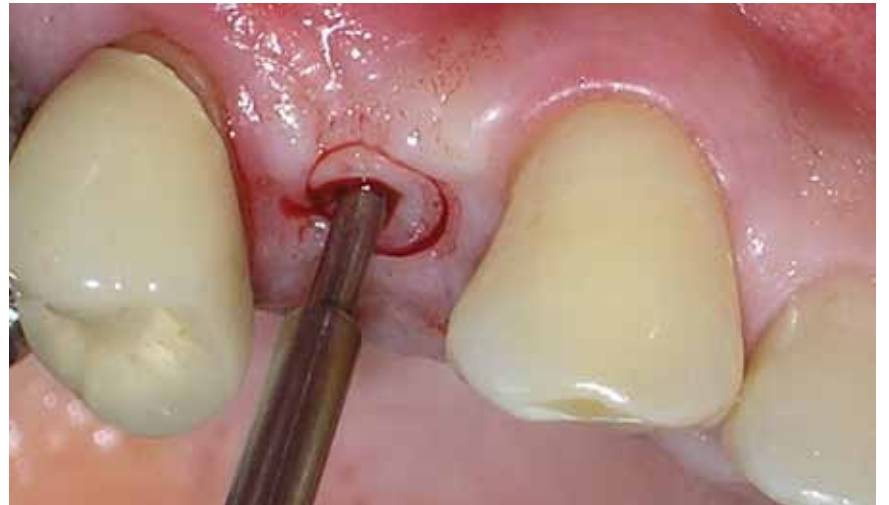

Fig. 7: Guide the punch to accurately incise the attached gingiva, which is directly over the head of the implant.

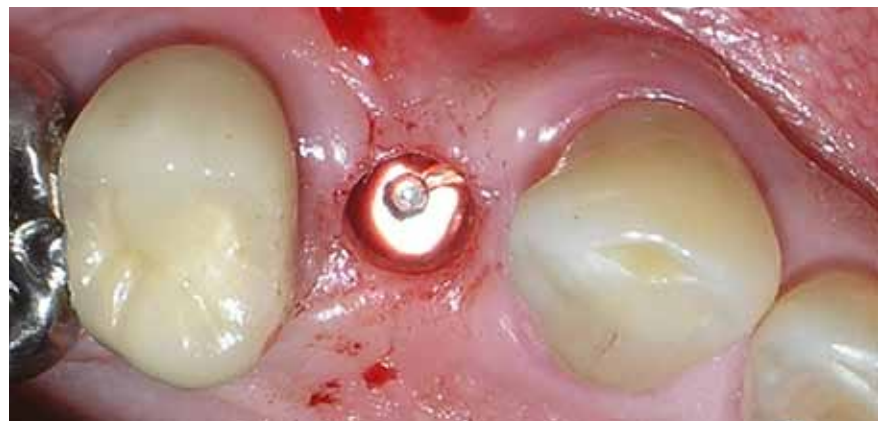


Fig. 8: Accurate and circular removal of the soft tissue over the implant with no exposed bone.

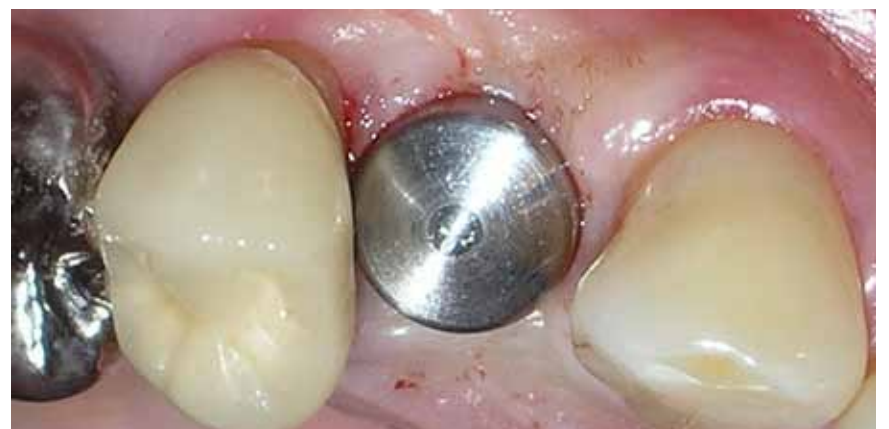




Fig. 9: It is recommended to use the smallest diameter punch, allowing the temporary healing abutment to plump out the excess attached gingiva.


AD

**Anew** NARROW-body implants

HANDS-ON WORKSHOP

DESIGNED TO FIT where **no** other can



Conventional fixtures, a predictable clinical standard, continue to exclude a wide range of patients with insufficient bone, narrow spaces and converging roots.

Reserve your space for the first HOW™ Hands-on Workshop in New Orleans & learn in real-time on an esthetic model how Anew Narrow-Body Implants overcome these challenges, with affordable remedies for the largest number of patient's immediate needs.

To register, or for more information, call Dentatus (800) 323-3136.

**December 9th - New Orleans, LA**

© 2009 Dentatus USA, Ltd · Patented & Patents pending · Photos courtesy of New York University Dental Center

AD

BETA

Dental Collab

FINALLY A SOLUTION FOR GETTING THAT SECOND OPINION.

WWW.DENTALCOLLAB.COM

FIRST MONTH FREE  
CODE: ITDC09



IT'S NEW



ing abutment to plump out the excess attached gingiva so as to mimic correct emergence profile and improve esthetics (Fig. 9). This also places some pressure on the attached gingiva around the implant to facilitate hemostasis postsurgically. One or two gut sutures may be used for hemostasis if needed.

This simple technique allows accurate exposure of the implant head with minimal postsurgical bleeding. This technique is indicated in situations where adequate attached gingiva is present on the ridge and over the head of the implant. Thus, obtaining the desired result of attached gingiva adjacent to the final restoration allows for an esthetic and functional restoration. ■

**References**

1. van Steenberghe D.A. Retrospective multicenter evaluation of the survival rate osseointegrated implants supporting fixed partial prosthesis in the treatment of partial edentulism. *J Prosthet Dent* 1989;61:217-222.
2. Jemt T, Lekholm U, Tagnar A. Osseointegrated implants in the treatment of partially edentulous patients: A preliminary study on 876 consecutive placed implants. *Int J Oral Maxillofac Implants* 1989;4:211-218.
3. Jemt T, Lekholm U. Oral implant treatment in posterior partially edentulous jaws: A five-year follow-up report. *Int J Oral Maxillofac Implants* 1995;8:635-640.
4. Adell R, Lekholm U, Rockler B, Brånemark P.I. A 15-year study of osseointegrated implants in the treatment of the edentulous jaw. *Int J Oral Surg* 1981;10:387-416.
5. Albrektsson T, Dahl E, Enbom I, et al. Osseointegrated oral implants. A Swedish multicenter study of 8,159 consecutively inserted Nobelpharma implants. *J Periodontol* 1988;59:287-296.
6. Adell R, Ericksson B, Lekholm U, Brånemark P.I., Jemt T. A long-term follow-up study of osseointegrated implants in the treatment of the totally edentulous jaw. *Int J Oral Maxillofac Implants* 1990;5:347-359.
7. Lekovic V, Camargo PM, Kokkevold PR, et al. Preservation of alveolar bone in extraction sockets using bioabsorbable membranes. *J Periodontol* 1998;69:1044-1049.
8. Iasella JM, Greenwell H, Miller RL, et al. Ridge preservation with freeze-dried bone allograft and a collagen membrane compared to extraction alone for implant site development: A clinical and histologic study in humans. *J Periodontol* 2005;72:990-999.
9. Gapski R, Wang, HL, Mascarenhas P, Lang N. Critical review of immediate implant loading. *Clin Oral Implants Res* 2003;14:151-27.
10. Stanford CM, Brand RA. Toward an understanding of implant occlusion and strain adaptive bone modeling and remodeling. *J Prosthet Dent* 1999;81:553-61.
11. Schliemann PA, Wohrie PS, Rubenstein JE, DaSilva JD, Wang

N-H. Ten-year results for Brånemark implants immediately loaded with fixed prosthesis at implant placement. *Int J Oral Maxillofac Implants* 1997;12:495-503.

12. Tarnow DP, Emtiaz S, Classi A. Immediate loading of threaded implants at stage 1 surgery in edentulous arches: Ten consecutive case reports with 1- to 5 year data. *Int J Oral Maxillofac Implants* 1997;12:519-524.
13. Chiapasco M, Gatti C, Rossi E, Haefliger W, Markwalder TH. Implant-retained mandibular overdentures with immediate loading. A retrospective multicenter study on 226 consecutive cases. *Clin Oral Implants Res* 1997;8:48-57.
14. Misch, Carl E. *Contemporary Implant Dentistry*. Mosby Inc., 1995; 461-467.

**II About the author**

Dr. William E. Mason has been in private practice limited to periodontics and dental implants since 1984 in Saginaw, Mich. Mason has placed more than 2,800 implants since his implant training in 1989. He has published eight articles in the Journal of the Michigan Dental Association and two others in national dental journals. Mason is a member of the Dean's Faculty at the University of Michigan School of Dentistry, instructing in the Graduate Periodontics Clinic. He has lectured numerous times locally and performs surgical procedures at Delta College for the instruction of dental hygiene students. He also developed and patented the Palatal Anesthesia Device (PAD), an instrument that helps make palatal injections comfortable.



AD

# SimPlant<sup>®</sup> Crystal

## Split-second sharpness

**AAID '09**  
Visit us at booth 408!

**Sharp insights in the twinkling of an eye!**

- Quick start your case planning with DentalPlanit® - 24/7 online collaboration with local imaging centers and other partners
- Obtain crystal clear images from CT and cone beam scanners

**A must-have for your practice!**

- Plan your case step by step, with ease and confidence
- Work with your preferred scanner and implant brands
- Communicate with your patients in a crystal clear way

**3D Digital Dentistry**  
Allowing you to work in a more time and cost efficient environment

simple
compatible
unique

www.materialisedental.com



# Straumann launches new Roxolid

At the 2009 annual meeting of the American Academy of Periodontology (AAP) in Boston, Straumann announced the full market launch in North America of its new high-performance dental implant material Roxolid™.

Straumann Ø5.3 mm Bone and Tissue Level implants are now available in the new material in the United States and Canada, offering customers a new level of confidence with small diameter implants. Ø5.3 mm implants currently generate approximately 15 percent of the company's global implant sales.

Roxolid is an alloy of titanium and zirconium and has been designed spe-



cifically for dental implants. Its name conveys the concept of natural physical strength combined with solidity (osseointegration).

Rigorous tests in Straumann laboratories have shown the new material has higher fatigue and tensile strength than pure titanium (grade 4 annealed and cold worked), the current material of choice for dental implants. In addition, preclinical study results have indicated that bone integrated with Roxolid perform bet-

ter than with pure titanium (grade 4).

The combination of enhanced strength and osseointegration opens the door for a new generation of small diameter implants, which may be particularly advantageous in situations where there is limited space between teeth, and when preserving existing bone and vascular supply is important. A further potential advantage could be the use in thin alveolar bone.

## Straumann's largest prelaunch clinical program to date

Engineered and developed by Straumann, Roxolid has been undergoing a broad program of clinical trials in nine countries, the first of which began

nearly two years ago.

Involving 60 centers and more than 300 patients, this is one of the largest clinical research programs ever undertaken by a dental implant company prior to market launch. Based on reports to date, the implant survival rate exceeds 99 percent. In addition, Roxolid has been made available to 450 selected specialists in a controlled release program, in which more than 6,300 implants have now been distributed.

Initial clinical reports have already been presented by lead investigators at recent major congresses, including a review of the scientific evidence and clinical application by Prof. Hans-Peter Weber (chair of the Department of Restorative Dentistry and Biomaterials Sciences at Harvard School of Dental Medicine) at the AAP.

Although Straumann obtained regulatory clearance several months ago, the company chose not to launch Roxolid until the available data from preclinical and clinical trials, including 12-month results from completed studies, had been reviewed by a clinical advisory board of independent experts. On the basis of their unanimous recommendation, Straumann is proceeding with a full market launch, beginning in North America, the world's largest market for dental implants. Roxolid will also become available to doctors and patients in Europe in the coming weeks.

## The need for high-performance materials

Pure titanium is well known for its biological compatibility with the human body and its resistance to corrosion. The discovery that bone integrates with titanium (osseointegration) opened the way for its use in orthopedic surgery and subsequently in implant dentistry, where its physical properties were also important in order to bear the very strong forces of chewing. However, the mechanical properties are limited in the case of small diameter implants or parts, which are needed for narrow spaces.

This prompted the use of alternative materials, such as titanium alloys (e.g., Ti-6Al-4V, 'TAV'), but additional strength came at the price of impaired osseointegration due to inferior biocompatibility and surface characteristics.

According to published research, titanium and zirconium are the only two metals commonly used in implantology that do not inhibit the growth of osteoblasts, the bone forming cells that are essential for osseointegration. In contrast, the alloy of titanium and vanadium (TAV) has been shown to compromise osseointegration.

Furthermore, TAV cannot accommodate the sophisticated microstructuring processes required for Straumann's third generation SLActive® surface technology, which enhances osseointegration. ■

(Source: Straumann)

AD

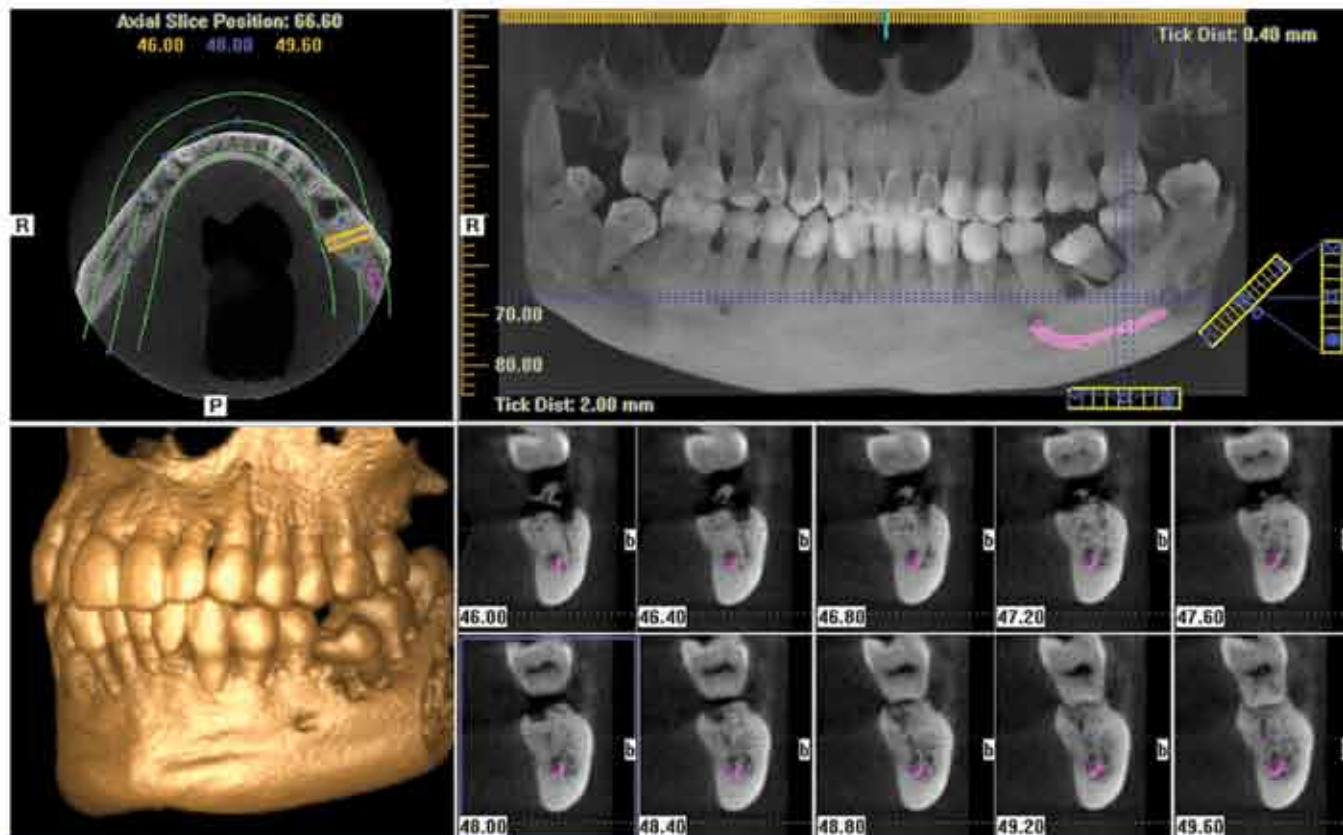
AAID AMERICAN ACADEMY OF IMPLANT DENTISTRY  
58TH ANNUAL MEETING  
NEW OPPORTUNITIES  
IN IMPLANT DENTISTRY  
NEW ORLEANS  
NOVEMBER 11-15, 2009  
WWW.AAID2009.COM

**THIS CASE-BASED CONFERENCE IS ONE OF THE BEST VALUES IN IMPLANT DENTISTRY.**

- Obtain up to 24 hours of comprehensive unbiased CE
- Interact one-on-one with the world-class presenters
- Take home clinically practical information you can use immediately
- Discover the latest products and services in implant dentistry



# Discover A New Dimension Of Predictability, Precision, And Affordability



**GX CB-500**  
POWERED BY i-CAT

New dimensions of diagnostic capability with remarkable affordability...only from Gendex.

Experience more advanced anatomical views by capturing 3-D images right in your office. Achieve accurate, immediate assessments with the GXCB-500®, powered by i-CAT®. This breakthrough, Cone Beam 3-D imaging technology is now incorporated into a system featuring ground-breaking affordability.

Provide reassurance through considerable radiation reductions, in comparison to traditional CT scans. Build patient confidence in treatment plans with a clear diagnosis. Best of all, this evolution in imaging is easily implemented! The GXCB-500 is a technological plus for both patients and practices.

- ☞ Cone Beam 3D Imaging Systems
- Panoramic X-ray Systems
- Intraoral X-ray Systems
- Digital Intraoral Sensors
- Digital X-ray Phosphor Plates
- Intraoral Cameras
- Imaging Software

Gendex Dental Systems  
www.gendex.com  
Call toll-free: 1-888-275-5286

**GENDEX**  
Imaging Excellence Since 1893