

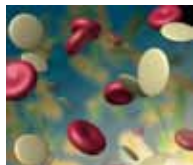# IMPLANT TRIBUNE

The World's Dental Implant Newspaper · U.S. Edition

NOVEMBER 2009

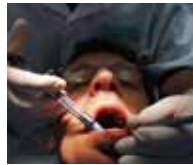www.implant-tribune.com

VOL. 4, No. 11



**Platelet-rich plasma**  
PRP therapy can accelerate bone and tissue growth

▶Page 2



**Implant experiences**  
Success rests on your interaction with the patient

▶Page 11



**New implant products**  
Implant system has many options, a variety of pricing

▶Page 22

## The forgotten implant: subperiosteal

By Pankaj Singh, DDS, DICOI, DABOI, FAAID

With very advanced jawbone resorption, there may not be enough bone width or height for the more common and routinely placed type of implant: the root form implant.

This advanced, severe bone resorption is due to long-standing edentulism and the detrimental forces from loading these jaws with soft-tissue supported dentures.

One complication that arises from this severe bone resorptive pattern is ill-fitting dentures that even after repeated relines aren't stable during normal or even soft mastication and the patients have to use massive amounts of denture adhesive to just keep them in place to speak.

Besides being a quality of life issue, it becomes a health issue as the lack of proper masticatory process results in inadequate nutrition, which leads to a host of digestive disorders including acid reflux and esophageal blockage, and can even contribute to metabolic disorders<sup>1</sup>. Chronic excessive use of denture cream containing zinc may result in hypocupremia and serious neurologic disease.<sup>2-4</sup>

Another major complication is pain from direct pressure on the exposed inferior alveolar nerve a

→ **IT** page 4

# AAID covers it all in New Orleans

By Sierra Rendon, Managing Editor

From implant design to emergency medicine to particulate grafting, there was in-depth information for everyone to take home with them from the American Academy of Implant Dentistry meeting, which was held Nov. 11 to 14 in New Orleans.

The meeting offered three days of education on new techniques on a wide variety of subjects.

Here is a sampling of the meeting's topics:

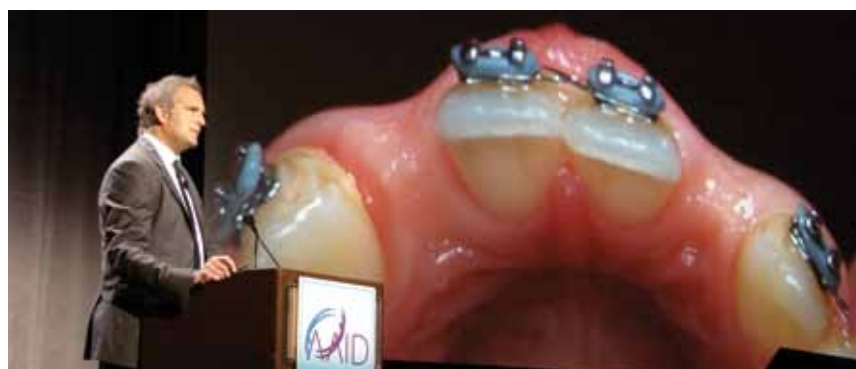**\*New implant design:** Drs. Henry Salama, Maurice Salama and David Garber presented from the perspective that implant-supported restoration must cosmetically equal or surpass that of conventional restorative dentistry.

They outlined the biological, clinical and biomechanical factors that allow clinicians to reduce or eliminate the waiting period to implant loading without sacrificing predictably successful osseointegration.

**Emergency medicine:** Dr. Stanley Malamed presented a dynamic pro-

Photo Gallery, Page 15

→ **IT** page 14



Above, Dr. Eric Van Dooren speaks Nov. 12 on the main podium. Below, Alex Miller, president of Meisinger, talks with AAID attendees about products. (Photos/Sierra Rendon)



AD

## AUXILIARIES: Are you implant certified?

Patient Questions... Insurance Coverage... Tracking...  
Operator Set Up... Radiographic Protocol...  
Assessment Parameters... Hygiene Instrumentation...  
Communications with the Lab...

Implant Training Makes all the Difference!

Dental Hygiene Implant Certification Program® (DHICP) • Practice Management Implant Certification Program® (PMICP)

Dental Assisting Implant Certification Program® (DAICP) • Implant Coordinator Training Program®

The ADIA presents these comprehensive courses at many venues throughout the year.



To find out more about these exciting programs and about membership in the ADIA visit our website:

www.adiaonline.org

PRSRT STD  
U.S. Postage  
PAID  
Permit # 306  
Mechanicsburg, PA

Dental Tribune America  
213 West 35th Street  
Suite #801  
New York, NY 10001

# AAID: Platelet-rich plasma enhances bone, tissue growth

An exciting treatment gaining acceptance in orthopedics and sports medicine, called platelet-rich plasma therapy (PRP), is showing strong potential for accelerated healing of dental implant procedures, according to a prominent dental researcher speaking at the American Academy of Implant Dentistry (AAID) annual meeting.

James Rutkowski, DMD, PhD, editor of the Journal of Oral Implantology and a practicing implant dentist in Pennsylvania, spoke at the AAID convention and said that for dental-implant patients, platelet-rich plasma therapy can accelerate bone and tissue growth and wound healing and help assure long-term success of implant placements.

"What could be better than using the body's own regenerative powers to grow bone and soft tissue safely and quickly? For dental implant procedures, PRP treatments can jump start bone growth and implant adherence in just two weeks, which cuts down the time between implant placement and affixing the permanent crown," Rutkowski said.

Platelet-rich plasma is obtained

from a small sample of the patient's own blood. It is centrifuged to separate platelet growth factors from red blood cells. The concentration of platelets triggers rapid growth of new bone and soft tissue.

"There is very little risk because we are accelerating the natural process in which the body heals itself," Rutkowski said. "PRP speeds up the healing process at the cellular level, and there is virtually no risk for allergic reaction or rejection because we use the patient's own blood."

Rutkowski noted that some orthopedic physicians have been using PRP with success for painful and hard to treat injuries like tennis elbow, tendonitis and ligament damage. An avid Pittsburgh Steelers fan, Rutkowski couldn't resist mentioning that PRP was used in 2009 pre-game Super Bowl treatment for two Steeler players (Heinz Ward and Troy Polamalo), and both were instrumental in the team winning its sixth Super Bowl.

For dental surgery applications, Rutkowski explained that PRP is mixed as a gel that can be applied directly in tooth sockets and other sites.

It also is effective in cases when

bone grafts are required to foster proper bone integration for implants.

Growth factors in PRP preparations help the grafts bond faster with the patient's own bone. Rutkowski reported that in one of his studies there was increased radiographic bone density during the initial two weeks following PRP treatment when compared to sites that did not receive PRP treatment.

"Accelerated healing is a goal we've been seeking in implant dentistry and we now have treatment that activates the natural healing process. It is a very promising development for implant dentistry," explained Rutkowski.

He estimates that about 10 percent of practicing implant dentists have used PRP treatment and predicts it will become more common as more studies are performed. ■

## About AAID

AAID is based in Chicago and has more than 3,500 members. It is the first organization dedicated to maintaining the highest standards of implant dentistry by supporting research and education to advance comprehensive implant knowledge. For more information, see [www.aaid.com](http://www.aaid.com).

# AAP supports foundation's guidelines on oral health for people with diabetes

New clinical guidelines released by the International Diabetes Foundation (IDF) emphasize the importance of periodontal health for people with diabetes. Diabetes affects approximately 246 million people worldwide, and this number is only expected to increase. The IDF is an organization of 200 national diabetes associations from 160 countries.

The new IDF oral health clinical guideline supports what research has already suggested: that management of periodontal disease — which affects the gums and other supporting tissues around the teeth — can help reduce the risk of developing diabetes; and can also help people with diabetes control their blood sugar levels. Studies have suggested there is a two-way relationship between diabetes and periodontal disease, and the IDF guideline outlines helpful guidance for

health professionals who treat people living with and at risk for diabetes.

The IDF guideline contains clinical recommendations on periodontal care, written in collaboration with the World Dental Federation (FDI), that encourage health professionals to conduct annual inquiries for symptoms of periodontal disease such as swollen or red gums or bleeding during tooth brushing, and to educate their patients with diabetes about the implications of the condition on oral health and especially periodontal health.

"Everyone should maintain healthy teeth and gums to avoid periodontal disease, but people with diabetes should pay extra attention," said Samuel Low, DDS, MS, associate dean and professor of periodontology at the University of Florida College of Dentistry, and president of the American Academy of Periodontology (AAP). "Periodontal dis-

ease triggers the body's inflammatory response which can affect insulin sensitivity and ultimately lead to unhealthy blood sugar levels. Establishing routine periodontal care is one way to help keep diabetes under control."

In recognition of American Diabetes Month, the American Academy of Periodontology commends the International Diabetes Foundation on the release of the Guideline on Oral Health for People with Diabetes. ■

## About AAP

The American Academy of Periodontology (AAP) is the professional organization for periodontists — specialists in the prevention, diagnosis and treatment of diseases affecting the gums and supporting structures of the teeth and in the placement of dental implants. The AAP has 8,000 members worldwide.

## IMPLANT TRIBUNE

The World's Newspaper of Implantology - U.S. Edition

### Publisher & Chairman

Torsten Oemus  
[t.oemus@dental-tribune.com](mailto:t.oemus@dental-tribune.com)

### Vice President Global Sales

Peter Witteczek  
[p.witteczek@dental-tribune.com](mailto:p.witteczek@dental-tribune.com)

### Chief Operating Officer

Eric Seid  
[e.seid@dental-tribune.com](mailto:e.seid@dental-tribune.com)

### Group Editor & Designer

Robin Goodman  
[r.goodman@dental-tribune.com](mailto:r.goodman@dental-tribune.com)

### Editor in Chief

Sascha A. Jovanovic, DDS, MS  
[sascha@jovanoviconline.com](mailto:sascha@jovanoviconline.com)

### Managing Editor/Designer

Implant & Endo Tribunes  
Sierra Rendon  
[s.rendon@dental-tribune.com](mailto:s.rendon@dental-tribune.com)

### Managing Editor/Designer

Ortho Tribune & Show Dailies  
Kristine Colker  
[k.colker@dental-tribune.com](mailto:k.colker@dental-tribune.com)

### Online Editor

Fred Michmershuizen  
[f.michmershuizen@dental-tribune.com](mailto:f.michmershuizen@dental-tribune.com)

### Account Manager

Humberto Estrada  
[h.estrada@dental-tribune.com](mailto:h.estrada@dental-tribune.com)

### Marketing Manager

Anna Wlodarczyk  
[a.wlodarczyk@dental-tribune.com](mailto:a.wlodarczyk@dental-tribune.com)

### Marketing & Sales Assistant

Lorrie Young  
[l.young@dental-tribune.com](mailto:l.young@dental-tribune.com)

### C.E. Manager

Julia Wehkamp  
[j.wehkamp@dental-tribune.com](mailto:j.wehkamp@dental-tribune.com)

Dental Tribune America, LLC  
213 West 35th Street, Suite 801  
New York, NY 10001  
Phone: (212) 244-7181, Fax: (212) 244-7185



Published by  
Dental Tribune America

© 2009, Dental Tribune International GmbH. All rights reserved.

Dental Tribune makes every effort to report clinical information and manufacturer's product news accurately, but cannot assume responsibility for the validity of product claims, or for typographical errors. The publishers also do not assume responsibility for product names or claims, or statements made by advertisers. Opinions expressed by authors are their own and may not reflect those of Dental Tribune International.

## Editorial Advisory Board

**Dr. Sascha Jovanovic, Editor in Chief**

Dr. Bernard Touati

Dr. Jack T. Krauser

Dr. Andre Saadoun

Dr. Gary Henkel

Dr. Doug Deporter

Dr. Michael Norton

Dr. Ken Serota

Dr. Axel Zoellner

Dr. Glen Liddelow

Dr. Marius Steigmann

**Tell us  
what  
you  
think!**

Do you have general comments or criticism you would like to share? Is there a particular topic you would like to see more articles about? Let us know by e-mailing us at [feedback@dental-tribune.com](mailto:feedback@dental-tribune.com). If you would like to make any change to your subscription (name, address or to opt out) please send us an e-mail at [database@dental-tribune.com](mailto:database@dental-tribune.com) and be sure to include which publication you are referring to. Also, please note that subscription changes can take up to 6 weeks to process.

## IT Corrections

Implant Tribune strives to maintain the utmost accuracy in its news and clinical reports. If you find a factual error or content that requires clarification, please report the details to Managing Editor Sierra Rendon at [s.rendon@dental-tribune.com](mailto:s.rendon@dental-tribune.com).

# Osteocele®

*The Future Is Now.*

## A Bone Matrix Product Containing Stem Cells.

### The Properties of Autograft without Associated Risks

The proprietary processing technology that produces Osteocele® results in a viable bone matrix product that preserves the native stem cells found in marrow rich bone. It is the only product available today that has the desired beneficial properties of autograft - osteoconduction, osteoinduction and osteogenesis — and that allows surgeons to provide their patients with optimal bone growth conditions without the added risk and cost of a secondary procedure.

### Low Immunogenicity

Mesenchymal stem cells are IMMUNE-PRIVILEGED cells that do not stimulate a cellular immune response. Osteocele does not activate T cell proliferation, as shown *in vitro* from Mixed Lymphocyte Reaction (MLR) testing.

### Histologic Evidence

Positive clinical use of Osteocele since 2005 demonstrates bone-forming ability. Histology from a human sinus augmentation study using Osteocele shows substantial vital bone content at 16 weeks, with very low residual graft material.<sup>1</sup>

### Bone Formation

Stem cells contained in Osteocele are capable of differentiating into bone cells. Every lot of Osteocele is tested for bone forming potential.

### Viable Cell Content

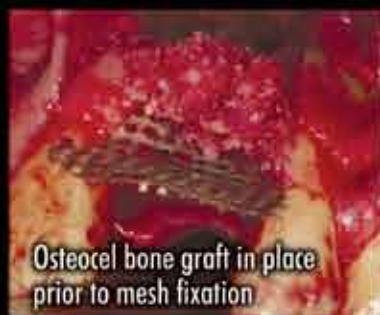The osteogenic potential arises from the stem cells in Osteocele. Following processing of marrow-rich bone, release testing demonstrates osteogenic potential according to the following criteria:

- Rich supply of stem cells: Greater than 50,000 cells/cc
- Viability: Greater than 70% cell viability
- Positive osteogenesis: *In vitro* cell culture assay

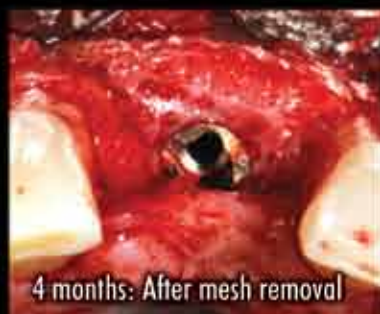<sup>1</sup> Histologic Evaluation of a Stem Cell Based Sinus Augmentation Procedure: A Case Series. — McAllister, Haghghat, Gonshor. — Journal of Perio., April 2009



Before: exposed implant



Osteocele bone graft in place prior to mesh fixation



4 months: After mesh removal

Ridge Augmentation clinical case.

For more information or to place an order call **800.441.3100**


**www.acesurgical.com**

ACE Surgical Supply Company, Inc. • 1034 Pearl Street, Brockton, MA 02301

## An Evening Lecture Series by Bradley S. McAllister, DDS, PhD

- January 27th, 2010 • Palo Alto, CA
- March 1st, 2010 • Fort Lauderdale, FL
- March 3rd, 2010 • Tampa, FL
- March 4th, 2010 • Orlando, FL
- March 23rd, 2010 • Chicago, IL

To Register, please call  
**800.441.3100**



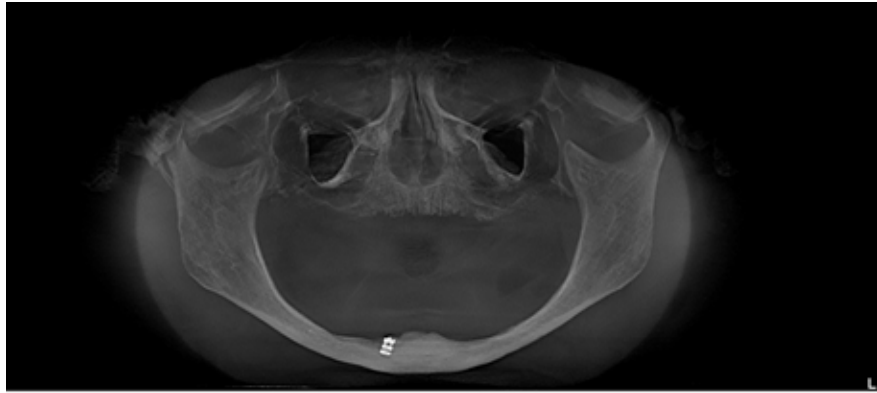


Fig. 1: Panoramic view of a severely resorbed mandible.



Fig. 2a: Mandibular complete arch subperiosteal implant with locator attachments and countersunk screw holes for bone screws.



Fig. 2b: Maxillary subperiosteal implant with receptacles with thread pattern for locator abutments and countersunk screw holes for rigid fixation using bone screws.

← **ii** page 1

result of dehissed inferior alveolar canal and mental foramen by the mandibular denture and resulting Trigeminal neuralgia.<sup>5</sup>

In these cases the subperiosteal implant can be of tremendous help.

By definition, a subperiosteal implant is a framework specifically fabricated to fit the supporting areas of the mandible or maxilla with permucosal extensions for support and attachment of a prosthesis. The framework consists of permucosal extensions with or without connecting bars and struts. Struts are classified as peripheral, primary and secondary. The subperiosteal implant can be constructed as a complete arch, unilateral or universal, and is

loaded immediately.

Prior to the tremendous success of the root form implants since Dr. Brånemark introduced the concept of osseointegration in 1981, the subperiosteal implant along with blade and plate implants were routinely used to support either a fixed, or removable, complete or partial prosthesis. The subperiosteal implant is custom made and designed to fit and sit on top and around the bone, but under the gums. There are two methods for its fabrication and installation.

The first and original technique is the "dual surgery" method. Usually under sedation, the jawbone is exposed and an impression of the bone is made using a custom impression tray and the impression material of choice (not alginate).

Whenever possible, vertical dimension in centric relation to the alveolar ridge with the opposing arch to provide inter-maxillary distance for determination of abutment height of the subperiosteal framework and the height of the prosthesis is recorded while the bone was still exposed. The gums are sutured closed and the patient is dismissed with a facemask-type compression bandage.

This impression is poured with plaster to fabricate a replica (model) of the jawbone and the model is used by the dental laboratory to custom cast the implant with the suprastructure to fit the jaw along with the final prosthesis that was prescribed. Six to eight weeks after the first-stage "impression acquisition" surgery, a second procedure is then carried out

where the jawbone is re-exposed and the implant placed and secured into place. The gums are closed with stitches over the subperiosteal and around the suprastructures and the prosthesis is placed into place.

This type of protocol was very common and predictable as it used very familiar and commonly practiced prosthodontic techniques for workup and fabrication of the implant and the final prosthesis, but was very unsatisfactory to the patient and a big deterrant for undergoing the therapy.

In the late 1980s and early 1990s with CT and within the past decade cone beam volumetric tomographic (CBVT) scans becoming more common in dental/oral surgical diag-

→ **ii** page 6

AD

## Benex<sup>®</sup> - Control Professional

Root Extraction Systems developed with Dr. Syfrig



- Safe and simple extraction of roots
- Maximal protection of the tooth socket
- Possibility of drilling even if minute root fragments or foreign bodies are present in the root
- Possibility of drilling independently of anatomic root canal

MEISINGER

GERMANY / USA



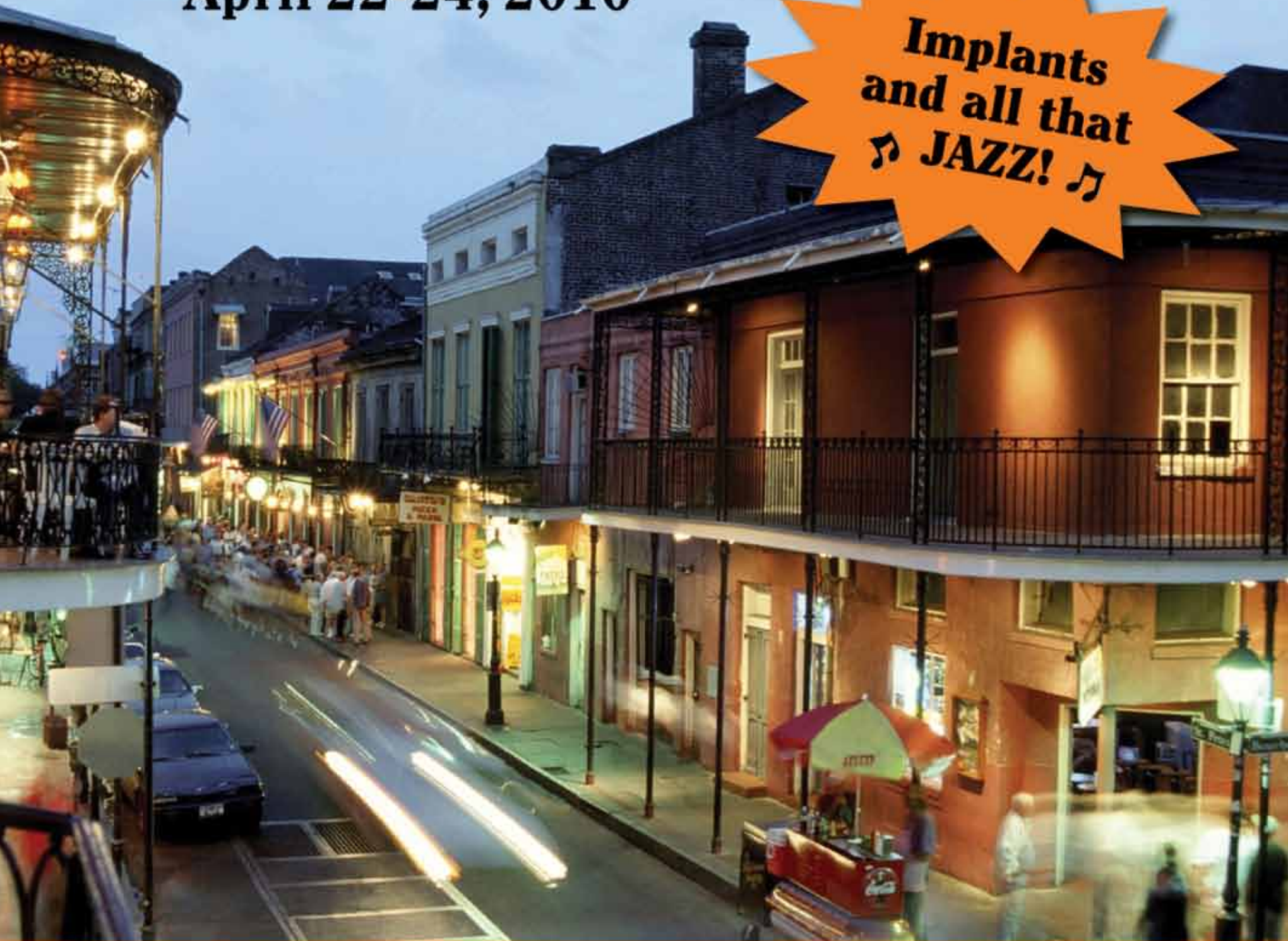

**MEISINGER USA, L.L.C.**  
 7442 South Tucson Way • Suite 130 • Centennial • Colorado 80112 • USA  
 Tel.: +1 (303) 268-5400 • Fax: +1 (303) 268-5407 • E-Mail: info@meisingerusa.com  
 www.meisingerusa.com • www.bone-management.com • www.occlusalrouter.com

# NEW ORLEANS

April 22-24, 2010

Implants  
and all that  
JAZZ!



## ICOI Spring Symposium and 13th IPS Symposium *New Orleans Marriott on Canal Street*

For more information please contact the ICOI Central Office  
at (973) 783-6300 or visit our website at [www.icoi.org](http://www.icoi.org)

Sponsored by:

**ADA CERP**® | Continuing Education  
Recognition Program

AGD - Accepted Program Provider  
FAGD/MAGD Credit, 5/1/09 - 6/30/12

Photo Credit: Richard Nowitz

ICOI is an ADA CERP Recognized Provider. ADA CERP is a service of the American Dental Association to assist dental professionals in identifying quality providers of continuing dental education. ADA CERP does not approve or endorse individual courses or instructors, nor does it imply acceptance of credit hours by boards of dentistry. ICOI designates this activity for **23 continuing education credits**.



**ADIA**

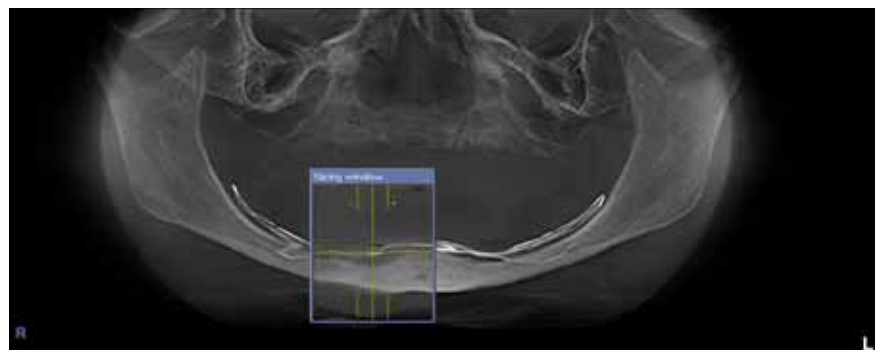


Fig. 3a: Panoramic.

← **ii** page 4

nosis and treatment planning, and medical modeling companies getting better and more accurate in computer modeling of anatomic structures, the first stage surgery for the fabrication of an accurate impression of the jaw was bypassed.

For the “single surgery” method, a special CT/CBVT scan of the arch being considered for rehabilitation is ordered. A replica (radiographic template) of the final prosthesis is fabricated with the denture base made with acrylic with 25 percent barium sulfate, a radiopaque marker that shows in the 3-D radiograph outlining the soft tissue (gum) architecture (Fig. 3).

The radiographic template is

worn during the scan, and using the scan data and advanced computer modeling techniques, a model of the jawbone and overlaying soft tissue is constructed.

This stereoithographic model (Fig. 4) of the alveolus and the overlaying gum (Fig. 5) is used by the dental laboratory to fabricate the custom subperiosteal implant and process and finish the prosthesis for immediate function.

A surgical procedure is then carried out where the alveolus is exposed and the implant placed and secured to the jaw (with bone screws) and any gaps between the implant and the underlying bone is filled with hard tissue graft of the dentist’s liking and guided bone regeneration technique is applied. The gums are closed with stitches

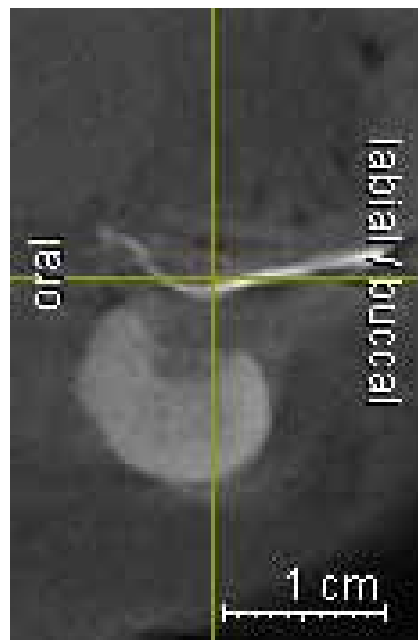


Fig. 3b: Cross-section view of the radiopaque radiographic guide; notice the dehissed mental foramen.

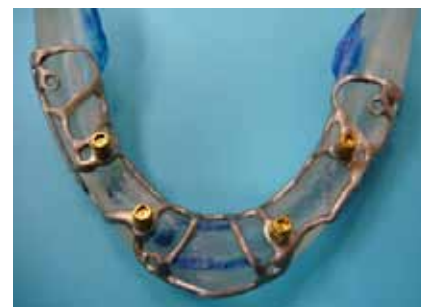

Fig. 4a: Mandibular model with the subperiosteal over it in place.



Fig. 4b: Maxilla, occlusal view.



Fig. 4b: Maxilla, anterior view.

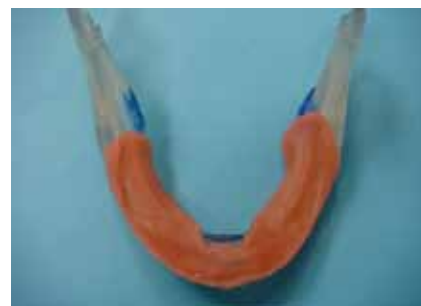

Fig. 5a: Mandible.

and the prosthetic is put into place for immediate function.

The patient is instructed in the usual manner for postoperative wound and prosthesis care and a stretchable compression bandage is applied.

This modern one-stage protocol is more palatable for the patient who is more likely to consider this form of implant therapy versus undergoing multiple augmentation procedures to build the ridge to the appropriate dimensions (height and width) in the certain areas for implantation of appropriately sized rootform implants. Depending on the location and type of materials used for augmentation, it could be six months to up to two years or more before the patient is rehabilitated with a final prosthesis.

At times, the patient is not a good candidate to undergo such significant augmentative procedures either due to health or financial considerations.

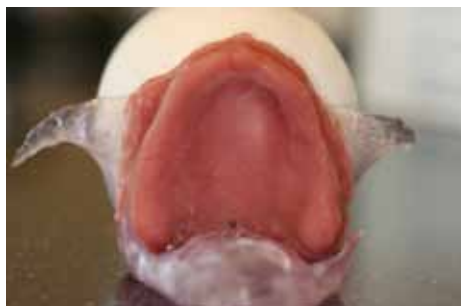

Fig. 5b: Maxilla.

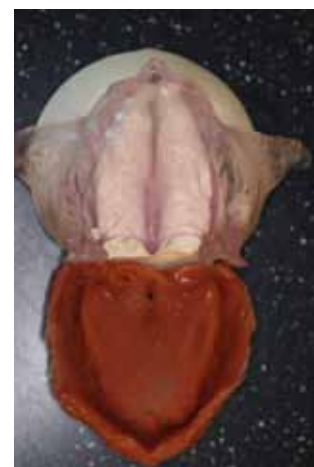




Fig. 5c: Maxilla degloved.


ADS

**ANEW<sup>®</sup> NARROW-body implants**

**HANDS-ON WORKSHOP**

DESIGNED TO FIT where **no** other can



Conventional fixtures, a predictable clinical standard, continue to exclude a wide range of patients with insufficient bone, narrow spaces and converging roots.

Reserve your space for the first HOW™ Hands-on Workshop in New Orleans & learn in real-time on an esthetic model how Anew Narrow-Body Implants overcome these challenges, with affordable remedies for the largest number of patient’s immediate needs.

To register, or for more information, call Dentatus (800) 323-3136.

December 9<sup>th</sup> - New Orleans, LA

© 2009 Dentatus USA, Ltd - Patented & Patents pending - Photos courtesy of New York University Dental Center

Dental Collab BETA

FINALLY A SOLUTION FOR GETTING THAT SECOND OPINION.

WWW.DENTALCOLLAB.COM

FIRST MONTH FREE

CODE: ITDC09



**Case report No. 1**

A 61-year-old caucasian female presents with the chief complaint that her lower denture doesn't fit well and every time she wore it, it caused great pain and a burning sensation in the lower jaw. She only wore it for cosmetic reasons and never chewed with them in and made excuses for not eating in company of others.

She has been to several dentists, including prosthodontists, who fail to fabricate complete removable mandibular dentures she can wear comfortably.

She also has sought consultations with several oral surgeons who would only recommend multiple autogenous onlay grafts in the intermental region for an implant-supported soft-tissue bourne overdenture with the possibility of still experiencing pain due to the free end saddles pressing into the exposed mental foramen and inferior alveolar nerve when chewing.

Her past medical history was significant for post-menopausal osteoporosis for which she takes Boniva (ibandronate sodium) once a month. She also suffers from hypertension, which is under control, and for which she takes a combination of thiazide diuretic and beta blocker. She also suffers from panic disorder for which she takes Zanax (alprazolam) on a regular basis.

Social history is significant for her becoming a widow eight years ago and is socially active, and her only son was to be married within three months of consultation.

Her past dental history is significant for periodontal disease, which was the reason for her losing all of her teeth by the time she was in her 30s and now having severe atrophy of both jaws.

Twenty years ago, she began implant therapy for supporting her complete mandibular dentures. During the years, the implants failed for one reason or another and the last one remaining is fractured with a piece still integrated but not usable. Both mental foramen and parts of the mandibular canal are exposed on the crest of the alveolus with the nerves enveloped in the soft tissue over the crest.

Treatment plans were developed after an initial panoramic view was extracted from a CBVT.

**Treatment plan No. 1**

- Total treatment time: eight to 12 months.

- Anterior illiac crest to be used as a donor site for block grafts to augment the intermental region and posterior mandible with bilateral relocation of the mental foramen and mandibular canal more apically and laterally.

- Surgery under general anesthesia.

- Insertion of a full maxillary removable denture and immediate insertion complete mandibular denture at the time of mandibular augmentation.

- Healing time of six months and then insert four implants to support an implant-supported locator mandibular overdenture or eight implants to support a fixed cemented prosthesis and, depending on the primary



Fig. 6: Duplicate cast of the stereolithographic model with the waxup of the subperiosteal framework with locator abutments.

stability of the implants, to either load immediately or delay the load four months.

**Treatment plan No. 2**

- Total treatment time: six to eight weeks. (Patient elected to undergo

this option.)

- One-stage protocol mandibular subperiosteal (bone contact side coated with hydroxyl apatite) placement and rigid fixation with bone screws and simultaneous bilateral relocation of the mental foramen and mandibular canal more apically and laterally.

- Surgery under I.V. conscious sedation and local anesthesia.

- Insertion of a full maxillary removable denture and immediate insertion of a functionally loaded complete mandibular denture using four locator abutments.

- Permanent relines of the lower prosthesis in two months.

**Case report No. 2**

A 48-year-old caucasian female presents with the chief complaint that her lower implant bar-retained over-

denture is extremely uncomfortable, doesn't fit well and is cosmetically unacceptable. She is also unhappy with the way her maxillary denture fits and feels.

She has sought consultation from several dentists including prosthodontists, periodontists and oral surgeons who recommended various options, including removal of the existing implants and placing new ones in a more favorable angulation and even changing the retention mechanism from bar to individual implant retention (o-rings, locators and type).

For the maxillary denture, all recommended a new denture.

Her past medical history was insignificant.

→ page 8

AD

# SimPlant<sup>®</sup> Crystal

## Split-second sharpness

**Sharp insights in the twinkling of an eye!**

- Quick start your case planning with DentalPlanit<sup>®</sup> – 24/7 online collaboration with local imaging centers and other partners
- Obtain crystal clear images from CT and cone beam scanners

**A must-have for your practice!**

- Plan your case step by step, with ease and confidence
- Work with your preferred scanner and implant brands
- Communicate with your patients in a crystal clear way

**3D Digital Dentistry**  
Allowing you to work in a more time and cost efficient environment

simple
compatible
unique

www.materialisedental.com

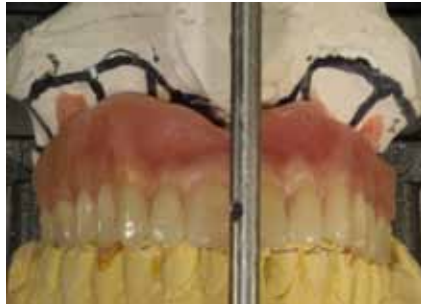

Fig. 7a: Processed final restoration; maxillary full denture.

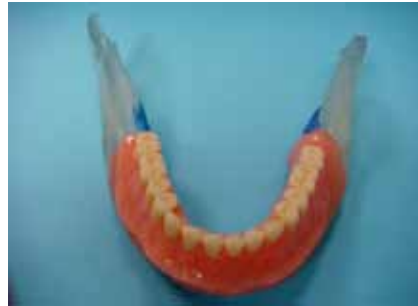

Fig. 7b: Processed final restoration; mandibular complete denture.

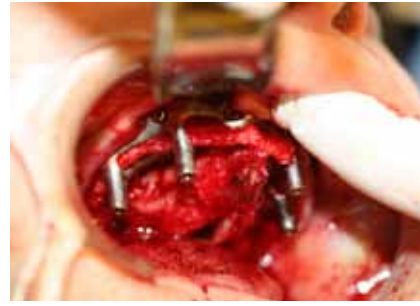

Fig. 8a: Subperiosteal over the maxillary ridge, held down with bone screws.



Fig. 8b: Bone screws and a mandibular subperiosteal.

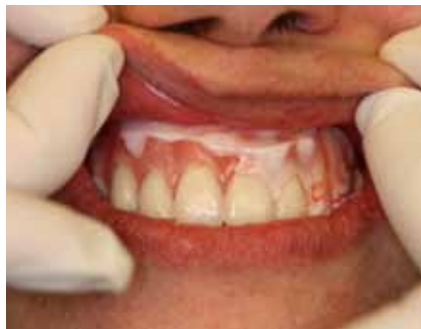

Fig. 9: Soft tissue reline of the immediately loaded maxillary denture.

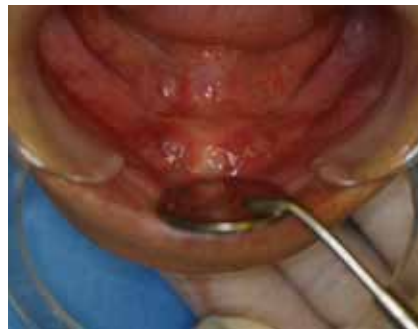

Fig. 10: Pre-op occlusal view of the severely resorbed mandible.

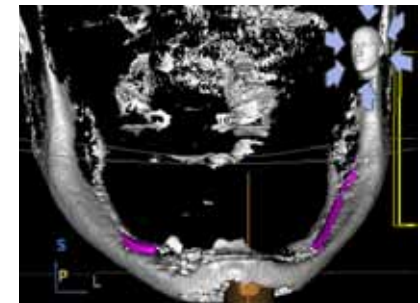


Fig. 11: Reconstructed view of the mandible with the exposed inferior alveolar canals highlighted in purple.

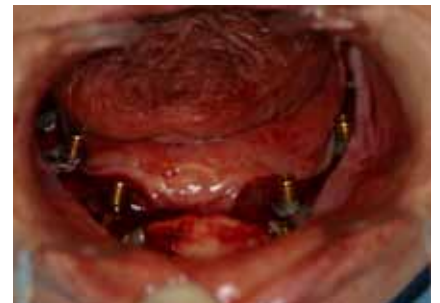

Fig. 12: Intraop view of the mandibular subperiosteal with bone screws visible on the buccal in the canine region.

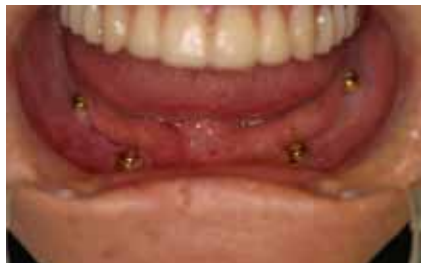

Fig. 13: Two weeks postoperative view of the transgingival locator abutments.

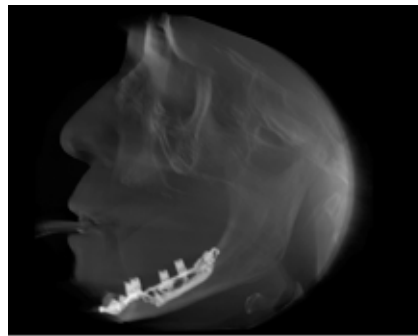


Fig. 14: Lateral Cephalometric view of the installed mandibular full subperiosteal implant. Notice the intimate fit of the framework to the underlying bone.

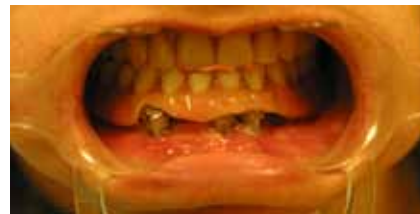

Fig. 15: Initial view of mandibular denture adapted to the implant-supported bar. Note the angulation of the implants, making the bar out too far labially where the buccal flange could not cover it, and a window cut out to accommodate the seating of the denture.

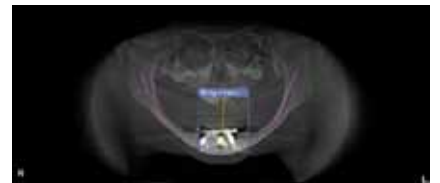


Fig. 16: Preoperative panoramic view outlining the mandibular canal in purple.

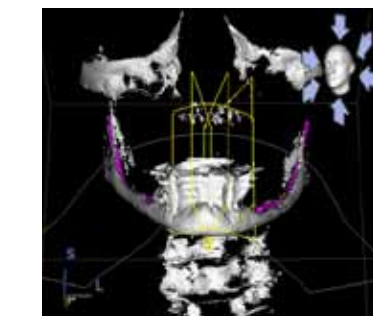


Fig. 17: Reconstructed 3-D view of the severely atrophied mandible and the maxilla with dehissed mandibular canals.

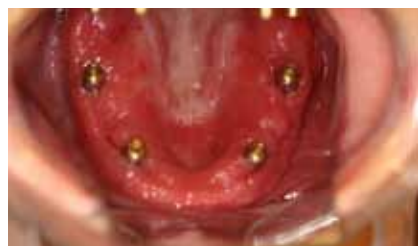

Fig. 18: One month postoperative view of the maxillary subperiosteal implant.

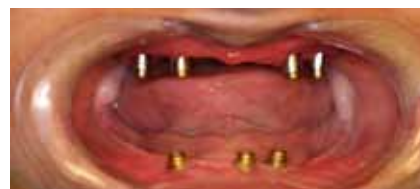

Fig. 19: Antero-posterior view of the permucosal locator abutment's part of the maxillary subperiosteal and the replacement of the mandibular bar for retention of complete dentures.

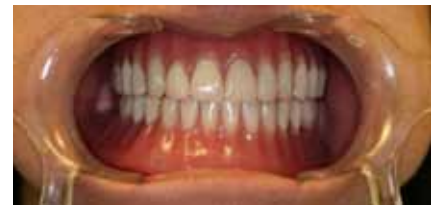

Fig. 20: Anterior view of the completed dentures in place, attached to the locator abutments.

← **ii** page 7

nificant and was categorized as an ASA1 patient. Social history is significant for divorce five years ago, and she is planning on remarrying in the near future.

Her past dental history is significant for becoming completely edentulous at age 18 upon recommendation of her dentist. Ten years ago, she had four implants placed in the anterior mandibular symphysis out of which one failed. Her bar was preserved and made usable with three implants.

Two years ago, she had new mandibular and maxillary dentures fabricated by a prosthodontist that was recommended by the periodontist who removed the failed implant.

Treatment plans were developed after evaluation of the panoramic view extracted from the initial CBVT.

Treatment plan the patient elected to undergo: Total treatment time of eight to 12 weeks.

- Remove the mandibular anterior bar and replace it with locator abutments and fabricate a new mandibular implant-retained overdenture on the remaining three implants.

- One-stage protocol maxillary subperiosteal (bone contact side coated with hydroxyl apatite) placement and rigid fixation with bone screws.

- Surgery under I.V. conscious sedation and local anesthesia.

- Insertion of an immediate insertion (locator attached) complete maxillary denture at the time of implant placement.

### Conclusion

Both patients and others like them have undergone this type of rehabilitation using subperiosteal implants without any untoward complications and have reported satisfactory results upon visits with the hygienist.

The author would like to acknowledge Dr. Jerome Kaufman, DDS, (prosthodontist) of Arch Dental at Le Visage Center for Cosmetic and

Implant Dentistry for performing the prosthetic workup and completion of such challenging reconstructions, and Ryan Dutton, CDT of Dutton Dental Laboratory, Ohio, for his exemplary fabrication of such difficult and precise frameworks..

For detailed step-by-step instructions on the protocol for a one- or two-stage subperiosteal implant and accompanying prosthetics, please refer to Chapters 14, 15, 26 of the "Atlas of Oral Implantology," third edition.

### References

1. [www.articlesbase.com/health-articles/do-you-use-tagamet-pepcid-axid-or-zantac-62586.html](http://www.articlesbase.com/health-articles/do-you-use-tagamet-pepcid-axid-or-zantac-62586.html)
2. M. Spinazzi and M. Armani, Neurology, July 7, 2009; 75(1):676.
3. Nations SP et al., Neurology 2008 Aug. 26; 71:639.
4. Schaumburg H and Herskovitz S., Neurology 2008 Aug. 26; 71:622.
5. L. R. Carney, Neurology, Dec. 1967; 17: 1143.

### **ii** About the author

Dr. Pankaj Singh has authored the third edition of the best-selling textbook on dental implants, "The Atlas of Oral Implantology," which will be released in December. Singh is an attending faculty at the Department of Dental Medicine and Oral Surgery at LIJ-North Shore University Hospital Medical Center in New York and is a clinical instructor of advanced dentistry at New York University College of Dentistry (subatical). He is the founder and CEO of Arch Dental Associates and Le Visage Cosmetic & Implant Dentistry with offices in Manhattan, Huntington and Garden City, NY. Singh has been in private practice for more than 15 years, specializing in implant, sedation, reconstructive dentistry and dental sleep medicine. He is a graduate of New York University College of Dentistry. He completed his advanced training in dental implants at Brookdale Hospital and NYU.





# Materialise Dental, Medical Modeling establish partnership for surgery planning

Materialise Dental, which develops 3-D technology solutions for implant practices, oral maxillofacial surgeons and orthodontists, announced recently that it has established a partnership with Medical Modeling.

The new partnership allows Medical Modeling to exclusively manufacture orthognathic CAD/CAM splints for the United States market and equally provide support for the SimPlant® OMS software.

Materialise Dental focuses on 3-D digital dentistry, offering a range of integrated solutions in computer guided dentistry.

With SimPlant OMS, the company provides an interactive 3-D system for predictable diagnosis and treatment planning of orthognathic cases. SimPlant OMS allows for accurate 3-D cephalometric analysis, surgical simulation and prediction of soft tissue movements.

Based on the surgeon's pre-operative treatment planning, Medical Modeling then produces custom-made intermediate and final splints using the stereolithography (SLA) process, an additive manufacturing technique.

The splints provide a seamless link between planning and actual surgery, ensuring optimal jaw positioning during surgery without any time consuming model surgery.

Bart Swaelens, CEO of Materialise Dental said: "Medical Modeling has many years of experience in supporting development of an accurate and predictable orthognathic surgical protocol. We value the company's high esteem for quality service toward its customers and thus we trust they will do an excellent job in managing the SimPlant OMS software support. Their know-how in orthognathic surgery and our industry expertise in 3-D treatment planning software complement each other perfectly."

Andy Christensen, president of Medical Modeling, said: "We are proud to partner with Materialise Dental for the U.S. market, as they are a fast-growing international company with a strong background in the research and development of computer-guided treatment planning software and patient-specific medical devices. Thanks to our unique strengths, we can offer surgeons performing orthognathic cases a combination of the best 3-D treatment planning tools and orthognathic CAD/CAM splints available on the market today."

The partnership gives surgeons the possibility to opt for all-round assistance during the treatment planning process.

Engineers at Medical Modeling are equipped to help provide hands-on assistance for surgical planning using the software. Additionally, SimPlant OMS users will gain access to patented technology surrounding Medical Modeling's protocol including fidu-




cial registration of occlusal anatomy.

## About Medical Modeling

Medical Modeling Inc., based in Golden, Colo., is a world leader in production of custom anatomical models made using medical imaging data combined with additive manufacturing technology. Every day around the

world surgeons count on the company's ClearView® and OsteoView® anatomical models to prepare for and guide complex surgery spanning the fields of orthopedic surgery, spine surgery, cranio-maxillofacial surgery and neurosurgery. More information on Medical Modeling can be found at [www.medicalmodeling.com](http://www.medicalmodeling.com).

## About Materialise Dental

Materialise Dental focuses on 3-D digital dentistry by offering a range of products and services to support specialists in the treatment of their patients. Materialise Dental continues to lead the dental industry in medical image processing, surgery simulation and rapid prototyping technology. The company is represented worldwide by subsidiary offices and authorized distributors and is a trusted partner for many of the largest clinics and research institutions. For more information, see [www.materialisedental.com](http://www.materialisedental.com). 

AD






Enter to win an **iPod Touch** in a daily drawing when you participate in a free demo

## Quality Leader in 3D CBCT Imaging

# PreXion


The World's Best Image Quality

Visit us at GNYDM  
Booth #1225

The PreXion 3D Dental CBCT Scanner has the highest resolution of any Cone Beam System. Additional benefits include:

- **Soon:** Implant planning feature
- Upgraded panoramic view
- Generate more revenue
- Four different scanning modes
- User-friendly controls and software
- Powerful diagnostic 3D planning tools
- Proprietary XTrillion processor
- Ideal for implant planning
- Small foot print fits anywhere



Contact us today for an in-office demonstration at  
(650) 212-0300 | [info@prexion.com](mailto:info@prexion.com) | [www.prexion.com](http://www.prexion.com)