

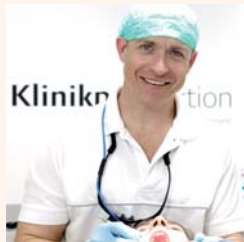DENTAL TRIBUNE

—   The World's Dental Newspaper · Nordic Edition   —

PUBLISHED IN STOCKHOLM

www.dental-tribune.com

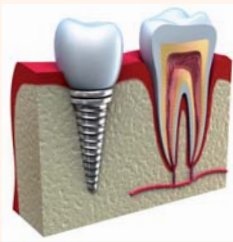VOL. 1, No. 2



INTERVIEW

Danish dentist Dr Jens Lætgaard on the challenges of performing live surgery and why he thinks video training is the educational tool of the future.

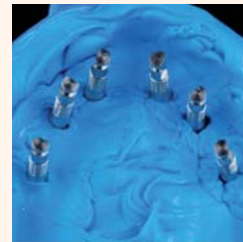
► Page 6



BIOPHOSPHONATES

Although the risks of bisphosphonates are disputed among professionals, clinical data suggests that they can be locally applied safely and efficaciously in dentistry.

► Page 12



TRENDS & APPLICATIONS

Implant restorations that offer the form and function of natural teeth: A clinical case of full-arch PFM restorations for an edentulous patient with advanced bone resorption.

► Page 13

Biomarkers for dental caries

By DTI

ODENSE, Denmark/VALENCIA, Spain: In order to determine potential biomarkers for dental caries, an international team of researchers from the Department of Biochemistry and Molecular Biology at the University of Southern Denmark in Odense and from the FISABIO Foundation in Valencia has taken a closer look at the human oral metaproteome, the most prevalent proteins found in oral biofilm.

Aiming to determine a minimum set of proteins that allow for discrimination between healthy and caries-affected dental plaque samples, the scientists identified 7,771 bacterial and 853 human proteins in 17 individuals. The study's metaproteomic analyses of the oral biofilm provide the first protein repertoire of human dental plaque, the researchers stated. Moreover, by using different mass spectrometry approaches, they were subsequently able to quantify individual peptides in healthy and caries-bearing individuals.

Their findings showed that healthy individuals appeared to have



The researchers were able to quantify individual peptides in healthy and caries-bearing individuals.

significantly higher amounts of enzymes associated with a high acid tolerance. Other proteins found to be at significantly higher levels in caries-free individuals were involved in exopolysaccharide synthesis, iron metabolism and immune response. By interpreting the potential bio-

markers collectively, the scientists were able to determine the oral health status of the individuals studied with an estimated specificity of over 96 percent. Although validation of the findings in larger sample size studies is necessary, the findings could be of use for developing future

caries risk screenings, the researchers concluded.

The results were published online on 14 August in the *PROTEOMICS* journal in the article "The human oral metaproteome reveals potential biomarkers for caries disease".

Milk keeps teeth white

Beverages such as black tea, coffee, cola and red wine can discolor the surface of the teeth. However, researchers from the University of Alberta may have found a solution to the problem—at least for the tea lovers out there.

In testing the effect of milk on the staining properties of tea, they found that it significantly reduced the tea's ability to darken the teeth. A staining procedure that involved either a solution of tea or a solution of tea with milk showed that casein, the main protein in milk, has the ability to bind the tannins, which are water-soluble compounds that are largely responsible for the staining properties of tea.

"The magnitude of the color change observed in our experiments is comparable to the color change seen with vital bleaching products and is more effective than whitening toothpastes," Dr. Ava Chow, an assistant professor at the university's school of dentistry said.

Night owls' higher risk of caries

People's circadian rhythms might have a greater impact on healthy teeth than one might assume. A study at Dalarna University has found that young Swedes who regularly stayed up late had an almost four times higher risk of dental caries than did early risers.

In the analyses, the scientists distinguished three circadian types: evening types, who are alert in the evening and tired in the morning; morning types, who are the opposite; and neutral types, who are neither particularly alert in the evening nor extremely tired in the morning.

The results indicated an association between caries risk and participants' individual circadian rhythm, breakfast habits and toothbrushing frequency.

Morning and neutral types reported more frequently that they had breakfast every morning and brushed their teeth twice a day. Evening types, in comparison, brushed their teeth less often and ate breakfast less regularly. More evening than morning types were categorized as being at high risk of caries. As a result, the predicted probability of being at high risk of caries was almost four times higher for evening types than for morning types.

Acknowledging the connection between sleeping preferences and dental hygiene habits, the scientists suggested that dentists consider their patients' circadian rhythms when approaching oral health education in daily dental practice, especially for patients with a high risk of caries.



AD

PRINT
DIGITAL
EDUCATION
EVENTS

ESSENTIAL DENTAL MEDIA

www.dental-tribune.com

The DTI publishing group is composed of the world's leading dental trade publishers that reach more than 650,000 dentists in more than 90 countries.

dti] Dental Tribune International

Clear aligners prove to be more beneficial than braces

MAINZ, Germany: In recent years, clear aligners have become a favourable treatment alternative in orthodontics to fixed orthodontic appliances (FOA). However, there are few studies about the effects of aligner treatment on oral hygiene and gingival

condition. A team of German researchers has now compared the oral health status, oral hygiene and treatment satisfaction of patients treated

They found that Invisalign patients have better periodontal health and greater satisfaction during orthodontic treatment.

To date, the majority of patients, particularly during childhood and adolescence, are treated with FOA. However, these appliances tend to complicate oral hygiene and thus interfere with patients' periodontal health. Moreover, treatment with FOA is not very popular in adult orthodontics for aesthetic reasons. Therefore, other orthodontic techniques have been developed to improve aesthetics and simplify oral hygiene procedures. An alternative to FOA is clear aligners, which are discreet and have the advantage of being removable during oral hygiene and eating or drinking. The use of clear aligners has increased

greatly in the last decade, one prominent example being Invisalign, produced by Align Technology since 1999. However, only a limited number of studies have compared the effects of Invisalign and FOA on oral hygiene, the researchers from the Johannes Gutenberg University of Mainz pointed out.

Their study included 100 patients who underwent orthodontic treatment, divided equally between FOA and Invisalign, for more than six months. The researchers performed clinical examinations before and after treatment to evaluate the patients' periodontal condition and any changes. Furthermore, a detailed questionnaire assessed the patients' personal oral hygiene and dietary habits, as well as satisfaction with the treatment. All of the patients received the same oral hygiene instructions before and during orthodontic treatment. This included the use of toothbrush, dental floss and interdental brushes three times daily.

The data analysis showed no differences between the two groups regarding periodontal health and oral hygiene prior to the orthodontic treatment. However, the researchers observed notable changes in periodontal condition in both groups during orthodontic treatment. They found that gingival health was significantly better in patients treated with Invisalign, and the amount of dental plaque was also less but not significantly different compared with FOA patients.

The questionnaire results showed greater satisfaction in patients treated with Invisalign. Only 6 per cent of the Invisalign patients reported impairment of their general well-being during orthodontic treatment, compared with 36 per cent of the FOA patients. Other negative effects that also were significantly higher in FOA patients included gingival irritation (FOA: 56 per cent; Invisalign: 14 per cent), being kept from laughing for aesthetic reasons (FOA: 26 per cent; Invisalign: 6 per cent), having to change eating habits during orthodontic treatment (FOA: 70 per cent; Invisalign: 50 per cent), and having to brush one's teeth for longer and more often (FOA: 84 per cent; Invisalign: 52 per cent).

The researchers concluded that orthodontic treatment with Invisalign has significantly lower negative impacts on a patient's condition than treatment with FOA, both with regard to gingival health and overall well-being.

The study, titled "Braces versus Invisalign: Gingival parameters and patients' satisfaction during treatment: A cross-sectional study", was published online in the *BMC Oral Health* journal on 24 June.

with FOA and the Invisalign-aligner-system.

In the study, Invisalign patients showed better periodontal health and greater satisfaction during orthodontic treatment than patients with fixed orthodontic appliances.

AD



34th CIOSP


São Paulo International Dental Meeting

January, 27-30, 2016

At the Expo Center Norte - São Paulo/SP - Brazil

Exhibit Inquiry: SUVISON, a sole world agent, sp2016@suvison.com

Information and Registration: secretaria.decofe@apcdcentral.com.br | ciosp.com.br



The largest dental event in Latin America!

Organizer:



São Paulo Dental Association

Support:



International Media:



IMPRINT

PUBLISHER:

Torsten OEMUS

MANAGING EDITOR DT NORDIC EDITION:

Kristin HÜBNER
k.huebner@dental-tribune.com

CLINICAL EDITOR:

Magda WOJTKIEWICZ

ONLINE EDITOR:

Claudia DUSCHEK

ASSISTANT EDITORS:

Anne FAULMANN

COPY EDITORS:

Sabrina RAAFF, Hans MOTSCHMANN

PRESIDENT/CEO:

Torsten OEMUS

CFO/COO:

Dan WUNDERLICH

MEDIA SALES MANAGERS:

Matthias DIESSNER
Peter WITTECZEK
Maria KAISER
Melissa BROWN
Weridiana MAGESWKI
Hélène CARPENTIER
Antje KAHNT

MARKETING & SALES SERVICES:

Nicole ANDRAE

ACCOUNTING:

Karen HAMATSCHEK

BUSINESS DEVELOPMENT:

Claudia SALWICZEK

EXECUTIVE PRODUCER:

Gernot MEYER

AD PRODUCTION:

Marius MEZGER

DESIGNER:

Franziska DACHSEL, Matthias ABICHT

INTERNATIONAL EDITORIAL BOARD:

Dr Nasser Barghi, Ceramics, USA
Dr Karl Behr, Endodontics, Germany
Dr George Freedman, Esthetics, Canada
Dr Howard Glazer, Cariology, USA
Prof. Dr I. Krejci, Conservative Dentistry, Switzerland
Dr Edward Lynch, Restorative, Ireland
Dr Ziv Mazor, Implantology, Israel
Prof. Dr Georg Meyer, Restorative, Germany
Prof. Dr Rudolph Slavicek, Function, Austria
Dr Marius Steigmann, Implantology, Germany

Published by DTI

DENTAL TRIBUNE INTERNATIONAL

Holbeinstr. 29, 04229, Leipzig, Germany
Tel.: +49 341 48474-302
Fax: +49 341 48474-173
info@dental-tribune.com
www.dental-tribune.com

Regional Offices:

UNITED KINGDOM

Baird House, 4th Floor, 15-17 St. Cross Street
London EC1N 8UW
www.dental-tribune.co.uk
info@dental-tribune.com

DT ASIA PACIFIC LTD.

c/o Yonto Risio Communications Ltd,
20A, Harvard Commercial Building,
105-111 Thomson Road, Wanchai
Hong Kong
Tel.: +852 3113 6177
Fax: +852 3113 6199

DENTAL TRIBUNE AMERICA, LLC

116 West 23rd Street, Suite 500, New York,
NY 10001, USA
Tel.: +1 212 244 7181
Fax: +1 212 224 7185

© 2015, Dental Tribune International GmbH

DENTAL TRIBUNE

The World's Dental Newspaper - United Kingdom Edition

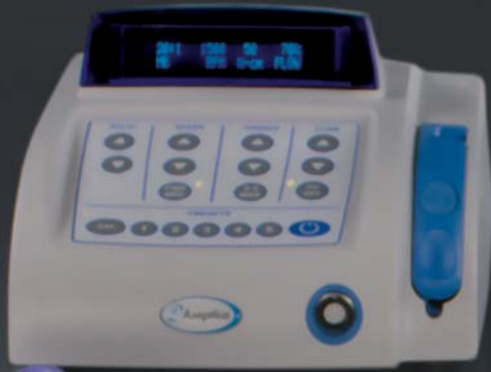All rights reserved. Dental Tribune makes every effort to report clinical information and manufacturer's product news accurately, but cannot assume responsibility for the validity of product claims, or for typographical errors. The publishers also do not assume responsibility for product names or claims, or statements made by advertisers. Opinions expressed by authors are their own and may not reflect those of Dental Tribune International.



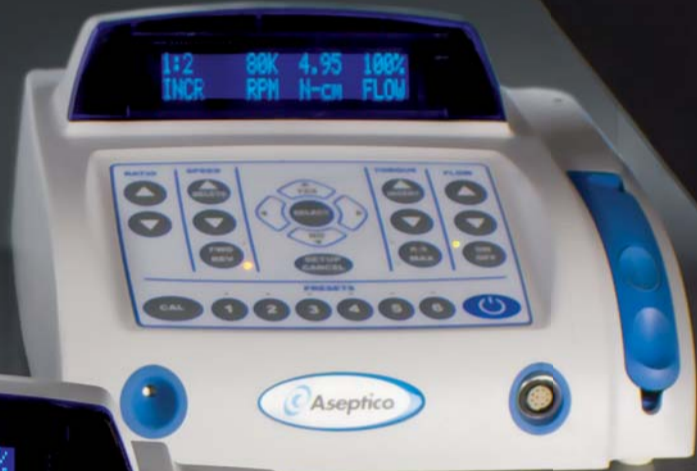Scan this code to subscribe our weekly *Dental Tribune Nordic* e-newsletter.

The **Right Tools** For The **Job**
Implant, Surgery & Endo Motors

AEU-6000
Up to 50Ncm



AEU-7000
Up to 80Ncm



AEU-7000L
Up to 80Ncm w/ LED



+1.425.487.3157 • www.aseptico.com • int@aseptico.com



See us at
EAO 2015
 Stand B1

Distributor and OEM
 Inquiries Welcome!

"If you are looking to purchase a high quality American-made motor, then you should consider Aseptico."

— Paresh Patel DDS



"Aseptico fulfilled my needs beyond my expectations. I am so pleased with my Aseptico AEU-7000 units that I recommend them to all my students at the Reconstructive Dentistry Institute as well as at my lectures at various dental societies and conferences."

— Ara Nazarian DDS

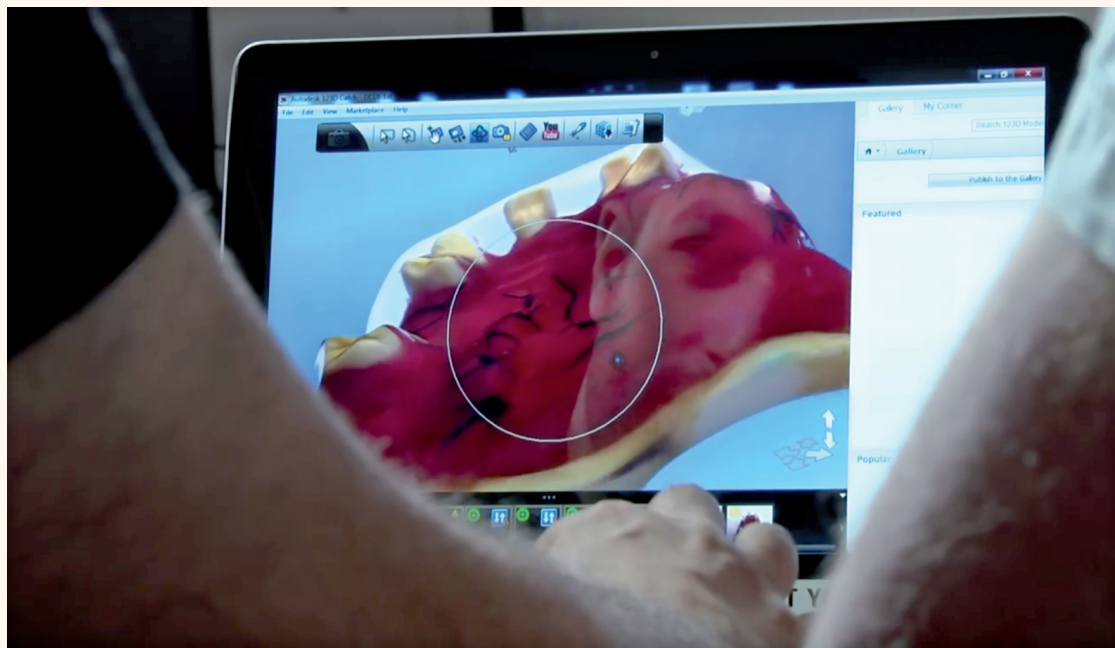


3-D holographic scanning device shortens denture-fitting process significantly

JERUSALEM, Israel: Students from the Hebrew University of Jerusalem and the Hadassah Medical Center have developed HoloDent, a holographic scanning device that promises to improve the process of fitting dentures significantly. According to the creators, the system not only shortens the fitting process from up to a month to 30 minutes, but also allows for more accurate prostheses than do conventional methods.

Generally, denture fitting involves a long and often painful adjustment process for the patient, including multiple clinic visits and several modifications until the soft and hard materials match the exact measurements of the mouth.

"The process of fitting dentures hasn't significantly changed in the last 100 years," said Dr Anat Sharon, Director of the Maxillofacial Prosthetics Clinic at Hadassah Medical Center. "It is such a long process that most dental clinics simply refuse to carry out the procedure."



The 3-D scanner produces a precise digital impression of the mouth and outputs it to a computer, reducing the time it takes to get dentures from 30 days to 30 minutes. (© Hebrew University of Jerusalem/Hadassah Medical Center; Screenshot/DTI)

Aiming to replace these outdated dental procedures, including the fabrication of dentures, Sharon and a group of engineering and business graduate students de-

veloped HoloDent as part of the Biodesign Israel programme.

The programme, which aims to bring medical innovation to the

market through multidisciplinary, team-based research, is a joint effort of the Hebrew University of Jerusalem and Hadassah Medical Center.

"HoloDent is the first holography scanning device for intraoral 3-D modeling, reducing the time it takes to get dentures from 30 days to 30 minutes, while making the treatment far more comfortable and precise for all patients," Amit Zilberstein, a Biodesign fellow and CEO of the HoloDent company, said.

The new 3-D device, which recently won an award at the Startup Open Israel competition, could also improve accessibility to accurate denture fitting for ageing populations in developing countries by providing access to a cost-effective digital solution, the creators hope.

HoloDent could benefit millions of dental patients worldwide by avoiding the pain and discomfort associated with conventional fitting methods, as well as greatly reducing the time required. According to the university's press release, the new device has a market of US\$500 million (€455 million) in the US alone.

Study finds varying disinfection protocols

MADRID, Spain: A team of researchers from the department of endodontics at Universidad Rey Juan

Carlos in Madrid has conducted a study to determine whether there are differences in the disinfection

protocols of endodontists and general dentists. The scientists found that endodontists are more likely to keep up to date with protocols published in the literature, whereas general dentists rely on protocols learnt during their dental training.

The study authors sent out an invitation to participate in an online survey to 950 dentists affiliated with the Spanish board of dentistry. The survey consisted of nine questions regarding irrigation protocols and other factors related to disinfection during root canal therapy. It was completed and submitted by 238 (25.05 per cent) of those invited, divided equally between general dentists and endodontists.

The researchers found no statistically significant differences in the respondents' first choice of an irrigant solution: sodium hypochlorite. However, they noted statistically significant differences in the protocols used by general dentists and by endodontists in relation to various factors. These factors included the concentration of sodium hypochlorite, the use and type of irrigant applied to remove the smear layer, the use of adjuncts to irrigation, the enlargement of the apical preparation when shaping a necrotic tooth, and the maintenance of apical patency throughout the debridement and shaping procedure.

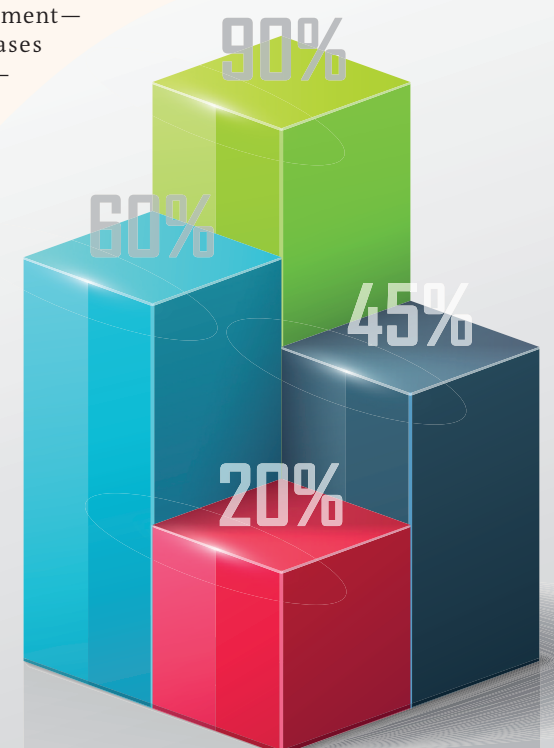
The study's findings showed that general dentists and endodontists

follow different and sometimes inadequate disinfection protocols. "The results of the survey demonstrated that endodontists keep up to date with protocols published in the literature, whereas general dentists use protocols learnt during their dental training. Both groups of clinicians should be aware of the importance of disinfection techniques and their relationship to treatment outcomes," the researchers stated.

They pointed out that controlling micro-organisms during root canal treatment—especially in cases with necrotic pulp—is essential to improve treatment outcomes.

"Clinicians should update their protocols and also consider referring patients to a specialist when their protocols are based on traditional techniques, especially in those cases with necrotic pulp," they concluded.

The study, titled "Differences in disinfection protocols for root canal treatments between general dentists and endodontists", was published in the July issue of the *Journal of the American Dental Association*.



Join the largest educational network in dentistry!

DT STUDY CLUB
COURSES | DISCUSSIONS | BLOGS | MENTORING

www.DTStudyClub.com

- education everywhere and anytime
- live and interactive webinars
- more than 500 archived courses
- a focused discussion forum
- free membership
- no travel costs
- no time away from the practice
- interaction with colleagues and experts across the globe
- a growing database of scientific articles and case reports
- ADA CERP-recognized credit administration

Register for
FREE!

Whitening without abrasion or chemical bleaching

Curaden introduces new Black is White toothpaste

Swiss company Curaden's new whitening toothpaste Black is White aims to whiten the teeth gently but effectively. Containing activated carbon, the toothpaste, which is a striking black colour, removes discoloration without abrasion or chemical bleaching. Whitening effects are further enhanced by blue-filter particles. Owing to this optical solution, the teeth appear whiter without having to use chemical bleaching agents. The toothpaste further contains 1,450 ppm fluoride and hydroxylapatite for remineralisation. Without sodium lauryl sulphate, triclosan or additional bleaching agents, Black is White can be used as a regular toothpaste on a daily basis.

Today, CURAPROX is represented in more than 60 countries worldwide. In 2013, the company ven-

tured into the Swedish market and began building up distribution channels. Its range of atraumatic

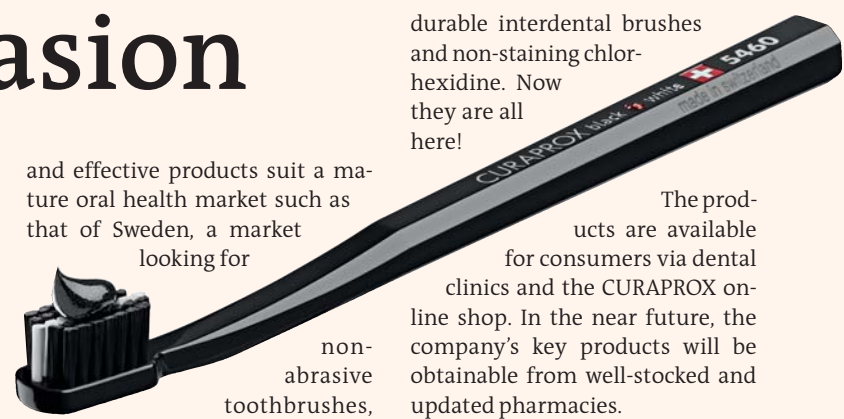and effective products suit a mature oral health market such as that of Sweden, a market looking for

non-abrasive toothbrushes,

durable interdental brushes and non-staining chlorhexidine. Now they are all here!

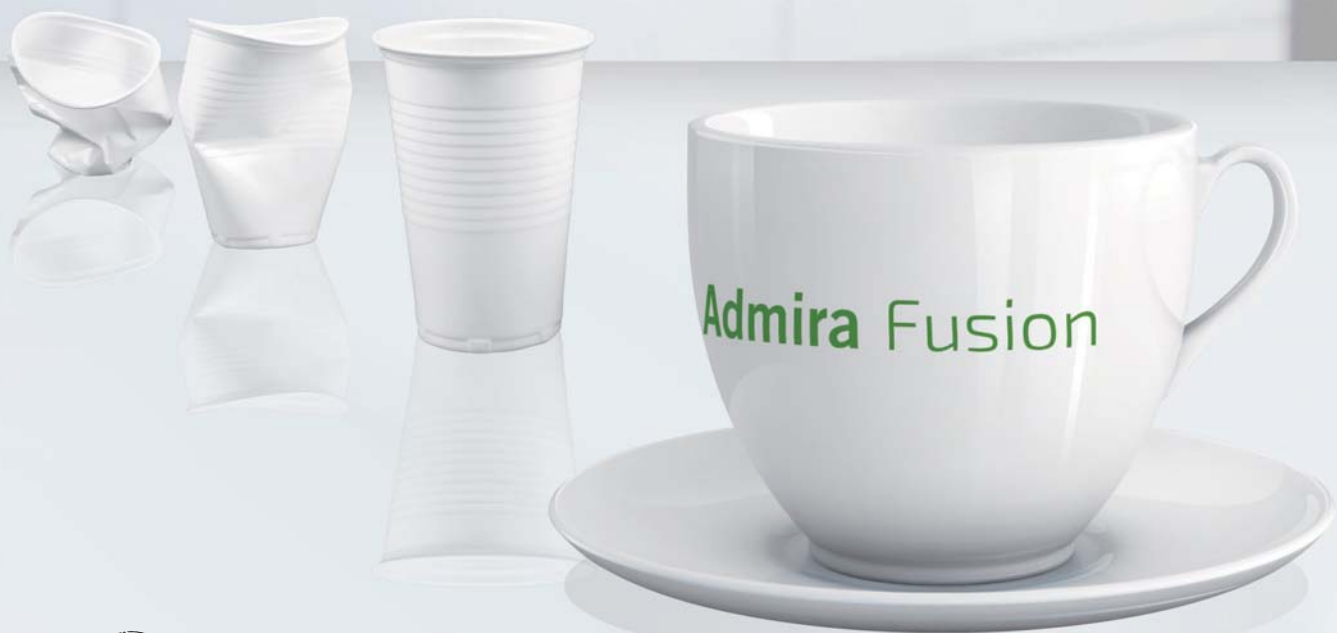The products are available for consumers via dental clinics and the CURAPROX online shop. In the near future, the company's key products will be obtainable from well-stocked and updated pharmacies.

AD



True evolution

Take advantage of current offers!*



Swiss-owned company Curaden is a pioneering expert in oral health and individual dental prophylaxis, based in Kriens near Lucerne. Its unique range of oral health products have been created and developed in Switzerland under the brand name CURAPROX since 1972. Together with dental professionals in teaching, research and practice, the company introduces products that serve one purpose only: to keep teeth healthy for a lifetime. The company's collaboration with Swiss dentists, dental hygienists and university specialists has produced a wealth of knowledge about cleaning techniques and dental care—and about products that combine true benefits with real comfort: atraumatic, effective and accepted.

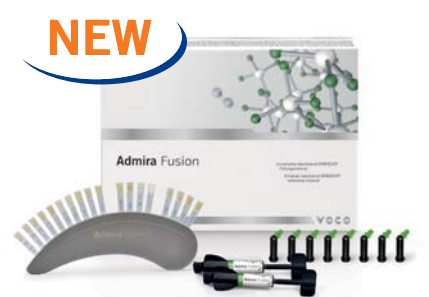CURAPROX's wide range of products for dental prophylaxis include its flagship product, the ultra-soft CS 5460 toothbrush with 5460 CUREN bristles, which are very effective against plaque and gentle on the gingiva. Other unique products are the long-life Prime interdental brush line with a non-breakable CURAL wire, and the non-staining chlorhexidine rinse CURASEPT ADS.

THE FIRST CERAMIC FOR DIRECT FILLINGS

- The worldwide first purely ceramic-based restorative material
- Lowest polymerisation shrinkage (1.25 % by volume) and particularly low level of shrinkage stress**
- Inert, so highly biocompatible and extremely resistant to discolouration
- Meeting highest demands in anterior and posterior regions
- Excellent handling, simple high-lustre polishing procedure coupled with high surface hardness guarantee first-class long-term results
- Compatible with all conventional bonding agents

* Find all current offers on www.voco.com or contact your local VOCO dental consultant
** in comparison to all conventional restorative composites

Admira Fusion



Please visit us!
Norges Varemesse, Lillestrøm
29th-31st October 2015
Stand: B04-39

“I want to reach out to the everyday dentist”

An interview with Dr Jens Lætgaard, founder of digital training platform Klinikproduktion.dk

Having performed live surgeries at seminars and trade shows for more than ten years, Danish dentist Jens Lætgaard is an expert when it comes to explaining dental procedures comprehensibly. With his new website, Klinikproduktion, the surgeon, who also runs a private practice in Roskilde in Denmark, aims to enhance daily procedures at dental clinics. *Dental Tribune*

with Klinikproduktion. We record everything with six high-definition cameras to provide more than just one angle. In addition, our videos are targeted at the whole team, so the assistants and everyone involved will benefit from watching.

Your surgery cage at SCANDEFA in April attracted quite a lot of attention.

can get very close and is able to see all the details through the glass and, of course, on the big screens. A larger cage would just move the audience further away.

What do you do when something unexpected happens on stage?

Continue! One has to stay calm and importantly one has to be honest and demonstrate how to resolve issues that arise. During a surgical treatment at my last show, I broke two burs in the bone and they were stuck. This had never happened to me before, and I had to get them

opportunity for teaching. I would rather demonstrate treatment of a case that is going wrong or unexpectedly and how to save it.

How common are live surgeries in general?

I think they are not very common. Live surgery requires substantial set-up, many sponsors or collaborators who are sold on the idea and patients from the local area. However, as already mentioned, it gains a great deal of attention, which is attractive for most companies.

the procedure itself makes one nervous, one should not perform live on a stage. Personally, I have always enjoyed teaching, but I have not had any education on how to perform live. Even if I had, there would always be situations for which I could not control or plan.

What are the limitations in live surgery in terms of time and procedures performed?

When we first started, we had an elderly female patient who needed four implants, which were to be immediately loaded, and we planned that the procedure would last for 2.5 hours. We thought it was extremely exciting, but there were only about 150 people in the room. When we performed third molar extractions 2 hours later, we had 300 people in the room. The point is that when one performs fairly short procedures, one can keep the minds of the audience busy. A long procedure, however, can be problematic. Maybe 45 minutes, including preparation and cleaning, is a good time frame.

That is the reason I chose third molar extractions, root resections and simple implant treatments for my live shows. And that is also what I intend to demonstrate with Klinikproduktion: everyday life in a dental clinic.

Could you explain that further?

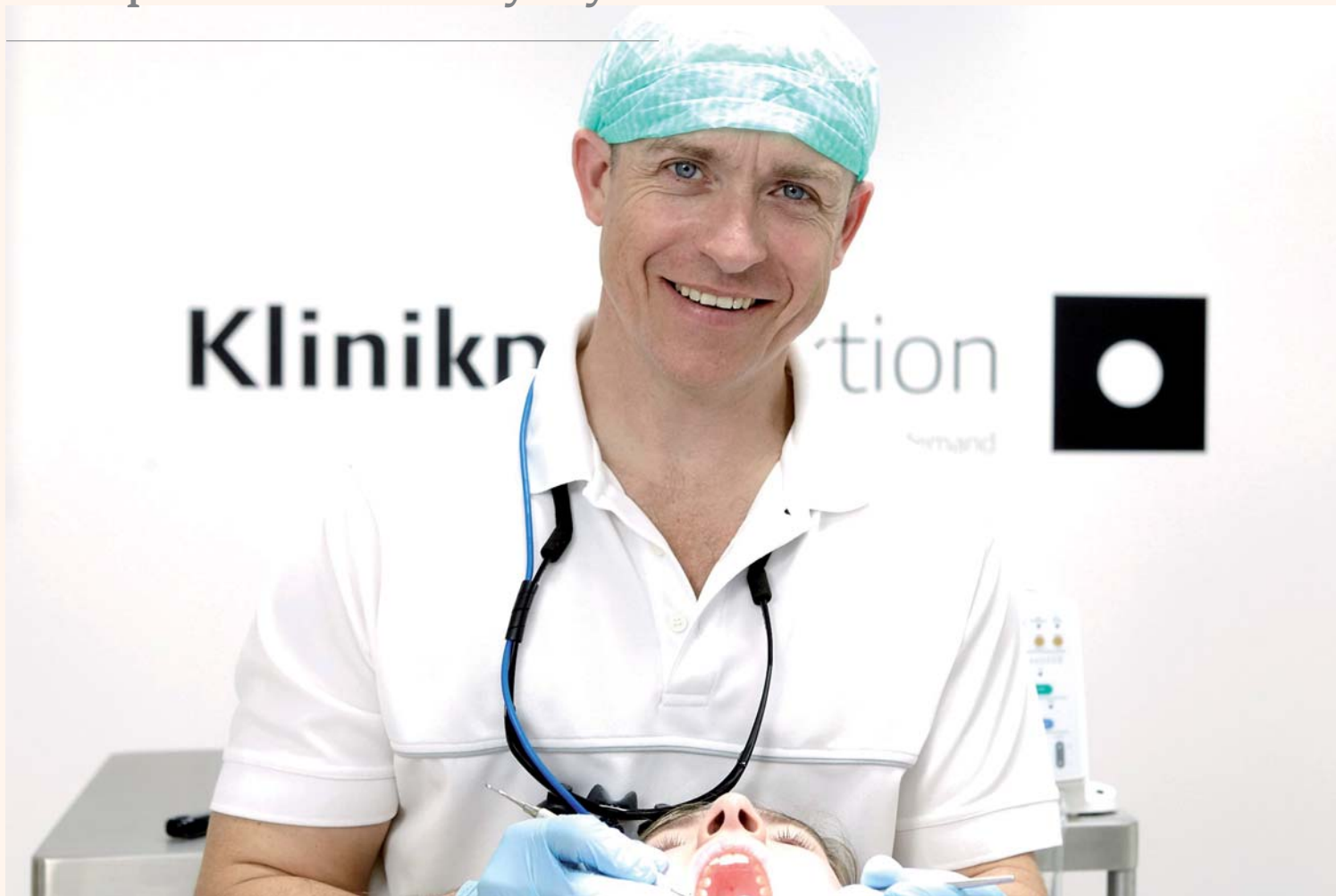My goal is to keep to the simple treatments that make up daily practice. There are some good-quality videos available, but they are mostly targeted at specialists wishing to advance their skills even further. I want to reach out to the everyday dentist and teach him or her and his or her team how to improve their work. Third molar extractions, for example, are what clinics perform on a daily basis. In quite a simple manner, I can teach practitioners how to carry out the whole procedure in a better and safer way.

But if it is such a common procedure, what is there for practitioners still to learn?

We have patients in the clinic every week who have been referred because their dentist had struggled to remove a third molar for hours, but had not succeeded. A specialist would probably have needed 10–15 minutes to remove it. This expertise does not necessarily apply to a general practitioner who does not perform surgical interventions every day. Still, many patients expect their own dentist to be able to perform this procedure.

Do you think videos could be a valuable educational tool for dentists?

“My aim is not to demonstrate the perfect scenario anyway.”



Klinikproduktion's founder Dr Jens Lætgaard.

Nordic Edition spoke with the Dane about his elaborately produced treatment videos and why he thinks video training is the educational tool of the future.

Dental Tribune Nordic Edition: Your company Klinikproduktion produces video courses and carries out surgeries at trade shows. What is most important when it comes to live treatment?

Dr Jens Lætgaard: Many websites that offer live surgery videos in dentistry focus on the mouth only and the videos are often recorded with a single camera. As a viewer, one thus misses out on all the other details around the chair, for example what instruments are lying behind the surgeon or how the assistant holds the suction. This is what we are trying to change

What are the professional benefits of such demonstrations?

An advantage of live surgeries is that often the whole team attends exhibitions. Dentists, hygienists and assistants can come and go as they like. They can watch and discuss what they have seen—directly on-site or afterwards—with no obligations. For the audience, it is always exciting to watch live performances because they can see exactly what happens.

Is not it challenging to operate in such a small space with a whole team?

I have been performing live surgeries for many years now, so no, not really. Normally, when one sees live surgeries they are at a relative distance. With our set-up—only 3 × 3 square metres—the audience

out. Such scenarios are beneficial to the audience. If the bone, instruments or patient do not act in the manner expected, one has to continue and show the audience how to handle the situation. My aim is not to demonstrate the perfect scenario anyway.

Have you ever had to suspend a live treatment because of unexpected complications?

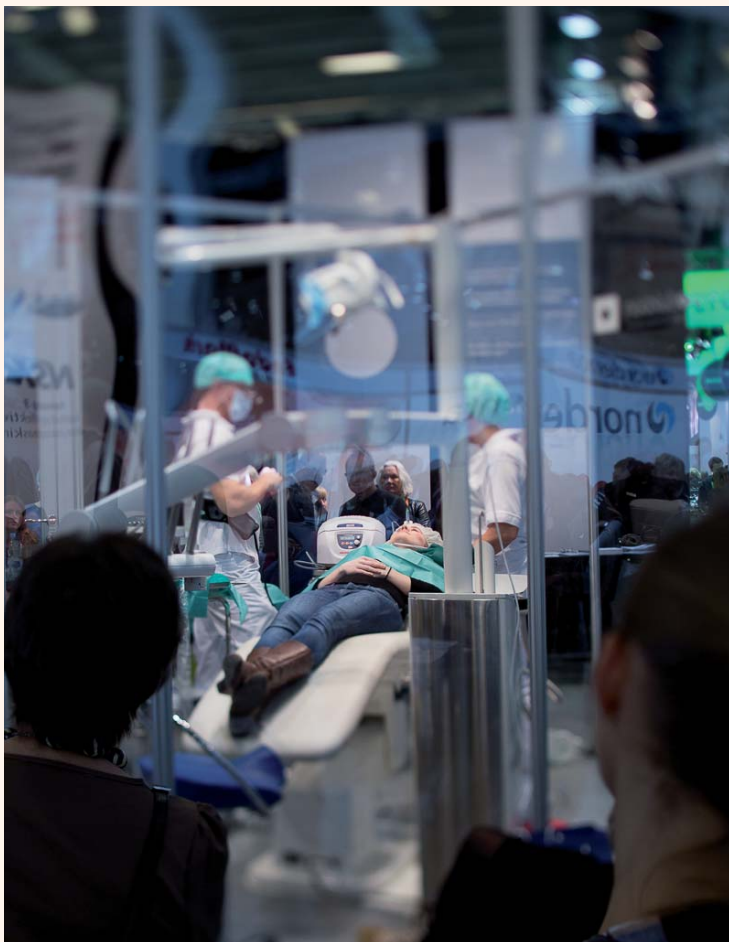I have never had a moment in live surgery in which we did not manage to resolve any problems. I demonstrate procedures I do every day, which means I am fairly confident about them. But that is no guarantee, of course. I once did a sinus lift during which the Schneiderian membrane was accidentally perforated. Well, that is a rare occurrence, but it offers a far better

Where do you find your patients?

I recruit them from my usual patients. I offer them a discount for the inconvenience of having to show up in a different place and to compensate for there being an audience. One has to be careful of whom one chooses to participate. A very nervous patient would not be a good choice. One has to inform the patient thoroughly about the agenda, which means discussing potential complications, such as nerve injuries and extensive bleeding.

Steady nerves appear to be a requirement for both the patient and the operator performing live.

One has to have a certain natural ability to handle a live situation. If the thought of a surgery in front of an audience leaves one shaking or



Lætgaard and his team performing live surgeries at SCANDEFA 2015 in Copenhagen. (Photos: Kristin Hübner and Robert Strehler)

AD

Yes, indeed! Being able to replay a video is a great advantage, and the whole team can watch it together or individually. That is also the feedback I have received from our users. They appreciate the opportunity to watch 5 minutes of a 20-minute video, as well as being able to re-watch it however many times they wish.

The ability to replay in video training is an outstanding feature compared with live surgeries. One can always go home and repeat the part one wishes to watch again, such as reviewing the incision and the filling. As a dentist, one can also ask one's assistants to watch a video in preparation for a surgery. For example, if one is performing an implant treatment for the first time, one could ask one's staff to watch three videos of 5 minutes each at home to prepare for the procedure.

Is this the way people actually use the videos?

When we started Klinikproduktion a year ago, it was natural for me to think that this is the way people should use them, but then I spoke to a dentist and asked him whether he had seen the videos. He told me that he had not. I explained to him how he could use them in many ways, for example as an internal education tool in team meetings. Surprisingly, the dentist I spoke to had not thought of this option at all. So, my job will probably also include teaching our users how to use the videos in daily practice.

Are there other projects you hope to venture into?

Interactive live streaming is something we have wanted to do for some time now. The audience would be able to ask questions during the procedures. I think it is quite important to enter into dialogue and discuss scenarios. As a surgeon,

one will always be in a position in which somebody disagrees with one and wants to ask a critical question. Personally, I think critical questions are more fun to answer, because then a discussion emerges in which I have to explain why I am doing something a certain way.

Criticism is good. I once had a live surgery during which an audience member asked me why I did not do something differently and his suggestion was a fantastic idea I had never even thought about. I said, "Thank you, I will definitely do that in the future". It is exactly this sort of interaction that I like best. That is where we all learn.

Are Klinikproduktion's videos approved for professional dental training?

Right now, there is a test after every video. This means that the users can earn continuing education credits after watching the videos and taking the tests. The requirements for further training in Denmark are fairly poor. There are no stipulations, but the dental association recommends that their members participate in 25 hours of continuing education every year. However, so far, the association is not prepared to assume responsibility and there are no requirements for dentists.

In fact, I recently suggested at the Danish Dental Association's annual meeting making 25 hours of yearly continuing education a requirement. Well, they did not vote for my suggestion. It is a little absurd. Why be afraid of losing association members? If the members are not willing to do further education, they should not be in the association in the first place.

Thank you very much for the interview.

The Dental Tribune International C.E. Magazines



www.dental-tribune.com



I would like to subscribe to

- CAD/CAM
- cone beam
- cosmetic dentistry*
- DT Study Club (France)**
- gums*
- implants
- laser
- ortho
- prevention*
- roots

€44/magazine (4 issues/year; incl. shipping and VAT for customers in Germany) and €46/magazine (4 issues/year; incl. shipping for customers outside Germany).** Your subscription will be renewed automatically every year until a written cancellation is sent to Dental Tribune International GmbH, Holbeinstr. 29, 04229 Leipzig, Germany, six weeks prior to the renewal date.

4 issues per year | * 2 issues per year
 *** €56/magazine (4 issues/year; incl. shipping and VAT)

** Prices for 2 issues/year are €22 and €23 respectively per year.

Shipping address _____

City _____ Country _____

Phone _____ Fax _____

Signature _____ Date _____

PayPal | subscriptions@dental-tribune.com Credit Card

Credit Card Number _____ Expiration Date _____ Security Code _____

↑ SUBSCRIBE NOW!

fax: +49 341 48474 173 | e-mail: subscriptions@dental-tribune.com

Achieving lifelike aesthetics

Replacing existing Class IV restorations using only two composite shades

By Dr Frank J. Milnar, USA

Recognising the unique biological architecture of the natural tooth, dentists today practise conservative procedures and minimally invasive techniques in order to preserve the maximum amount of healthy structure when restoring dentition to proper form and function.¹ This can prove challenging when combined with patient expectations for an aesthetically pleasing smile and the predilection towards bio-modification and biomimetics in modern dentistry.²⁻⁴ Additionally, visual ergonomics is of optimal importance when restoring the anterior segment of patients presenting with Class IV fractures that have been previously restored.⁵

In the past, recreating the unique characteristics of natural dentition could be difficult and confusing. Manufacturers released multiple composite shades, opacities and translucencies, all of which were required to reconstruct individualised teeth. Therefore, the direct composite placement technique became overwhelming and time-consuming.

Fortunately, dental material manufacturers have helped to improve and

enhance dental treatments by developing direct composites that simplify the layering process. Today's biomimetic direct composite materials reduce the number of composite shades required to recreate aesthetic restorations and simplify and enhance predictability. These new composites address demands for minimally invasive treatment while providing increased strength and optical characteristics, universal application, improved adhesion, and optimal handling and sculptability when reconstructing the biological, aesthetic and physical architecture of natural teeth.⁶

Among the new alternatives available is a nano-hybrid indicated for Class I-V restorations. GrandioSO (VOCO) is a newly developed universal nano-hybrid restorative that displays greater wear resistance, enhanced shade stability, long-lasting polish retention, flexural strength similar to that of natural dentition, and low shrinkage. GrandioSO is unique owing to its construction, which includes 30-50% less resin compared with other micro-hybrid resin-based restoratives.⁷ GrandioSO contains

very small designer nano-particles made from silica dioxide filler particles grown to 20-40 nm, then covered with a special coating.⁷ Glass-ceramic fillers with an average particle size of 1 µm combined with the designer nano-particles create a nano-hybrid composite that outperforms conventional composites, which have limited use.⁸

The rate of polymerisation shrinkage in the newest modern-generation composites reaches 2-2.5% when curing.⁹ However, the low resin content of GrandioSO decreases shrinkage to 1.6%, reducing stress and, as a result, eliminating the undesirable white line that often appears with resin-based composites during the finishing process.⁸ The unusually high surface hardness found with GrandioSO results from the increase in filler load. Conventional composite filler weights range from 70 to 77%, compared with GrandioSO's 89%.⁷ Owing to its unusually high surface hardness (210.9 MHV), GrandioSO is the closest composite to natural enamel (350-450 MHV).⁸ It maintains its strength, is highly polishable, and demonstrates long-term abrasion

and wear resistance.¹⁰ In addition, the composite retains surface smoothness and a permanently polished sheen.

Although emulating natural tooth structure, shape and shade while blending with surrounding dentition still requires careful composite selection and artful procedures during the placement protocol, the availability of new nano-hybrid composites such as GrandioSO enables simplified techniques.

Clinical case

This following clinical case describes how GrandioSO was used to re-restore the maxillary anterior teeth of a 48-year-old female patient. Old and discoloured Class IV composite restorations on teeth #11 and 21 were removed, and the patient's smile rejuvenated using the GrandioSO composite and a predictable two-shade composite layering technique.

The patient presented with 15-year-old composite restorations on her

anterior maxillary teeth (Figs. 1 & 2). She was not interested in porcelain veneers or unnecessary removal of tooth structure. She requested only reversible and repairable restorations.

Before the pre-existing composite restorations were removed, the patient's occlusion was analysed. A comprehensive intra-oral examination was performed that included an oral history, radiographs and photographs. The patient was in good health, and nothing contra-indicated direct composite re-restoration of teeth #11 and 21.

Morphological, histological and optical characteristics of the teeth were examined. In order to select the appropriate composite shade for replacing the old restorations, GrandioSO in Shades A1 and A2 were previewed side by side on teeth #11 and 21. This enabled the dentist to select the appropriate shades for

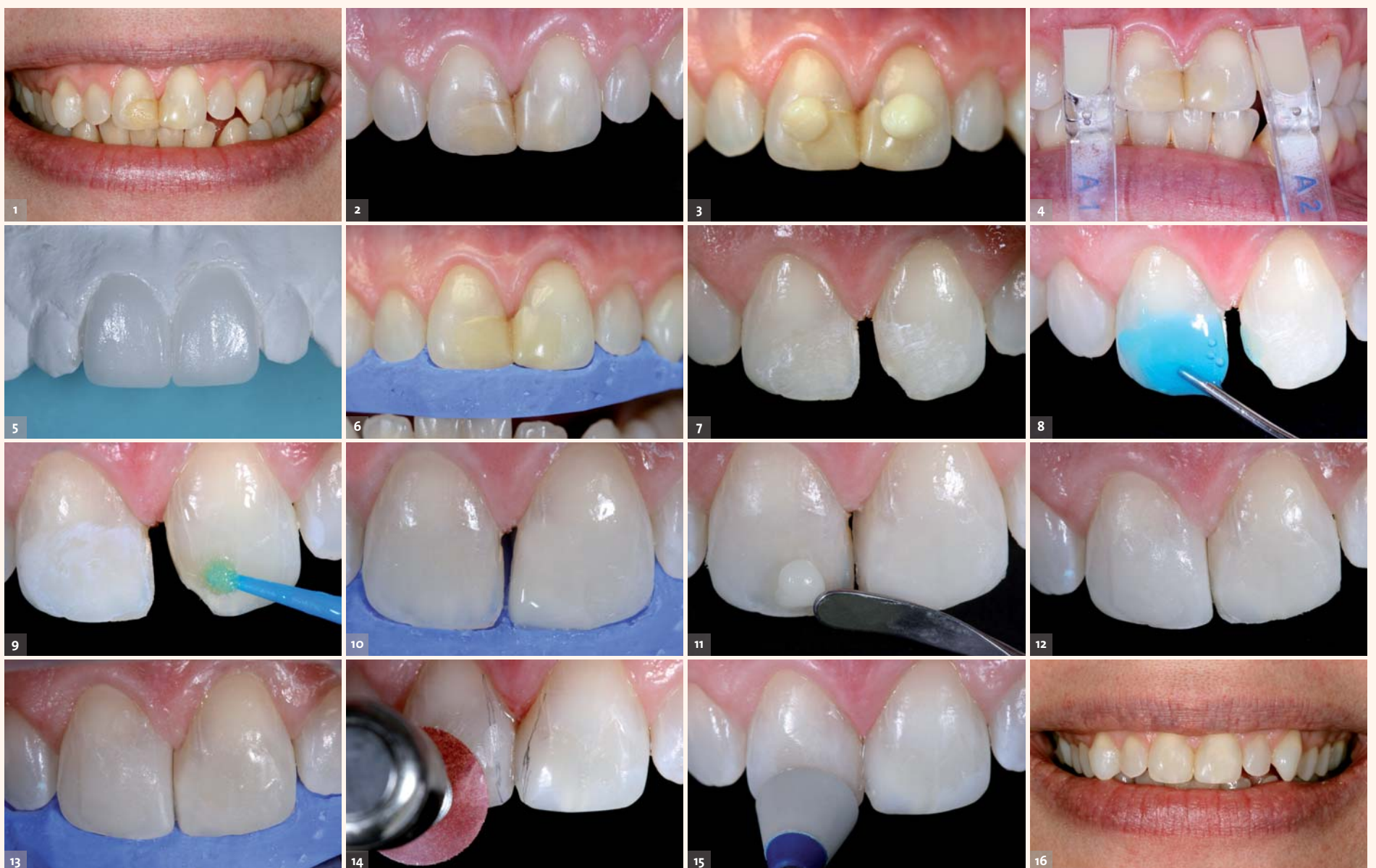
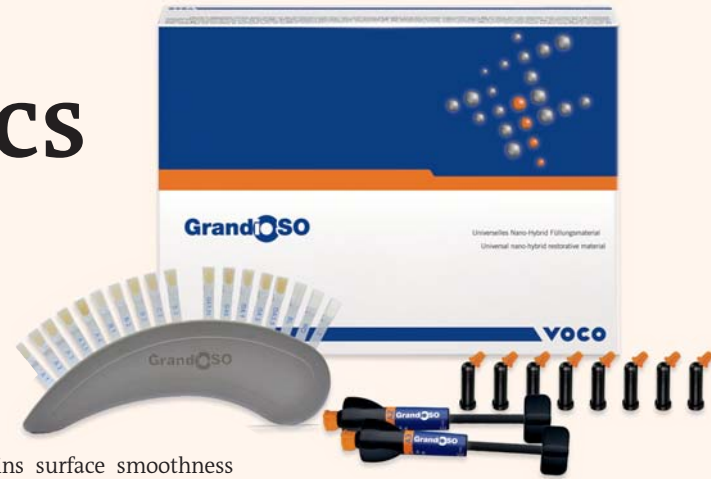
Fig. 1: Pre-op view of the patient's natural smile.—Fig. 2: Close-up pre-op view of teeth #11 and 21.—Fig. 3: Two shades of composite were previewed.—Fig. 4: Shades A1 and A2 would be used.—Fig. 5: An enhanced wax-up model demonstrated the anticipated treatment outcomes.—Fig. 6: The stent would be used to help maintain the facial-lingual line angles.—Fig. 7: View of the final bevel preparation.—Fig. 8: The teeth were etched using 35% orthophosphoric acid etch.—Fig. 9: A dual-curing, self-etching dentine-enamel bonding agent (Futurabond DC) was applied to the preparations using a brush.—Fig. 10: GrandioSO Shade A2 was placed to create the lingual enamel layer of tooth #21.—Fig. 11: In order to re-restore tooth #11, GrandioSO composite in Shade A2 was placed, sculpted and cured for 10 s.—Fig. 12: View of teeth #11 and 21 immediately after final placement of the composite material.—Fig. 13: The putty stent was again placed intra-orally to verify the length and width of the restorations.—Fig. 14: A 3M disc was used to impart the mesial transitional line angle.—Fig. 15: A Dimanto polishing cup was used.—Fig. 16: Post-op view of the nano-hybrid restorations on teeth #11 and 21; note the lifelike aesthetics, translucency and shade characteristics created with only two composite shades.

the case (Figs. 3 & 4), with Shade A2 being the lingual enamel layer and Shade A1 the final composite layer.

Before the original composite restorations were removed, a diagnostically enhanced model was created from preoperative impressions (Fig. 5). This model also would be used for fabricating a high-viscosity putty stent (Registrado X-tra, VOCO) that, when placed intra-orally, would provide a spatial reference and volumetric guide for composite placement (Fig. 6). This stent also would help maintain the facial-lingual line angles.¹¹

The old restorations were removed, and teeth #11 and 21 were prepared using diamond burs. In addition, a 2.5 mm infinite facial bevel was created (Fig. 7). Combined, this preparation design supported the fracture resistance and durability needed for the restorations and facilitated imperceptible restorative margins.¹²

The Class IV preparations were then verified incisally, after which the teeth were pumiced, rinsed and dried. Although manufacturers have developed newer generations of self-etching adhesives that demonstrate predictable long-term bonding and marginal integrity, selective enamel etching is still advocated in the literature in order to ensure excellent clinical results.¹³⁻¹⁶ Thus, the preparations were etched with 35% orthophosphoric acid (Vococid, VOCO) for 15 seconds, rinsed and dried (Fig. 8). A single-dose bonding agent (Futurabond DC, VOCO) was then applied to the preparations using a brush for 20 seconds (Fig. 9). The selected bonding agent eliminated evaporation, would not spill, and required fewer steps, thereby helping to reduce technique sensitivity. The bonding agent was air thinned with high pressure and light cured for 10 seconds per tooth.

The putty stent was placed intra-orally and GrandioSO composite in Shade A2 was applied in a 1.5 mm thick increment to form the lingual enamel layer and block any show-through on tooth #21 (Fig. 10). This layer was cured for 10 seconds (note that darker shades require 20 seconds). In order to assess this lingual enamel layer, the putty stent was removed. In order to simulate higher value and lower chroma in the middle and incisal thirds of the maxillary central incisor, the putty stent was again placed intra-orally, and Shade A1 was placed, sculpted and cured for 10 seconds. The re-restoration of tooth #11 was performed analogously (Fig. 11-13).

The restorations were then finished using a series of discs (Fig. 14) and contour, shape and shine cups and points.¹⁷ These helped to ensure that the restorations demonstrated a similar harmony and balance with the adjacent teeth, as well as with each other. These finishing steps also imparted realism by better defining line angles (e.g. mesial transitional line angle). In order to create a natural-looking final lustre, a one-step polishing system (Dimanto, VOCO) particularly well suited to the high surface hardness of new composite materials was used (Fig. 15).

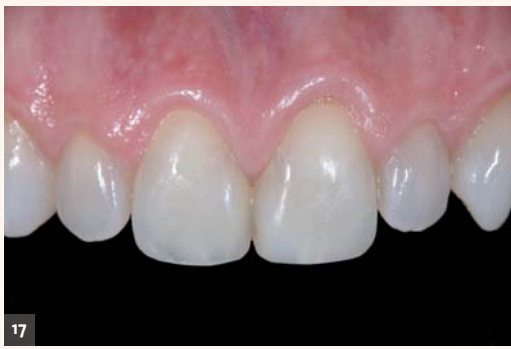


Fig. 17: Post-op close-up view of the completed two-shade composite restorations on teeth #11 and 21.

Conclusion

The case presented here has demonstrated the manner in which only two shades of a direct composite resin were used to produce imperceptible Class IV restorations

(Fig. 16 & 17). With the development of new-generation composites, the ability to recreate restorations with two composite shades, as opposed to three or more, while reproducing durable and aesthetically pleasing characteristics contributes to our goal to provide less technique-sensitive treatment in biomimetic, conservative and effective ways.

Editorial note: A list of references is available from the publisher.



Dr. Frank J. Milnar is co-founder of the Minnesota Academy of Cosmetic Dentistry and maintains a private practice in St Paul in Minnesota in the US. He can be contacted at Frank@milnardds.com.

AD



Tribune CME

1 Year Clinical Masters™ Program in Aesthetic and Restorative Dentistry

12 days of intensive live training with the Masters in **Athens** (GR) and **Geneva** (CH)

Three sessions with live patient treatment, hands-on practice, plus online training under the Masters' supervision.

Learn from the Masters of Aesthetic and Restorative Dentistry:



Dr. Ed McLaren



Dr. Panos Bazos



Dr. Mauro Fradeani



Dr. Stavros Pelekanos



Dr. Didier Dietschi



Dr. Gianfranco Politano

Registration information:

12 days of live training with the Masters in **Athens** (GR), **Geneva** (CH) + self study

Curriculum fee: €9,900

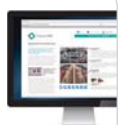(Based on your schedule, you can register for this program one session at a time.)

Details on www.TribuneCME.com

contact us at tel.: +49-341-484-74134

email: request@tribunecme.com

Collaborate
on your cases
and access hours of
premium video training
and live webinars



University
of the Pacific
you will receive
a certificate from the
University of the Pacific



100 C.E.
CREDITS



ADA CERP®
Continuing Education Recognition Program

ADA CERP®
Continuing Education Recognition Program

Tribune Group GmbH is the ADA CERP provider. ADA CERP is a service of the American Dental Association to assist dental professionals in identifying quality providers of continuing dental education. ADA CERP does not approve or endorse individual courses or instructors, nor does it imply acceptance of credit hours by boards of dentistry.



Tribune Group GmbH is designated as an Approved PACE Program Provider by the Academy of General Dentistry. The formal continuing dental education programs of this program provider are accepted by AGD for Fellowship, Mastership, and membership maintenance credit. Approval does not imply acceptance by a state or provincial board of dentistry or AGD endorsement.