

implants

international magazine of oral implantology



research

Dental-dedicated MRI—a new imaging technique in implantology?

case report

Periosteum as a regenerative tool in alveolar bone augmentation

events

World's leading congress EuroPerio11





DIRECTO

HEALING HAS A NEW DEFINITION

Designed for PBM Laser Therapy

Prevents infections

Speeds up recovery

VISIT US
MEDENCY.COM



Dr Georg Bach

President of the DGZI



Defining the future of implantology

Dear colleagues!

As we embark on another exciting year in the field of oral implantology, we are thrilled to present this latest issue of *implants—international magazine of oral implantology*. This edition reflects the dynamic evolution of our specialty, showcasing groundbreaking research, clinical advancements, and the continued pursuit of excellence that defines modern implantology.

One of the most promising developments in dental imaging is the introduction of dental-dedicated MRI (ddMRI). This revolutionary technology eliminates ionising radiation while providing unprecedented insights into soft-tissue diagnostics. As detailed in this issue, the implications for pre-implant assessment, oral surgery, and comprehensive treatment planning are vast. With ongoing research at esteemed institutions, ddMRI is poised to redefine diagnostic standards in implantology.

Beyond imaging, regenerative techniques continue to shape our field. The use of periosteum as a regenerative tool in alveolar bone augmentation exemplifies how innovation is improving clinical outcomes. This novel technique, detailed in our case report, highlights the potential of biological scaffolds in enhancing bone regeneration and optimising implant success.

The connection between periodontitis and systemic health is another critical topic we explore. The growing body of evidence linking periodontal disease to conditions such as cardiovascular disease, diabetes, and even neurodegenerative disorders underscores the importance of comprehensive oral health care. Understanding these connections allows us to adopt a more holistic approach

to implant therapy, ensuring not only successful osseointegration but also overall patient well-being.


The global implantology community thrives on collaboration and knowledge exchange, and 2025 is set to be a landmark year for scientific gatherings. Events such as EuroPerio11 and the 3rd European Congress for Ceramic Implant Dentistry offer unparalleled opportunities for learning, networking, and sharing best practices. Additionally, the International Dental Show (IDS) 2025 will once again serve as a hub for industry advancements, bringing together professionals from around the world to explore the latest innovations.

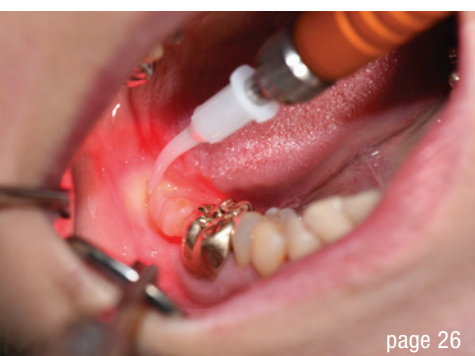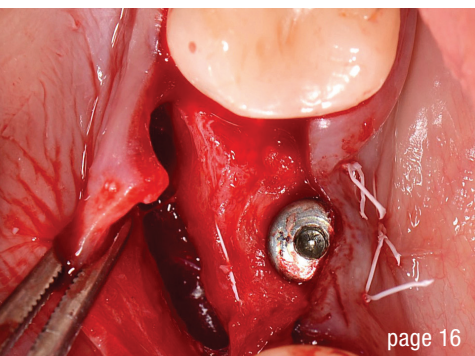
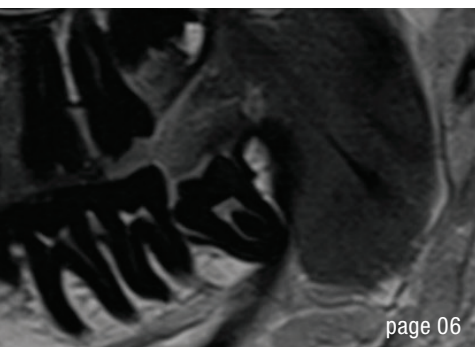
At the core of our profession is the commitment to patient-centered care, evidence-based practice, and continuous learning. Through this magazine, we aim to provide you with valuable insights, clinical pearls, and the latest research to support your daily practice and inspire your professional growth.

Enjoy reading this issue and let us continue shaping the future of implantology together!

Sincerely,

Dr Georg Bach
President of the German Association
of Dental Implantology





Cover image courtesy of MEDENCY SRL
www.medency.com



editorial

- Defining the future of implantology 03
Dr Georg Bach

research

- Dental-dedicated MRI—a new imaging technique in implantology? 06
Dr Georg Bach & Markus Bach
- Impact of periodontitis on systemic health and on implants—Part 2 12
Profs Curd Bollen, Paul Tipton & Gagik Hakobyan

case report

- Novel technique using periosteum as a regenerative tool in alveolar bone augmentation 16
Drs Cosmin Dima & Iulia Florea

interview

- 30 years of laser dentistry 26
An interview with Dr Frank Liebaug

events

- The global dental industry gathers in Cologne International Dental Show (IDS) 2025 30
- Focus on science and practice 32
3rd European Congress for Ceramic Implantology
- World's leading congress in periodontology and implant dentistry 34
EuroPerio11
- Shaping the future of ceramic implantology 36
4th Annual Congress of EACim

news

- news 37
- manufacturer news 40

about the publisher

- imprint 42

CONELOG®
PROGRESSIVE-LINE
conical performance ^[1,2]
at bone level

Precise conical connection

- Long conus for reduced micromovements
- Superior positional stability in comparison to other conical systems [1, 2]
- Integrated platform switching supporting the preservation of crestal bone



www.biohorizonscamlog.com/conelog



[1] Semper-Hogg, W, Kraft, S, Stiller, S et al. Analytical and experimental position stability of the abutment in different dental implant systems with a conical implant-abutment connection Clin Oral Invest (2013) 17: 1017.
[2] Semper Hogg W, Zulauf K, Mehrhof J, Nelson K. The influence of torque tightening on the position stability of the abutment in conical implant-abutment connections. Int J Prosthodont 2015;28:538-41.

CONELOG® is a registered trademark of CAMLOG Biotechnologies GmbH. It may however not be registered in all markets.

Dental-dedicated MRI—a new imaging technique in implantology?

Dr Georg Bach & Markus Bach, Germany

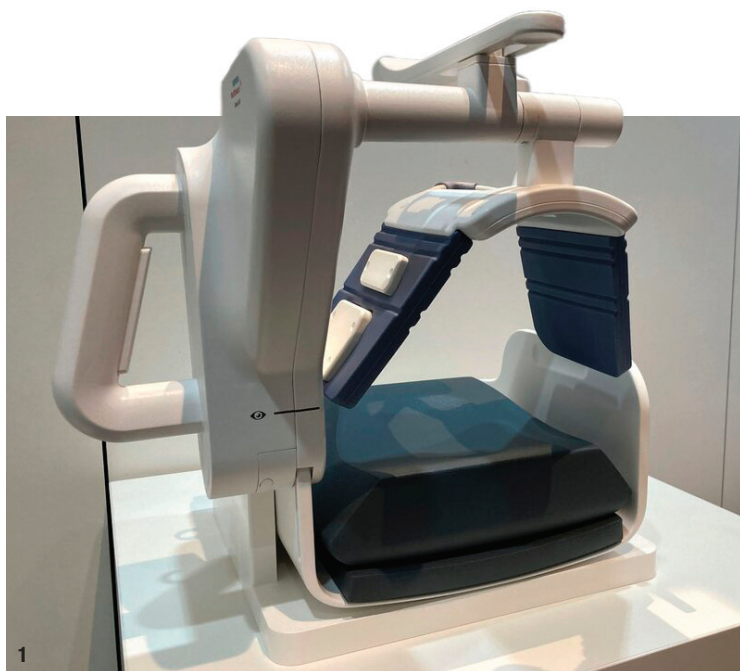

Fig. 1: Flexible coil of the ddMRI device.

At the 2024 European Congress of DentoMaxilloFacial Radiology in Freiburg in Germany, Dentsply Sirona and Siemens Healthineers unveiled the first MRI system specifically designed for dental applications—or dental-dedicated MRI (ddMRI), marking a significant breakthrough in dental imaging. Two key advantages of the MAGNETOM Free.Max Dental Edition MRI unit were highlighted: its complete elimination of ionising radiation and the unprecedented possibilities it provides in dentistry. Notably, it enhances soft-tissue diagnostics, offering unparalleled insights and precision. This article examines the development, advantages, limitations and clinical applications of dental MRI, giving particular focus to its role in pre-implant diagnostics, oral surgery and other dental specialties. It also discusses the technological advancements that have made MRI a viable imaging modality in dentistry and its potential impact on future clinical practice.

Although, the debut of the first dental MRI system was a landmark moment, it was the result of nearly two de-

acades of dedicated research. By early 2023, the development process had advanced significantly, providing the first promising indications that the technology could be presented to the public. This progress culminated in a symposium in the spring of 2023, attended by approximately 50 experts, primarily from academic institutions, who gathered to review and discuss the preliminary findings.

The initial results were so compelling that both the companies involved and the panel of experts agreed to collaborate on the scientific integration of MRI in dentistry. As part of this initiative, Siemens Healthineers provided a modified version of its current low-field MRI system, MAGNETOM Free.Max, which was installed at Aarhus University in Denmark. Under the leadership of Prof. Rubens Spin-Neto from the Section for Oral Radiology and Endodontics at the Department of Dentistry and Oral Health, extensive research efforts were launched to both enhance hardware components, such as the receiving coil, and develop workflows specifically tailored for dental applications with the clear objective of establishing MRI as a viable and integral tool in dentistry.

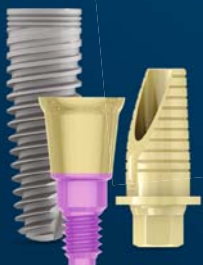

“Achieving truly practice-friendly device dimensions remains a challenge.”

Current status

The collaborative research efforts have yielded remarkable success. In just one year, MAGNETOM Free.Max Dental Edition was introduced. The ddMRI system differs significantly from conventional medical MRI machines. While standard MRI systems operate at field strengths of 1.5 or 3.0 T, the ddMRI utilises a reduced field strength of 0.55 T. This reduction has been achieved primarily through advanced software-based innovations in signal processing, incorporating AI-driven algorithms to enhance image quality and accelerate data acquisition.



ONE
ABUTMENT,
ONE TIME



MIS[®]
CONNECT

TISSUE-LEVEL SCREW-RETAINED SYSTEM
MAKE IT SIMPLE

The MIS CONNECT is a stay-in abutment placed immediately after implant insertion and remains in place throughout the restoration process. Its design allows the prosthetic procedure and restoration to be performed away from the bone and within the soft tissue. Learn more about MIS at: www.mis-implants.com

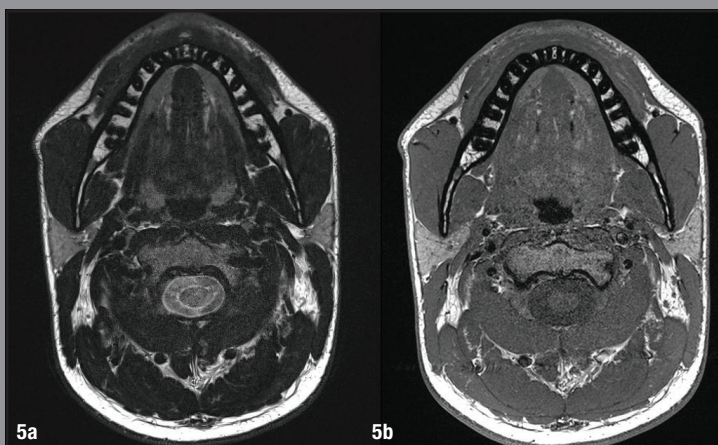
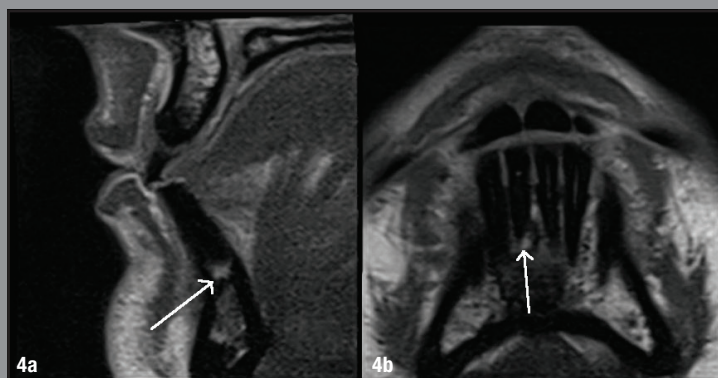
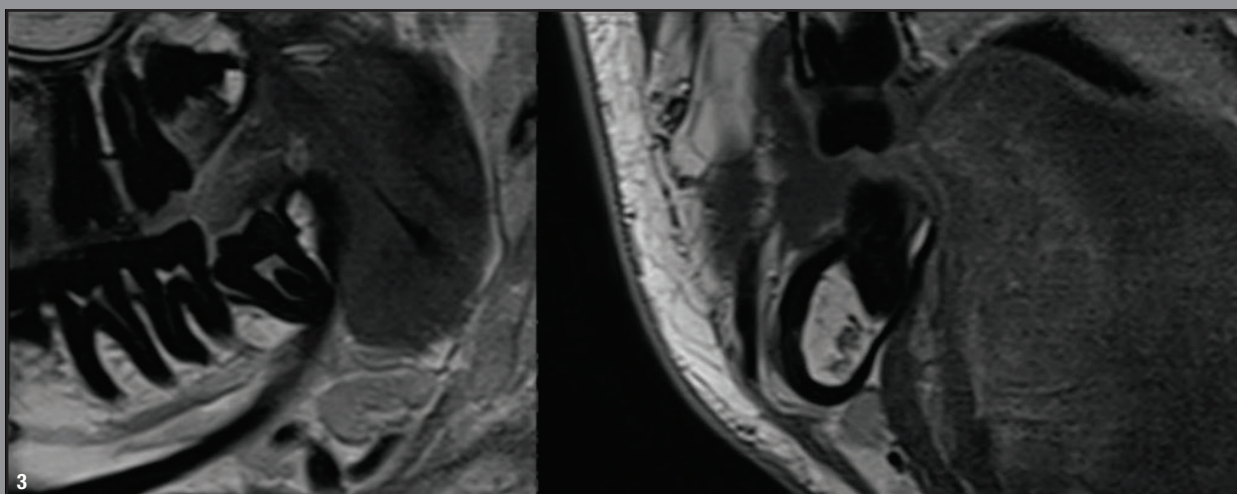
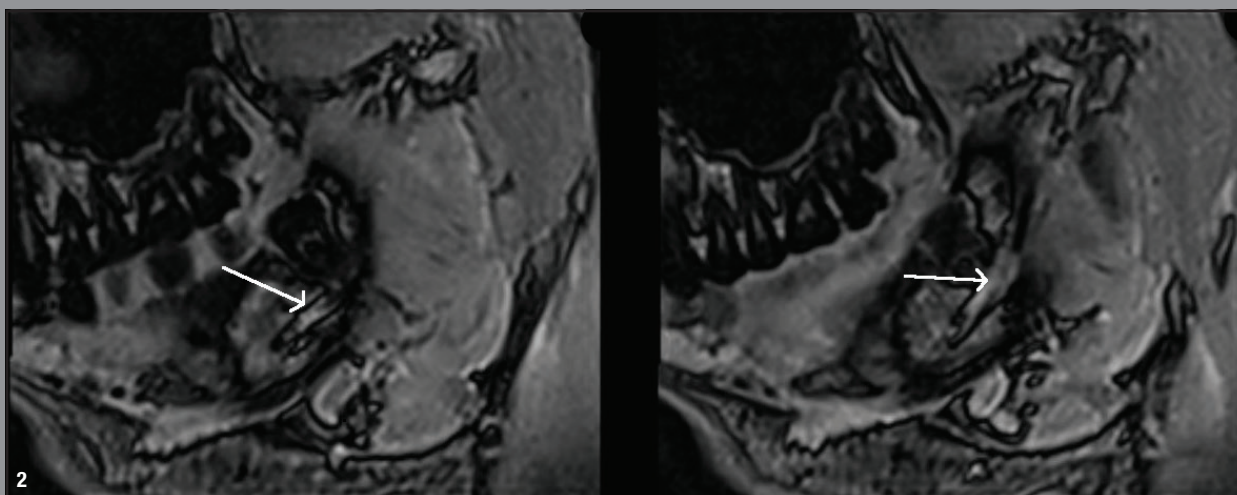


Fig. 2: Course of the inferior alveolar nerve. Sagittal FLAIR sequence illustrating the nerve's pathway in relation to an impacted lower wisdom tooth.

Fig. 3: T1-weighted Turbo Spin Echo (TSE) imaging of the impacted tooth 48, presented in sagittal (left) and axial (right) sections.

Figs. 4a+b: T2-weighted Turbo Spin Echo (TSE) sequence of the mandibular anterior region, clearly depicting a hyperintense zone apical to tooth #41, indicative of an acute inflammatory process.

Figs. 5a+b: Axial sections of a 3.5T MRI, displaying T1-weighted imaging (a) and an additional T1-weighted sequence (b) for a detailed view of the mandible.

Reducing the field strength decreases structural demands, simplifying installation, conserving resources (including helium and energy) and enabling a more compact design. With a smaller footprint, lighter weight and reduced cooling requirements, the ddMRI system offers greater flexibility in installation sites. It operates using Siemens DryCool energy system, requiring just 0.7 l of liquid helium for magnet cooling over its entire lifespan. In contrast, conventional low-field MRI systems in human medicine consume approximately 200 l of helium, which must be regularly replenished. This drastic reduction in helium usage not only lowers acquisition and maintenance costs but also significantly enhances the system's sustainability.

Achieving truly practice-friendly device dimensions remains a challenge. Currently, the ddMRI system is still designed as a whole-body MRI, requiring substantial space. At present, it occupies 24 m²—comparable to the size of a spacious waiting room. Furthermore, despite ongoing efforts to reduce its weight, the system still weighs 32 tonnes.

Given the current hardware, software and application requirements, the primary target audience for the ddMRI unit remains universities and dental clinics. According to the companies involved, these institutions have already shown strong interest in the technology. Once the necessary regulatory approvals have been secured, regular distribution will commence, paving the way for wider adoption in academic and clinical research settings.¹

A major advantage: Radiation-free imaging

The most significant benefit of dental MRI is its ability to generate images without ionising radiation, making it a major advancement in patient safety. Unlike conventional imaging methods such as CBCT and CT, which rely on X-rays that can damage DNA, MRI sequences are produced using a strong magnetic field that aligns protons in the body. As a result, dental MRI eliminates radiation exposure, rendering the principles of as low as reasonably achievable and as low as diagnostically acceptable obsolete. Moreover, without the need to justify radiation exposure, unlimited imaging becomes possible.²

This breakthrough is particularly beneficial for dental specialties that rely on frequent imaging, such as paediatric dentistry, orthodontics and restorative dentistry. Children, in particular, stand to gain from radiation-free imaging, ensuring safer diagnostics without long-term risks. Additionally, dental MRI is an ideal solution for patient groups requiring repeated examinations, such as those undergoing tumour follow-up, pregnant women or other individuals in sensitive life stages where radiation exposure poses long-term risks.³ Beyond these applications, dental implantology stands to gain significantly

from this new technology because it opens up new diagnostic possibilities while ensuring maximum patient safety.

Advantages for oral surgery

Besides long-term patient safety and superior visualisation of soft-tissue structures, dental MRI offers several further advantages over conventional imaging modalities used in dental practice, such as CBCT and panoramic radiography.^{4–6} One notable capability is the precise localisation of the inferior alveolar nerve within the mandibular canal during third molar surgery. Compared with conventional imaging techniques, dental MRI provides clearer native visualisation, reducing the risk of nerve damage and improving surgical planning.⁷ Additionally, MRI surpasses other imaging methods in the early detection of diseases with significant soft-tissue involvement.⁸ They offer detailed visualisation of muscles, nerves and ligaments, making them particularly valuable for identifying pathological soft-tissue processes such as tumours at an early stage.⁹

“The most significant benefit of dental MRI is its ability to generate images without ionising radiation, making it a major advancement in patient safety.”

Advantages for dental implantology

In dental implant planning, dental MRI offers a key advantage: the precise localisation of nerves and soft-tissue structures, such as the gingiva, and their anatomical relationship to the planned implant site. This level of detail is crucial for ensuring accurate implant placement and minimising surgical risks.^{10,11}

While conventional CT excels in bone visualisation, early studies on implant planning using dental MRI have shown promising results, addressing one of the key limitations of MRI in comparison to CT. Research conducted both *in vitro* and on patients has successfully demonstrated the feasibility of implant planning and guided implantation using CAD/CAM techniques.^{12,13} For optimal implant planning in complex intra-oral anatomies, a hybrid approach combining ddMRI and CT should be considered. This integration would allow practitioners to leverage the supe-