issn 1868-3207 • Vol. 6 • Issue 1/2021

1/21

ortho

international magazine of orthodontics

case report
Post-orthodontic restorative approach for young patients with missing anterior teeth: No-preparation and ultra-conservative techniques

feature
Recognising and avoiding negative stress and burn-out

technique
Inspired by the Maya—skull and tooth reconstruction with 3D printing

dti] Dental Tribune International

CURAPROX

SWISS PREMIUM
ORAL CARE

Prof. Mauro Labanca

Prof. Mauro Labanca is an oral surgeon and the registrar of the European section and a councillor of the International College of Dentists.

Per aspera ad astra

We are unquestionably living in a difficult, complex time that will enter the history books. We are fortunate to be the first generation not to have experienced a major war, but instead we are living another kind of trauma through this pandemic.

Too many words have been said and are being said, far too many, about what is happening. This verbal redundancy confuses, annihilates, saddens and adds despondency to what the pandemic is causing. If *some* of us have been affected, directly or indirectly, by the virus and disease, we *all* have certainly been affected by the media pressure bombarding us daily, adding a collective insecurity and depression that our psychiatric colleagues are struggling to manage. I believe that in order to stem this situation, *we* can and therefore *must look for positive aspects* that, even if difficult to imagine, can be considered in this period, when we are all being tested as humans.

That our profession (especially the private segment) is among those that have only had to close temporarily and, when compared with others, has certainly not suffered as much financially; this is a primary aspect that should make us feel privileged and more positive than those who have really lost everything.

As an international speaker, accustomed to lecturing around the world, I found myself returning to full-time dental practice, what I studied for. And now, with no meetings (if not virtual), interminable business dinners or even congresses, at times frankly useless, it has given me the opportunity to slow down, take a breath and look around. *Looking around*, I believe, is the most important thing this pandemic has given us besides the physical suffering it has caused.

Why not use this imposed professional slowdown to do something else? Why not use this moment, in which we maybe have fewer patients, to reorganise our practice, to review protocols, to check that our staff are adequately trained and informed, to learn whether we can do something to improve the services we offer and be more prepared when things return to "normal"?

We could use this time to organise our patients' files, to concentrate on our continuing education (notwithstanding the continuing education required by law), to engage more with our team, to think about how to communicate to our patients that we have used this time to grow, to improve, to change, because in difficult moments we grow, and *those who do not know how to grow succumb*. We miss live events—there is no doubt—but above all, we miss the convivial aspect of these events. The scientific aspect can easily be found by reading a book or a scientific journal, or following a webinar (provided it is of quality). Finally, why not use these quiet evenings spent at home to perhaps improve your English, to read a novel, to rediscover the value of emotions, because we are forced to slow down the crazy rhythm, often not justified, that most of us experience in normal times?

I hope that the SARS-CoV-2-wreaked havoc will be stopped as soon as possible, but even more so, *I hope that when the virus is overcome, a better world will remain*, more sensitive, more attentive, more aware of what true life values are—and then we could really say that, *through hardship, we have reached the stars*.

Prof. Mauro Labanca

Editorial note: This editorial was published as well in the Italian edition of implants—international magazine of oral implantology, *volume 10, issue 1/2021.*

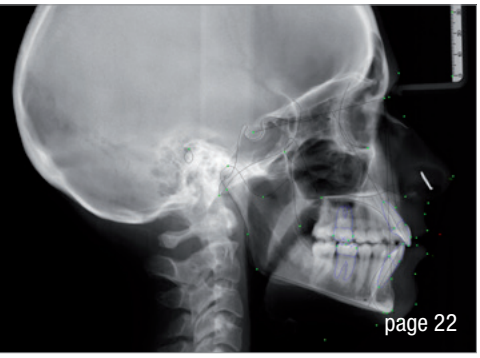

editorial

Per aspera ad astra 03
Prof. Mauro Labanca

case report

Post-orthodontic restorative approach for young patients with missing anterior teeth: No-preparation and ultra-conservative techniques 06
Dr Didier Dietschi

The importance of treatment planning and patient compliance in the clear aligner orthodontic technique 12
Dr Tomás A. Salazar

Clear aligner orthodontic treatment of a complex malocclusion 22
Dr Gina Theodoridis

interview

Minimum touch orthodontics: Giving patients security and freedom 28
An interview with Dr Luis Carrière

feature

Recognising and avoiding negative stress and burn-out 32
Jerko Bozikovic

Stars and social media influencers are turning clicks into clear aligner cases 36
Jeremy Booth

technique

Inspired by the Maya—skull and tooth reconstruction with 3D printing 38
Dr Yassine Harichane

practice management

Can Slow Dentistry be digital? 44
Dr Miguel Stanley

research

COVID tongue—dentists urged to remain alert to symptoms in the oral cavity 48
Jeremy Booth

interview

Sustainable dentistry is a philosophy that offers the best version of ourselves 50
An interview with Dr Primitivo Roig

industry report

I-arch: Innovation in the biomechanics approach 52
Sia Orthodontic Manufacturer

about the publisher

international imprint 54

Cover image: Krakenimages.com/Shutterstock

SIGN UP NOW

Dental Tribune e-newsletter

DENTAL TRIBUNE

The world's dental e-newsletter

news / live event coverage / online education / KOL interviews
event reviews / product launches / R&D advancements

www.dental-tribune.com

facebook.com/DentalTribuneInt

twitter.com/DentalTribuneIn

linkedin.com/company/dental-tribune-international

Post-orthodontic restorative approach for young patients with missing anterior teeth: No-preparation and ultra-conservative techniques

Dr Didier Dietschi, Switzerland

Introduction

Congenital aplasia or the early loss of permanent teeth after trauma may be corrected by means of orthodontic or implant treatment. The proper diagnosis of dental and skeletal conditions normally guides the choice between the treatment options.[1, 2] The need for long-term maintenance of prosthetic restorations and their potentially negative influence on periodontal health[3] have always been considered main shortcomings favouring an orthodontic solution.[4, 5] However, different anatomical, functional and aesthetic anomalies may result from the orthodontic approach. The increasing desire of our patients for aesthetics obliges restorative dentists to consider these deficiencies and to propose appropriate solutions. Well-known treatment modalities such as whitening and composite resin bonding have gained popularity as they have improved in practicability, efficiency and predictability.[6–8]

The aim of the present paper is to review and outline the interest of direct restorative modalities aimed at correcting anatomical, functional and aesthetic anomalies after orthodontic treatment in patients with missing anterior teeth. The use of such a therapeutic means in comprehensive treatment planning will be discussed.

Primary parameters	Skeletal conditions Dental conditions Soft-tissue profile Patient's age Number and localisation of missing teeth
Local parameters	Tooth forms and dimensions Conditions of the edentulous section: • Persistence of primary dentition • Soft- or hard-tissue defects
Secondary parameters	Patient's motivation and understanding Patient's economic means Patient's dental hygiene

Table 1: Decision parameters for the treatment of patients with missing anterior teeth.

Treatment decision rationale

There are different decision levels for the treatment of young patients with missing anterior teeth (Table 1). Each of them should be carefully weighed during treatment planning, as both orthodontic and prosthodontic treatment options are in principle irreversible.

Essentials of orthodontic treatment strategy

Initial skeletal conditions as well as inter-arch and intra-arch dental relationships will determine the opportunity for orthodontic space closure. In the absence of evidence of malocclusion requiring mandibular tooth extractions, Class I occlusion cases usually favour treatment of the edentulous section/s by space maintenance or opening, followed by prosthetic replacement of the missing tooth/teeth. Conversely, the presence of Class III malocclusion contra-indicates orthodontic space closure of missing maxillary anterior teeth. Maxillary anterior spaces should be closed orthodontically in Class I extraction cases (severe crowding) or in some Class II cases where alveolar and skeletal growth potential pre-

Fig. 1a: Missing or impacted canines. The best option is space maintenance or opening with implant-supported restorations. During surgery, proper soft-tissue anatomy will need to be re-established.

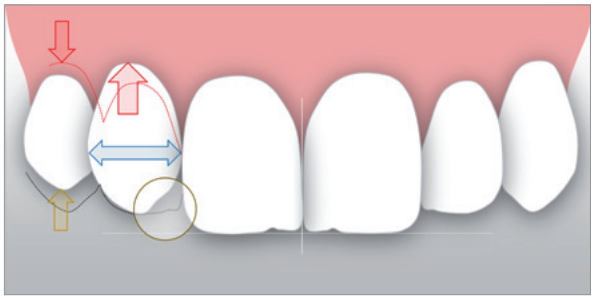

Fig. 1b: Missing lateral incisor. Space closure is a frequent treatment option and results in the following anatomical and aesthetic discrepancies: excessive canine coronal and cervical diameters (blue arrow), a deficient canine incisal profile (circle), an apically displaced gingival zenith (red arrow) and a premolar that is too short, both cervically and incisally (red and brown arrows).

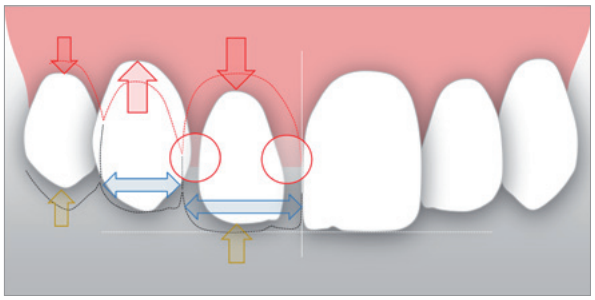

Fig. 1c: Missing central incisor. Space closure is less frequently chosen. If it is, it will result in the following anatomical and aesthetic discrepancies: a lateral incisor that is too narrow and short, both cervically and incisally (red, blue and brown arrows), flat mesial and distal papillae around the lateral incisor (circles), and a canine and premolar with the same deficiencies as described for the space closure for a missing lateral.

Fig. 2a: A 21-year-old patient completed orthodontic space opening after extraction of impacted canines.

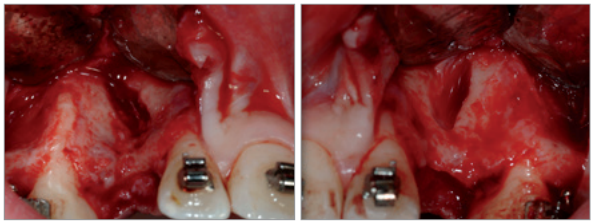

Fig. 2b: Intra-op views showing extreme bone defects extending all the way to the palate, which necessitated extensive guided bone regeneration. Implants were placed in a second phase (stepped approach).

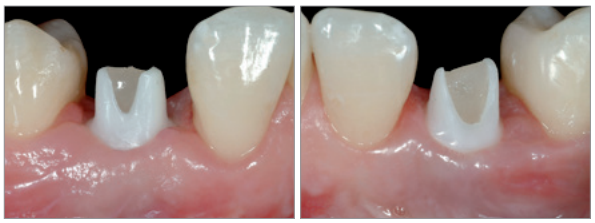

Fig. 2c: Zirconia abutments in place.

Fig. 2d: Post-op view showing good gingival and anatomical integration. Space opening and implant-supported restorations are nowadays the most appropriate therapeutic option.

clude an orthodontic correction of the Class II relationship. It should be stressed that, in any clinical situation, a trial diagnostic set-up is mandatory for anticipating the influence of orthodontic treatment on occlusal, periodontal and dental conditions. Figures 1a to c depicts the most common clinical problems and their possible restorative solutions, after orthodontic space closure.

Space maintenance or opening

Depending on the occlusal conditions and particularly on the patient's age at the time of treatment planning, the alternative option to orthodontic space closure is space maintenance or opening, followed by prosthetic replacement of the missing teeth. The three major treatment

Fig. 3a: A 17-year-old patient with congenitally missing lateral incisors completed orthodontic space closure. The canines had a very unusual sharp appearance. The optimal smile line and gingival profile were superimposed on the photograph to demonstrate the various anatomical and aesthetic deficiencies, such as described in Figure 1b.

Fig. 3b: Aesthetic analysis was done on the computer and served as proper communication with the patient and for the detailed treatment planning.

Fig. 3c: In-office whitening was performed to unify tooth colour; this treatment modality was chosen in this case owing to the limited colour correction needed.

Figs. 3d & e: Post-op views after full smile enhancement using freehand direct bonding following the natural layering concept (inspiro, Edelweiss DR). Central incisors were restored mainly with a single layer of achromatic enamel. Note that the gingival profile correction shown in Figure 3a was not performed owing to the young age of the patient and limited gingival display (low lip line).

options for anterior tooth replacement are implant-supported crowns (Figs. 2a–d), metal-based or all-ceramic adhesive bridges and removable dentures, which are mostly considered for provisionalisation, especially in young patients when definitive treatment has to be postponed. Because implants will not follow alveolar bone growth, fixture placement should not be used in young patients until full jaw growth has been attained, from 18 to 25 years of age and even later.[9, 10]

Ultra-conservative restorative procedures after space closure

The anatomical and aesthetic anomalies that result from spontaneous space closure or orthodontic procedures may be corrected by choosing the appropriate restorative modalities, often involving a multidisciplinary approach (Figs. 3 & 4)[2.]

Recontouring

Recontouring or odontoplasty may be performed during or after orthodontic treatment. For instance, when canines have to be moved into the positions of the lateral incisors, there is usually a space discrepancy. In this situation, the careful reduction of canine diameter and palatal volume will improve the inter-arch relationship as well as reconstructive procedures (Figs. 4a & b). The ratio of the root diameter to the crown diameter will dictate the amount of tissue that can be removed interproximally, provided that corrections can be made entirely in enamel to avoid dentine exposition or root proximity.

Whitening

A problem of tooth colour often arises when the canines are in a more mesial position. These teeth present with a more saturated colour (normally, a similar hue but a higher chroma) compared with that of incisors (Figs. 3a & c). After the required odontoplasty has been performed, colour correction should be tried, using one of the available whitening techniques for vital teeth, namely chairside whitening or home whitening.[6–8]

Direct composite bonding

Modern composite resin kits provide very performant restorative materials. Besides the dramatic improvements made in their physico-chemical properties, modern composites have satisfactory colour stability and aesthetic potential.[11–13] Among the various layering options, the which became the reference in reliability and simplicity is the natural layering concept, which corresponds to a bilaminar, anatomical application of dentine- and enamel-like shades which closely emulate natural hard tissue.