

# CAD/CAM

international magazine of digital dentistry

## trends & application

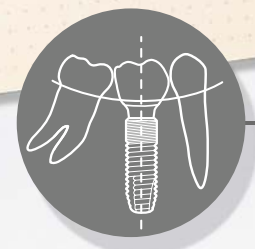
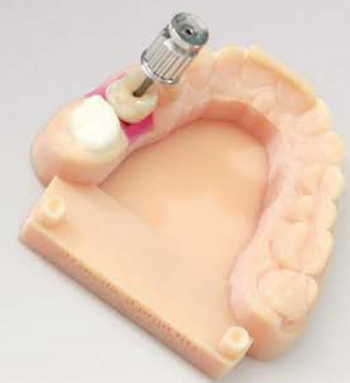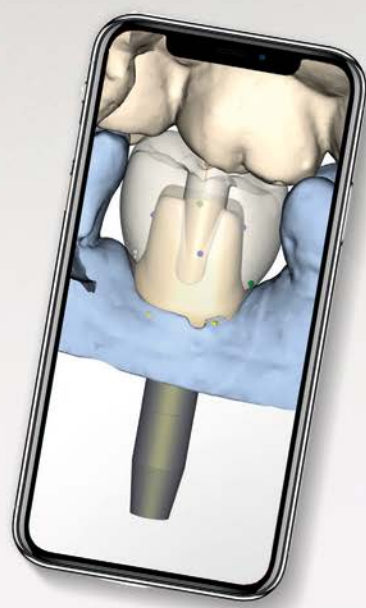
Optical impression and provisional prosthesis: Proposal for a new approach

## industry report

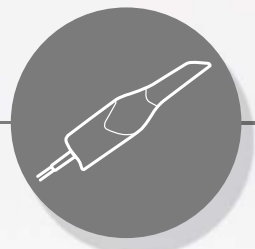
The complete digital implant workflow

## cone beam supplement

Matching of CBCT and virtual wax-up for single-tooth replacement of a central incisor



Planning and guided surgery



Digital impression



Restorative solution

## Digital implant workflow

# Connect to the future

From data capturing, planning, guided surgery to the final restorative solution, with the digital implant workflow from Dentsply Sirona you have all the support you need to save time, grow your business and provide patients with the best possible care.

[www.dentsplysirona.com](http://www.dentsplysirona.com)



Dentsply Sirona does not waive any right to its trademarks by not using the symbols or 32671431-USX-1902 © 2019 Dentsply Sirona. All rights reserved

**Dr Scott D. Ganz**

Editor-in-Chief



# Change

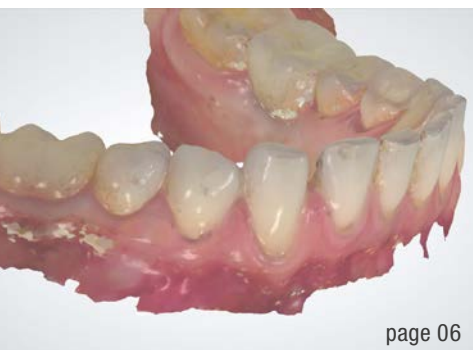It is a new year... and it is time for change. As we contemplate what transpired in 2018, we must also think about what will happen in 2019. In many ways the dental industry is at a crossroads of sorts, the investment in analogue solutions has been a mainstay of our educational initiatives and daily clinical practices for more than a millennium. We are now closing in on all-digital solutions for most procedures in dentistry, including crown-and-bridge, orthodontics, porcelain laminate veneers, dentures, surgical placement of dental implants, and implant restorations. Of course, moving from analogue to digital requires a behavioural change. Can we exist in an all-digital world? Is this the future of dentistry? Thus, the crossroads of change.

Besides a behaviour change in order to adopt a digital workflow, we must first invest in new equipment and learn the new digital language that is necessary to move pixels and voxels around on our LCD computer monitors to design new smiles, diagnose pathology, or to place implants in the correct positions to support a new occlusion. The move from analogue is not easy because of the monetary investment and the time necessary to learn new ways to communicate our treatment plans and turn them into reality. Dentists are truly artists of the oral cavity; however, as I have stated many times, we are really the “architects and the engineers” of the oral cavity—and

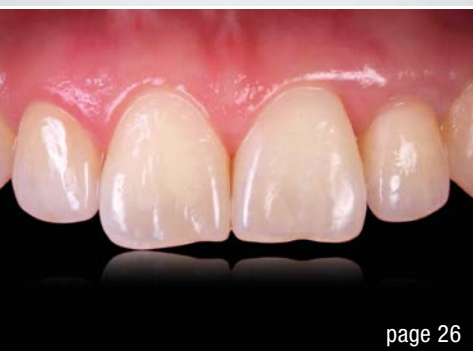we now have some very powerful digital tools to create the blueprints necessary to achieve success. Clinicians used to using their well-trained hands to sculpt a beautiful functional and aesthetic result intraorally, are now using their hands to move a mouse around a screen to create a virtual restoration with the same outcome. It is a behavioural change for sure, but one that brings wonder and excitement to those who embrace the potential of the digital world.

Fortunately, many dental schools have made the change, and are now investing in the proper equipment (with thanks to the dedicated manufacturers who offer their assistance) to educate and train the next generation of clinicians to be proficient in the digital workflow that exists today, and that will continue to evolve for years to come. Therefore, change was necessary to the standard “analogue” dental curriculum to insure future progress. We are fortunate that Dental Tribune International is also a partner in this digital evolution—not only offering physical publications, but a strong online presence to help spread the word to our global community. Let’s see what change is in store for 2019.

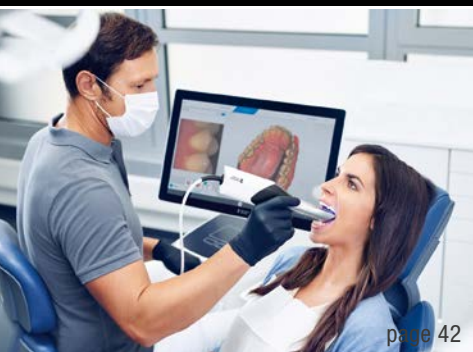
Dr Scott D. Ganz  
Editor-in-Chief



page 06




page 26



page 42

Cover image courtesy of PRIMA DENTAL  
primadental.com



## editorial

Change 03  
Dr Scott D. Ganz

## trends & applications

**Optical impression and provisional prosthesis:**  
**Proposal for a new approach** 06  
Drs Olivier Landwerlin & Michel Fages

## study

**Comparison of guided and non-guided implant placement accuracy**  
**In vitro study with 3D printing (Part 1)** 18  
Dr Łukasz Zadrozny, Marta Czajkowska & Dr Leopold Wagner

## case report

**Full-guided treatment for the edentulous mandible:**  
**a proof-of-principle report and technical note** 22  
Drs Christos Alamanos & Reinhold Lang

## industry report

**The complete digital implant workflow** 26  
Drs Kirill Kostin, Mikhail Erohin, Oleg Ponomarev & Maxim Kozhevnikov

## cone beam supplement

**Matching of CBCT and virtual wax-up for single-tooth replacement**  
**of a central incisor** 30  
Dr Jakob Zwaan

## manufacturer news

40

## meetings

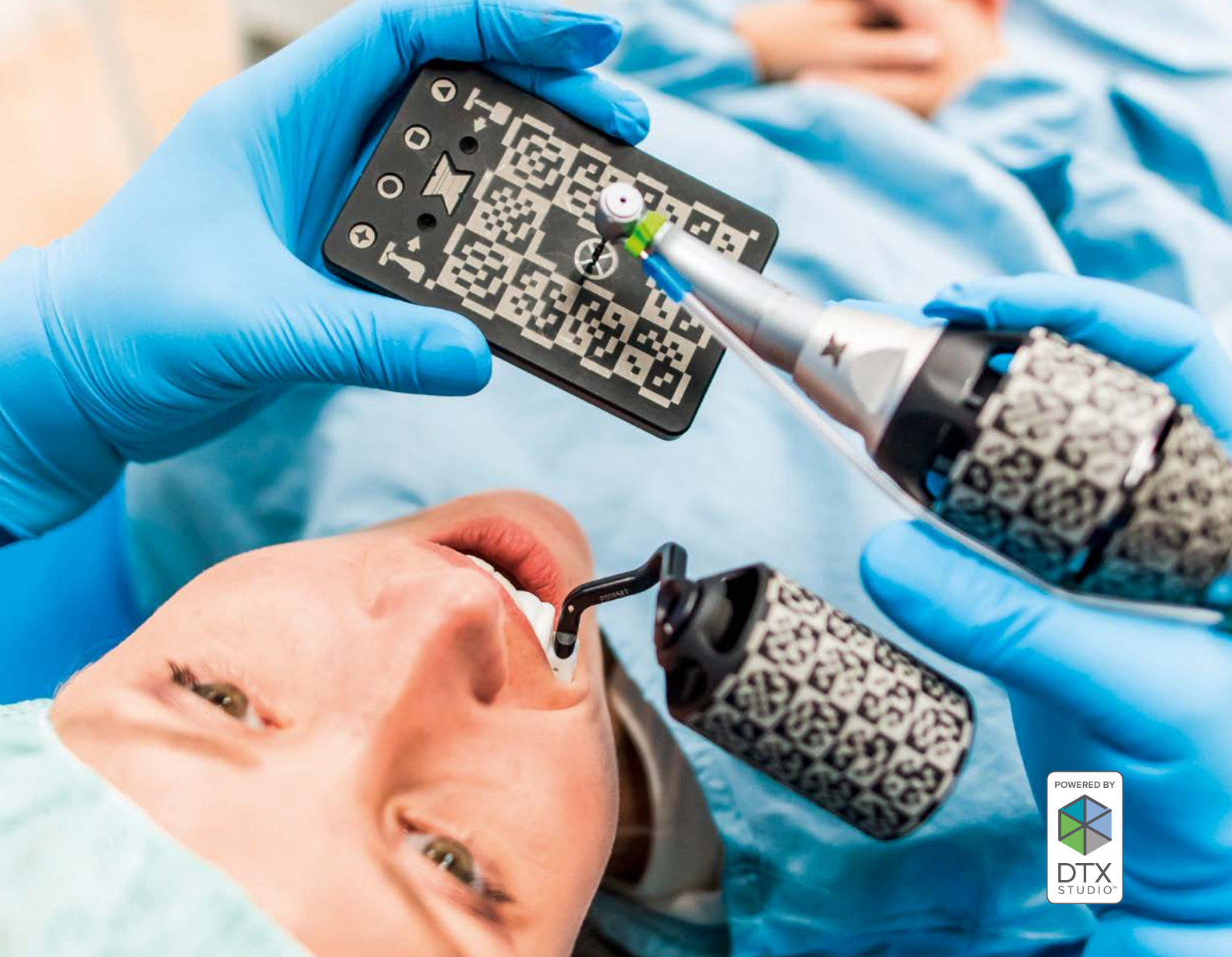
**Nobel Biocare Global Symposium in Madrid to open new chapter**  
**in implant dentistry** 46

International events 48

## about the publisher

submission guidelines 49

international imprint 50



# Same-day 3D navigated surgery

- Perform free-hand surgery with real-time 3D guidance for your drills and implants with X-Guide
- Adapt your implant plan anytime during surgery
- Facilitate more same-day diagnostic and treatment sessions with DTX Studio suite

GMT 59319 GB 1811 © Nobel Biocare Services AG, 2019. All rights reserved. Distributed by: Nobel Biocare. X-Guide is either registered trademark or trademark of X-Nav Technologies, LLC in the United States and/or other countries. Nobel Biocare, the Nobel Biocare logotype and all other trademarks are, if nothing else is stated or is evident from the context in a certain case, trademarks of Nobel Biocare. Please refer to [nobelbiocare.com/trademarks](http://nobelbiocare.com/trademarks) for more information. Product images are not necessarily to scale. Disclaimer: Some products may not be regulatory cleared/released for sale in all markets. Please contact the local Nobel Biocare sales office for current product assortment and availability. For prescription use only. Caution: Federal (United States) law restricts this device to sale by or on the order of a licensed dentist. See Instructions For Use for full prescribing information, including indications, contraindications, warnings and precautions.



# Optical impression and provisional prosthesis: Proposal for a new approach

Drs Olivier Landwerlin & Michel Fages, France

## Introduction

The widespread use of intraoral optical impressions and constant improvements in dental computer-aided design (CAD) software today allow the practitioner to manage various kinds of clinical situations, from the simplest to the most complicated, by using different types of dedicated equipment (camera software, processors and, more recently, 3D printers) as part of a completely digital workflow.<sup>1</sup> Arch scanning methods using intraoral scanners yield impressions that are comparable to those obtained with traditional equipment in terms of clinical precision<sup>2</sup> because they eliminate the variations caused by the user, reduce the readjustment processing time and costs, and improve patient satisfaction and comfort.<sup>3, 4</sup>

It is customary to distinguish direct computer-aided design/computer-aided manufacturing (CAD/CAM), in which all the stages (optical impression, CAD, CAM) are

undertaken in the practice, from the semi-direct method, in which a digital impression is sent via the Internet to the dental technician for fabrication. When crowns and bridges are produced using semi-direct CAD/CAM, this usually includes the use of a temporary prosthesis. The temporary bridge is retained while the definitive prosthesis is fabricated in the laboratory. This helps in terms of maintaining aesthetic and functional factors, and in the event of adaptations to vital teeth, it protects pulp vitality and reduces inter-session sensitivity. The therapeutic goals of temporary CAD/CAM readjustments are similar to those of conventional fabrication techniques.<sup>5</sup> The transitory fixed prosthesis is designed to enhance aesthetics, stabilisation, and/or function for a limited period, after which it is replaced by a definitive prosthesis.

Often, such prostheses are used to assist in the determination of the therapeutic effectiveness of a specific treatment plan or the form and function of the planned definitive prosthesis. The following requirements need to be met:

1. biological requirements: protect the dental pulp; maintain and contribute to periodontal health; provide a comfortable, functional occlusal relationship; maintain tooth position; and protect remaining tooth structure;
2. mechanical requirements: resist functional load and resist removal forces without fracturing;
3. aesthetic requirements: resemble natural teeth (chameleon effect) and achieve the stability of the shade at that time.

The materials used in CAD/CAM are more fracture-resistant than the resins used chairside;<sup>6,7</sup> they are extremely aesthetic in aspect and afford repair or modification directly at chairside.<sup>8</sup> The ability to produce temporary prostheses with optimal, more predictable adjustment margins is of the greatest interest from the aspects of plaque control, gingival health and protection of residual dental structures. The respect of limits, aesthetics and the choice of sufficiently resistant restorative materials are important factors to take into account, especially during mid- or long-term temporary aesthetic restoration.<sup>9</sup>

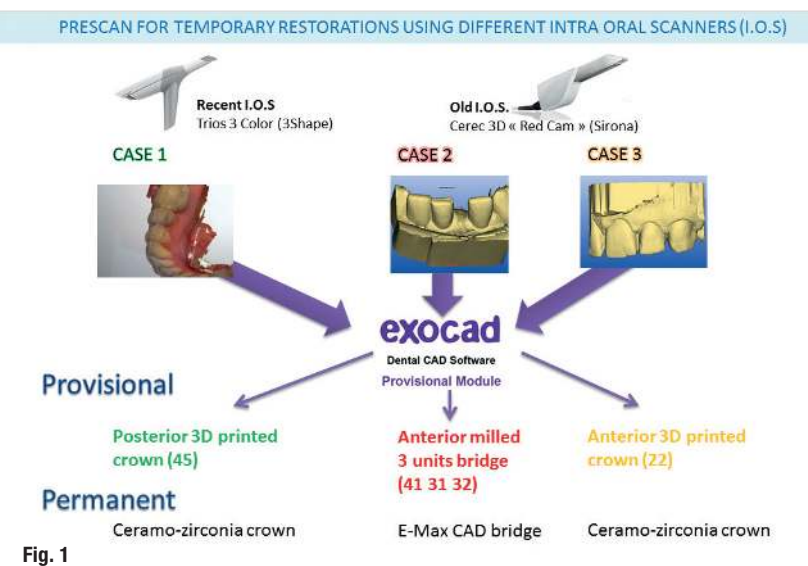


Fig. 1

**Fig. 1:** Pre-scan for temporary restoration. Three-dimensional proprietary formats DCM (3Shape) and CDT (Sirona) can be imported in STL format in exocad open software after conversion and exported for fabrication (3D printing or milling) of the provisional restorations.

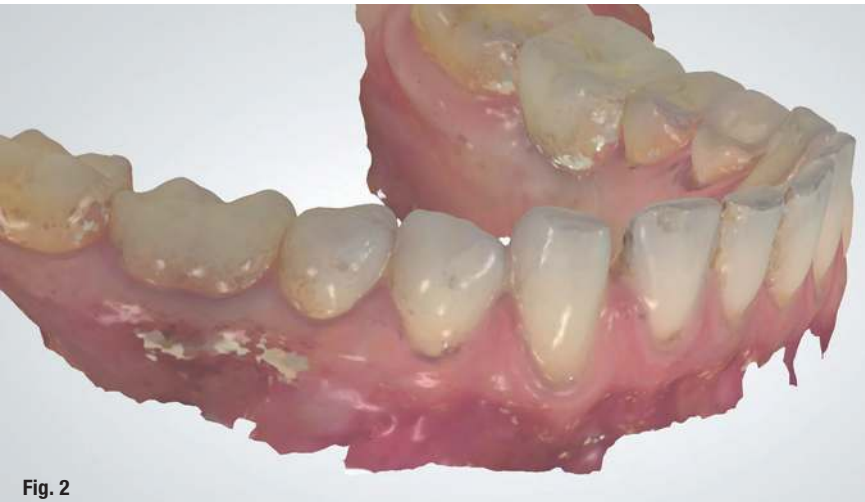

Fig. 2



Fig. 3

**Case 1—Fig. 2:** TRIOS 3 color (3Shape) pre-scan. **Fig. 3:** Bonding of a fibre-reinforced composite post under a rubber dam (LuxaCore Dual, DMG).

In conventional techniques, a crown or a bridge can be prepared, that is, undertaken before the teeth are made, based on a wax-up or self-casting, using an impression taken prior to preparation. Transposed to CAD/CAM, this demands 3D digital recording of the initial clinical situation with the aid of an intraoral scanner. This article puts forward a modern, routine development in the management of CAD/CAM-produced temporary teeth based on three clinical case studies: one using a subtraction method (milling) and the others using an additive method (3D printing).

In the milling method (subtraction), the volume is reduced (block or disc) until the shape required is achieved. Three-dimensional printing is an additive method by the deposit of successive layers until the final shape is achieved. Stereolithography (SLA) was invented in the 1980s and involves the hardening of liquid light-cured resin placed in a tray by photopolymerisation, using a laser that builds the object up layer by layer. A similar 3D printing technology used for the fabrication of temporary dental crowns is known as digital light processing (DLP), which uses a projector instead of the laser. The digital projection of the

3D shape of the tooth on the liquid resin allows superimposition of successive layers by light-curing the resin. It is one of the most precise 3D printing methods.<sup>10</sup>

For the past few years, 3D printing has been used in various areas of dentistry:<sup>11</sup>

- surgical guides,<sup>12</sup>
- model manufacture,<sup>13–15</sup>
- manufacturing of burn-out resin or wax pieces for the lost-wax method,<sup>16</sup>
- anatomical models for the planning of surgery or for educational purposes,<sup>17,18</sup>
- aesthetic prototypes (mock-up),<sup>1</sup>
- removable prostheses.<sup>19</sup>

Quite recently, the materials used in the 3D printing of temporary crowns and bridges have been marketed and are now being used successfully alongside intraoral scanners.<sup>20</sup> The purpose of this article is to demonstrate the usefulness of rapid prototyping for the realisation of temporary dental restorations from preliminary optical

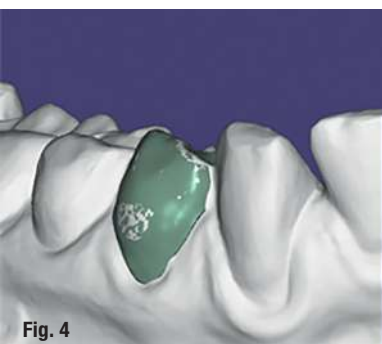


Fig. 4

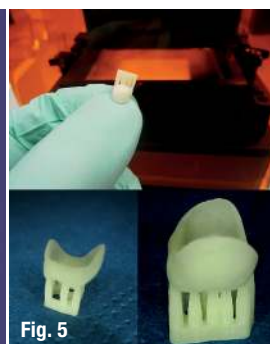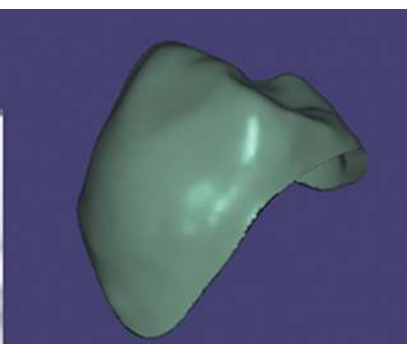


Fig. 5

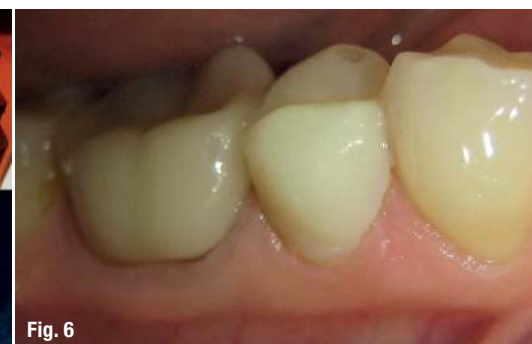
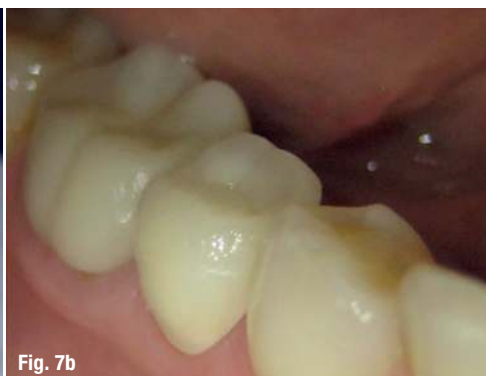
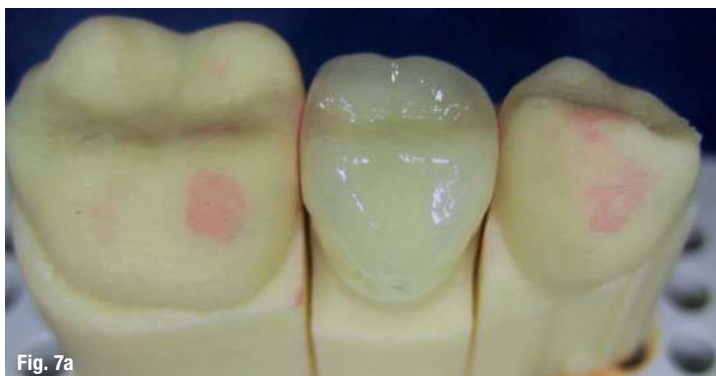Fig. 6

**Case 1—Fig. 4:** Creating eggshell temporaries for tooth #45 with the exocad provisional module. **Fig. 5:** 3D printing of the temporary crown with E-Dent 400—biocompatible, CE-certified Class IIa (described as generally invasive products with a short-term application, validated up to one year in the mouth by the manufacturer) and 3D printed support structure. **Fig. 6:** Temporary crown on tooth #45 set in the mouth.



**Case 1—Figs. 7a & b:** 3D printed model for fabrication of the stratified zirconia crown in the laboratory (a). Zirconia crown set in the mouth (b).

impressions gained using intra-oral scanners. We implemented this method using two scanners: a last-generation (2016) scanner (TRIOS 3 color, 3Shape) for Case 1, and a previous generation (2008) scanner (CEREC 3-D Redcam, Sirona) for Cases 2 and 3 (Fig. 1).

We describe the workflow to obtain an open STL file format of the final restorative design from proprietary format files, CDT for the CEREC 3-D scanner and DCM for the TRIOS scanner. We show that these files can be either milled or 3D printed to produce the final prosthesis.

After the presentation and comparison of the two fabrication techniques based on three clinical case studies, we will discuss which materials are available for 3D printing, in which type of printer they can be used, and the advantages we might draw from both case studies by manufacturing provisional prostheses prior to the preparation of the teeth.

### Conventional methods for fabrication

Practitioners habitually use several methods to fabricate provisional prostheses:<sup>21</sup>

1. They preform custom crown shells (cellulose acetate or polycarbonate forms).
2. They customise resin restorations by different techniques:
  - direct technique assisted by a matrix (elastomeric or alginate impression or vacuum-formed plastic template) or by using a custom-carved technique (block temporary); or
  - indirect technique with the help of a laboratory that delivers an almost finished restoration (which will be relined and readapted in the mouth) from an impression of the clinical situation; this needs an impression preparation and antagonist arch and, often, a method for registering the occlusion.

Materials used for provisional restorations produced by conventional methods involve various polymers: poly-

methyl methacrylate (PMMA), poly(ethyl methacrylate) (PEMA), and bis-GMA light-polymerised urethane dimethacrylate (UDMA).

Direct methods are often very quick to implement, but a number of studies have shown better quality of restoration by indirect methods:

- It is known that fabricating provisional crowns by the indirect technique produces more acceptable marginal adaptation than do other techniques.<sup>22</sup>
- Chairside time is reduced because most of the procedures are completed before the patient's visit.
- Less heat is generated in the mouth because the volume of the resin used is small. The amount of heat generated and transferred to the pulp chamber, however, may be sufficient to cause thermal damage to the pulp and odontoblasts. The temperature rises in the pulpal chamber during fabrication of provisional resin crowns.<sup>23</sup>
- Contact between the resin monomer and the soft tissue is minimised compared with the direct procedure.
- There are fewer final occlusal or aesthetic corrections. In the case of aesthetic or multi-unit restorations, the indirect fabrication of a provisional prosthesis becomes almost compulsory.

### Case presentation

For 3D printing, the final CAD files of the restoration must be in open STL format to be printed. In our report, we describe that the workflow is similar regardless of the intraoral scanner used (new or old generation).

**Case 1: Temporary 3D printed posterior crown** (on a Perfactory Vida high-resolution printer, EnvisionTEC) based on a preliminary impression with a TRIOS 3 color intraoral scanner.

#### *Initial situation and preliminary treatment*

In a 37-year-old patient, necrosis under a composite led to loss of the vitality of tooth #45 owing to caries. The missing tooth structure did not affect the entire morphology of



the tooth, and we wanted to realise a zirconia core structure layered with aesthetic porcelain, a viable option for opacity in cases of stained, devitalised teeth. This restoration would be sealed just after the intervention and during the necessary laboratory phase.

We took a preoperative scan (pre-scan) of the initial situation with TRIOS 3 color to produce a temporary crown using a 3D printer (Fig. 2). The impression (in DCM format) was transferred to the cloud via 3Shape Communicate to be converted into STL format. The pre-prosthetic treatment involved a root canal therapy and the setting of a fibre-reinforced composite post under a rubber dam (Fig. 3).

*Fabrication of the provisional prosthesis with a 3D printer*

A provisional prosthesis was made according to the shape of the tooth in the pre-scan, using the provisional eggshell module of exocad software (exocad; Fig. 4). The temporary crown was fabricated with the Perfactory Vida printer (Fig. 5) and fixed in the mouth with temporary cement (Fig. 6). After the base had been removed, the temporary crown was relined and adapted in the mouth on the day of preparation.

*Fabrication of the final restoration with CAD*

An optical impression was taken on the day of measurement and positioning of the temporary impression. This enabled the fabrication of a zirconia coping and the stratification of the aesthetic ceramic on the printed model (Fig. 7a) and the coping was then set in the mouth (Fig. 7b).

**Case 2: Temporary bridge milled in a fabrication centre from a CEREC 3-D Redcam optical impression**

The aim of CEREC in the past-decade technology was to produce chairside ceramic restorations typically as single unit. The slowness of both the optical impression and the milling machine made it difficult to produce even a definitive three-unit fixed dental prosthesis (FDP) in a single appointment. The method of fabricating a provisional by pre-scan

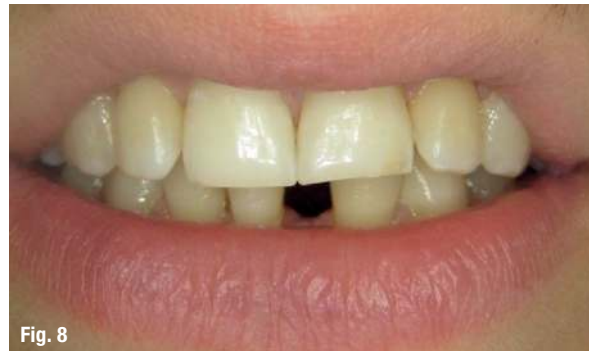

Fig. 8

**Case 2—Fig. 8:** Initial clinical situation: tooth #31 is missing.

and eggshell CAD can help to temporise during the laboratory phase.

*Initial situation*

A 19-year-old patient came for a consultation after a fall of several meters on to a rock, which had caused fracture of the jaw and was followed by surgical implantation of an osteosynthesis titanium plate. Fractured tooth #31 had to be removed owing to this operation, causing unitary edentulism. Owing to the presence of the osteosynthesis plate, the option of an implant was rejected after a scan (Fig. 8). Six months later, the bone growth and maturation reached the terminal point and the bone became eligible for bridge application.<sup>24</sup>

*Manufacturing of a three-unit provisional bridge*

A preliminary optical impression was taken with a CEREC 3D camera to record the initial situation and to create a dental morphological base for the manufacture of the FDP. The digital CDT file was then opened with the mainstream 3D open-source Blender software (Version 2.63.33; www.blender.org) equipped with the add-on Open Dental CAD developed by Patrick Moore for the export of the file in STL so that it can be read by exocad. The digital impression was optimised by free open-source CAD software (www.freecadweb.org) by trimming the edges to remove any artefacts created by the lower lip, which obstructs

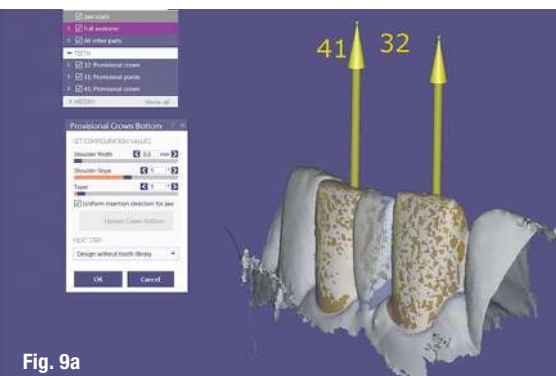


Fig. 9a

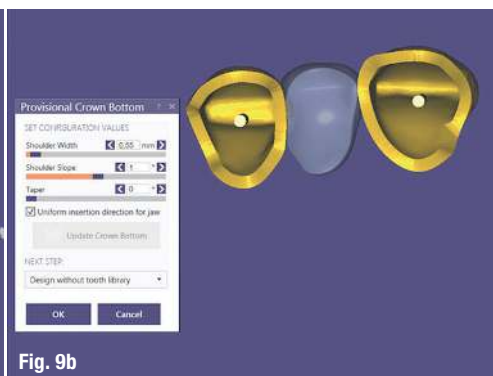

Fig. 9b

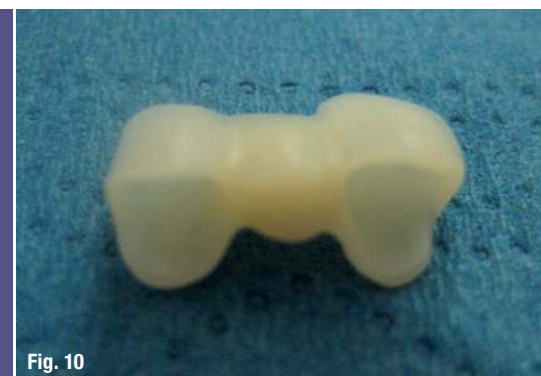

Fig. 10

**Case 2—Figs. 9a & b:** Positioning of the insertion angle of the future preparation (a). Adjustment of the thickness of the walls of the temporary bridge (b). **Fig. 10:** Temporary FDP milled (dentallgroup.eu).