


# ortho

international magazine of orthodontics



## case report

Laser-assisted orthodontic treatment of a dilacerated impacted maxillary incisor

## case report

Canine substitutions: Protocols for predictable excellence

## feature

What will be the new normal after COVID-19?

# Treat Boldly.



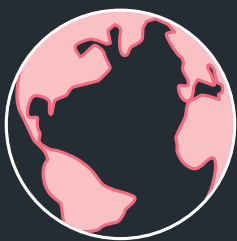
## Register today!

Join us for ClearCorrectXP 2021—ClearCorrect's 3-day global virtual event designed to empower you to *treat boldly*. During this can't-miss event, you'll hear from experts on clinical topics from fundamentals and complex movements, to practice management, and everything in between.

October 5-7, 2021

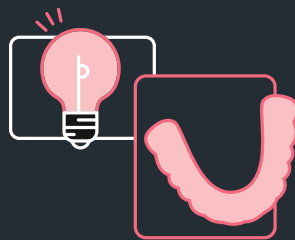
**cc|x<sup>p</sup>** VIRTUAL EVENT

To learn more and register, visit [ClearCorrectXP.com](https://ClearCorrectXP.com)




### GLOBAL EVENT

Hear from a diverse panel of speakers from around the world on the latest advancements and best-practices in clear aligner treatment.



### DIVERSE CONTENT

Participation is free! With content tailored to a variety of experience levels, specialties, and roles—in 6 different languages—there's something for everyone!



### ENGAGING FORMAT

Virtual 3-day event, broadcast live, and hosted in multiple formats, including general sessions and engaging, debate-style discussions.

**Dr Tif Qureshi**

Clinical Director of IAS Academy



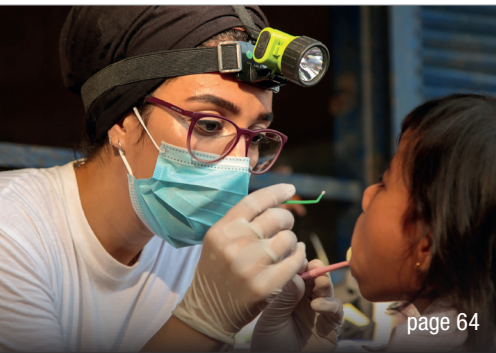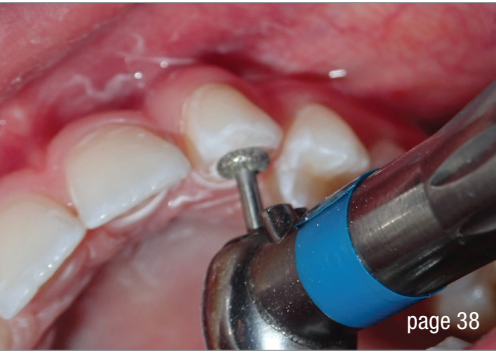
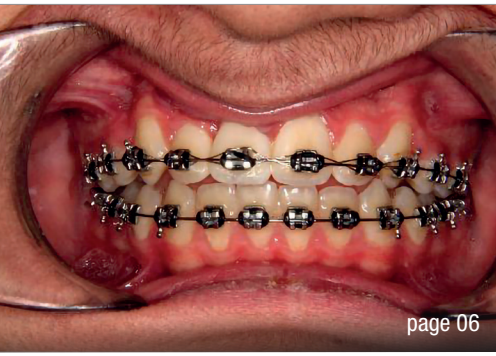
## The align, bleach and bond (ABB): its beginning and future

After practicing for only a few years my career nearly ended mid-1990s when I was desperately unhappy as a dentist. Why? Because in the British NHS a dentist, trying to do his best for his patients would occasionally on explaining why they needed treatment, hear the question “Is that because you want a Porsche?” This had a slowly grinding effect on me. There typically was little explanation to the public by British representative bodies about what quality dentistry meant or cost, so this was normal. At one point, I nearly left the profession, but the purchase of a basic dental intra-oral camera in 1997 changed my mind. From that point on, visual communication became a critical part of my practice. I moved towards aesthetic and cosmetic dentistry, and in the late 1990s, I started taking many courses and discovered that patients, once they could visualise their teeth, wanted to deal with aesthetic issues. One of these issues was tooth position and the need for orthodontics. This had a profound effect on the parameters of smile design. I learned of course how to ‘cut’ teeth to a correct position, but this made me uncomfortable, so we referred many patients to the orthodontist. But many rejected this offer, and for those who went, it was rare for them to proceed, because at that time, only comprehensive treatment was typically offered by the specialists. The concept of “limited objective orthodontics” was not widespread thus, patients often returned rejecting 1 year+ orthodontic treatment and requested veneers. For a while I did these veneers. This discomfort prompted me to experiment with spring aligners focused on the anterior zone (2003). I helped patients understand what I was going to align, and what I was leaving untouched, understanding ideal vs. compromised goals. This worked amazingly on a few initial cases, and suddenly within a few weeks, these aligners fixed smile design parameters that normally needed heavy preparation to

resolve. I contacted 20+ patients who had previously refused comprehensive orthodontics and had planned veneers. Every single person accepted limited objective treatment (2 to 3 months of aligning the anterior teeth). Then, with simultaneous bleaching, I found an important thing happened: every patient who initially wanted veneers, after straightening and whitening, just wanted to know what I could do about the “irregular edges”. I fixed this with “reverse triangle edge bonding”, a concept I developed to mask joins and make the process simple. “Progressive smile design using align, bleach and bond” without doubt changed the approach of many practitioners in the UK and Europe. Of course, some orthodontists felt that orthodontics should not be something a general dentist performs, and some in cosmetic dentistry feared that this could have an impact on the number of veneers they would place.

With 30 years in one single practice, it is patently clear that early interceptive treatment in cases where bites are deepening, guidance lost, teeth crowding, dentine getting exposed and envelopes of functions constricting – result in much better outcomes for patients you treat versus those you don’t. The latter often end up needing far more complex, expensive treatment later in life. ABB setup for functional and occlusion driven outcomes is the perfect blend of treatment for many of these cases. In my practice, over 30 years, no patient ever went on to develop the need for full-mouth rehabilitation, because I have always used a combination of early interceptive bonding and orthodontics to restore teeth, on patients that I have educated through the use of intra- and extra-oral cameras.

I am hoping that, in the future, research proves this and starts to change our approach to dentistry to a long-term, holistic view of what we can prevent functionally and orthodontically.



Cover image: AGE Solutions S.r.l.  
www.maestro3d.com



**editorial**

The **align, bleach and bond (ABB)**: 03  
its beginning and future  
Dr Tif Qureshi

**case report**

**Laser-assisted** orthodontic treatment 06  
of a **dilacerated impacted maxillary incisor**  
Drs Kazem Dalaie, Samin Ghaffari & Mazir Mir

**Easy clear aligner workflow: A case report** 12  
Drs Ujjwal Pyakurel & Manish Bajracharya

Treating **teen athletes** with **ClearCorrect aligners** 22  
and **DentalMonitoring** to minimise office visits  
Dr Melissa Shotell

**Mandibular advancement with clear aligners:** 28  
Indications and treatment protocols  
Dr Rafi Romano

**Canine substitutions:** Protocols for predictable excellence 38  
Dr Robert "Tito" Norris

**Dental anti-ageing: The interdisciplinary management of** 48  
**complex rehabilitation** with invisible aligners  
Drs Antonello Francesco Pavone, Andrea Bazzucchi,  
Simone Verardi, Alessandro Rampello & Mario Bazzucchi

**feature**

What will be the **new normal** after **COVID-19?** 62  
Jerko Bozиковic

**special**

**Humble Smile Foundation: Fostering equitable oral healthcare** 64  
access alongside **environmental sustainability**  
Nathalie Schüller

The year that was and the **future** that awaits the **ICD** 66  
The International College of Dentists

**meetings**

**EAS** announces programme for **Malta** congress this **October** 68

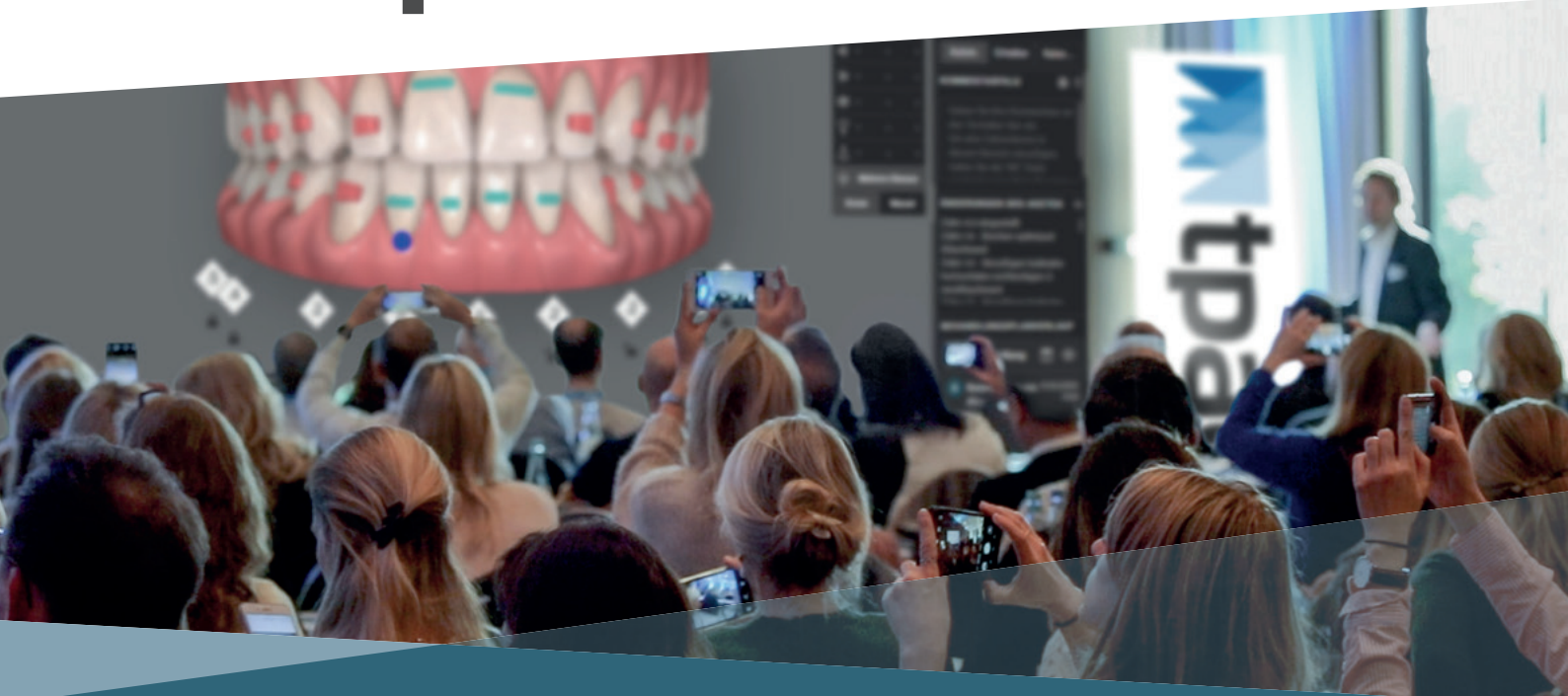**industry report**

**I-liner: Think differently** 70  
Sia Orthodontic Manufacturer

**TPAO**—an aligner congress unlike any other 71  
inviSolution

**about the publisher**

submission guidelines 72  
international imprint 74



# TREATMENT PLANNING COLOGNE 26./27. NOV IN ALIGNER ORTHODONTICS

A unique, interdisciplinary concept: World-renowned orthodontists present their complex case studies. inviSolution's software specialists dissect these cases with regards to each step of the treatment planning involved. All secrets will be revealed. You will leave a true Master of Digital Treatment Planning.



CMDT Matthias Peper • Dr David Raickovic • Dr Sandra Tai • Dr Iván Malagón • Dr Pedro Costa Monteiro • CMDT Björn Reiners  
 Dr Udo Windsheimer • Dr Susana Palma • Dr Enzo Pasciuti • Dr Thomas Drechsler • Dr Boris Sonnenberg  
 Dr Jörg Schwarze • Dr Dietmar Zuran • Dr Mareike Niederwarenbrock  
 Dr Andreas Dasy • Dr Alviano Wagner

More information, registration  
 and **early bird discount\*** at  
[www.tpao-congress.com](http://www.tpao-congress.com)



\*Available until 09/30/2021

# Laser-assisted orthodontic treatment of a dilacerated impacted maxillary incisor

Drs Kazem Dalaie, Samin Ghaffari & Mazir Mir, Iran & Germany

## Introduction

Impaction of the permanent teeth is commonly seen in mixed dentition, especially impaction of maxillary incisors. Disturbance in the eruption of anterior teeth will cause serious aesthetic problems. Given the high importance of treatment of impaction of maxillary central incisors and considering the many advantages of laser application for surgical exposure and acceleration of orthodontic tooth movement, the aim of this paper is to describe the successful treatment of an impacted maxillary central incisor via laser application for surgical exposure and orthodontic traction.

## Case presentation

A 10-year-old boy presented with the chief complaint of delayed eruption of a maxillary anterior tooth. Clinical and radiographic examination revealed impaction of the maxillary right central incisor (Fig. 1), which was horizontally

positioned with a dilacerated root. The maxillary dental midline had deviated owing to drifting of adjacent teeth, especially the maxillary right lateral incisor, into the area of the unerupted tooth.

## Treatment procedure

In the first phase, brackets were bonded on all permanent teeth. After levelling and alignment of the maxillary arch and providing enough space for the eruption of the impacted tooth, a relatively rigid stabilising archwire was placed. Periodontal surgery was then performed for exposure of the tooth. The crown of the tooth was impacted within soft tissue, so there was no need for removal of bone. The procedure was conducted using a 975 nm pulsed laser (LaserHF standard, Hager & Werken) at 3 W and with a duty cycle of 50% and a fibre diameter of 0.4 mm (Fig. 2). The irradiation time was 150 seconds. After removal of the soft tissue, an attachment with a ligature tied to it was bonded to the facial surface of the

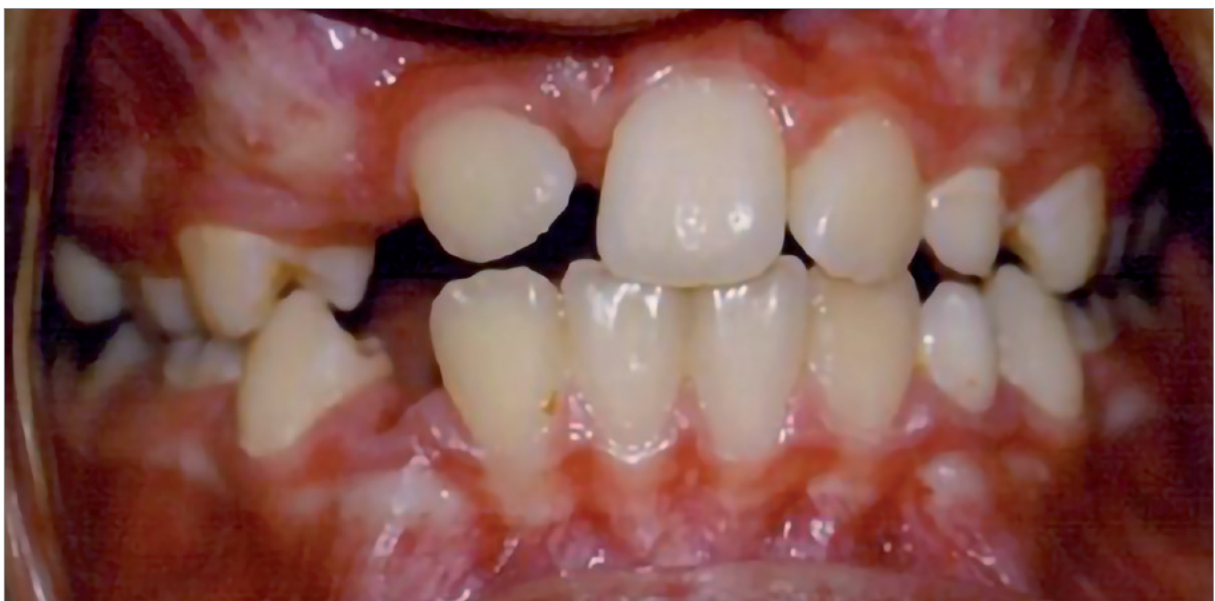

Fig. 1a: Intra-oral photograph revealing impaction of the maxillary right central incisor.

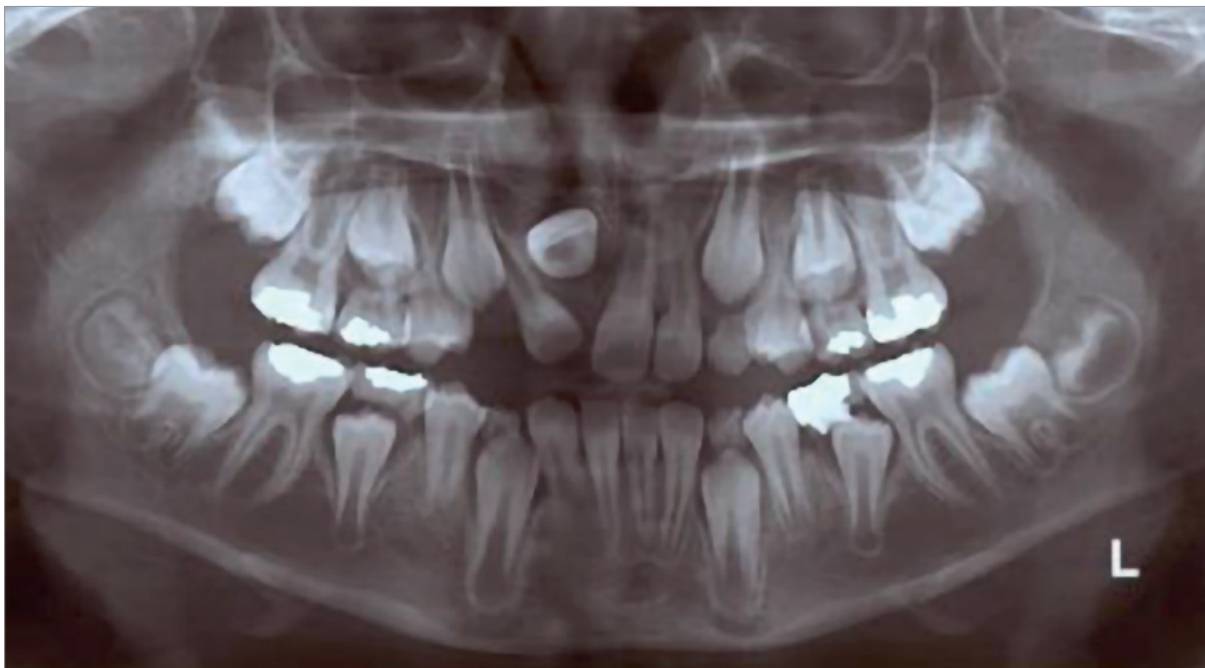

Fig. 1b: Panoramic radiograph revealing impaction of the maxillary right central incisor.

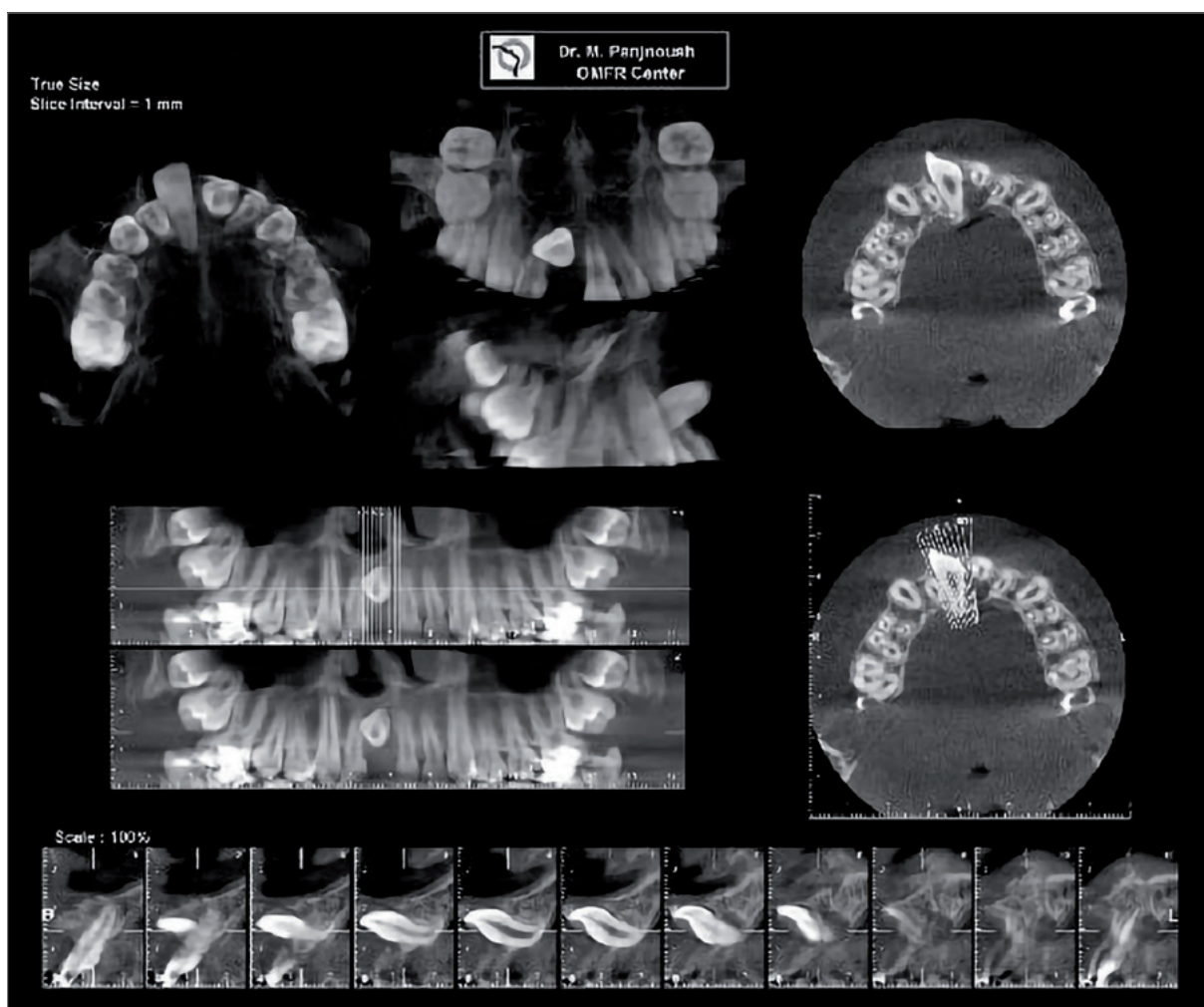
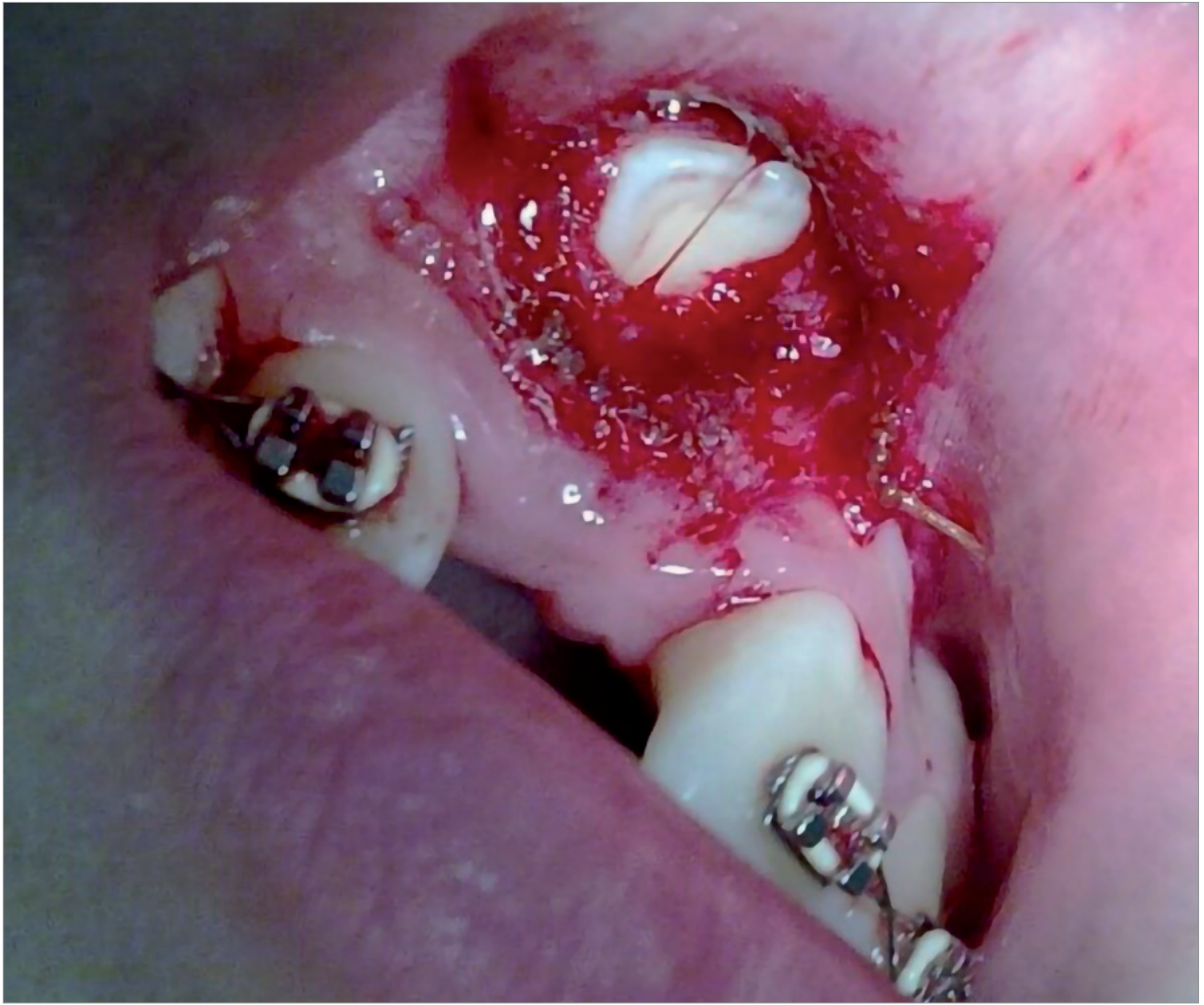
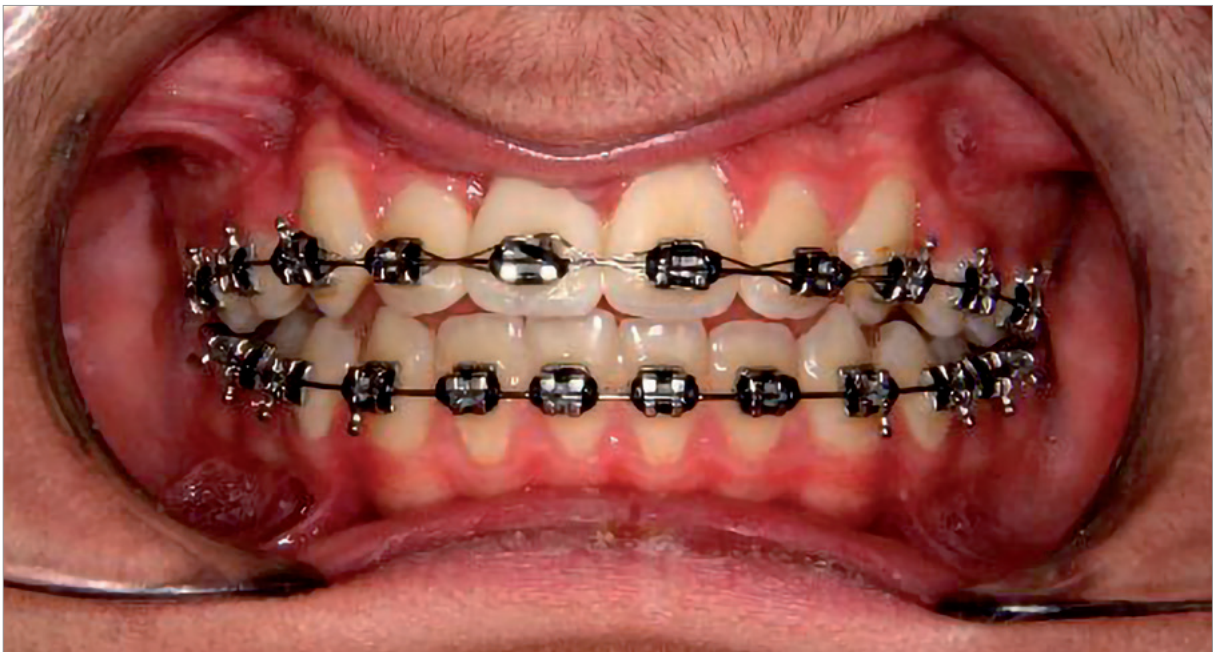

Fig. 1c: CBCT scan revealing impaction of the maxillary right central incisor.

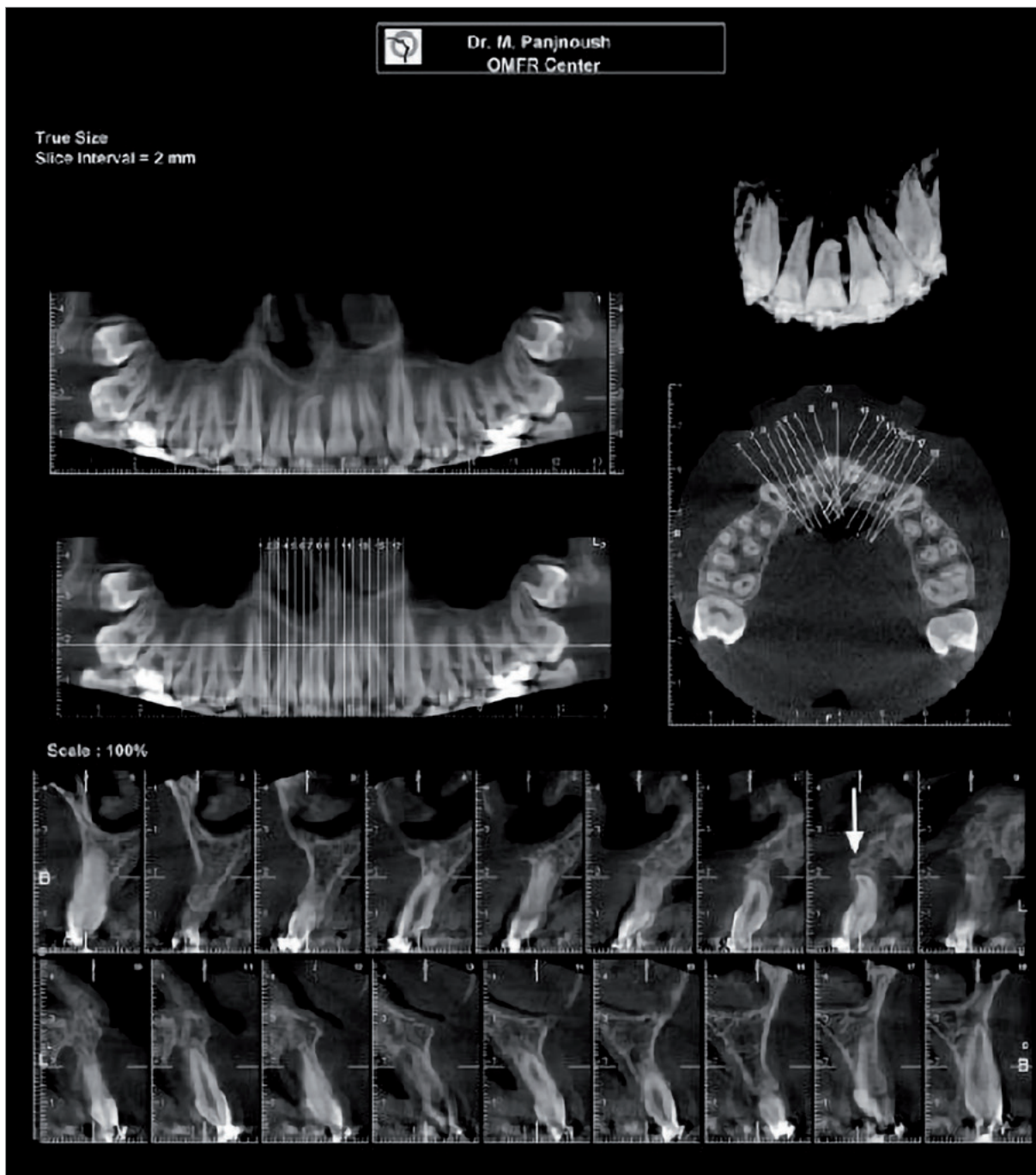


**Fig. 2:** Laser-assisted surgical exposure of the impacted tooth.



**Fig. 3:** Successful eruption and levelling and alignment of the impacted tooth after 15 months.





**Fig. 4a:** CBCT scan showing the proper position of the impacted tooth with a favourable gingival margin, minimal root resorption and an acceptable amount of surrounding bone.