


# implants

international magazine of oral implantology



## research

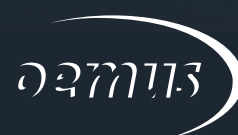Clinical relevance of the use of implant-supported provisional restorations to contour the emergence profile

## case report

All-on-four treatment in an atrophic mandible using dynamic guided surgery

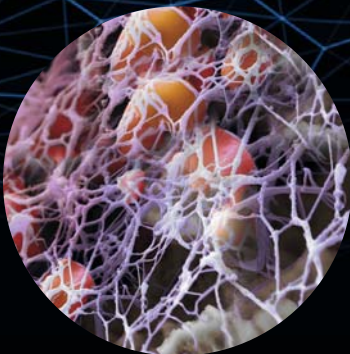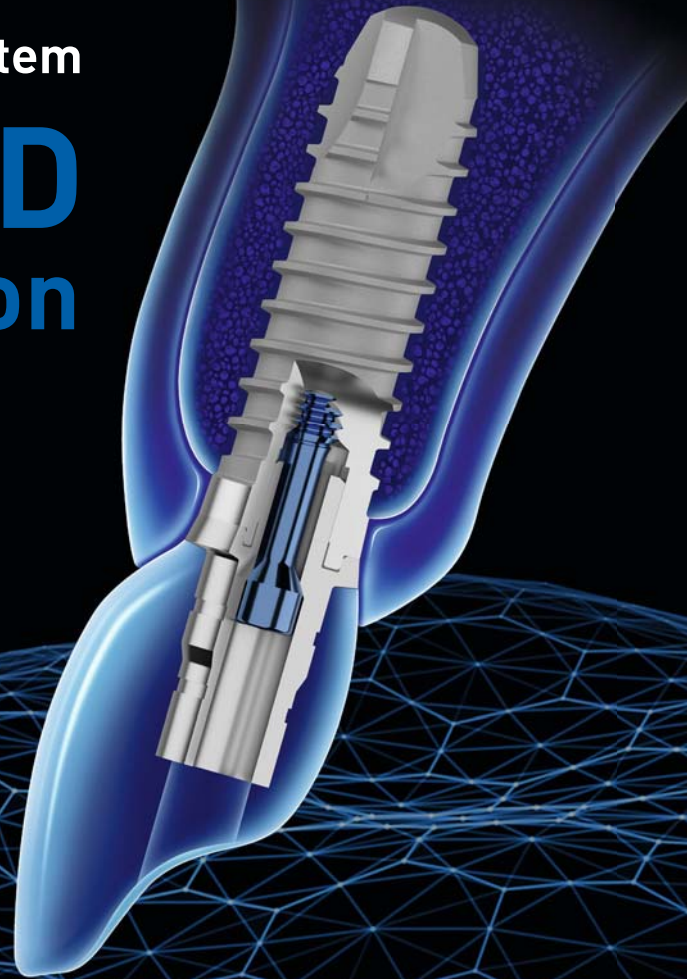## interview

Quality products at accessible prices




The Thommen Dental Implant System

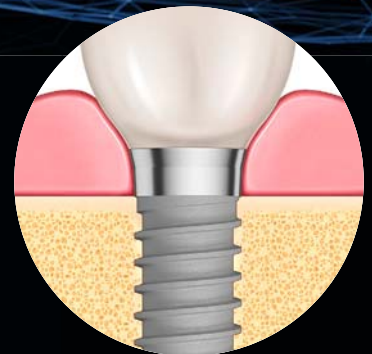
# MULTIGUARD Protection Solution



**INTEGUARD®**  
Matrix



**EVERGUARD®**  
Connection



**TISSUEGUARD®**  
Collar

Driven by science, not trends.

**Dr Rolf Vollmer**

First Vice President and Treasurer of DGZI



## Dear colleagues and friends,

**After a break due to the COVID-19 pandemic**, the annual meeting of the Arbeitsgemeinschaft Dentale Technologie (dental technology working group; ADT) could take place again, and so I and the German Association of Dental Implantology (DGZI) team could participate in this year's event in Nürtingen in Germany. Participants were again able to engage face to face, but online participation was also made possible by the organiser.

The event focused on the ever-increasing importance of digital technology—for dentists and dental technicians alike. One of the most decisive developments in this context is probably digital impression taking. Most of us can say from personal experience that it simplifies processes, and patients would like to avoid analogue impressions. However, despite all the possibilities of digital technology and the efforts by many congress participants to establish these, current developments cannot (yet) completely replace our analogue work. After all, analogue knowledge is of great importance, especially for the further development of technology. It was refreshing to see how, despite these limitations and bureaucratic burdens, dental technicians continue to pursue innovations for the benefit of our patients. We can certainly look forward with anticipation to what digitalisation and further development in the technical field may bring us in the future.

In addition to the digital production of crowns and dentures, the focus was on the materials used for their production. One of the numerous surveys on the experiences of the congress participants made it clear that the majority of the participants — more than 80 per cent — now manufacture crowns and dentures metalfree from zirconia. This topic was also addressed in the discussion

of the S3 guideline of the Deutsche Gesellschaft für Prothetische Zahnmedizin und Biomaterialien (German society for prosthetic dentistry and biomaterials) on all-ceramics, their indications and Regulation (EU) 2017/745 of the European Parliament and of the Council of 5 April 2017 on medical devices. The latter has created a large burden for laboratories in everyday implementation and has meant that many materials have had to be taken off the market for reasons of recertification.

Something new for most of the participants was probably the job description of the dentist, a trained dental technician who is allowed to carry out prosthetic treatments independently in Switzerland, for example. Whether it will be possible for denturists to produce and fit complete dentures in Germany in the future met with a divided response and great contention. There are no legal requirements for such a development at present.

More information about the ADT conference can be found in the editorial section of this issue.

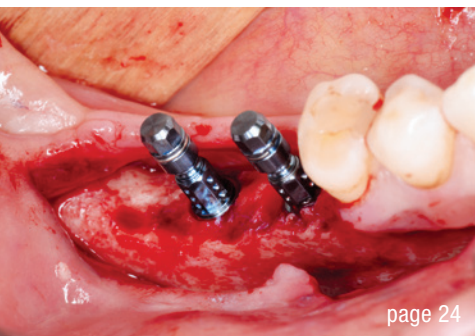
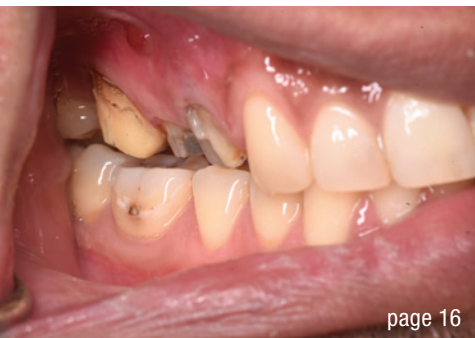Personally, I hope you have had a wonderful and relaxing summer holiday and are looking forward to the DGZI's annual congress in Berlin on the first weekend in October.

Yours,

A handwritten signature in black ink, appearing to read 'R. Vollmer', written in a cursive style.

Dr Rolf Vollmer

First Vice President and Treasurer of DGZI



Cover image courtesy of  
NucleOSS/www.nucleoss.com



**editorial**

Dr Rolf Vollmer 03

**research**

Clinical relevance of the use of implant-supported **provisional restorations** to contour the emergence profile 06  
Dr Marina Siegenthaler

**case report**

**All-on-four** treatment in an atrophic mandible using dynamic guided surgery 12  
Dr Jacques Vermeulen

**Cystic lesion management** with enucleation and reconstruction followed by delayed implant placement for maxillary premolars 16  
Dr Ali Tunkiwalla & Darshan Parulkar

Is **autologous bone** irreplaceable? 24  
Dr Jochen Tunkel

Immediately loaded full-arch restoration on **four implants in the maxilla** 32  
Dr Marco Toia

**interview**

“At Neoss, we have the luxury of being able to be **more forward-oriented**” 34  
An interview with Dr Robert Gottlander

Quality products at **accessible prices** 38  
An interview with Salih Sanli

**industry**

**Driven by science, not trends** 40  
Janine Conzato

**manufacturer news** 41

**events**

Younger and more dynamic and **exciting than ever before** 46  
Janine Conzato

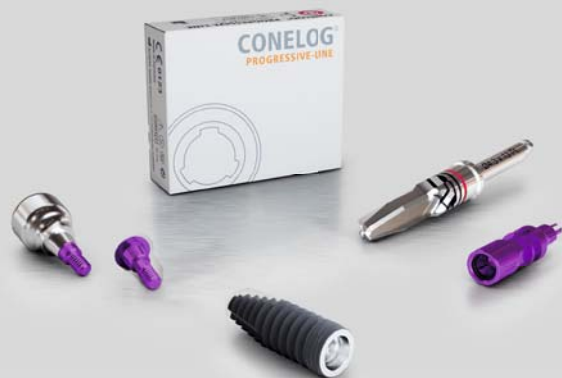**Fifty years of experience**—strategies for the future 48  
Dr Rolf Vollmer

**about the publisher**

imprint 50

TRULY CONICAL PRECISION

**CONOLOG<sup>®</sup>**  
SYSTEM



## CONOLOG<sup>®</sup> PROGRESSIVE-LINE conical performance<sup>1,2</sup> at bone level

### Precise conical connection

- long conus for reduced micromovements
- superior positional stability in comparison to other conical systems<sup>1,2</sup>
- easy positioning with excellent tactile feedback
- integrated platform switching supporting the preservation of crestal bone

[1] Semper-Hogg, W, Kraft, S, Stiller, S et al. Analytical and experimental position stability of the abutment in different dental implant systems with a conical implant-abutment connection Clin Oral Invest (2013) 17: 1017  
[2] Semper Hogg W, Zulauf K, Mehrhof J, Nelson K. The influence of torque tightening on the position stability of the abutment in conical implant-abutment connections. Int J Prosthodont 2015;28:538-41



Oral Reconstruction  
International Symposium

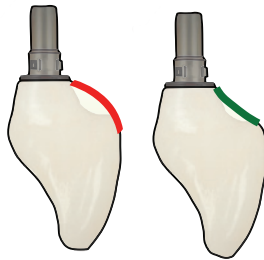
13 – 15 October  
2022, Munich

# Clinical relevance of the use of implant-supported provisional restorations to contour the emergence profile



Dr Marina Siegenthaler, Switzerland

## CONVEX CONCAVE



1

**What shape emergence profile** of single implant crowns is ideal? Does the use of an implant-supported provisional restoration affect the clinical outcome and does its use justify the increase in cost and time?

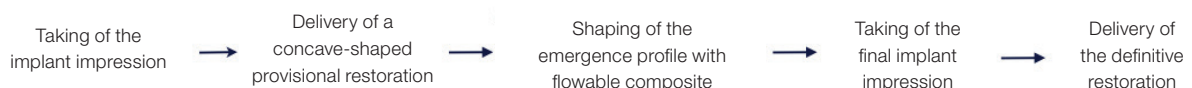
### Introduction

A successful implant therapy is characterised by the maintenance of healthy and stable peri-implant tissues over time. Unless anterior implants are loaded immediately, the time between implant placement and insertion of the definitive restoration demands a provisional restoration in order to increase patient comfort and

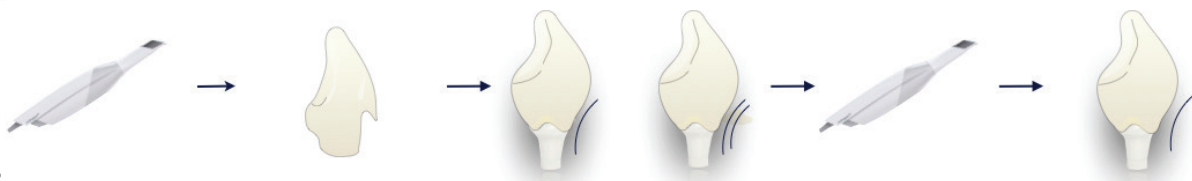
aesthetics. During this period, changes in the peri-implant tissues occur<sup>1</sup> which often result in a reduction of papilla height, an apical displacement of the mucosal margin and a decrease in thickness of the buccal tissue.<sup>2</sup> Subsequent remodelling processes, however, will then lead to an improvement and stabilisation of the peri-implant soft-tissue complex after one year. To minimise these changes and to shape the peri-implant tissue, the use of implant-supported provisional restorations has been suggested.<sup>3</sup> Surprisingly and despite the widespread use of implant-supported provisional restorations in clinical practice, their potential additional value in terms of aesthetic and clinical outcomes has only recently been investigated.<sup>4</sup>

### Implant-supported provisional restorations

Implant-supported provisional restorations are commonly used when two-piece implants are placed in the aesthetic zone, enabling individualisation of the transmucosal, peri-implant mucosa—the emergence profile—in order to better mimic the natural soft tissues and obtain a stable long-term result. These types of provisional restorations have an obvious benefit in function and aesthetics; nevertheless, they do increase the treatment cost and time. Other provisional restorations, such



2





**STRAUMANN  
WORLD CLASS CUP  
2022**



### **CUTTING-EDGE CLINICAL SCIENCE, WORLD-CLASS COMPETITION**

The Straumann World Class Cup is a leading innovative hybrid event that brings together top clinicians from around the globe to showcase their expertise on key topics in dentistry: Immediacy, Regenerative, Digital and Esthetics. From September through December 2022, follow along as 20 teams present high-quality clinical cases over 3 virtual rounds. Straumann World Class Cup culminates in a 4<sup>th</sup> and final round in which the highest scoring teams will compete face-to-face in the **ESTHETIC DAYS** event.

### **HIGH-QUALITY CLINICAL CONTENT IN A FRESH, FUN FORMAT**

Straumann World Class Cup is the premium clinical education event for dental professionals in 2022! Over the course of 4 months 80 experienced clinicians will share their best cases as they compete to win the World Cup.

Twenty teams – each composed of 4 clinicians – will demonstrate their expertise and clinical skill while educating the audience at the same time. Matches will consist of a clinical case presentation by each team that applies evidence-based treatments and showcases valuable real-world clinical applications ready to use in your daily practice. The variety of clinical approaches and topics will open new perspectives and present tools for more efficient and predictable solutions for your patients.

### **EACH ROUND OF MATCHES WILL FOCUS ON A KEY TOPIC IN DENTISTRY:**

- Qualifying Round 1 (Virtual) – September 6<sup>th</sup>–9<sup>th</sup>:  
**Immediacy**
- Qualifying Round 2 (Virtual)– October 4<sup>th</sup>–7<sup>th</sup>:  
**Regenerative**
- Qualifying Round 3 (Virtual) – November 8<sup>th</sup>–11<sup>th</sup>:  
**Digital**
- Final Match (In person) – December 3<sup>rd</sup>:  
**Esthetics**

A jury of 12 world-renowned experts will evaluate the cases and assign points. The winner of each virtual round – and the chance to participate in the final face-to-face match in Palma de Mallorca – will be determined by both the expert jury and audience voting.

To become the winner of the Straumann World Class Cup, the 4 clinicians composing a team will have to work together and indispensable to their success will be the loyal fans back home who engage, share, and vote for their team.

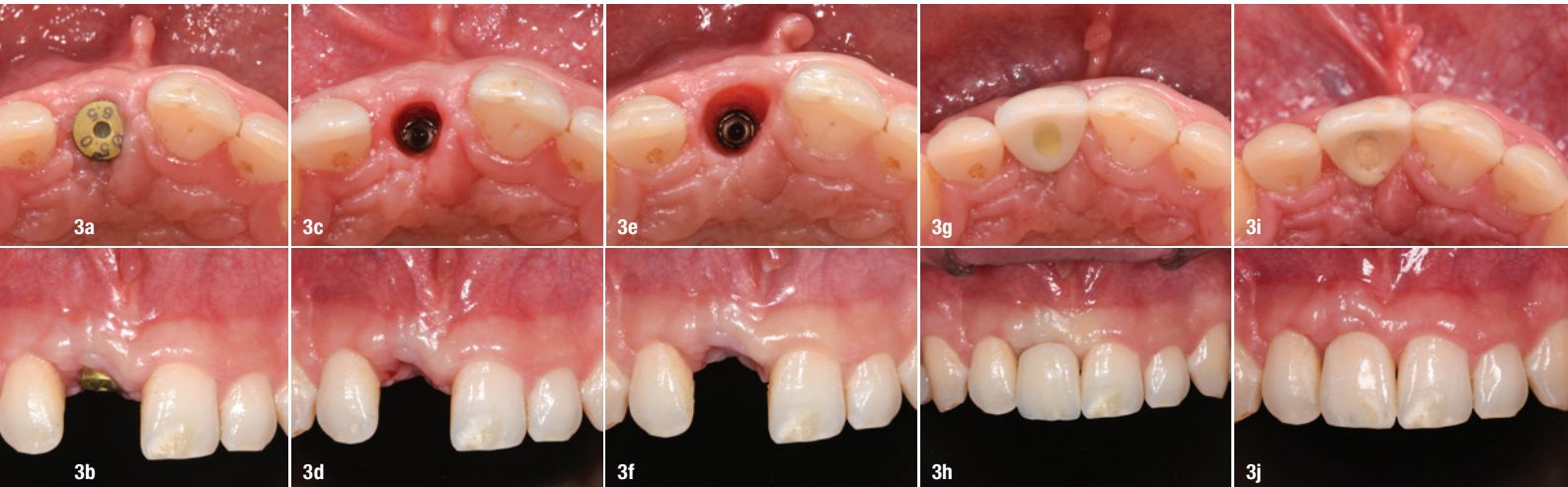
Attractive prizes will be awarded throughout the entire competition to recognize the efforts and skill of as many teams as possible.

Make sure to follow the Straumann World Class Cup online, where scores and team rankings will be available 24/7.

This is the 2022 event you can't miss! Sharpen your skills while learning from the world's finest clinicians in an innovative format. Whatever your level of expertise, you're sure to discover a tip, tool, or treatment approach that you can apply in your own clinical practice.



**REGISTER NOW ON**  
[www.straumann.com/swcc](http://www.straumann.com/swcc)

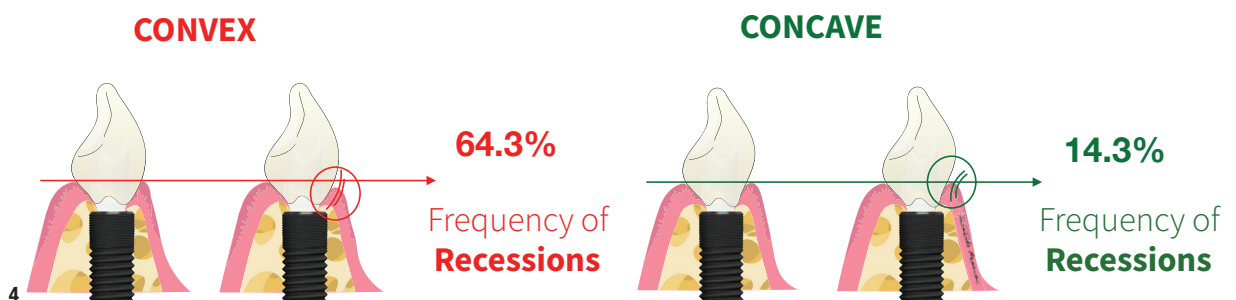


as splints, can be used as cheaper alternatives to using implant-supported provisional restorations, but these do not allow the shaping of the emergence profile. Typically, the shape of the emergence profile of implant-supported provisional restorations is either convex or concave (Fig. 1). However, and despite their wide use in daily practice, the shape that is most beneficial for the stability of the peri-implant mucosa around screw-retained restorations remained unclear. Furthermore, whether the additional investment in time and cost has a clinical impact was uncertain. A recent randomised clinical trial, however, addressed these questions and revealed that provisional restorations had a limited benefit in aesthetic and clinical outcomes.<sup>4</sup>


### Conditioning of the emergence profile

There are different methods available to condition the emergence profile, differing in terms of the number of steps and the resulting shape. The most commonly described shape is a concave shape, allowing space for the buccal soft tissue. Conversely, a convex contour of the emergence profile has been recommended when an implant is placed in a too oral position.<sup>5,6</sup> In order to avoid creating a niche for bacteria and to enable proper oral hygiene measures, a concave contour between the (too oral) implant shoulder and the crown margin is not recommended.

The most commonly used method in clinical practice for shaping the emergence profile is described here. After taking an implant impression, an initially under-contoured, implant-supported provisional restoration is fabricated. The buccal, cervical contour of the provisional restoration already representing the level of the prospective crown margin—usually mimicking the antagonist. This buccal initially sharp contour is filled (usually with a flowable composite) to a concave shape, resulting in slight mucosal pressure that produces local ischemia, which should subside within a few minutes. Selective pressure is added on the mesial and distal aspects to allow for papilla formation. Care should be taken not to apply too much pressure, as this can result in retraction of the tissue, causing recession and, in the worst case, tissue necrosis. The soft tissue is left to adapt, and the process is repeated after approximately one week, shaping the emergence profile further until satisfaction. Typically, two to three appointments are needed. A final implant impression (including the shaped emergence profile) is taken and the definitive restoration delivered according to the previously shaped tissues (Figs. 2–3j). Alternatively, for example in the premolar region, a healing abutment can be individualised in the same manner, avoiding the need for an implant-supported provisional restoration and decreasing costs. The before-mentioned, recent three-arm randomised controlled clinical trial compared the two different emer-








# sharp and deep threads profile

ensures a strong mechanical  
adhesion with bone tissue.  
Provides the high ISOQ values  
required for immediate and  
early loading.



NucleOSS™

**T6**  
torq