


# implants

international magazine of oral implantology



## research

Prevention 0: The best way to prevent peri-implant disease?

## case report

Full-arch implant rehabilitation

## events

1<sup>st</sup> Future Congress sets new standards





GC Implants:  
Quality derived  
from tradition



[www.gctech.eu](http://www.gctech.eu)

**Dr Rolf Vollmer**

First Vice President and Treasurer of DGZI



## We are ready for the future

Dear colleagues,

Our last Annual Congress, which took place under the motto "Visions in Implantology", has shown that there is an ongoing development and significant progress in the field of dental implantology, in particular when it comes to digitalisation. For instance, the accuracy of bone-supported drill templates is constantly improving, whereas the amount of planning deviations is decreasing. Yet, we would be well advised to maintain a critical stance towards our own ambitions. In addition, we should always reassess the large amount of available information, obtained through modern radiology for example, in a critical and realistic fashion. The number of medical mistreatment cases does not decrease as a mere consequence of having a large amount of information and scientific data at our disposal and it would be unwise to believe that. Specialists working in the field of dental implantology, as well as courts are currently dealing with an increasing number of malpractice cases and bad treatment results, which is obviously a global issue. A couple of years ago, Dr Dennis Tarnow complained about the fact that sixty per cent of his new patients, already having implants, were attending his clinic to receive follow-up treatments. It is not without reason that we are facing an increasing number of patients suffering from peri-implantitis today.

So-called peri-implantitis classifications are being introduced at the moment and respective new treatment methods are being proposed by the various scientific associations. Our colleagues who are working in this field deserve the highest praise and our utmost respect. Let's have a closer look at various cases that are being published.

I personally believe that many cases of peri-implantitis are home-grown or lie within the responsibility of the implantologists. To show all of these different cases in their

entirety would go far beyond the scope of this editorial, so let's just name some of the main causes of peri-implantitis: risky implantations in regions with low bone volume, disregard of both the periodontal conditions and underlying general illnesses, disregard of the therapeutic indication or inaccurate positioning, disregard of already established principles and guidelines, inadequate prosthetic care, remaining excess cement, and insufficient education of the implantologist, only to name a few. With regard to aetiology, there are no statistically significant studies yet, and thus further research is urgently needed.

Please consider that there is no technology capable of replacing the human brain and of considering all the vital factors that are necessary to achieve the best possible treatment results for our patients. The fact remains that medical mistreatment has to be avoided by all possible means. In addition, I would argue that a good medical education is the key to preventing mistakes and thus the key to success.

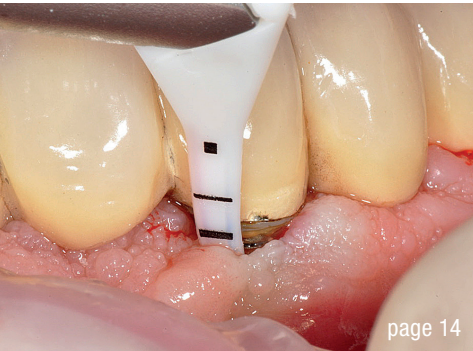There is a new DGZI educational programme for the entire practice team, which is about to be launched. It features a modern training for dental technicians and can be requested at our office in Düsseldorf, Germany. We will be happy to provide you with personal advice and to forward special requests to the respective heads of department.

With this in mind, I remain with best regards and wish you a Merry Christmas and a peaceful new year.

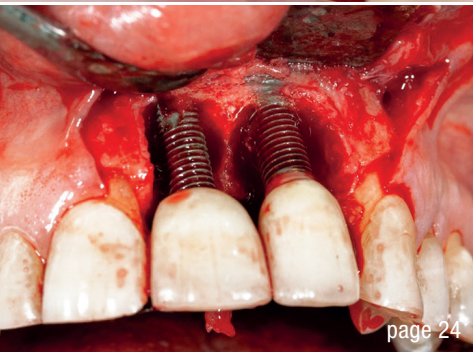
Yours,

A handwritten signature in black ink, appearing to read "Dr Rolf Vollmer".

Dr Rolf Vollmer



page 14



page 24



page 44

Cover image:  
 CONELOG® system by CAMLOG  
[www.camlog.com](http://www.camlog.com)



**editorial**

**We are ready for the future** 03  
 Dr Rolf Vollmer

**research**

**Dental extraction: What else?** 06  
 Prof. Mauro Labanca, Dr Ernesto Amosso,  
 Dr Giuseppe Galvagna & Prof. Luigi F. Rodella

**Prevention 0: The best way to prevent peri-implant disease?** 14  
 Prof. Magda Mensi, Timothy Ives & Dr Gianluca Garzetti

**case report**

**Full-arch implant rehabilitation** 18  
 Dr David García Baeza

**industry**

**Peri-implantitis therapy** 24  
 Dr Fernando Duarte & Dr Gregor Thomas

**Quality seal for dental implants** 28  
 Dr Dirk U. Duddeck

**Connection between periodontal and peri-implant health emphasised** 30

**interview**

**Innovate, educate, inspire** 32

**Mini in size, high in standard** 36

**events**

**Essential guide for clinical practice in implant dentistry** 42

**1<sup>st</sup> Future Congress sets new standards** 44

**news**

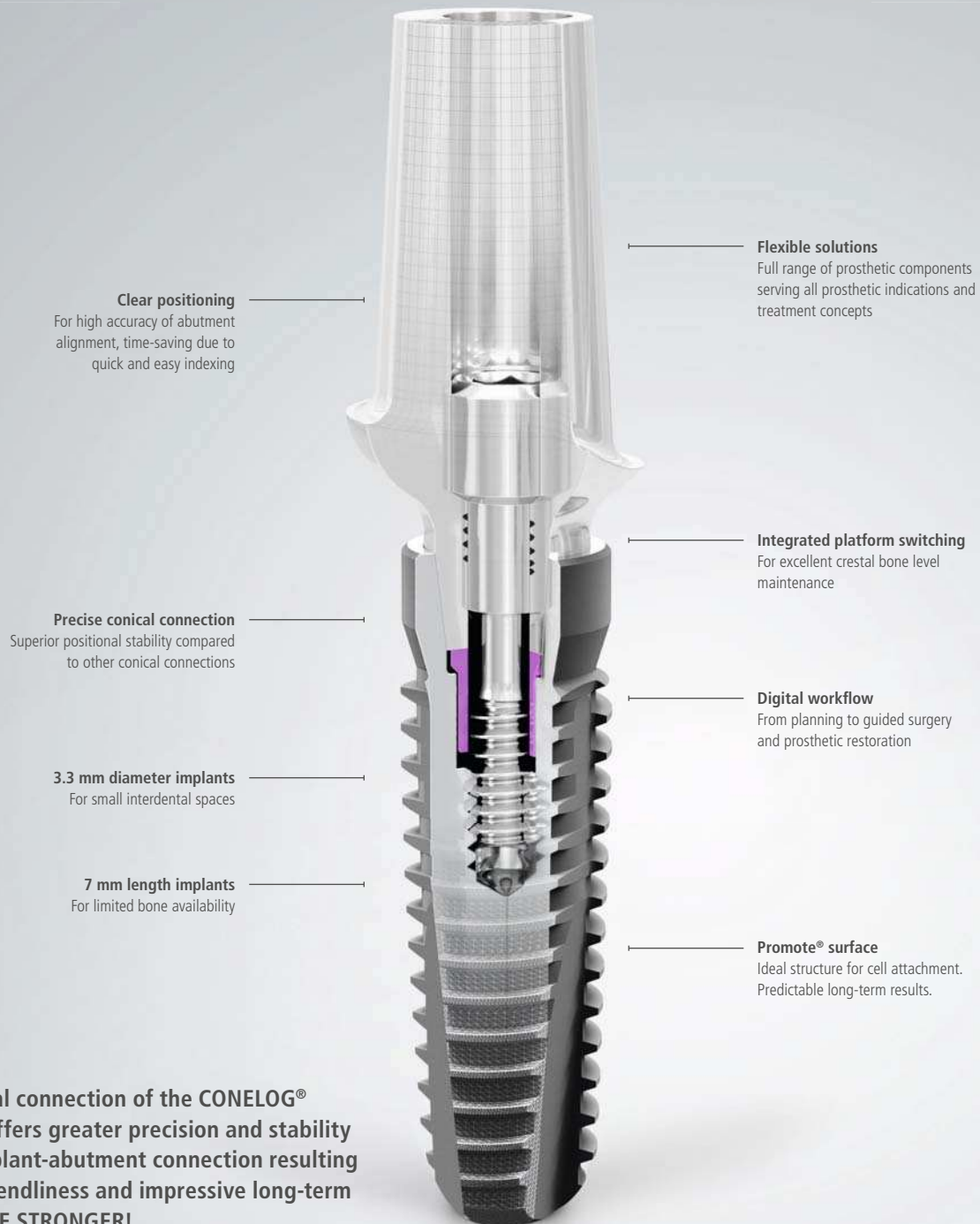
manufacturer news 38

news 48

**about the publisher**

imprint 50

# BE STRONGER!



**Clear positioning**

For high accuracy of abutment alignment, time-saving due to quick and easy indexing

**Flexible solutions**

Full range of prosthetic components serving all prosthetic indications and treatment concepts

**Precise conical connection**

Superior positional stability compared to other conical connections

**Integrated platform switching**

For excellent crestal bone level maintenance

**3.3 mm diameter implants**

For small interdental spaces

**Digital workflow**

From planning to guided surgery and prosthetic restoration

**7 mm length implants**

For limited bone availability

**Promote<sup>®</sup> surface**

Ideal structure for cell attachment. Predictable long-term results.

The conical connection of the CONOLOG<sup>®</sup> implant offers greater precision and stability of the implant-abutment connection resulting in user friendliness and impressive long-term success. BE STRONGER!



Read more here:  
[www.camlog.com/en/whitepaper-conelog](http://www.camlog.com/en/whitepaper-conelog)

# Dental extraction: What else?

Prof. Mauro Labanca, Dr Ernesto Amosso, Dr Giuseppe Galvagna & Prof. Luigi F. Rodella, Italy

**The decision-making process** leading to a dental extraction has changed a great deal in the history of dentistry. We have moved from the concept of elimination of the infective source to one of bone preservation and regeneration of the alveolus. With the advent of modern drugs and the collaboration between different medical specialties, today we can consider extraction to be a totally safe procedure for the patient,<sup>1</sup> even though it should be deferred as much as possible in favour of the increasingly advanced techniques of restoration, recovery or regeneration.

When, unfortunately for the patient, extraction is indicated, how is this situation managed? And what is the deci-

sion tree to which we can refer today? This type of therapy, which is often under-estimated but of relevance to every single dental specialty, and especially important for general practitioners, is too little considered but is of great importance for the patient in the present and the future (Fig. 1).

## Anaesthesia

Anaesthesia is the initial phase of any dental treatment. Often poorly evaluated by the operator, it plays a key role—for more than only clinical reasons—in ensuring greater compliance on the part of the patient. The patient will, in fact, judge the work of his or her dentist almost exclusively on the basis of the pain suffered: first in the

### Decision tree of extraction

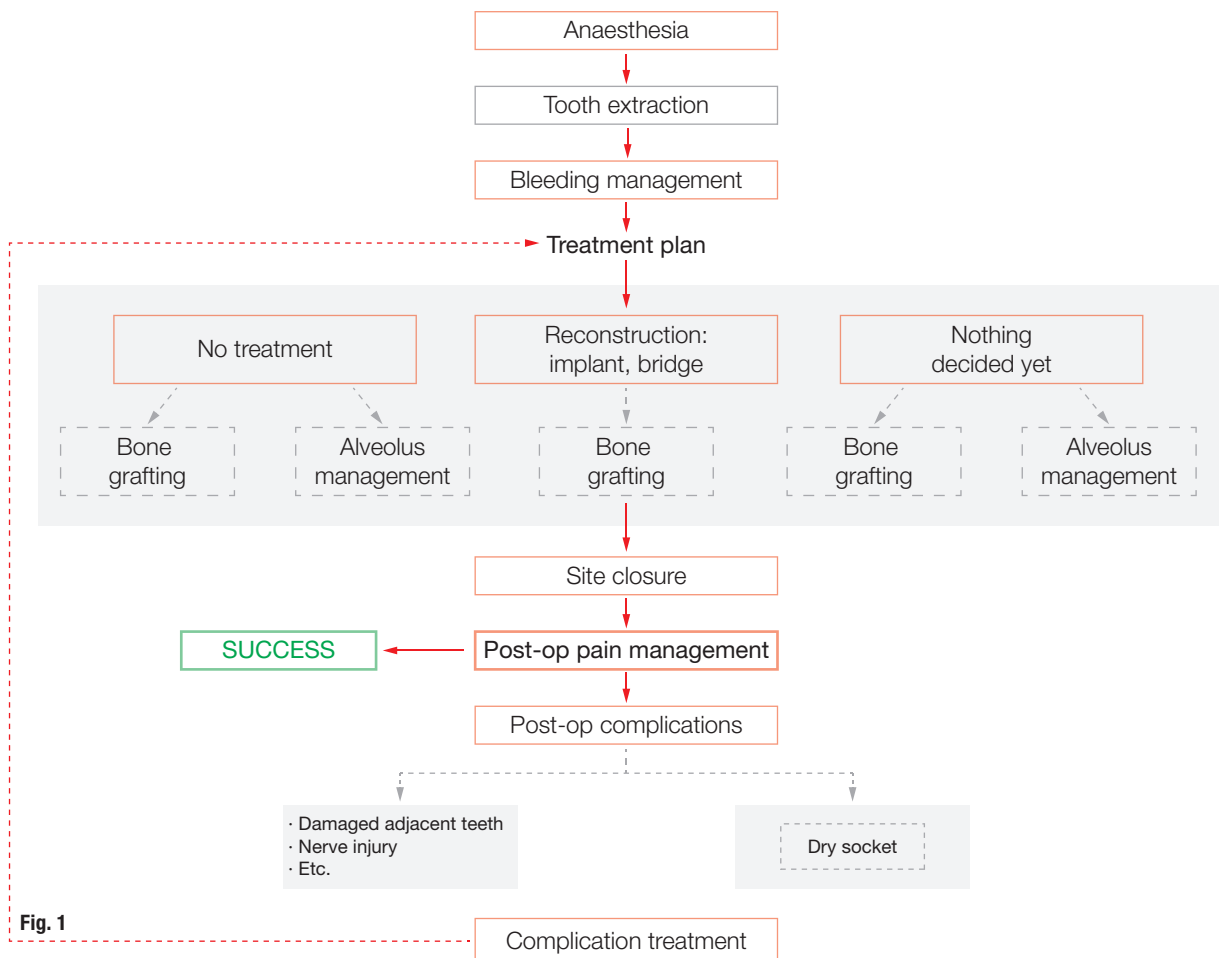
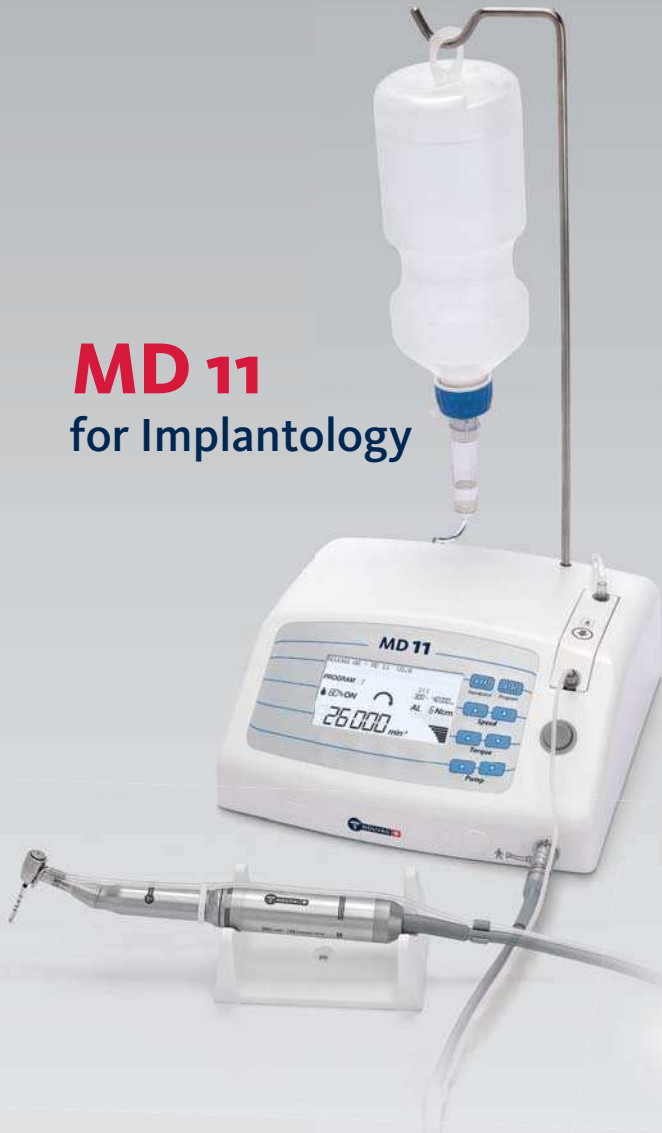

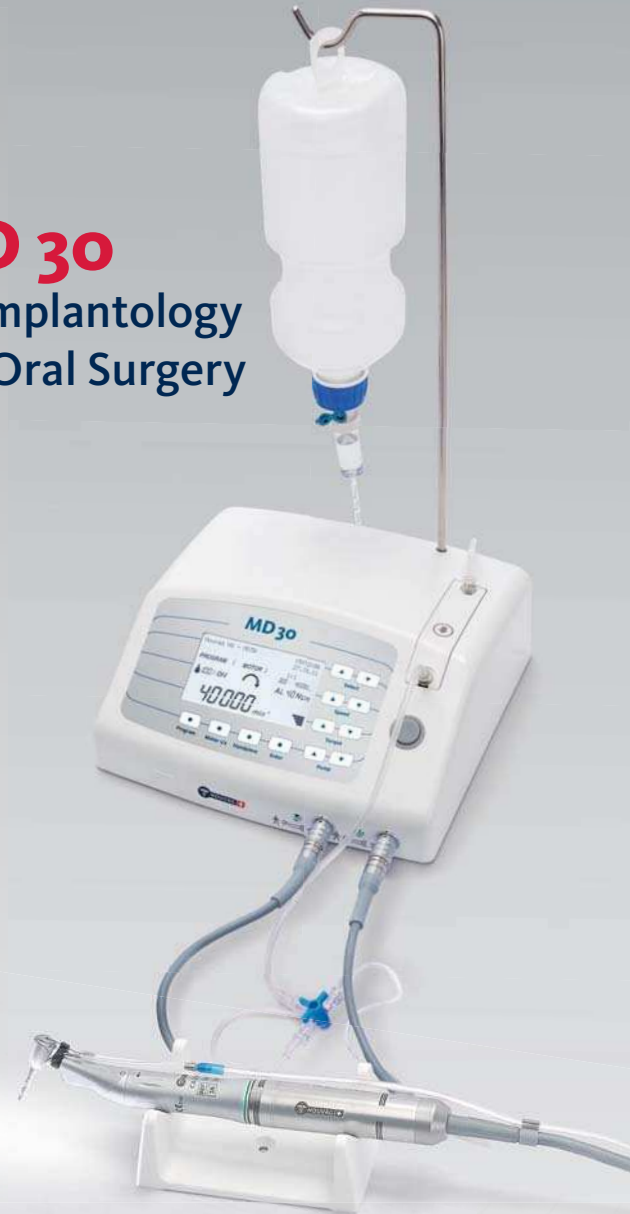Fig. 1

We talk implantology

**MD 11**  
for Implantology



**MD 30**  
for Implantology  
and Oral Surgery



- **Easy** | Simple device setup
- **Strong** | Powerful and smooth motor
- **Reliable** | High quality finish



Scan me to be linked to the Nouvag contact form. ▶



NOUVAG AG · Switzerland  
info@nouvag.com · [www.nouvag.com](http://www.nouvag.com)

injection phase, then with regard to the pain felt during the operation and perceived after any type of treatment.

It is, therefore, essential that a topical anaesthetic is used to make the injection phase as least unpleasant as possible and that the injection is performed by applying the right pressure, so as not to overstretch the tissue (a cause of pain in itself) and in the right anatomical site (Figs. 2 & 3). Moreover, the recommended injection time is 1 ml/minute. Nevertheless, 84 per cent of dentists inject 1.8 ml in 20 seconds or less.<sup>2</sup> A compound suitable for the planned intervention must be used in terms of duration of its action and, therefore, of effectiveness, paying attention also to the quantity of vasoconstrictor present and the overall patient condition.

As far as the compound to be used is concerned, the absorption time and the duration time must, of course, always be carefully considered, and this must not be arbitrary, but linked to the type of extraction planned, in order to always have the most adequate pain coverage not only during the operation but also in the immediate postoperative period.

Articaine is one of the most recently developed local anaesthetic drugs available to dentists worldwide and the most widely used local anaesthetic in Europe. Articaine is closer to physiological pH and therefore its onset is quicker. Owing to its higher lipo-solubility, articaine is a potent dental anaesthesia molecule, and it has a longer duration than lidocaine owing to its higher protein binding. Being both an amide and an ester, its degradation starts as soon as it reaches the bloodstream, its metabolism is quicker and, therefore, it is safer to use. It has the lowest systemic toxicity, which is why it can also be used during pregnancy.

Lidocaine is one of the most widely used anaesthetics even though there are several other compounds of comparable efficacy; these drugs differ in terms of pharmacokinetic parameters.

For long procedures, bupivacaine is the most logical choice for its long anaesthetic duration in soft tissue, although, according to some studies, it is also the most painful during injection.<sup>3-6</sup>

It should be remembered that the presence of a vasoconstrictor is often fundamental not only for good control of haemostasis, but also and above all to antagonise the vasodilatory effect induced by any local anaesthetic. Inadequate use of the vasoconstrictor can make a simple extraction complex if the haemostatic effect is not induced. Indeed, the administration of a high concentration of vasoconstrictor (with the local anaesthetic) if used in an inappropriate manner (for example with an intraligamentous procedure) can create severe compli-

cations. For instance, that might contribute to the onset of dry socket, which could possibly result from an excessive vasoconstriction induced in the area of the intervention along with other possible factors.

## Extraction and management of the alveolus

After having carried out adequate anaesthesia, the tooth or root can be extracted as planned. And obviously, as indicated, the dentist's choice regarding the treatment of the post-extraction alveolus will reflect what needs to be done in the site involved in the extraction.

After extraction, dimensional and aesthetic changes to the oral tissue occur. For this reason, it is important to contextualise the procedure (if it is not urgent) within a broader treatment plan.

The reasons for an extraction can be numerous. According to the directives of the Società Italiana di Chirurgia Orale ed Implantare (Italian Society for oral and implant surgery), the indications that lead to the decision to extract a tooth are as follows:

- the presence of ongoing dental caries that has led to a widespread destruction of the dental crown, affecting the gingival margin and making it impossible to recover the element;
- irreversible apical lesions;
- serious periodontal disease with non-reversible alveolar bone loss;
- fractured roots;
- orthodontic treatment;
- dysodontiasis of the third molars;
- management of infectious loci in patients having to undergo radiation therapy;
- immunodepressed patients;
- patients having to undergo treatment with bisphosphonates or anti-coagulants of the latest generation; and
- impacted teeth or continued presence of primary teeth in the mouth.

Once the extraction has been carried out, it will then be possible to opt for:

1. an immediate regenerative treatment;
2. a delayed regenerative treatment; or
3. no treatment.

The preservation of the alveolar process after a dental extraction is recommended to preserve the bone's volume and the soft tissue over it and to simplify the subsequent rehabilitation. It has been widely illustrated in the literature that, every time a dental extraction is carried out, a restructuring of the bone takes place in the site of extraction, leading to a decrease in volume, accompanied by qualitative and quantitative changes that affect the result of a prosthetic rehabilitation, especially if it is the anterior zone that is affected, which is further impacted



by the significant aesthetic changes.<sup>7,8</sup> It should be remembered that, with the extraction of a tooth, the periodontium is eliminated and with it the rich vascular network that characterises it. The supply of blood and lymph is essential for the turnover of the gingival cells and of the periodontal ligament itself, and even if to a lesser extent, it also contributes to the nourishment of that portion of bone close to it. Another determining factor for bone resorption is the surgical technique that is adopted during extraction; indeed, if a full-thickness flap is raised, the blood supply in the external cortex is interrupted, inducing a remodelling of the affected area.

We should stress that the alveolar bone is a structure that is closely linked to dental survival, and it undergoes important changes where the latter is absent. There are numerous studies that show that the greatest reduction in bone volume occurs mainly in the first three months, continuing in lower percentages in the first year after surgery.

In the first six months, the volumetric variation is quantifiable as 3.80mm in width and 1.24mm in height, with displacement of the crestal profile by two-thirds with respect to the original position.<sup>7-13</sup>

Based on an analysis of correlation, the vestibular thickness of the bone wall of less than 1 mm has been identified as a critical factor associated with the extent of bone resorption. The thin-walled bone phenotype shows significant bone resorption with mean bone loss of 7.5 mm compared with the thick-walled bone phenotypes, with a predicted loss of 1.0 mm.

### Benefits of a bone grafting material

Studies conducted on samples of patients who had to undergo dental extraction have confirmed that the placement of biomaterials in the alveolar site immediately after extraction, compared with the samples where nothing was inserted, showed a significant reduction in the reshaping process, with preservation of the bone volume after healing, validating the concept of ridge preservation.<sup>7-14</sup>

It has been demonstrated in numerous histological studies carried out on different samples of bone taken from sites treated with different types of biomaterials,<sup>15, 16</sup> that beta-tricalcium phosphate is one of the few synthetic materials to be completely resorbable, with no trace remaining one year later in any of the samples examined. Moreover, an improvement of between 6 and 23 per cent was observed in the receiving site compared with the sites treated only with the presence of the coagulum (Figs. 4-12).<sup>13</sup>

Recently, in a systematic review, Ten Heggeler et al. demonstrated that the use of biomaterials in the post-extraction site resulted in alveolar volume preservation

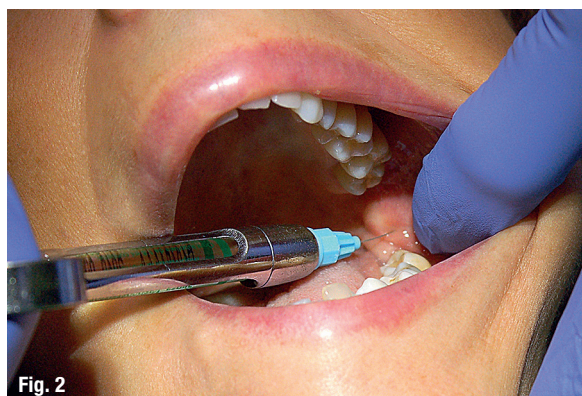

Fig. 2

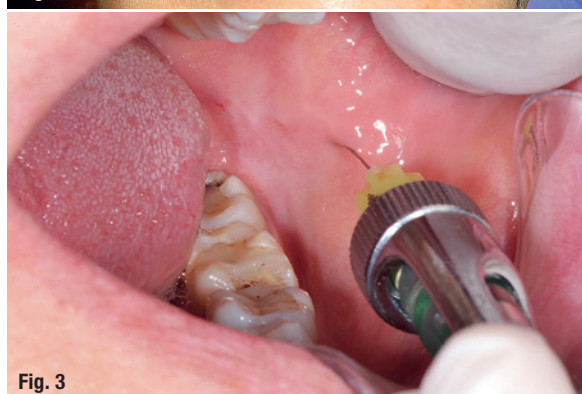

Fig. 3

**Fig. 2:** Anaesthesia administered to the alveolar inferior nerve. **Fig. 3:** Anaesthesia administered to the buccal nerve.

during healing.<sup>17</sup> It should also be noted that alveolar sites filled only with fibrin sponges do not register any significant improvement.

The technique of preserving the extraction site thus has proved to be effective both in minimising the resorption of the bone tissue and in expanding the bone volume for subsequent treatment with implants.<sup>18, 19</sup>

In some situations, when there is no implant or regenerative intervention planned directly after the extraction, it may be necessary and appropriate to control the haemostasis and the flap closure in an appropriate manner, in order to make the postoperative phase easier and thereby reduce the risk of infection of the site or the onset of dry socket. The control of haemostasis will be important, but at the same time, it will be essential for the dentist to verify at the end of the extraction that there is bleeding in the post-extraction alveolus. In case of a lack of bleeding, the site must be freshened in order to ensure the fundamental blood supply necessary for full healing of the site. A lack of spontaneous bleeding could instead be prodromal to a dry socket.

### Bleeding management and collagen sponges

Several risk factors associated with post-extraction dental complications, including age, gender, drugs, ex-