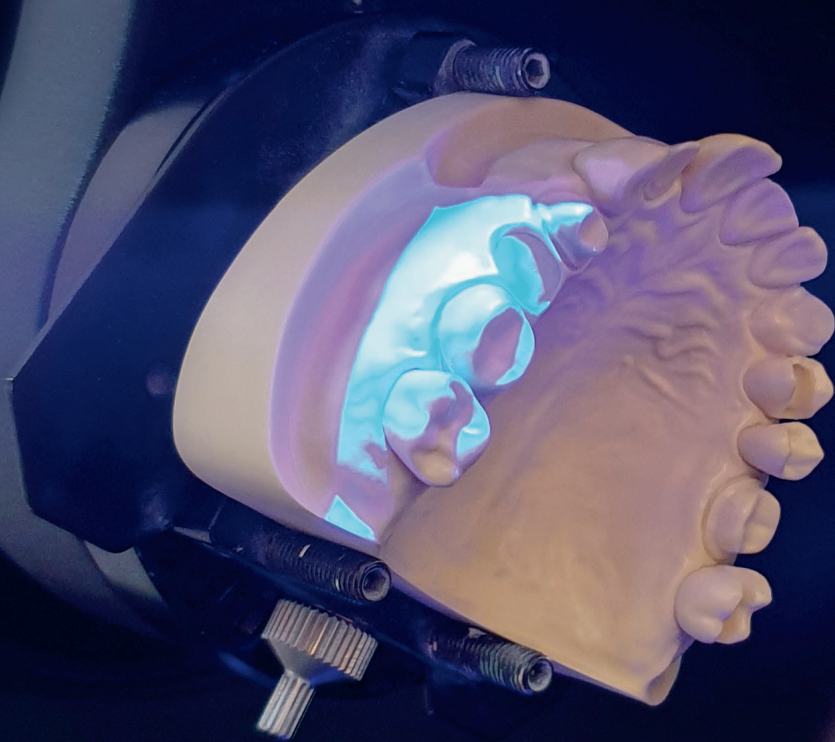

digital

international magazine of digital dentistry



research

The diode laser
in a fully digital workflow

case report

Digital procedures for the design
of a sequential occlusion

interview

How 3D printing has transformed dental care



2D & 3D
exams

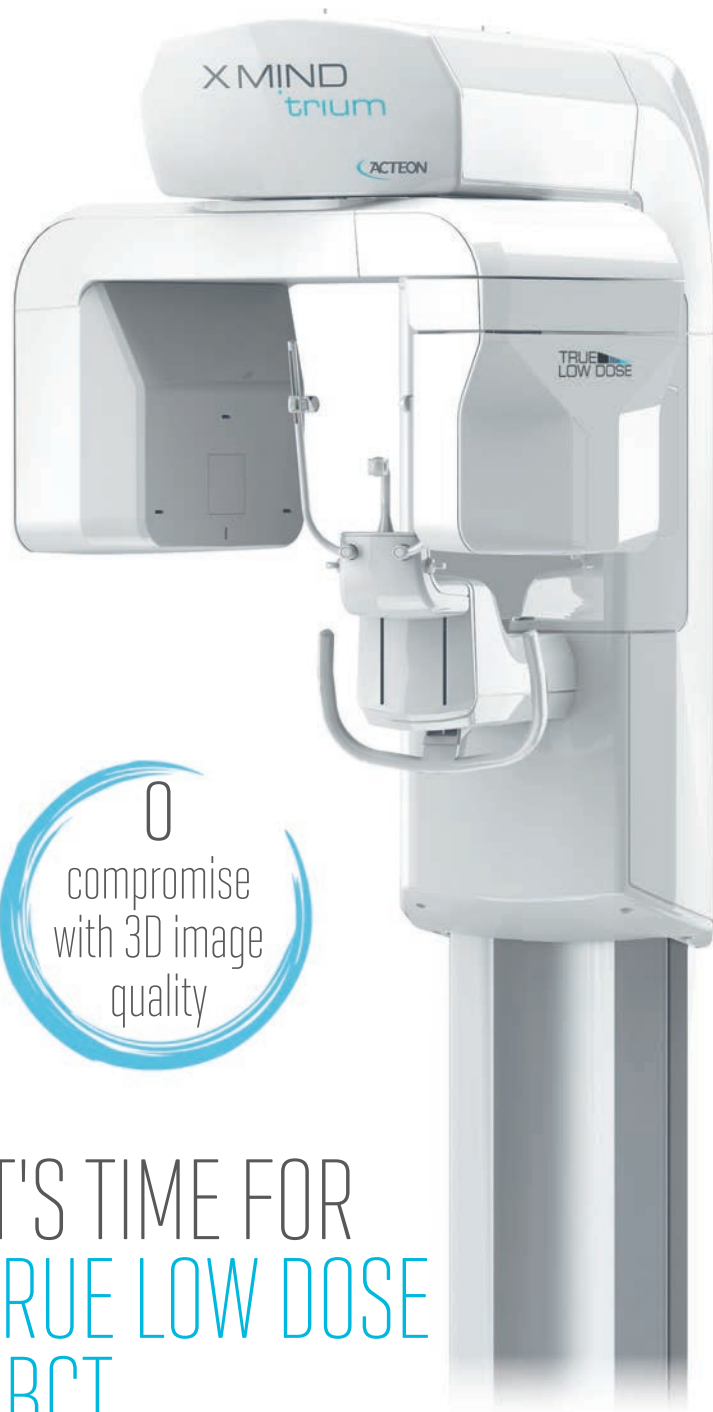MAC
Compatible

75 μ m
High resolution
image

up to
50%
dose reduction

1 MINUTE
implant planning
report

0
compromise
with 3D image
quality



IT'S TIME FOR
TRUE LOW DOSE
CBCT

Dr Scott D. Ganz

Editor-in-Chief



Holiday season 2020—normalcy

We are now in the last month of 2020, and the outlook for 2021 is still not clear. The current pandemic still has a grip on countries around the globe, making it difficult to travel, host and attend educational meetings and symposia, or even visit with our family and close friends. We can only hope that help is on the way with vaccines that are effective and safe, allowing us to return to a sense of normalcy and confidence. In our world of dentistry, we have always maintained a high level of infection control for our patients and staff, and we have always worn protective masks, shields and gowns. Of course, today, we are all taking extra precautions to ensure that we can deliver care in the most effective and efficacious manner. Therefore, dentistry will remain vital, important and essential to the health and welfare of the population worldwide.

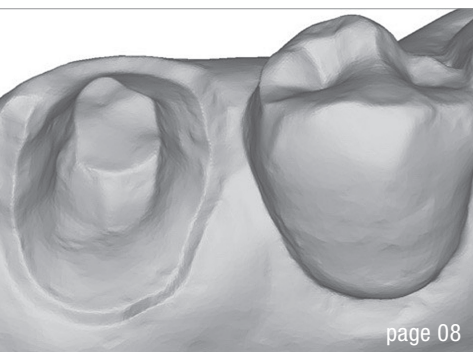
The COVID-19 pandemic has focused the globe on communicating remotely, whether it is with our family or our colleagues. Our new normal may not allow for in-person meetings in the foreseeable future, which means that our educational opportunities will need to be visualised on a computer screen, tablet or smartphone. For many educators, this will require a somewhat different skill set, in terms of delivery, presentation materials, and the use of videos and animations which may or may not reproduce satisfactorily, depending on the speed of internet or Wi-Fi connections. Additionally, it is an entirely different experience when one is presenting alone in a room facing a video camera where there is no direct feedback from what it is when speaking to a small group of clinicians or from a larger podium at a major conference. Our educational experiences will therefore become a modified reality for both the recipients and those delivering the content. Clinicians who were forced to close

their practices may have elected to spend more time online reading and watching educational videos, gaining important insights from experts around the globe. Similarly, we might even predict that during government sanctioned lockdowns authors from around the globe may have taken the required time away from their offices to write new articles or textbook chapters or to prepare new lectures, videos or webinars.

What has *not* changed are the numerous publications which will continue to deliver excellent content on a wide range of subjects, research and general interest topics. We are fortunate that the pages of our publications are made possible through a digital medium using software applications like Microsoft Word to compose the text and image editing software to prepare illustrations or clinical photographs for print or online presentation. All submissions are submitted online in a digital format. The articles are then compiled, reviewed, edited and then, once approved, sent for final layout to be approved prior to publication. We are fortunate that even during the pandemic the various offerings from Dental Tribune International have continued to provide high-quality content of interest to our readership. We thank you for your patronage and appreciate your dedication to our chosen profession through our offerings. We also want to thank all of our incredible contributors, who spend countless hours documenting and preparing the manuscripts that you find within the pages of **digital**.

Wishing everyone a very safe holiday season and a happy new year!

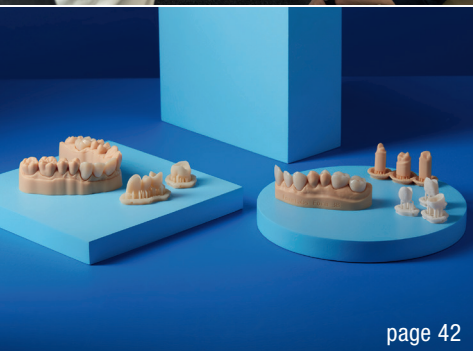Dr Scott D. Ganz
Editor-in-Chief



page 08



page 38



page 42

Cover image:
Tennisfitball555/Shutterstock.com



editorial

Holiday season 2020—**normalcy** 03
Dr Scott D. Ganz

feature

Cooperation is key 06
An interview with Giuseppe Romeo

research

The diode laser in a fully **digital workflow** for **prosthetic** treatment 08
Dr Carmine Prisco

case report

Digital procedures for the design of a sequential occlusion **in a complex clinical case** 12
Dr Mario Perotti, Maurizio Melano & Marco Marzolla

Guided applications for partial extraction therapy 22
Drs Scott D. Ganz & Isaac Tawil

Fully validated digital workflow with Straumann CARES Digital Solutions and coDiagnostiX 30
Dr Ferit Bayram

industry report

KATANA **Zirconia Block: Useful tips** for processing 34
Mathias Fernandez Y Lombardi

interview

DEDICAM: Clear concepts at maximum **flexibility** 38
An interview with Jörg Elbel & Martin Steiner

High-quality dental treatments with CAD/CAM technology 40
An interview with Janne Ruokola

How 3D printing has transformed **dental care** 42
An interview with Georgio Haddad

news

Study highlights benefits of **in-house 3D printing** for immediate dental implant placement 44
Iveta Ramonaite

meetings

Dentsply Sirona sets new standards in **digital dental events** 46
Jeremy Booth

about the publisher

submission guidelines 48
international imprint 50


IT'S SIMPLE
WHEN YOU
HAVE ALL THE
OPTIONS



MIS® | C1

THE CONNECTION FOR PREDICTABLE BIOLOGY. **MAKE IT SIMPLE**

The MIS C1 conical connection implant system offers uncompromising accuracy, with high initial and biological stability and a safe, yet simple, procedure. A consistent concave emergence profile of the C1 prosthetic components improves soft tissue esthetic results. Learn more about the C1 implant and MIS at: www.mis-implants.com



Cooperation is key

By Iveta Ramonaite, Dental Tribune International



Giuseppe Romeo is of the opinion that dental technicians need to have an open conversation with dentists to promote future cooperation. (Image: © Giuseppe Romeo)

Giuseppe Romeo is a dental technician and owner of a prosthetic dentistry laboratory in Turin in Italy. In this interview, he speaks to Dental Tribune International about how COVID-19 has affected his work in the laboratory and about the impact that the pandemic has had on his personal and professional life.

Mr Romeo, could you tell us a bit about yourself and your work in general?

My situation is unusual because I'm based in Turin, but I was born in New York. I lived in the US for the first five years of my life. Then we moved to Italy because my parents decided to come back here. I received my education as a technician in Italy, and after I finished my five years of school, I moved to Switzerland and did a two-year master's degree at the University of Geneva. During that time, I had the possibility of working with Dr Pascal Magne, Prof. Dr Uls Belser and Didier Dietschi, and had the chance to work in Michel Magne's laboratory. Michel was not only my professor but also my mentor, my teacher. I worked with him for ten years. After that, I moved back to the US and stayed in Los Angeles for five years, working at the University of Southern California for three of those years. During my time in the US, I had the opportunity to become an assistant clinical professor in restorative science. And then, at the beginning of 2015, I came back to Italy.

It is safe to say that COVID-19 took everyone by surprise and that its suddenness left no time for preparation. What was your initial response to the pandemic and the confinement measures ordered by the authorities?

Yes, it was a strange time for me as well. I was completely astonished at the pandemic taking place all around the world. I stopped travelling immediately, and this was a big change

for me. I love travelling, and I go see patients and dentists in different countries. Here in the laboratory, we had to pay close attention to proper disinfection procedures and to learn how to best deliver the cases. Fortunately, not all the dentists that I work with had to close their offices. I continued to work in the laboratory during the lockdown in Italy. Everything had to be customised, very well disinfected and boxed differently than before.

There is still a lot of uncertainty about the post-COVID-19 era in dentistry. As a dental technician, do you feel optimistic about the long-term changes the pandemic may produce in dental laboratories and the dental field in general?

I know that most of the clinical offices still don't have the same volume of work, since they can't see the same number of patients a day. This reduced number of patients has subsequently reduced the quantity of work, and this has been reflected in the dental laboratory. Dental laboratories have the same problem because they are the mirrors of the clinical office, of the current state of affairs. In my case, because I specialise in veneers and the aesthetic zone, employing the precision of the microscope, I still had some requests coming in because some patients and dentists still appreciate the quality of my work. Compared with the big laboratories, COVID-19 hasn't affected work in my laboratory much. Big laboratories focus on production volumes. Mine is a small laboratory—there are three of us, sometimes four—and so the quantity of the work and the quality of the work are completely different from that of big laboratories.

Lastly, there's a lot of discussion around the mental health of dentists and dental technicians at the moment. Has the pandemic affected you personally?

I can tell you that I have a lot of defects as a person, but one of my strengths is that I always seek to rise to the challenges of life and that I'm always thinking positively. I try to talk with dentists and other people and to stay active in my job and my relationship with dentists and their patients. That is why I don't think that COVID-19 will affect me in the future because I'm still working every day and I can see the result. This is what we have to go through right now, and we have to stay humble. We have to fight every day and we can't surrender. I think that we can find a solution because dentists want to have a conversation with dental technicians in order to understand and address the situation. I have to admit that I had to lower the price for some cases, but it was not damaging for me. It helped me to have a better relationship with the dentist and the patient. So when dentists and patients realise that a dental technician is open to creating something for the future, I think that there is a good possibility for better future cooperation.

MAESTRO 3D

Innovative solutions for dental applications

www.maestro3d.com



2 x 5.0 MEGAPIXEL

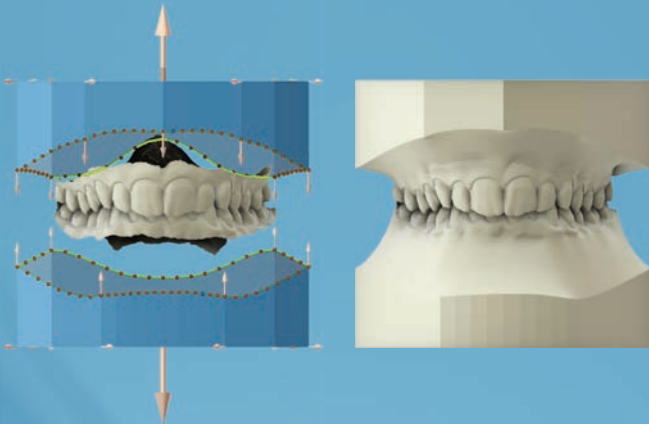
Plug & Play 

Smart Impression Scanning

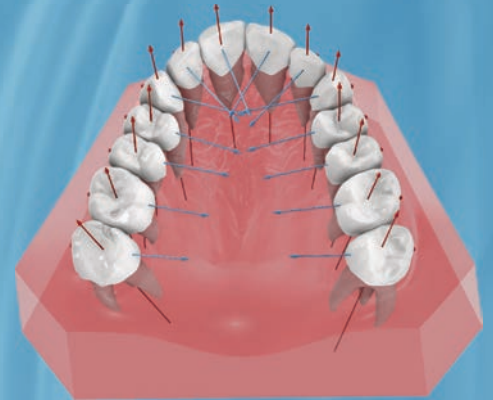
Accuracy less than 8 micron

Texture Superimposition

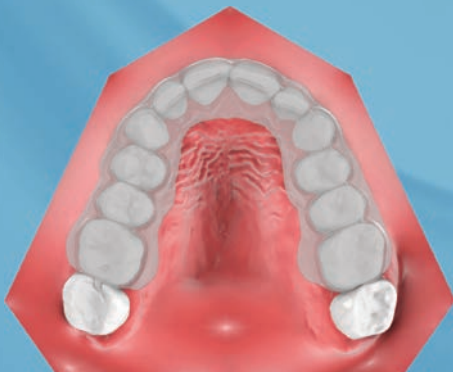
Study Models



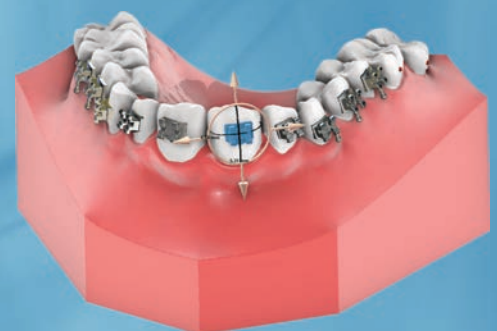Virtual Setup



Clear Aligner

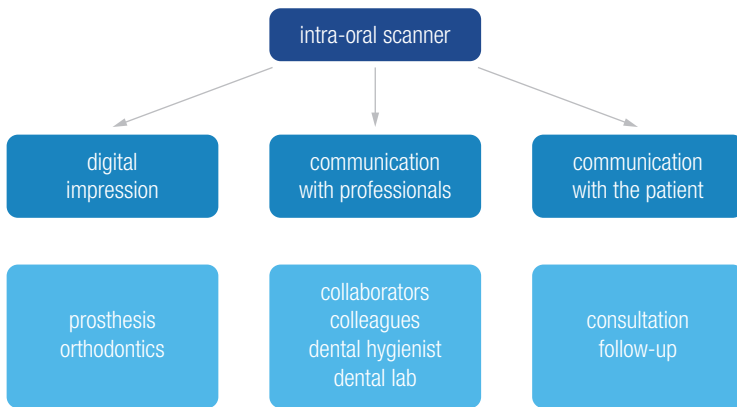


Indirect Bonding



The diode laser in a fully digital workflow for prosthetic treatment

Dr Carmine Prisco, Italy



the most widely used technology in the modern dental practice

Fig. 1: The intra-oral scanner is the most widely used technology in today's dental practice.

Modern dentistry has undergone an incredible evolution owing to the many new available technologies. The digital transformation and the technological evolution in dental surgery represent a very interesting opportunity for the modern dentist to develop his or her practice. Technologically supported dentistry is completely oriented towards patients' needs, well-being and comfort. Reduced treatment times, minimal invasiveness and better care with predictable results are the guiding

principles.¹ A fully digital workflow in prosthetic dentistry respects these principles. The purpose of this article is to show how the use of a diode laser can be integrated into the procedures of a fully digital workflow to make it more effective, simpler and faster.

The intra-oral scanner is the most widely used technology in the modern dental practice (Fig. 1) and its use is the first step to a fully digital workflow in prosthetic dentistry. The optical impression is used both for a virtual 3D diagnostic analysis of a dentition to plan a minimally invasive treatment² virtually and for taking impressions during the various phases of the digital workflow.³ Transferring a correct impression to the laboratory is fundamental for the success of a prosthetic treatment, and the use of a diode laser is effective in obtaining a clearly readable impression. Versatility and simplicity of use make the diode laser particularly useful in digital prosthetic dentistry for the following: periodontal health, pre-impression troughing and haemostasis, minor pre-impression surgery and second-stage implant surgery.

Periodontal health

Good periodontal health is an essential condition for any prosthetic treatment: the prosthetic patient always needs adequate periodontal pretreatment for a correct digital impression and for the full success of the therapy. While

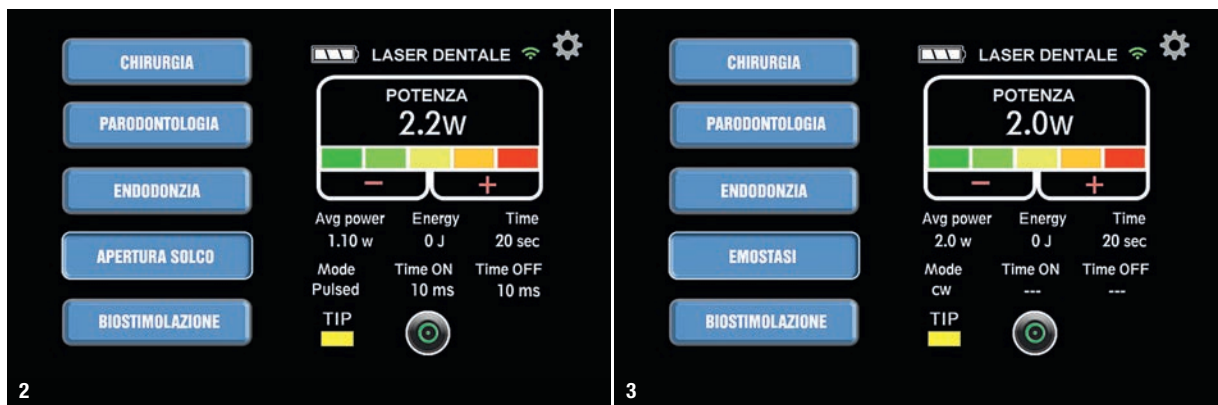
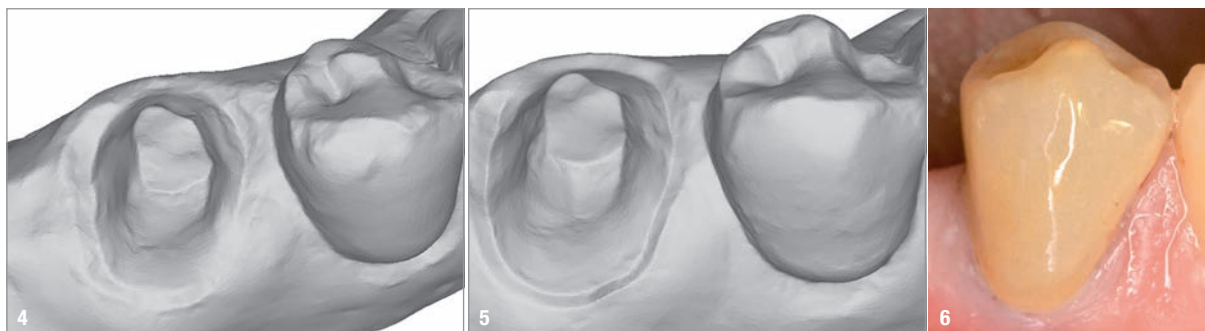


Fig. 2: The settings of the 980nm diode laser used with single-use fibres. **Fig. 3:** The laser settings for completely drying the sulcus with a programme in continuous-wave mode.



Figs. 4 & 5: Comparison of the impression without and with treatment of the sulcus shows that the use of the diode laser yields a clearer and more defined impression. **Fig. 6:** There is no significant gingival retraction one year after crown positioning.

many laser-assisted therapeutic protocols have been reported in the literature, the laser-assisted full-mouth disinfection protocol¹ is the one used in our daily clinical practice and is naturally adapted to the patient's periodontal health status. In accordance with the guiding principles of technologically supported dentistry, our goal is to perform the tooth preparation and the optical impression in a single session. The absence of gingival inflammation is an essential condition. Therefore, a session of photodynamic and photothermic therapy a few days ahead is always recommended for a bactericidal effect. A 10% povidone-iodine solution is placed in the gingival sulcus before inserting the fibre of the laser (PRIMO, MEDENCY), employing a pulsed mode of 50 microseconds on and 50 microseconds off for 30 seconds at a power of 2W.

Pre-impression troughing

Many tooth preparation systems for one-piece complete-coverage crowns, bridges⁴ and veneers,⁵ like vertical preparation without a finishing line, are discussed in the literature. In our clinical experience, in order to obtain a good optical impression, a simple principle of tooth preparation must be respected when using an intra-oral scanner: juxta-gingival preparation in non-aesthetic areas whenever possible and minimal intrasulcular preparation in aesthetically relevant areas. However, a minimal gingival displacement can help the dentist while taking the impression. Many studies on the evaluation of non-invasive gingival displacement systems are reported in the literature.⁶ The diode laser can be used for gingival displacement. While techniques involving gingival retraction cords or a diode laser lead to similar amounts of gingival retraction, use of the diode laser requires less time, is simpler for the operator and is more comfortable for the patient than are retraction cords.⁷ Pre-impression taking with a diode laser does not create gingival retraction problems compared with use of a cord impregnated with aluminium chloride. The amount of recession has been reported as clinically insignificant for both techniques.⁸

A 980nm diode laser is used with single-use fibres of 10mm and 400 μ . The laser is set on a pulsed mode of 10 microseconds on and 10 microseconds off for 20 seconds at 2.2W (Fig. 2). A single rapid and gentle movement of the activated fibre in the gingival sulcus is sufficient to achieve the desired result. The optical impression is taken with the WOW intra-oral scanner (Biotech Dental). Sometimes, a haemostasis treatment may be recommended to achieve the complete drying of the sulcus with a programme in continuous-wave mode for 20 seconds at 2W (Fig. 3). Comparison of the quality of the impression without (Fig. 4) and with (Fig. 5) treatment of the sulcus showed that the use of the diode laser yielded a clearer and more defined impression. In accordance with the results reported in the literature,⁸ there was no significant gingival retraction one year after crown positioning (Fig. 6).

Minor pre-impression surgery

In some cases, minor gingival surgery is necessary for a good result of a prosthetic treatment. Modern dentistry, thanks to the use of advanced technologies, makes it possible by reducing the number of sessions and the inconvenience to the patient. A classic case is a subgingival partial fracture of a tooth that had undergone endodontic treatment at one time (Fig. 7). After tooth reconstruction with a root fibre-reinforced post and composite, the use of a diode laser for minor surgical gingival correction is strongly recommended. The aim was to remove the excess gingival tissue and bring the fracture margin outside the gingival sulcus (Fig. 8). The laser is used with single-use fibres of 10mm and 400 μ , and the programme is set to a pulsed mode of 25 microseconds on and 50 microseconds off, 6.5W and an average power of 2.17 W. Its cutting performance without oedema and with immediate coagulation allowed for preparation of the abutment and impression taking in the same session.

It is recommended to allow the gingival tissue to rest for 10–15 minutes between abutment preparation and impression taking. We use this time for the adaptation of a