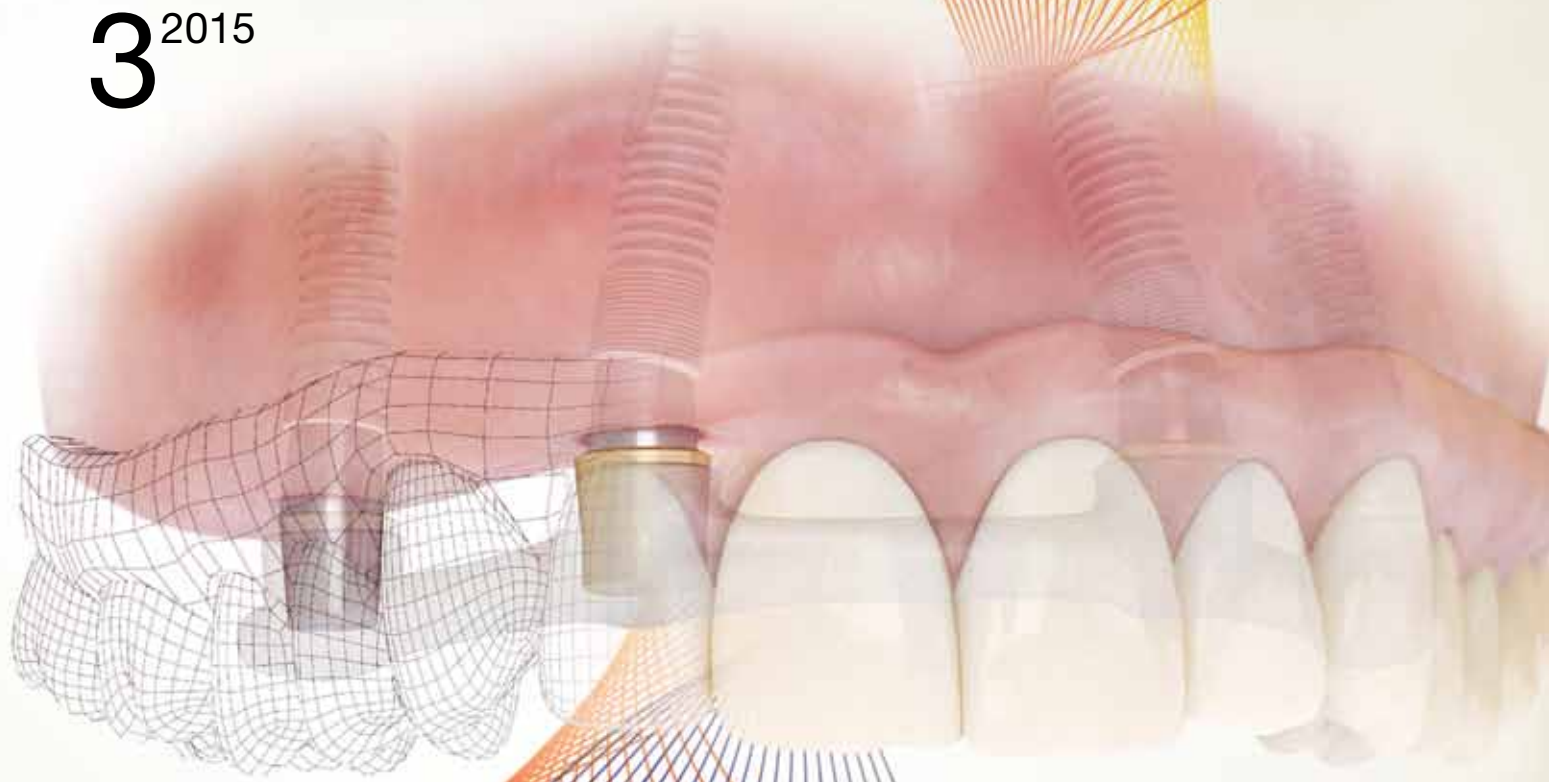

• implants

the international C.E. magazine of oral implantology

3²⁰¹⁵



c.e. article

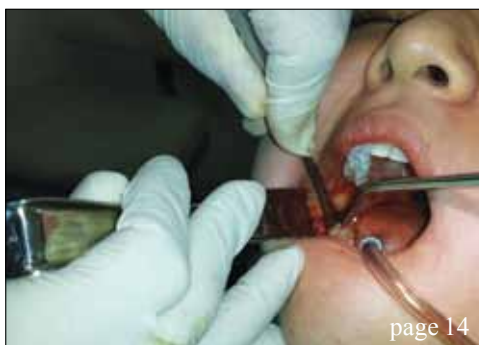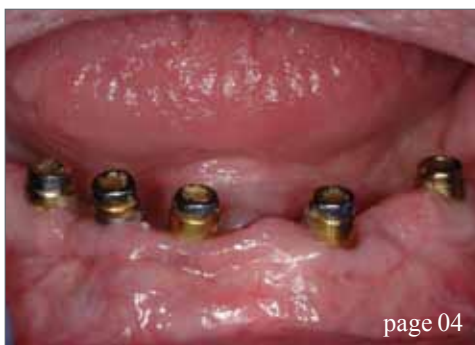Treatment
options for the
edentulous arch

events

AAID's annual
conference blends
cutting edge, classic

industry

Piezomed:
Minimally invasive,
maximally effective



| c.e. article

- 04 Treatment options **for the edentulous arch**
_Mark Montana, DDS

| education

- 14 Extraction Academy offers hands-on
Mini Residency Program

| events

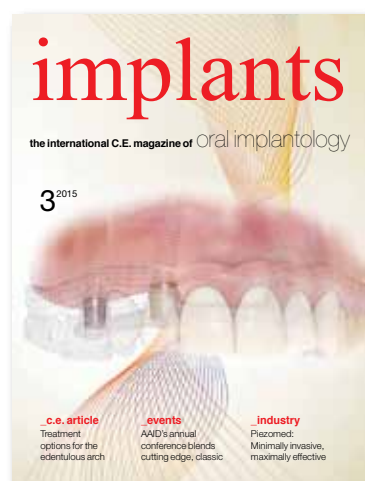- 16 **AAID conference** blends classic, cutting edge
_Max Moses, AAID
- 18 MEISINGER to host its 6th Annual **High Altitude Comprehensive Implant Symposium**

| industry

- 20 **Hahn Tapered Implant**: 45 years in the making
- 22 Piezomed: **Minimally invasive, maximally effective**

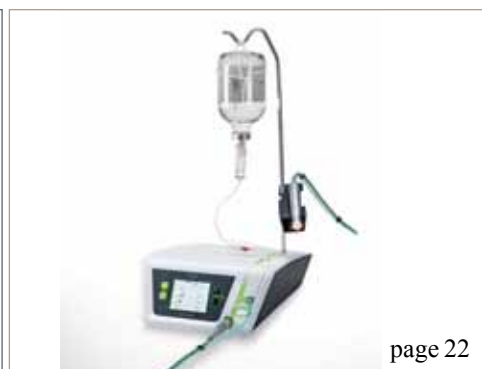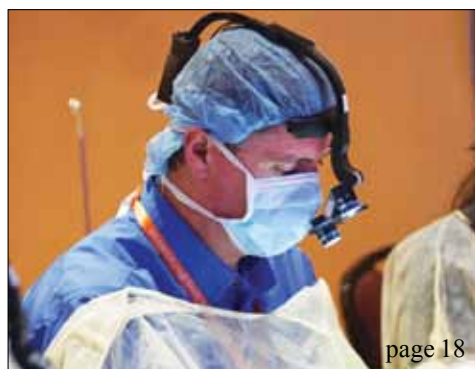| about the publisher

- 24 Submissions
- 26 Imprint



| on the cover

Cover image provided by
DENTSPLY Implants.



ATLANTIS™

For all major
implant systems

A stable and comfortable solution for edentulous patients

ATLANTIS™ Conus concept



ATLANTIS Conus concept allows for friction-fit, non-resilient prosthetic solutions for fully edentulous patients and is designed for optimal chewing function, sense of taste and oral hygiene.



STEPPS™



SIMPLANT™



SYMBIOS™



ANKYLOS™

ASTRATÉCH
IMPLANT SYSTEM
XIVE™



ATLANTIS™

Treatment options for the edentulous arch

Author_Mark Montana, DDS

_c.e. credit

This article qualifies for C.E. credit. To take the C.E. quiz, log on to www.dtstudyclub.com. Click on 'C.E. articles' and search for this edition (Implants C.E. Magazine — 3/2015). If you are not registered with the site, you will be asked to do so before taking the quiz. You may also access the quiz by using the QR code below.



_Historically, when a patient's dental condition reached a state of total tooth loss, treatment was limited to a complete denture with no hope of improving that status. The greatest challenge, particularly when working with a lower jaw, was providing a denture with reasonable stability and retention.¹ Success was greatly dependent upon the skill of the practitioner but also on the neuromuscular ability of the patients, their supporting structures and a philosophical attitude toward their condition.² Treatment for patients suffering complete edentulism has been revolutionized by the ongoing success of dental implants such that the standard of care for the mandible is an implant overdenture.

The spectrum of prosthetic modalities developed since the acceptance of endosseous implants to the dental market ranges from the very simple to the astoundingly complex. As this field of study once directed by specialists has evolved into a mainstay of the general practice, favor of expeditious and reproducible methods has gained dominance over complex therapies. Implant overdentures and fixed hybrid prostheses are choices typically offered by the dentist based upon a patient's financial ability.

While both are generally successful, the overdenture and the hybrid prosthesis are not without pitfalls.

_The implant-retained overdenture

The implant-retained overdenture is described as a prosthesis that covers, and is supported by, the natural tissues retained by the dental implant; the design is considered implant-assisted rather than supported.³ Placement of two to five implants is commonly found for the edentulous mandible with emphasis on creating a large anteroposterior spread between the endosseous pillars. If more than two implants are clustered in a small AP range, the prosthesis cannot move freely about a single axis of rotation and the denture may dislodge during function.

By creating the fulcrum on the most posterior overdenture abutments, the denture will pivot in function resulting in disengagement from the attachment mechanism and cause premature wear of the retentive components. Therefore, an increase in the number of implants beyond two does not

Fig. 1_Pre-treatment radiograph showing five implants clustered in the anterior mandible. (Photos/Provided by Dr. Mark Montana)

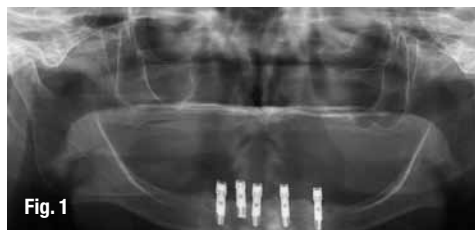

Fig. 2_Clinical image of patient; note the wear of the metal abutments due to disengagement of the nylon retention inserts as a result of fulcrum during function.

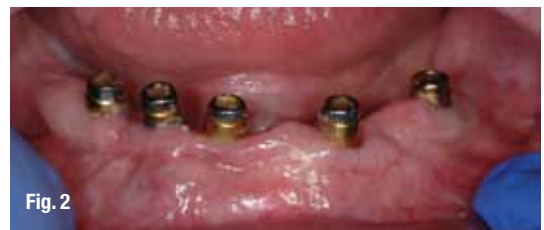

Fig. 3_Duplication of an acceptable denture serves as a custom tray. Holes of sufficient diameter to accommodate impression copings have been prepared.

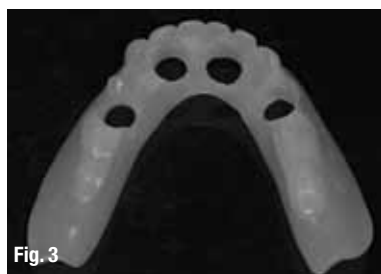
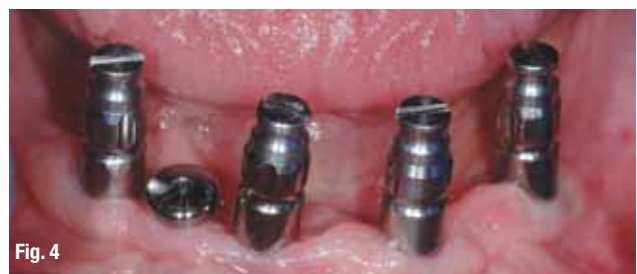
Fig. 4_Open tray impression copings seated on the dental implants. One implant is selected for disuse and covered with a transmucosal abutment.



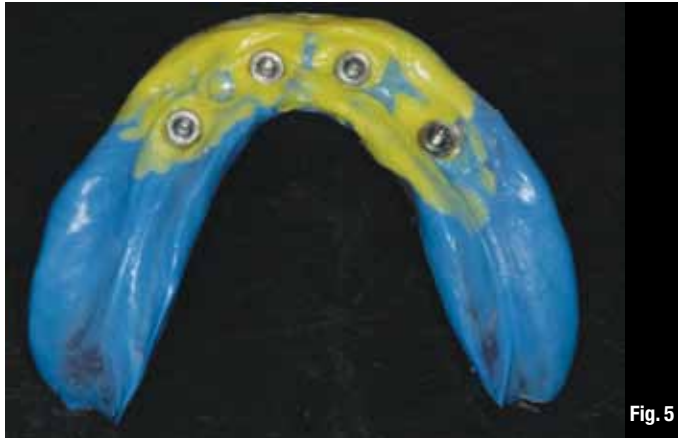

Fig. 5

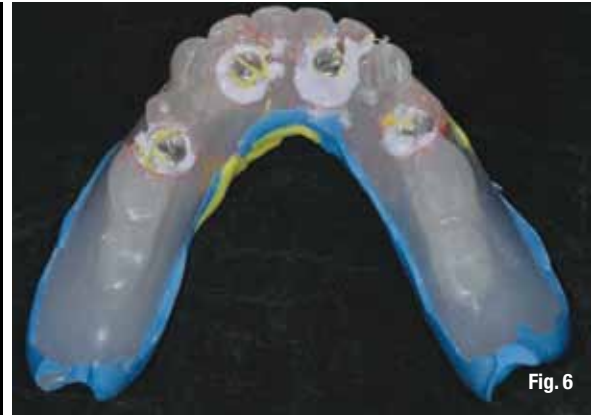

Fig. 6




Fig. 7

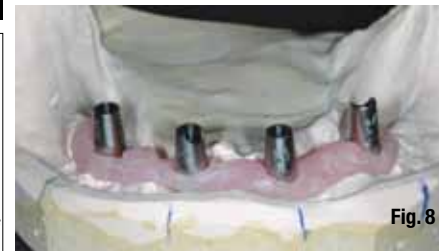

Fig. 8

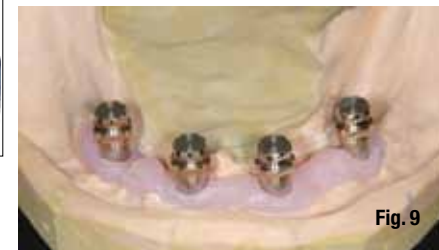

Fig. 9

necessarily provide a linear increase in retention and stability. In fact, the opposite may be true. Because support is provided by the mandible itself, resorption of the supporting structure will result in increased tipping of the denture during function, resulting in dislodgment. Therefore, the dentist and patient must be cognizant of the need for relining of the prosthesis periodically to assure optimal performance.^{4,5,6,7}

Recommendation is, therefore, placement of two implants in the anterior mandible to allow one axis of rotation. These implants should also be positioned such that future implants may be considered should the patient wish for an implant-supported alternative.

The hybrid prosthesis

The screw-retained hybrid prosthesis is a fully implant-supported structure and, therefore, is not affected by incremental resorption of the residual ridges. It has gained in popularity as the technically difficult and costly gold frameworks have been replaced by CAD/CAM titanium structures and by proven success of angled implant placement to increase the AP spread. Because the restoration

has a metal substructure, it is possible to cantilever posterior to the terminal abutment, increasing the length of the functional arch.

However, the esthetic component of the restoration, namely the denture teeth and acrylic resin matrix, are inherently weak materials originally intended for use in complete and partial dentures where functional load is comparatively low. If insufficient inter-arch space is available, the risk of fracture or displacement of denture teeth or resin base is high as the materials will be too thinned to withstand forces generated during function and especially parafunction.

Unfortunately, this is an increasingly common occurrence, especially in restoration of the maxilla with a fixed hybrid prosthesis. Inconvenient screw-access holes may further weaken the prosthetic teeth. Repair of a fractured or lost tooth requires removal of the hybrid prosthesis and correction in the dental laboratory.

The dentist must be prepared to remove the structure and later re-seat it once the repair is completed. The patient must accept he or she will be without "teeth" for the length of time required for the technician to fix the problem. Attempts to prevent fracturing by increasing the thickness of

Figs. 5, 6 Completed final impression using the custom tray and light body and medium body PVS, as well as rigid bite registration material around the impression copings to eliminate any movement of the copings.

Fig. 7 Design images showing the contour and tooth position of the duplicate denture and proposed design of the ATLANTIS Conus Abutments.

Fig. 8 ATLANTIS Conus Abutments on the working cast. Each abutment has the tooth number location scribed on the buccal-facing surface.

Fig. 9 SynCone caps seated on the abutments on the working cast. An impression of this arrangement is made to fabricate a cast metal frame to reinforce the final restoration.

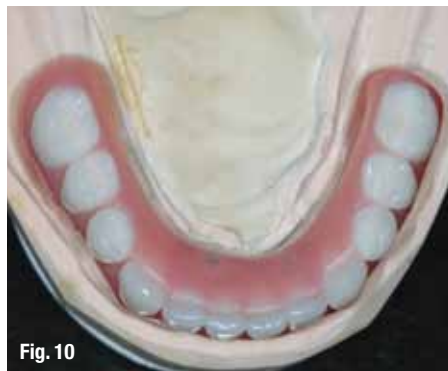

Fig. 10_Completed laboratory restoration; note the termination of the arch at the first molar to avoid excessive cantilever length. The chrome frame is opaqued on the functional side to prevent gray show-through.

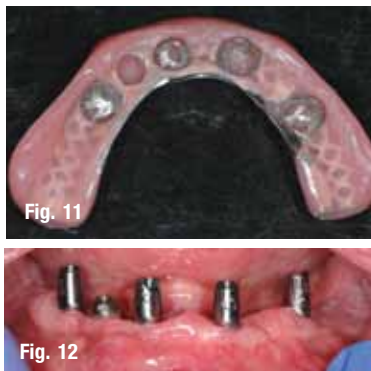


Fig. 11_Completed laboratory restoration showing the metal frame and recessed area to receive the SynCone caps.

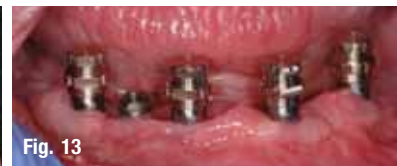

Fig. 12_ATLANTIS Conus Abutments seated. Note the 'margins' of the abutment, and the point where the parallel preparation begins, is supra-gingivally positioned.

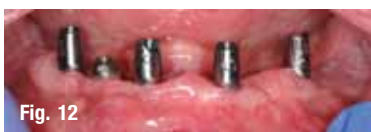

Fig. 13_SynCone caps are fitted to the abutments to verify unobstructed and complete seating.

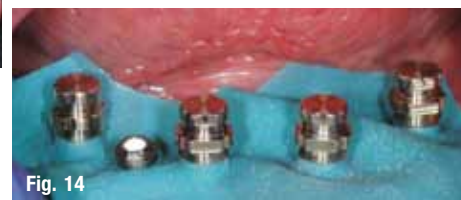

Fig. 14_Rubber dam is placed over the abutments to prevent pick-up material from locking into undercut areas below the prepared margin. SynCone caps are seated and ready to be captured into the prosthesis.

the resin is limited by the space available to do so. If inadequate inter-arch space is encountered, correction cannot be achieved by adding more material. Rather a change in design to a different and possibly more expensive restoration may be needed.

When hybrids are used in the maxilla, conflict may arise in attempting to improve the esthetic and phonetic result by use of ridge lapping and the limitations such shapes impose on proper oral hygiene.

The benefits of the fixed hybrid prosthesis are clearly improved function and minimal post-treatment complications as long as the patient is able to properly clean it and breakage is avoided. Because it is fixed, the patient cannot remove it to clean away entrapped debris and properly remove plaque. Repair or replacement of the resin teeth requires removal and re-seating by a dentist.

ATLANTIS Conus concept: the removable implant-supported bridge

As described above, the tissue-supported overdenture performs best with only two implants placed in the anterior region. When more than two implants are placed, the goal should be to provide a completely implant-supported result.^{8,9}

The Atlantis Conus concept (DENTSPLY Implants) provides the optimal functioning convenience of a fixed hybrid but also allows patient retrievability for unobstructed oral hygiene practice, regardless of the degree of ridge lap. It is, in effect, a prosthesis that can be removed by the patient, with the stability of a fixed bridge.

The concept centers around patient-specific abutments, each milled to a 5 degree convergence, and parallel to each other in the dental arch. Recommendation is for at least four implants in the mandible and four to five implants in the maxilla.

These uniquely designed, conical abutments are fitted by corresponding metal SynCone caps (DENTSPLY Implants), which are incorporated into the prosthesis. The result is a friction-fit, stable, retentive and fully implant-supported bridge that re-

mains removable by the patient.¹⁰ No special latches or plunger attachments are necessary to retain it. The patient merely slides the bridge in vertically onto the abutments and removes it in the opposite way. Because the abutments are a part of the ATLANTIS (DENTSPLY Implants, Waltham, Mass.) portfolio, it is available for all major systems.

In addition, because each abutment is custom made, correction of angled implant placement is possible up to 30 degrees. Two major requirements are necessary: the dentist must make an accurate, implant-level impression, and a scan must be made of either an approved denture set-up or of a completed denture to be retrofitted. The ATLANTIS Conus Abutments are then designed to be positioned optimally within the denture confines. The fixed yet removable prosthesis offers the advantages of excellent chewing function, improved esthetics and fracture resistance (as no screw access holes are present) and optimally facial supporting contours, without compromising cleaning by the patient.

Case report

A 73-year-old woman with a history of 11 years of complete edentulism of the maxilla and mandible, and five endosseous implants in the anterior mandible, presented with a chief complaint of a non-retentive and unstable lower denture. The implants were standard diameter, externally hexed, Brånemark fixtures. She had moderate resorption of both the maxillary and mandibular residual ridges (Fig. 1).

The patient had bone loss involving the implant bodies, but comparing the radiographic evidence available, documenting her condition through the years, it appears the bone loss occurred soon after implant placement and no appreciable change was seen thereafter.

During those 11 years, her treatment history included initial restoration of the implants with a complete denture retained by the Locator attachment system (Zest Anchors); and the maxilla was restored with a complete denture. She advised that

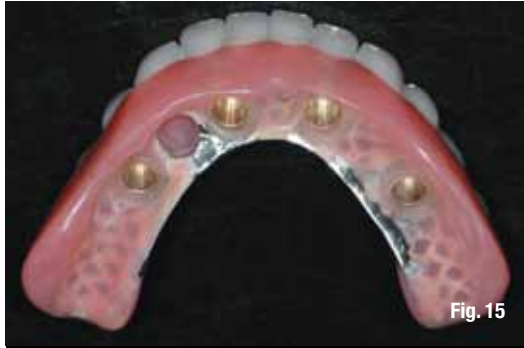

Fig. 15

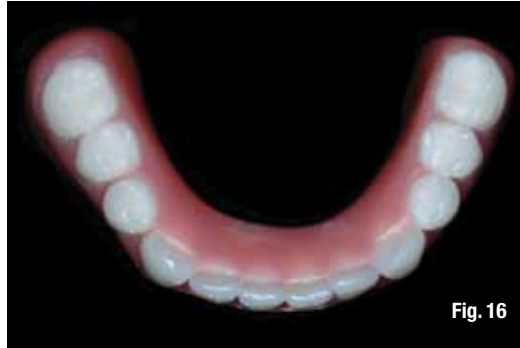

Fig. 16

the result was unsatisfactory as the lower denture displaced during function.

Her history further reveals that the Locators were replaced with Preci-Clix attachments (Ceka Attachments) with no demonstrable improvement. The patient was later retreated by the author, with new maxillary and mandibular complete dentures and new Locator attachments used to retain the lower prosthesis. The attachment male components were secured intraorally using auto-polymerizing resin to eliminate the possibility of laboratory error.

The patient continued to experience problems with the lower denture coming loose during function and required frequent replacement of the nylon male inserts; replacement with Extended Range inserts did not vary performance. The metal abutments demonstrated considerable wear as well (Fig. 2). Relining the lower denture did not improve the performance of the anchor system.

At the subsequent appointment, the patient was presented with the ATLANTIS Conus concept as a potential solution to her ongoing dilemma. Treatment options were presented as well, including a fixed hybrid prosthesis and a 2-in-1 bar overdenture. These were rejected as inter-arch space was less than optimal, requiring compromise to the strength of the design. The patient also expressed a desire for a removable design as she was concerned with having adequate facial support and wished to be able to remove the prosthesis for proper hygiene and maintenance. It was agreed that a new maxillary and mandibular complete denture would be fabricated, and ATLANTIS Conus abutments would be made to secure the lower restoration.

Clinical and laboratory procedures

Because the existing dentures were made within the last five years and were acceptable with regard to tooth position and vertical dimension, it was decided that clear, acrylic resin duplicates of each denture would be made to serve as custom trays.¹¹ Double-sided impressions of each denture were

made and delivered to the dental laboratory for fabrication of the duplicates. Once processed, the copy denture borders were shortened by 2 mm to allow border molding. The duplicate of the mandibular denture clearly showed the position of each Locator housing and therefore the position of the dental implants. Holes of adequate diameter to allow the duplicate denture to be placed in the patient's mouth over impression copings were prepared (Fig. 3). The intaglio surface of both the upper and lower duplicate denture were relieved to allow for a wash impression.

The patient returned for final impressions, and the Locator abutments were removed and kept in appropriate order to avoid confusion when re-seating them at the appointment completion. Open tray impression copings were connected to each of the four dental implants to be restored and tightened into place; one implant with greater bone loss and placed significantly more shallowly than the rest was omitted (Fig. 4). Light-body poly vinyl siloxane was injected around the base of each impression coping and medium-body PVS was placed in the custom tray.

The tray was seated, ensuring that the impression copings were completely accessible through the holes previously prepared. The patient was instructed in facial and tongue movement to achieve proper peripheral border extension. Regisil Rigid (DENTSPLY) bite registration material was injected around each impression coping to rigidly adhere them to the impression tray. This step is critical as reliance on flexible impression material may allow transfer error when constructing the working cast.

Once the impression materials were fully set, the screws retaining the impression copings were removed and the final impression and tray were withdrawn from the patient (Figs. 5, 6). All Locator abutments were re-seated and tightened. Final impression of the maxilla was completed with border molding using modeling plastic and a wash impression with light-body PVS. Upon completion, the patient was dismissed.

Fig. 15 Completed bridge with SynCone caps processed in position. Because they have been processed intra-orally, there is no error in fit. These caps are extremely retentive, allowing only vertical displacement of the prosthesis.

Fig. 16 Completed restoration. Note the absence of screw access holes for a prosthesis that looks like a denture yet fits like a bridge.

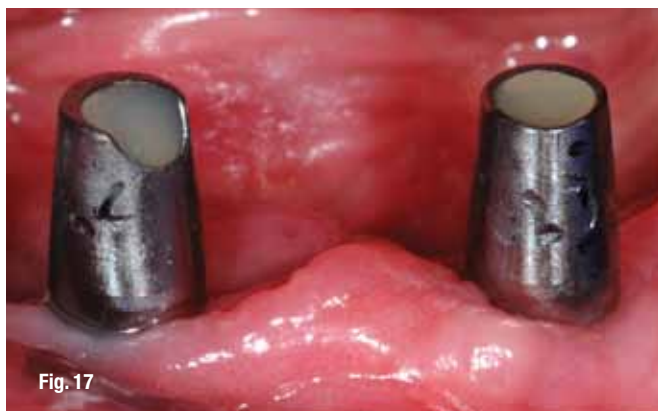

Fig. 17

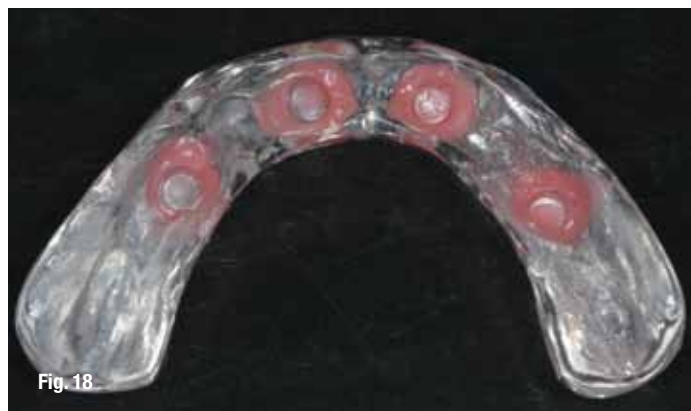

Fig. 18

Fig. 17_ATLANTIS Conus abutments torqued to specified level, obturated with Teflon tape and composite resin.

Fig. 18_Laboratory processed, clear duplicate prosthesis with siliconized reline material to improve retention; to be used as a nighttime appliance to protect the tongue from the sharper edges of the abutments.

In the dental laboratory, implant analogs were secured to the impression posts, and gingival mouldage was injected around the analogs to an adequate depth to completely cover the coping-analog interface. The impressions were boxed with wax and poured in vacuum-mixed die stone. After setting, the impression coping screws were removed and the impressions were separated from the hardened casts; standard laboratory procedures were followed in cleaning and trimming the working casts. Base plate and wax rims were made for continuation of the denture fabrication. The impression materials were removed from the duplicate denture, and it was positioned back onto the mandibular cast to be scanned. An online order was completed including identification of the implants involved, and the case was shipped to DENTSPLY Implants for the design and manufacture of the ATLANTIS Conus Abutments.

The working cast, implant analog connections and the denture duplicate were scanned at the ATLANTIS production site, and the abutments were individually designed using ATLANTIS VAD (Virtual Abutment Design) software to ensure that all abutments were parallel to each other. The restorative margin of each abutment was placed close to the soft-tissue height surrounding each implant but always supra-gingival to guarantee unobstructed seating of the finished restoration.

Each abutment was milled to a 5 degree taper to match the SynCone caps, ensuring an intimate friction-fit. Upon design completion, the images of the abutment designs were made available for review and approval before manufacturing (Fig. 7). Once the design presented was found to be satisfactory, approval for production of the patient-specific abutments was granted. It is important to note that no fees are incurred by the dentist or dental laboratory during this process until design is agreed upon and authorization to proceed is given. The abutments are custom designed to fit specifically to the denture set-up or duplicate denture provided; there are no sizes,

heights, angles or collars to select from a catalog and, therefore, no risk of choosing incorrectly.

When received, the ATLANTIS Conus abutments were secured to the working cast with abutment screws, along with four prefabricated SynCone caps (Figs. 8, 9). The caps were seated on to the abutments and sent to the dental laboratory to be impressed. The impression was poured twice, one in improved dental stone and one in refractory material for fabrication of a cast metal frame. While waiting for the frame to be completed, final try-in appointments for the denture set-up were completed, and the patient approved fabrication of the dentures.

The denture set-up with a final bite record was returned to the dental lab, the cast metal frame was seated on the improved dental stone cast and areas around the stone copy of the SynCone caps were blocked out prior to processing. The SynCone caps will be captured intraorally, rather than having them processed in the dental laboratory. All work was completed on the duplicate stone cast rather than the original working cast. The cast metal frame was opaqued to prevent gray show-through. The set up was transferred to the cast with the metal frame and the dentures were processed (Figs. 10, 11).

Because the ATLANTIS Conus concept results in a fully implant-supported prosthesis, the peripheral borders of the finished structure were greatly reduced and the occlusal table was abbreviated at the first molar. The length of functional arch follows the identical AP spread principles used for hybrid prosthetics to avoid excessively long cantilevers.

At this point, the structure was a bridge and not an overdenture. To facilitate seating of the abutments in the patient, a clear matrix was made with the abutments on the original working cast, where they have remained since receipt. Each abutment was identified with one, two, three and four black ink dots respectively, based on their position on the cast. The clear matrix was seated over the abutments, and corresponding black dots were drawn on it to line up

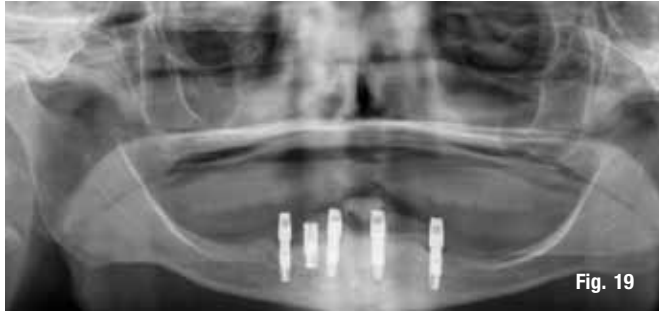


Fig. 19

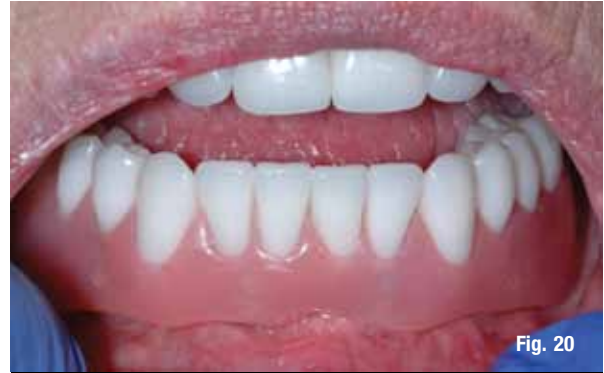

Fig. 20

exactly with those on the abutments. The completed mandibular bridge was double-side impressed by the dental technician, and an injection-mold copy of clear acrylic resin was made.

The patient was scheduled for completion of treatment. The Locator abutments were again removed and Teflon tape was placed in the implant excluded from the design. The abutments were seated onto the dental implants (Fig. 12), and the clear matrix was placed to verify that each abutment was correctly orientated by checking that the dots on the matrix superimposed with those on the abutments.

Once verified, the abutments were torqued to 20 Ncm, appropriate for the implants involved. The SynCone caps were placed and viewed with magnification to assure that they were superior to the gingival tissues (Fig. 13). The prosthesis was placed over the caps to verify there was no obstruction of complete seating. The prosthesis was removed and vent holes were drilled through the buccal contours of the acrylic resin to relieve hydraulic pressure during capture of the caps. The SynCone caps were lifted and a rubber dam was placed around the abutments to prevent pick-up resin from locking into undercuts, and the caps were re-seated (Fig. 14).

Attachment processing material (Chairside by Zest Anchors) was placed in the reservoirs of the prosthesis and seated over the SynCone caps. The upper denture was placed, and the patient was instructed to gently close into full occlusion and to maintain position for two minutes while setting occurred. After two minutes, the excess flow of pick-up resin was checked for hardness, and after an additional minute, the prosthesis was ready for removal. Removal was uneventful, although retention was considerable. Removal of the bridge can only occur after the long-axis of the abutments; no tipping or rotating is possible (Figs. 15, 16).

Once removed, the excess pick-up material was cleaned up and the bridge was properly polished where needed. The abutments were packed with Teflon tape to within 3 mm of the surface, and the

remaining space was filled with flowable composite resin (Fig. 17). The patient was instructed on placement and removal and repeated the exercise until we were satisfied she would experience no difficulties performing this. The clear, duplicate copy of the bridge was seated onto the abutments using a chairside soft lining material (Fig. 18).

This copy serves as a temporary device for the patient to wear when cleaning the finished bridge or when sleeping to protect the tongue from scraping against the abutments. A panoramic radiograph was taken at completion of treatment (Fig. 19).

The patient returned after one week and again after six weeks, and reported at both visits that the lower bridge did not move at all during function and stayed seated until she removed it. She commented on the ease of cleaning the dental abutments, and she reported no discomfort and no food entrapment. Overall, the patient was very pleased with the result (Fig. 20).

Discussion

The number of implants placed for an edentulous patient should be based upon whether the design is to be implant-assisted or implant-supported. If the goal is a minimalist design utilizing the soft tissue for support, two implants using Locator attachments are appropriate to retain a mandibular denture and will provide a predictable outcome. However, when more than two implants using resilient overdenture retainers are employed, there is not a corresponding linear increase in retention of the denture, and the result may suffer. Therefore, when at least four implants are planned, the restoration should be designed as implant-supported to maximize the value of the patient's greater investment.

This article discusses just such a situation where a patient had experienced repeatedly low value from her investment of five implants. By redesigning her treatment to become implant-supported through the use of the ATLANTIS Conus concept, a successful result was achieved without the greater expense

Fig. 19 Panoramic radiograph of the abutments seated on the four selected implants. Because the restoration is fully implant-supported, gradual diminution of the residual ridge will present no consequence to the patient.

Fig. 20 Completed bridge in place showing flange length suitable to prevent food entrapment and support the lip and cheeks. Because the restoration remains removable, these flanges do not prevent excellent home care.