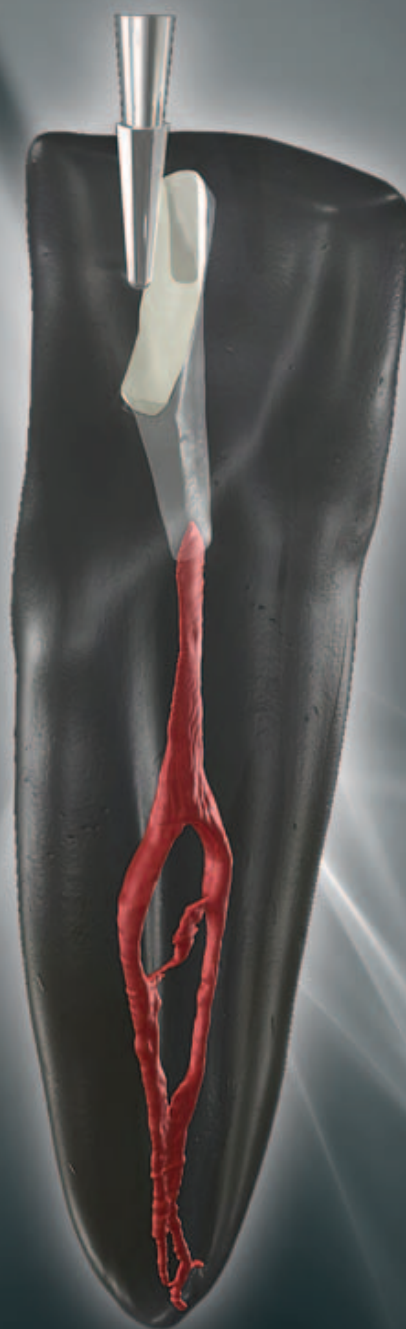

roots

international magazine of endodontology

1 2010



| **special**

Evidence-based
endo-implant algorithm

| **case report**

Managing maxillary molars

| **instrumentation**

File selection: Why geometry matters most



Ultrastreaming in the root canal



for an effective cleaning

VDW.ULTRA®

**Ultrasonic device with endo-focus.
Safe operation thanks to clear user
guidance following endodontic
indications:**

- Passive, ultrasonic irrigation reaches all areas inaccessible to instrumentation
- Cavity preparation
- Retreatments
- Removal of metal posts and separated instruments



Want more information?
VDW GmbH · P.O.Box 830954 · 81709 München · Germany
info@vdw-dental.com · www.vdw-dental.com

Endo Easy Efficient®

Dear Reader,



Dr Chris J. Lampert
Guest Editor

The success of modern endodontic treatment can largely be attributed to the work of Dr Herbert Schilder. This is not because he pioneered 3-D obturation with warm gutta-percha, not because he defined the first mechanical and biological objectives for shaping and cleaning a root-canal system, not because he stood by his principles in the face of criticism, but because he *raised the bar* for endodontic success to a new level. Numerous gifted educators and clinicians have followed and furthered Dr Schilder's principles and techniques. In fact, in this edition of **roots**, two contributing authors were trained by Dr Schilder.

Historically, endodontic treatment has been considered the last option for saving a tooth prior to extraction. The option of endodontic treatment was compared to that of not having a tooth, which was an easy decision to make. Presently, dental implants are the comparative treatment against which endodontic success is measured. Many believe, and I agree, that this comparison has also raised the bar for endodontic treatment success to a new level.

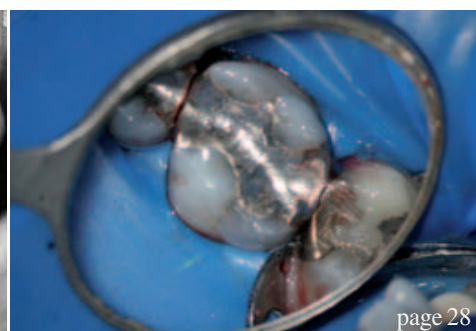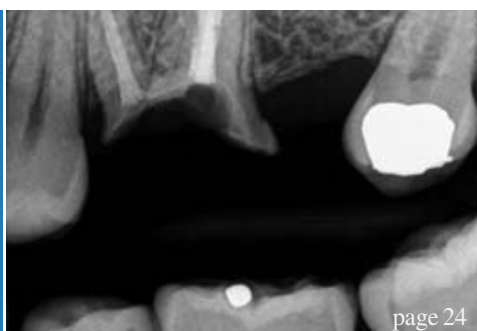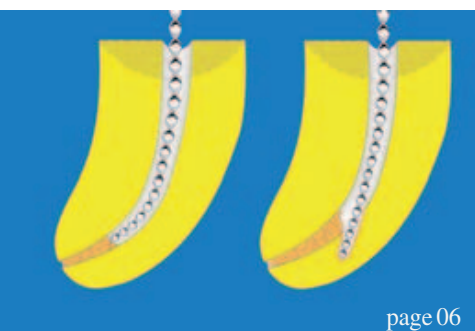
Raising the level of endodontic treatment begins with knowing when to treat a compromised case and when not to treat a hopeless case. Correctly determining this improves the success of endodontic treatment. Utilising technology such as cone-beam imaging gives clinicians diagnostic information about the aetiology of endodontic pathology that is critical to determining whether a case can be treated endodontically. Treating complicated cases with advanced micro-surgical endodontic treatment is also required to improve the success of endodontic treatment. It is essential that current and future generations of endodontic clinicians continue to practise and improve micro-surgical endodontic treatment.

I am honoured to contribute to this edition of **roots**. As you will see in the following articles, **roots** has become a premier international endodontic publication. It offers a forum for renowned clinicians and educators to share their knowledge and expertise with colleagues in all fields of dentistry. I hope you will enjoy this issue of **roots** as much as I did.

Sincerely yours,

A handwritten signature in black ink that reads "Chris Lampert". The signature is fluid and cursive, with a long, sweeping underline.

Dr Chris J. Lampert
Guest Editor
Endodontist
Portland, Oregon, USA



editorial

- 03 Dear **Reader**
I Dr Chris J. Lampert, Guest Editor

special

- 06 Untying the **Gordian Knot**:
An evidence-based **endo-implant algorithm** (Part I)
I Dr Kenneth S. Serota

clinical report

- 20 **Apical microsurgery**—Part IV:
The REB and REP
I Dr John J. Stropko

case report

- 24 **The importance of endodontics** in
implant treatment planning
I Dr Jose M. Hoyo
- 28 **Managing maxillary molars**
I Dr Mark Dreyer
- 30 **Comprehensive evaluation of previous
root canal therapy**
I Dr Richard E. Mounce

opinion

- 34 **The perceptions of a David** in a land of **Goliaths**
I Dr Barry Lee Musikant

research

- 36 **Determining working length,**
or how to locate the **apical terminus** (Part II)
I Prof Vladimir Ivanovic & Dr Katarina Beljic-Ivanovic

instrumentation

- 44 **File selection**: Why geometry matters most
I Dr L. Stephen Buchanan

industry news

- 46 **Ready-to-use root-canal sealer:**
2Seal easymiX
I VDW

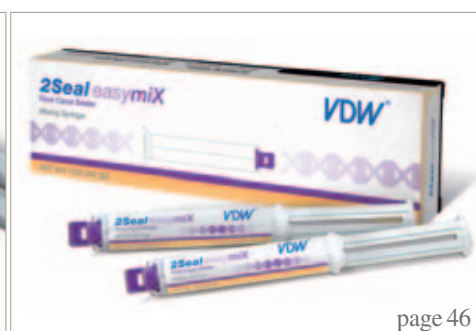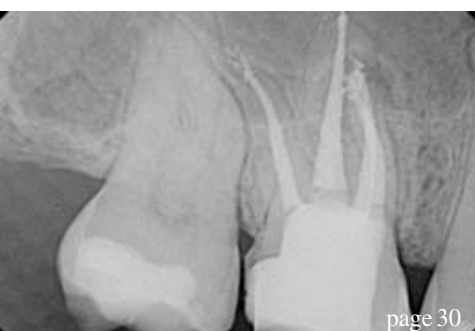meetings

- 48 **International Events**

about the publisher

- 49 I submission guidelines
50 I imprint

Cover: OK endodontic access bur (SS White). Image courtesy of Dr Eric Herbranson and Dr David J. Clark, drclark@microscopdentistry.com.




TOOLS TO KEEP SMILING

No less than ...
...4 launches !

D-RaCe

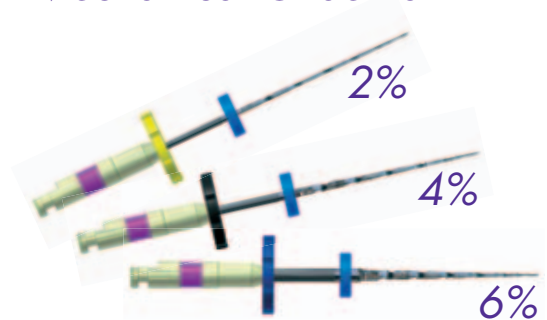Desobturation made easy



www.d-race.ch

FKG RaCe ISO 10

Mechanical Glide Path




Spreader 4%

NiTi & Electro-chemical polishing



SMG handle

Indicator of uses



For K/H files and reamers

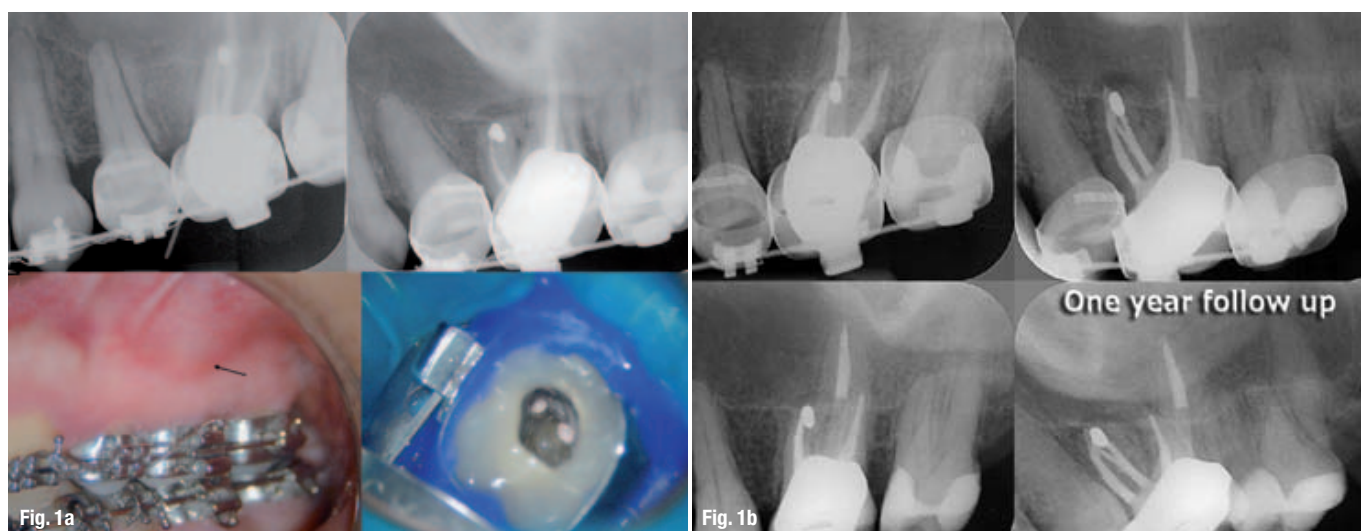
www.fkg.ch

FKG
FKG DENTAIRE
Swiss Dental Products



Untying the Gordian Knot: An evidence-based endo-implant algorithm (Part I)

Author_ Dr Kenneth S. Serota, USA



Figs. 1a & b Previous endodontic therapy on tooth #14 had failed; the clinician chose to correct the problem with a microsurgical procedure on the mesio-buccal root. This procedure failed over time as well (sinus tract). Radiographic and clinical evidence indicate the developing apical lesion.

The root-canal system was reaccessed, the untreated canal identified, the entire system debrided, disinfected and after interim calcium hydroxide therapy, obturated. One year later, the lesion had healed. While the retrograde amalgam remained in the root end, its presumed ability to seal a complex apical terminal configuration effectively was ill considered. Everything leaks in time; re-treatment is always the first choice for resolution of an unsuccessful endodontic procedure, where possible.

Study the past, if you would divine the future.

—Confucius

The endodontic implant algorithm provides highlights in the assessment and identification of determinant factors leading to endodontic failures, in order to help in the decision-making process, whether it is adequate to implement a new endodontic approach versus extraction and replacement with dental implants.

—Confusion

_Over the years, endodontics has diminished itself by enabling the presumption that it is comprised of a narrowly defined service mix; root-canal therapy purportedly begins at the apex and ends at the orifice. Nothing could be further from the truth. It is the catalyst and precursor of a multivariate continuum, potentially the foundational pillar of all phases of any rehabilitation (Figs. 1a–c).

Early diagnosis of teeth requiring endodontic treatment, prior to the development of peri-radicular

disease, is critical for a successful treatment outcome.¹ Aesthetics, function, structure, biotics and morphology are the variables in the equation of optimal oral health. Interventional or interceptive endodontics, restorative endodontics, the re-engineering of failing therapy, transitional endodontics and surgical endodontics encompass a vast scope of therapeutic considerations prior to any decision/tipping point to replace a natural tooth.

Everything we do as dentists is transitional, with the exception of extractions. No result is everlasting, none are permanent; thus our treatment plans must reflect this reality. Artifice versus a natural state is not a panacea for successful treatment outcomes (Figs. 2a–d).

In 1992, funding from the Cochrane Collaboration was obtained for the UK Cochrane Centre based in Oxford to facilitate the preparation of systematic reviews of randomised trials of health care.² The Cochrane Systematic Review is a process that involves locating, appraising, and synthesising evidence from scientific

studies in order to provide informative empirical answers to scientific research questions.

In 1952, the enterprising son of an inventor named Ron Popeil created infomercials using 30- to 120-second television spots to sell his inexpensive array of useful products, including the Pocket Fisherman and the Veg-O-Matic food slicer. The singular goal of an infomercial was to have the viewer phone immediately and place his or her order—no waiting weeks, months or even years for the lofty marketing goals of branding to pay off. Somewhere along the way, dentistry morphed the two concepts. Nowhere is this becoming more apparent than in the debate on the endodontic implant algorithm. "We have met the enemy ... and he is us." (*The Pogo Papers*)

Scientific doctrine is the cornerstone of endodontic therapeutics. However, of late, anecdotal testimony has become the default setting for new paradigms to justify endodontic treatment modalities and an encomium to technological advances. The strength of the arch of this or any specialty's integrity and relevance must rely on a keystone of randomised clinical trials and evidence-based treatment outcomes. Expert opinions reflected through the looking glass of business models or global tours cannot replace stringently controlled clinical assessments distilled from exacting independent investigations. Science cannot be applied through a McLuhanistic rear-view mirror of technology. The two must symbiotically occupy the same space regardless of whether that is antithetical to the Pauli Exclusion Principle, one of the most accepted laws of physics: no two objects can simultaneously occupy the same space.

In December 2004, Salehrabi and Rotstein³ published an epidemiological study on endodontic treatment outcomes in a large patient population. The outcomes of initial endodontic treatment by general practitioners and endodontists participating in the Delta Dental Insurance plan on 1,462,936 teeth of 1,126,288 patients from 50 states across the US were assessed in an eight-year timeline. Subsequent to non-surgical endodontic treatment over this period 97 % of teeth were retained in the oral cavity. The combined incidence of untoward events, such as re-treatments, apical surgeries and extractions, was 3 % and occurred primarily within three years from the completion of treatment. Analysis of the extracted teeth revealed 85 % had no full coronal coverage. A statistically significant difference was found between covered and uncovered teeth for all tooth groups tested, which is consistent with the findings of numerous investigations.⁴⁻⁶

The purpose of this publication is to evaluate current trends and perceptions pertaining to the standard of

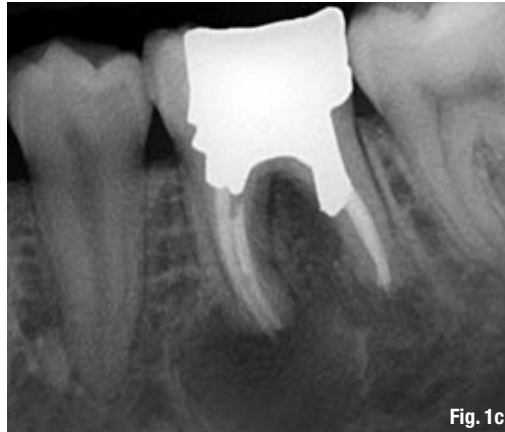

Fig. 1c "Listening to both sides of a story will convince you that there is more to a story than both sides." (Frank Tyger). The endodontic implant algorithm ensures that philosophy does not obscure pragmatism and expediency does not denigrate adaptive capacity.

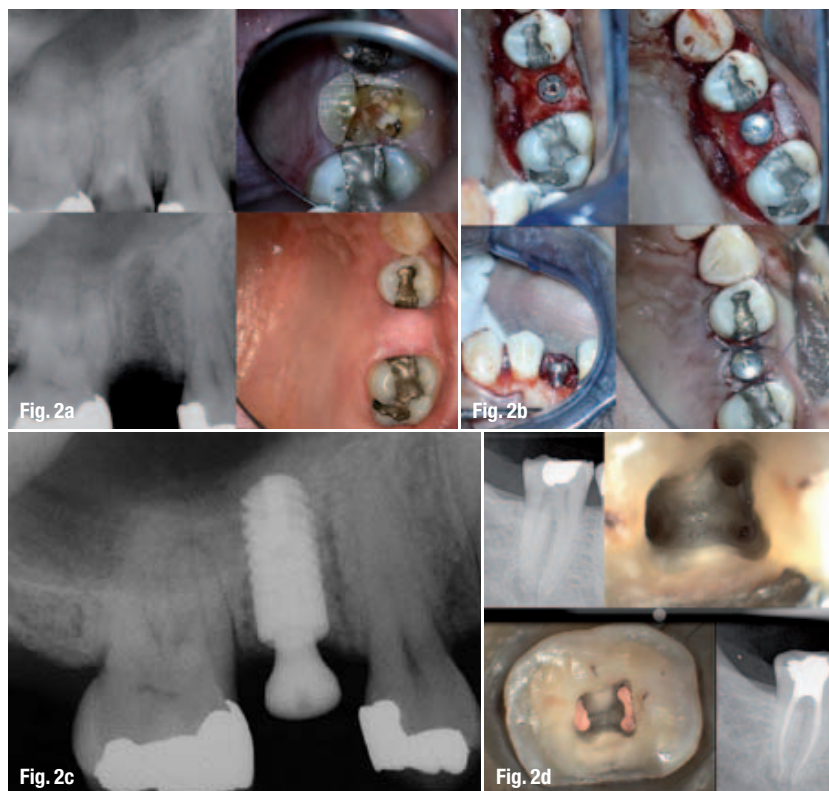
care in endodontics and provide an evidence-based consensus on their relevance and application. Part II will address the algorithm by which sacrifice of natural structures for ortho-biological replacements can be validated and the engineering principles and designs that best mimic clinical dictates.

_Evolutionary paradigm shifts

Three surveys have been conducted with the membership of the American Association of Endodontists since the late 1970s. The first reflected what is now an anachronistic view of emergency procedures and the standard of care defining non-surgical therapy during that period.⁷ The second, done prior to the technological advances of the last decade of the twentieth century, was hallmarked by a dramatic decrease in leaving pulpless teeth open in emergency situations and a significant decline in the use of culturing prior to obturation.⁸

The report on the second survey indicated that the concept of *debridement and disinfection* versus *cleaning and shaping* was now the focus of the biological therapeutic imperative and the need for expansive microbial strategies was recognised as being of paramount importance (Fig. 3). The primary patho-physiologic vectors of pulpal disease and the myriad complexity of the root-canal system had always been understood; as the century closed, clinicians were provided with new tools and technology to expand the boundaries and limitations of endodontic treatment procedures (Figs. 4a & b).

Root-canal infections are polymicrobial, characterised predominantly by both facultative and obligate anaerobic bacteria.⁹ The necrotic pulp becomes a reservoir of pathogens; toxic consequences and their resultant infection are isolated from the patient's immune response. Eventually, the microflora and their by-products will produce a peri-radicular inflammatory response. With microbial invasion of the peri-radicular tissues, an abscess and cellulitis



Figs. 2a & b Tooth #4 was determined to be non-salvageable. It was removed, the socket stimulated to regenerate and in four month's time an ANKYLOS implant inserted, a sulcus former placed and the tissue closed over the site to allow for osseo-integration to occur.

Figs. 2c & d The choice of a natural tooth versus an ortho-biological replacement will increasingly be a powerful force in dental treatment plans. The temptation to select one or the other based on expediency versus complexity, on marketing versus science, will be the sine qua non of the standard of comprehensive care.

Fig. 3 The degree of complexity of the root-canal system has been understood for most of the past century. The failure to negotiate the labyrinthine ramifications of the root-canal system has purportedly been a function of technical limitation rather than comprehension and yet, it took until the mid-1970s to appreciate that thermo-labile condensation of an obturating material could demonstrate a greater occlusive degree of the system than any other modality.

may develop. The resultant inflammatory response will initiate a protective and/or immuno-pathogenic effect. Additionally, it may destroy surrounding tissue, resulting in the five classic signs and symptoms of inflammation: calour, dolour, rubor, tumour and penuria. Patient evaluation and the appropriate diagnosis/treatment of the source of an infection are of utmost importance.

Patients demonstrating signs and symptoms associated with severe endodontic infection (Table I) should have the root-canal system filled with calcium hydroxide and the access sealed. In the event of copious drainage, the access can be left open for no longer than 24 hours, the tooth then isolated with rubber dam, the canals irrigated and dried and calcium hydroxide inserted into the root-canal space, and the access sealed.¹⁰

The antibiotic of choice for peri-radicular abscess remains Penicillin VK; however, recent studies have reported that amoxicillin in combination with clavulanate (1 gm loading dose with 500 mg q8h for seven days) was a more effective therapeutic regimen.¹¹

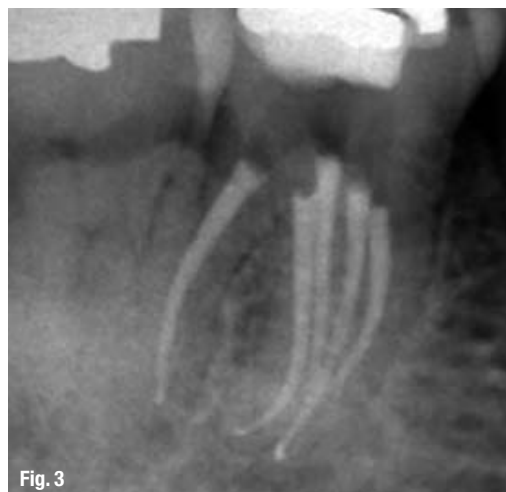
Systemic antibiotic administration should be considered if there is a spreading infection that signals failure of local host responses in abating the dispersion of bacterial irritants, or if the patient's medical history indicates conditions or diseases known to reduce the host defence mechanisms or expose the patient to higher systemic risks. Antibiotic treatment

is generally not recommended for healthy patients with irreversible pulpitis or localised endodontic infections (Table II). Numerous studies with well-defined diagnosis and inclusion criteria have failed to demonstrate enhanced pain resolution beyond the placebo effect.^{12,13}

The sophistication of endodontic equipment, materials and techniques has been steadily iterated and innovated since the second survey. The microscope first introduced to otolaryngology around 1950, then to neurosurgery in the 1960s, is now the standard of care for the voyage into the microcosmic world of the root-canal system. Recursions in the micro-processing technologies of electronic foraminal locators begat unprecedented accuracy levels, improved digital radiographic sensors and software-enhanced diagnostic acumen, and ultrasonic units with a variety of tips designed specifically for use when performing both non-surgical and surgical endodontic procedures minimised damage to coronal and radicular tooth structure in the effort to locate the pathways of the pulp. The treatment outcome of non-surgical root-canal therapy currently is far more predictable than at any other period in our history.

_Diagnosis

Of all the technologic innovations embraced by endodontics, digital radiography should have generated the greatest impact; however, its value remains limited in diagnosis, treatment planning, intra-operative control and outcome assessment. Flat-field sensors still require three to four parallax images of the area of interest in order to establish better perception of depth and spatial orientation of osseous or dental pathology. These 3-D information deficits, geometric distortion and the masking of areas of interest by overlying anatomy or anatomical noise are of strategic relevance to treatment planning in general and endodontics specifically (Figs. 5a & b).¹⁴



Cone-beam computed tomography (CBCT) produces up to 580 individual projection images with isotropic sub-millimetre spatial resolution enhanced by advanced image receptor sensors. It is thus ideally suited for dedicated dento-maxillofacial CT scanning. When combined with application-specific software tools, CBCT can provide a complete solution for performing specific diagnostic and surgical tasks. The images can be re-sliced at any angle, producing a new set of reconstructed orthogonal images, and studies have shown that the scans accurately reflect the volume of anatomical defects. The limited volume CBCT scanners best suited for endodontics require an effective radiation dose comparable to two or three conventional peri-apical radiographs and as such are set to revolutionise endodontics (Fig. 6).^{15,16}

Three-dimensional pre-surgical assessment of the approximation of root apices to the inferior dental canal, mental foramen and maxillary sinus are essential to treatment planning. The ability of CBCT to diagnose and manage dento-alveolar trauma using multiplanar views, the determination of the root-canal anatomy and number of canals, the detection of the true nature and exact location of resorptive lesions and the discovery of the existence of vertical and horizontal fractures outweigh concerns about the degree of ionising radiation and the risks posed.¹⁷ Provided CBCT is used in situations in which the information from conventional imaging systems is inadequate, the benefits are essential for optimisation of the standard of care.

Patel reported that peri-apical disease can be detected sooner and more accurately using CBCT compared with traditional peri-apical views and that the true size, extent, nature and position of peri-apical and resorptive lesions can be accurately assessed.¹⁸ Using a new peri-apical index based on CBCT for identification of apical periodontitis, peri-apical lesions were identified in 39.5% and 60.9% of cases by radiography and by CBCT, respectively ($p < 0.01$).



Fig. 4b

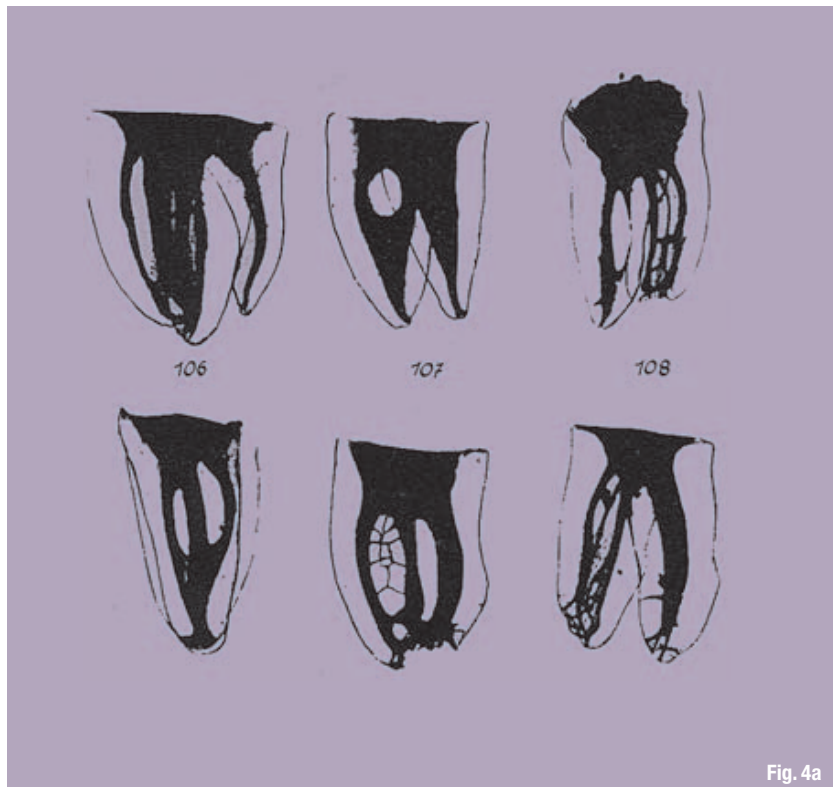


Fig. 4a

Simon et al. compared the differential diagnosis of large peri-apical lesions with traditional biopsy. The results suggested CBCT might provide a faster method to differentially diagnose a solid from a fluid-filled lesion or cavity, without invasive surgery.^{19,20} In spite of the presence of artefacts, the learning curve related to image manipulation and the cost, CBCT will invariably be the accepted standard of diagnostic care and treatment planning in endodontics in the very near future.

Access

An improperly designed access cavity will hamper facilitation of optimal root-canal therapy. If the orientation, extension, angulations and depth are inaccurate, retention of the native anatomy of the root-canal space becomes precarious. The requirements of access cavity design can be achieved by conceptual and technical regression of the existing configuration to that which one would logically expect to have seen prior to the insults of restoration, function and ageing. If tertiary dentine were perceived of as 'irritational dentine' or dystrophic calcification considered 'decay', the chamber outline could be used to blueprint an inlay configuration for the access design that literally replicates the virgin tooth (Fig. 7).

Removal of the existing restoration in its entirety and/or preliminary preparation of the coronal tooth structure for the subsequent full coverage restoration will identify decay, fractures, unsupported tooth structure and expose the anatomy of the underlying

Fig. 4a Panel of anatomic preparations from the classic work by Walter Hess (*The Anatomy of the root canals of teeth of the permanent dentition*, London, 1925).

Fig. 4b In order to determine the number of root canals and their different morphology, ramifications of the main root canals, location of apical foramina and transverse anastomoses, and frequency of apical deltas, 2,400 human permanent teeth were decalcified, injected with dye and cleared (Vertucci FJ, 1984).