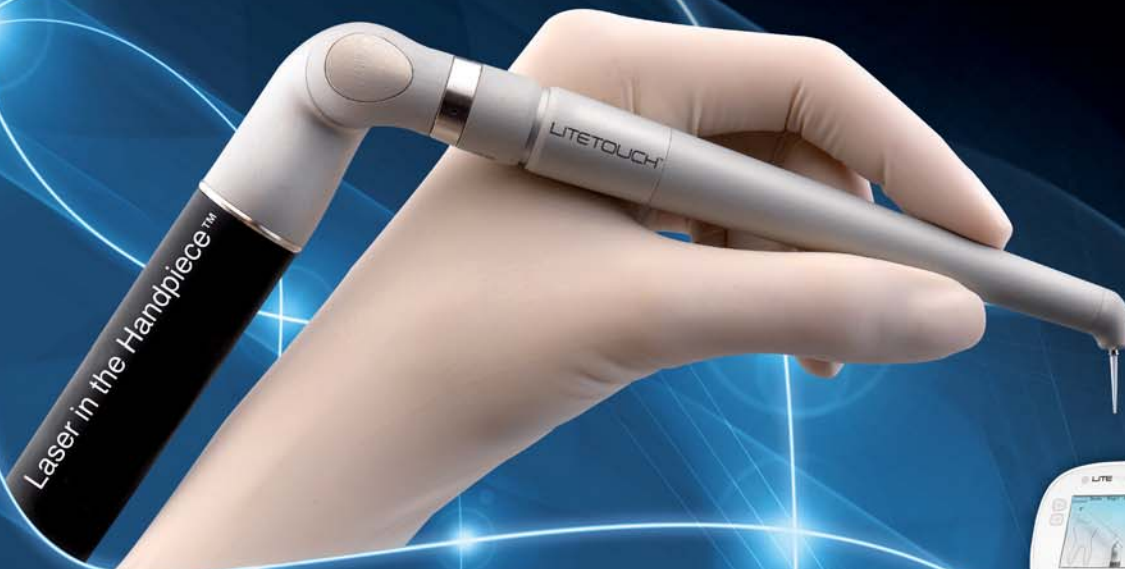

# laser

international magazine of laser dentistry

4<sup>2011</sup>



## | research

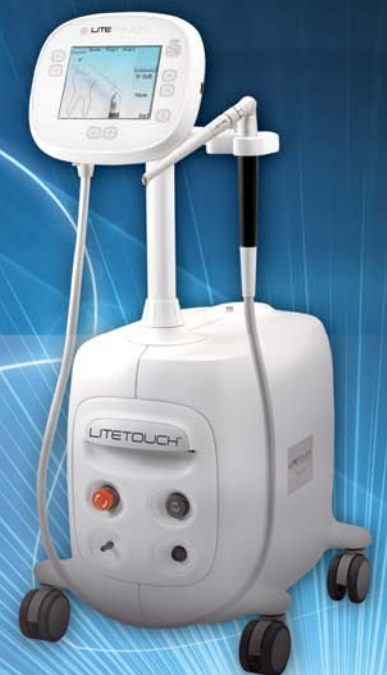Treatment of gingival hyper-pigmentation with the Er,Cr:YSGG laser

## | case report

Smile enhancement with laser technology — Predictable and esthetic

## | education

Start of the new Master of Science course Lasers in Dentistry at RWTH Aachen University



0277113



Preserved collagen fibrils  
of the intertubular dentin  
at the entrances to the  
dentinal tubules.

# The universe at your fingertips.



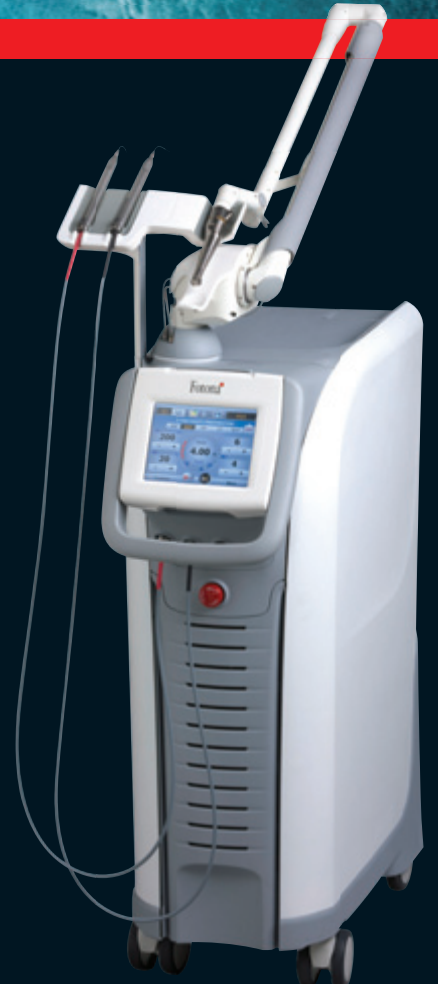## LightWalker®

### LightWalker TwinLight™ Treatment Concept

- Dentistry's two best wavelengths in one system: Nd:YAG and Er:YAG
- Optimum use of the unique laser-tissue interaction characteristics of each wavelength
- Nd:YAG is superior for coagulation and deep disinfection
- Er:YAG is uniquely efficient at ablating hard and soft tissues
- Dual wavelength procedures dramatically improve the outcome of treatments
- Maximum safety and efficacy

**Fotona**  
choose perfection

Visit [www.lightwalkerlaser.com](http://www.lightwalkerlaser.com) today!



www.fotona.com

88897100

# Under the **laser** light tree!



Prof Dr Norbert Gutknecht  
WFLD President  
Editor-in-Chief

\_The year 2011 was full with a numerous of highlights.

Depending on the regional cultures and customs, the christmas trees are differently adorned. A big variation of different light sources are found all around it, generating varying pleasant impressions of all kinds.

Looking at our "Laser Light Tree", the year 2011 generated a number of new laser light sources and laser light combination in medical and dental devices generating varying pleasant treatment methods. Presents under the Christmas trees can be compared with the different conference meetings, exhibitions, and congresses such as IDS, WFLD-ED and a number of national meetings.

All we can say—it was a rich and enlightening year.

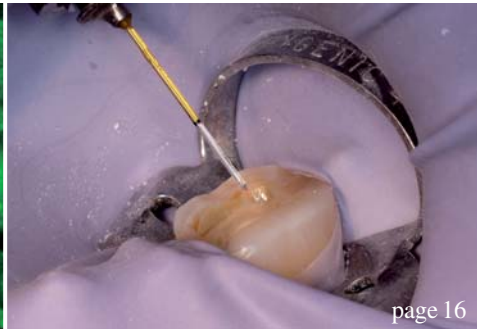
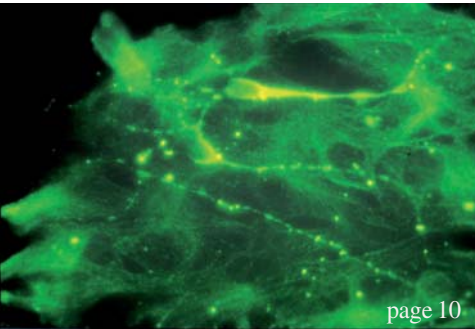
Now, the year 2012 is just around the corner, triggering special expectations. For sure, the WFLD congress in Barcelona will be the highlight in laser dentistry in the upcoming year 2012, where participants from all around the world will share their experiences and knowledge in their fields of expertise.

Looking forward to meet you in Barcelona I wish you all a Merry Christmas and a Happy New Year.

A handwritten signature in black ink, appearing to read 'Gutknecht', written in a cursive style.

Prof Dr Norbert Gutknecht  
Editor-in-Chief





| editorial

- 03 Under the **laser light tree!**  
| Prof Dr Norbert Gutknecht

| research

- 06 Treatment of gingival **hyper-pigmentation** with the Er,Cr:YSGG laser  
| Dr Gizem Berk *et al.*
- 10 **Some aspects** of the use of the Nd:YAG laser in periodontal therapy  
| Dr Talat Qadri *et al.*

| overview

- 16 Laser-assisted dentistry in the **daily office routine:** A “multi-wave” concept  
| Dr Kresimir Simunovic *et al.*

| case report

- 22 Smile enhancement with laser technology—**Predictable and esthetic**  
| Dr Hugh Flax
- 26 **Papillon-Lefèvre** syndrome  
| Dr Maziar Mir *et al.*

| user report

- 30 Er,Cr:YSGG laser for **cavity** preparation  
| Dr Ralf Borchers

| industry report

- 32 The use of the Er:YAG in laser-assisted **periodontal surgery**  
| Dr Avi Reyhanian

- 36 Laser in **daily practice** use  
| Prof Dr Frank Liebaug *et al.*

| meetings

- 39 **International** events 2012
- 40 Laser’s rightful place in **modern dentistry**  
| Jürgen Isbaner

| education

- 42 Fascination of **Laser Dentistry**
- 44 **Graduation** of the first Mastership Course of AALZ Greece  
| Dr Dimitris Strakas
- 46 Start of the new **Master of Science** course in Aachen  
| Dajana Klöckner

| news

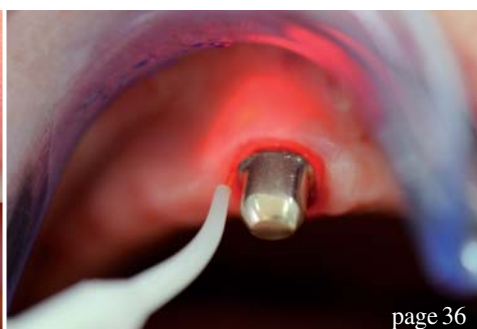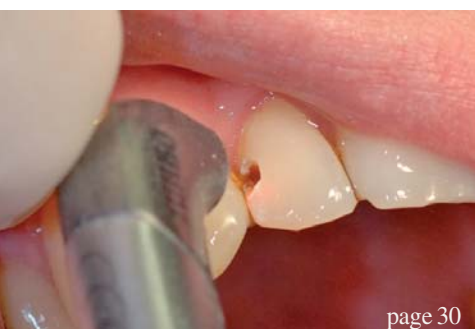- 48 **Manufacturer** News

| about the publisher

- 50 | imprint



Cover image courtesy of Syneron Dental Lasers, [www.synerondental.com](http://www.synerondental.com).  
Artwork by Sarah Fuhrmann, Oemus Media AG.



*Express  
your mastery*

Join the fast growing success of Syneron Dental Lasers

Presenting

**LITETOUCH™**

The unique fiber-free Er:YAG laser

Dentists' **1<sup>st</sup>** Choice  
for hard and soft tissue procedures

To explore cooperation opportunities please contact [dental@syneron.com](mailto:dental@syneron.com)  
W W W . S Y N E R O N D E N T A L . C O M



**Syneron™**  
DENTAL LASERS

# Treatment of gingival hyper-pigmentation with the Er,Cr:YSGG laser

## Clinical observation and one-year follow-up

**Authors**\_Drs Gizem Berk, Kubra Atici & Nuket Berk, Turkey

### Introduction

The colour of the gingiva is determined by several factors, including the number and size of blood vessels, epithelial thickness, quantity of keratinisation and pigments within the epithelium. Melanin, carotene, reduced haemoglobin and oxyhaemoglobin are main pigments contributing to the normal colour of the oral mucosa.<sup>1</sup> Frequently, the gingival hyper-pigmentation is caused by excessive melanin deposits mainly located in the basal and supra-basal cell layers of the epithelium.<sup>2</sup>

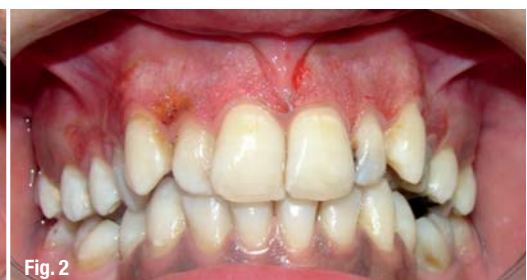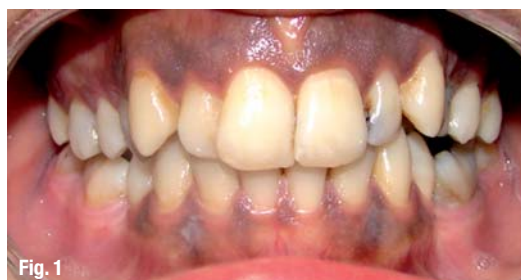Melanin is produced by specific cells—melanocytes residing in the basal layer—and is transferred to the basal cells, where it is stored in the form of melanosomes. It can also be found in keratinocytes of gingival epithelium.<sup>3</sup>

Melanin hyper-pigmented gingiva is an aesthetic problem for many individuals, particularly if the hyper-pigmentation is on the facial aspect of gingiva and visible during smiling and speech, es-

pecially those with gummy smiles.<sup>2</sup> The degree of pigmentation depends on a variety of factors, particularly the activity of melanocytes. Fair-skinned individuals are very likely to have non-pigmented gingival, but in darker-skinned persons, the chance of having pigmented gingiva is extremely high. The highest rate of gingival pigmentation has been observed in the area of incisors. The rate decreases considerably in the posterior regions.<sup>4</sup>

Gingival depigmentation has been carried out using surgical, chemical, electrosurgical and cryosurgical procedures.<sup>2, 5</sup> Recently, laser ablation has been recognised as one of the most effective, pleasant and reliable techniques.<sup>5</sup> Many laser systems such as Q-switched ruby laser, flash-lamp pumped-dye laser, argon laser, CO<sub>2</sub> laser, Nd:YAG laser and Er:YAG laser have been used for skin pigmentation.<sup>1, 2, 5</sup>

In the late 1990s, the Er,Cr:YSGG laser with a wavelength of 2,780 nm, frequency of 10 to 50 Hz, and pulse energy between 0 and 300 mJ was introduced as a safe and efficient wavelength to be



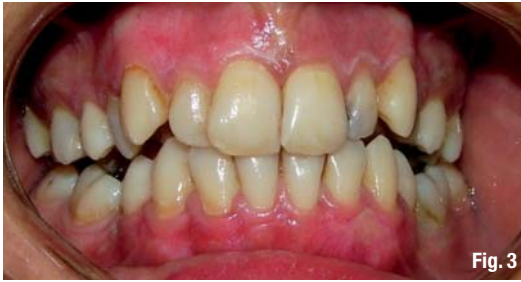

Fig. 3

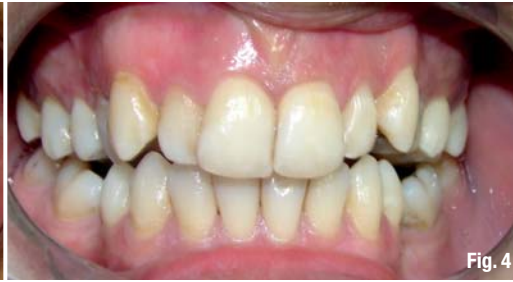

Fig. 4

used on hard and soft periodontal tissues, supported by several published studies regarding its beneficial effect in periodontal treatment.<sup>6,7</sup>

Re-pigmentation after gingival depigmentation is an important point of which clinicians should be aware. Reports of re-pigmentation are quite limited and varied.<sup>1</sup>

The following case shows successful depigmentation using an Er,Cr:YSGG laser and results regarding re-pigmentation obtained after a one-year follow-up period.

### Case report

A 29-year-old female, Turkish patient presented to our clinic who was not happy with her smile and aesthetic appearance owing to the pigmented regions, most pronounced in the anterior region. She had extensive pigmentation on her maxillary gingiva and moderate pigmentation on her mandibular gingiva (Fig. 1). The colour of the gingiva was dark to black. There was no contributory medical problem. The patient was very fearful of dental injections.

Preoperative pictures were taken and topical anaesthetic gel applied to the operatory field. In compliance with FDA rules, patient and staff used special eyeglasses for protection.

Er,Cr:YSGG laser application started with 600 sapphire tips (MG6, 6 mm) with 20 Hz, 140  $\mu$ s pulse duration (H mode) and 1.5 W, 20% air and 15% water in non-contact mode, about 1.5 mm away from

the tissue and with a sweeping motion localised only on the pigmented regions. The procedure was performed in a cervico-apical direction on all pigmented areas. After slight removal of the connective tissue, the setting was changed to 1.75 W, 40% air and 5% water in order to obtain more rapid ablation with less haemorrhaging but without thermal damage to the tissue.

Every five minutes, the operation field was wiped with sterile gauze soaked in 1% normal saline solution. The depigmentation procedure continued until no visible pigments remained. The complete treatment was performed in 30 min.

After wiping of the operative fields for the last time, there was slight bleeding (Fig. 2).

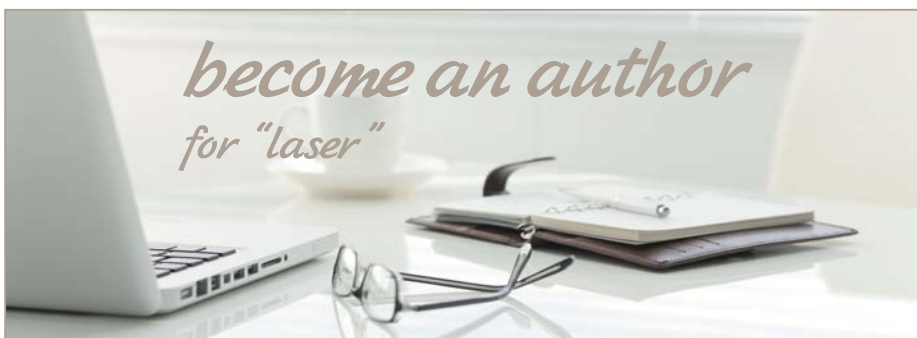No periodontal pack or additional material was applied to support the healing procedure.

The patient was recalled 24 hours, four days and seven days later and intra-oral pictures were taken (Fig. 3).

The patient was instructed to avoid smoking, alcohol, acidic beverages, and hot and spicy foods. He was advised to keep his wound area clean by brushing with a soft brush for the first week. No analgesic was prescribed.

### Clinical results

After 24 hours, the lased gingiva was partly covered with a thin layer of fibrin, which exfoliated during the first week after treatment. The ablated



Please contact Dajana Mischke  
✉ [d.mischke@oemus-media.de](mailto:d.mischke@oemus-media.de)



AD



wound was healed almost completely after four days. The colour of ablated gingiva was pink and healthy four days after ablation. The gingiva was visually similar to the normal untreated gingiva, completely without melanin pigmentation.

On the fourth day post-operatively, the patient was asked whether she had had any pain or discomfort within the past four days. She revealed that she had had a slight sensitivity on her maxilla about twelve hours post-operatively but did not need any medications and this did not cause any change in her usual routine. The patient was recalled six months and one year later, and intra-oral pictures were taken again (Fig. 4).

### Discussion

Numerous authors have reported successful results for the use of the lasers in hard and soft tissue applications. They include procedures common to oral surgery, oral pathology, restorative dentistry and periodontics.<sup>6-9</sup> There is abundant evidence that confirms markedly less bleeding, particularly of highly vascular oral tissues with laser surgery. Anecdotal reports that incising oral soft tissue with a laser is less painful than using a scalpel and therefore requires less oral aesthetic have no scientific confirmation to date.<sup>10</sup> In our study, topical aesthetic gel was applied, but no infiltration anaesthetic was used and we observed less bleeding during laser therapy compared with conventional surgical techniques. Post-operative pain from oral and otolaryngological surgical procedures has been claimed to be reduced in laser surgery. It is theorised that this may be due to protein coagulum that is formed on the wound surface, thereby acting as a biological wound dressing<sup>10,11</sup> and sealing the ends of the sensory nerves.<sup>12</sup> In the present study, patient satisfaction was high. There was no complaint of pain during treatment or post-operatively.

Some reports suggest that laser-created wounds heal more quickly and produce less scar tissue than conventional scalpel surgery.<sup>13,14</sup> In contrast, some studies have shown the delay of re-epithelisation of the laser wound compared with conventional wounds.<sup>15,16</sup> In our report about depigmentation treatment with the Er,Cr:YSGG laser, re-epithelisation was completed after seven days and the gingiva was similar to the normal untreated gingiva.

Re-pigmentation after depigmentation has been reported following the use of different techniques. The mechanism of re-pigmentation is not understood but according to the migration theory, active melanocytes from the adjacent pigmented

tissues migrate to treated areas, causing re-pigmentation.<sup>17</sup> Dummett and Bolden<sup>18</sup> observed partial recurrence of hyper-pigmentation in six out of eight patients after gingivectomy at one to four months, whereas Perlmutter and Tal<sup>17</sup> described partial recurrence after seven to eight years. Tal *et al.*<sup>19</sup> and Tal<sup>20</sup> did not observe re-pigmentation until 20 months after cryosurgical depigmentation. No recurrence of hyper-pigmentation was found in any of the four patients treated by Atsawasuwan *et al.*<sup>2</sup> at 11 to 13 months after gingival depigmentation using the Nd:YAG laser. Nakamura *et al.*<sup>21</sup> reported depigmentation with the CO<sub>2</sub> laser in ten patients. No re-pigmentation was seen in the first year, but four patients showed re-pigmentation at 24 months. Tal *et al.*<sup>1</sup> observed no re-pigmentation in any of the patients treated with the Er:YAG laser after six months.

In the present study, re-pigmentation was not observed during a one-year follow-up period. However, long-term observations are required to determine the efficiency of the Er,Cr:YSGG laser in hyper-pigmentation treatment.

### Conclusion

Treatment of gingival hyper-pigmentation by Er,Cr:YSGG laser radiation in a defocused mode was found to be a safe and effective procedure. Post-operative patient satisfaction in terms of aesthetic and pain was impressive. The gingiva healed uneventfully and completely regenerated with no infection, pain, swelling or scarring. No re-pigmentation had occurred after one year post-surgery. Based on these observations, the Er,Cr:YSGG laser is a good treatment choice for gingival hyper-pigmentation.

*Editorial note: A list of references is available from the publisher.*

_contact	laser
<p><b>Dr Gizem Berk</b>                  Denta Form Health Center                  Mahatma Gandhi Cad. No. 34                  06700 G.O.P.                  Ankara, Turkey</p> <p>Tel.: +90 312 4476090                  Fax: +90 312 4462782</p> <p>gizemberk@yahoo.com                  www.dentaform.com.tr</p>	



**Lay the Foundations to your  
successful Future now!**

*New course: 17-22 February 2012, Aachen Dental University College, Dubai*



## **Mastership Curriculum Laser Therapy in Dentistry**

- One year clinical Certification Course
- Use of different laser systems in skilltraining and practical sessions.  
Practical instruction on laser handling and their subsequent practical use
- Live operations on patients or via direct monitor transfer
- Training to become a certified Laser Safety Officer is part of the course
- An internet based e-learning environment supports the participants for the home study

### **Module I**

Laser Safety (LSO)  
Laser Construction

2 Days

### **Module II**

Diode-Lasers  
Photo-Dynamic Therapy

4 Days

### **Module III**

Er:YAG-Lasers  
Er,Cr:YSGG-Lasers

4 Days

### **Module IV**

Written Exam,  
Presentation of clinical cases

2 Days



Aachen Dental Laser Center

#### **More information:**

AALZ GmbH · Pauwelsstrasse 17 · 52074 Aachen · Germany  
Tel. +49 - 2 41 - 47 57 13 10 · Fax +49 - 2 41 - 47 57 13 29  
[www.aalz.de](http://www.aalz.de) · [info@aalz.de](mailto:info@aalz.de)

