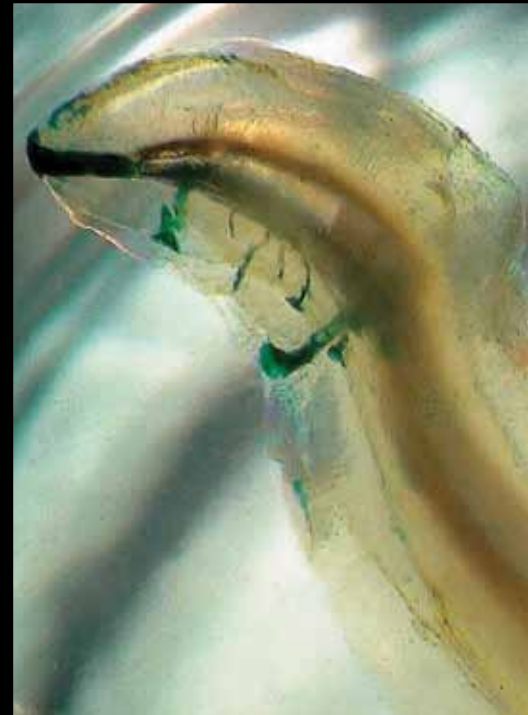
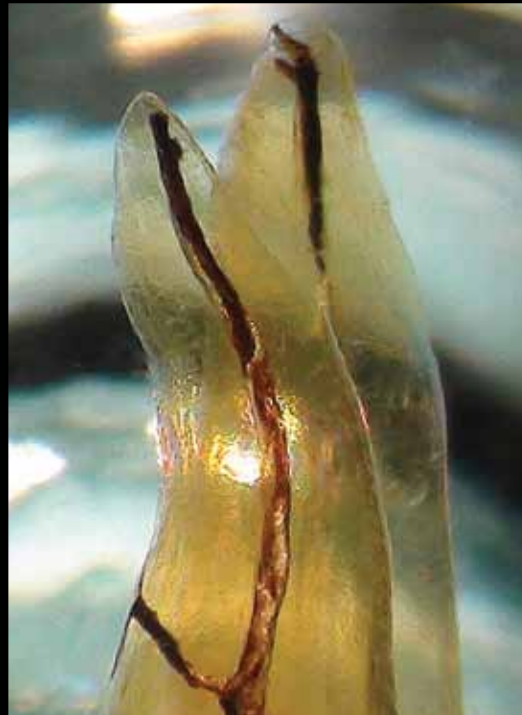
# roots

the international C.E. magazine of endodontics

1 2016



**C.E. article**

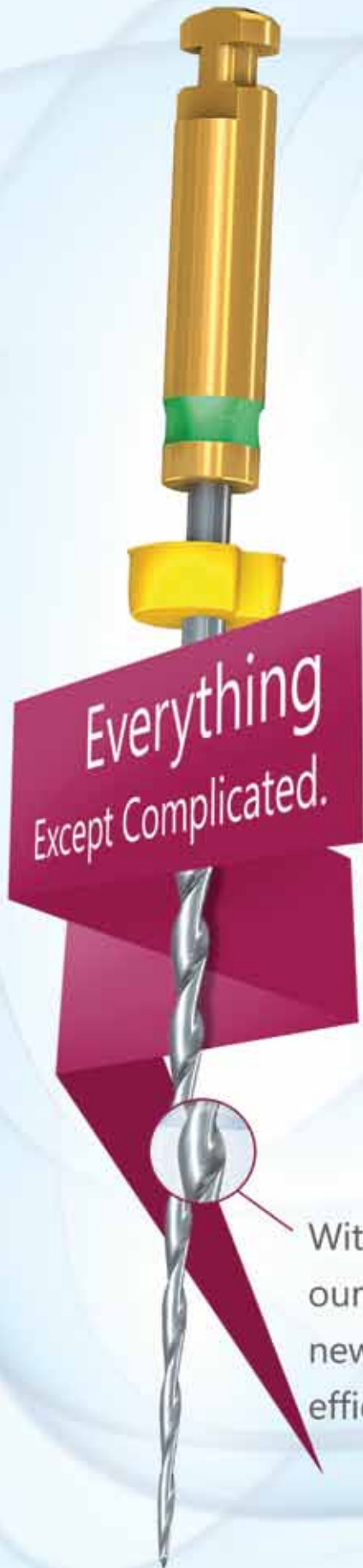Treatment planning:  
Retention of the  
natural dentition

**industry**

New rotary files

**education**

There is a better way



Everything  
Except Complicated.



With a Double-S crosscut design, our **F360**® file introduces new levels of flexibility and cutting efficiency to Endo treatment.



For safe, effective removal  
of instrument fragments.



The Komet® **Endo Rescue Kit** has revolutionized this procedure making it predictably quick and simple.

# A 10-year milestone for **Root Canal** **Awareness Week**



Fred Weinstein, DMD, MRCD(C),  
FICD, FACD

The American Association of Endodontists recently conducted Root Canal Awareness Week, a nationwide effort held each spring to encourage patients who need a root canal to see an endodontist to save their natural teeth.

This year marked the 10th anniversary of awareness week, which is definitely a milestone. Too many people have an irrational fear of dentists, and of root canal treatment in particular. The AAE is to be commended for helping dispel myths and for calling attention to our specialty.

Speaking of the AAE, perhaps you picked up this copy of *roots* at AAE16, the annual session in San Francisco, and you are reading this on the commute home. That's good, because this issue includes many helpful articles, including information on some of the many new endodontic products, from files and obturators to laser technology.

The centerpiece of this publication is Dr. Scott L. Doyle's article on retention of natural dentition and the replacement of missing teeth. This article, which originally appeared in AAE's *ENDODONTICS: Colleagues for Excellence* newsletter, is being made available in this issue of *roots* with the permission of the AAE. By reading this article, and then taking a short online quiz at [www.DTStudyClub.com](http://www.DTStudyClub.com), you will gain one ADA CERP-certified C.E. credit. Remember that with *roots*, you can always earn C.E. credit without lost revenue and time away from your practice.

To learn more about how you can take advantage of this C.E. opportunity, visit [www.DTStudyClub.com](http://www.DTStudyClub.com). You need only register at the Dental Tribune Study Club website to access these C.E. materials free of charge. You may take the C.E. quiz after registering on the DT Study Club website.

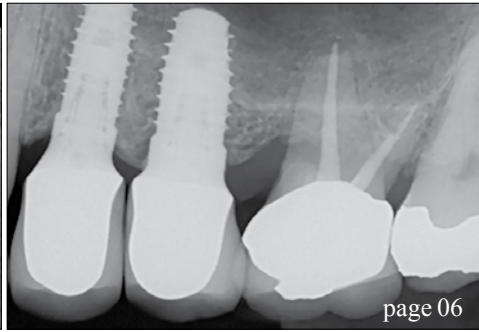
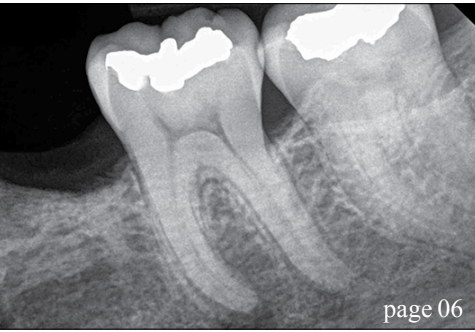
You can also access the vast library of C.E. articles published in the AAE's clinical newsletter by visiting [www.aae.org/colleagues](http://www.aae.org/colleagues).

I know that taking time away from your practice to pursue C.E. credits is costly in terms of lost revenue and time, and that is another reason *roots* is such a valuable publication. I hope you will enjoy this issue and that you will take advantage of the C.E. opportunity.

As always, I welcome your comments and feedback.

A handwritten signature in cursive script that reads "Fred".

Fred Weinstein, DMD, MRCD(C), FICD, FACD  
Editor in Chief



| **C.E. article**

- 06 **Treatment planning:** Retention of the natural dentition and the replacement of missing teeth  
\_Scott L. Doyle, DDS, MS

| **industry education**

- 12 There is a **better way** (and LVI can show you how to get there)  
\_Mark Duncan, DDS, FAGD, LVIF, DICOI, FICCMO

| **industry**

- 14 **Therma-Flow** Composite Warming Kit
- 16 New **Pac-Dent** rotary endodontic file system
- 17 Fotona launches **ST PRO Lightwalker** dental laser

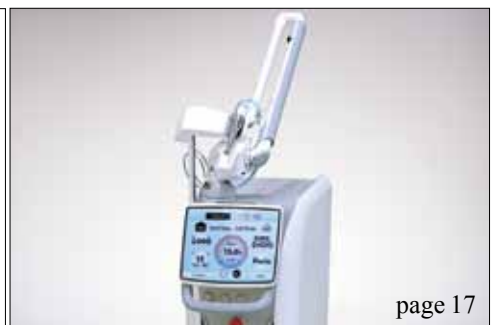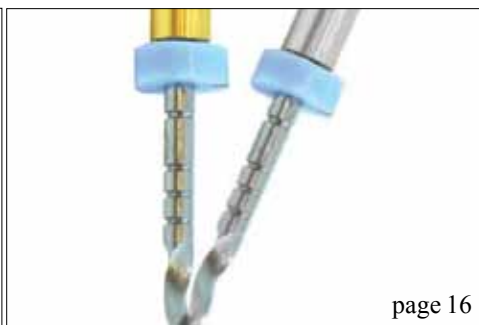| **about the publisher**


- 18 \_imprint



| **on the cover**

Photographs provided by Dr. Craig Barrington, [cbdds002@yahoo.com](mailto:cbdds002@yahoo.com).





Never accept  
“good enough.”

**Average. Adequate. Good enough.** For too long, standard root canal treatment has left bacteria, biofilm and smear layer behind. And for too long, treatment failure has been considered unfortunate, but unavoidable. That’s why Sonendo has developed breakthrough Multisonic Ultracleaning™ technology, giving you the power to deliver a level of cleaning that’s anything but “good enough.”



The GentleWave® Treatment Instrument provides **disinfection** that leads to **fast healing** with **minimal instrumentation**.

Talk to Sonendo® about the GentleWave® System today—and go beyond good enough. Visit [sonendo.com/better](http://sonendo.com/better).

**GENTLEWAVE®**  
ROOT CANAL THERAPY

VISIT US AT AAE16! APRIL 6-9 | SAN FRANCISCO | BOOTH #317



\*Sigurdsson A et al. (2016) J Clin Exp Dent.

© 2016 Sonendo, Inc. All rights reserved. SONENDO, the SONENDO logo, GENTLEWAVE, the GENTLEWAVE logo, MULTISONIC ULTRACLEANING, and SOUND SCIENCE are trademarks of Sonendo, Inc. MM-0177 Rev 01

# Treatment planning: Retention of the natural dentition and the replacement of missing teeth

Author\_Scott L. Doyle, DDS

## \_c.e. credit

This article qualifies for C.E. credit. To take the C.E. quiz, log on to [www.dtstudyclub.com](http://www.dtstudyclub.com). Click on 'C.E. articles' and search for this edition (Roots C.E. Magazine — 1/2016). If you are not registered with the site, you will be asked to do so before taking the quiz. You may also access the quiz by using the QR code below.



Preservation of the natural dentition is the primary goal of dentistry. Published surveys indicate that patients generally value teeth and express a desire to save their natural dentition in favor of extraction whenever possible.<sup>1,2</sup> Significant technological and biological improvements have been made in all disciplines of dentistry, making long-term retention of natural teeth more attainable. Patients entrust dental professionals to make appropriate recommendations regarding the maintenance and restoration of their oral health and function. It is essential to employ an evidence-based, interdisciplinary approach that addresses the interests of the patient when determining the best possible course of treatment.

In July 2014, the American Association of Endodontists, in collaboration with the American College of Prosthodontists and the American Academy of Periodontology, hosted a two-day Joint Symposium titled "Teeth for a Lifetime: Interdisciplinary Evidence for Clinical Success." Approximately 375 general dentists and specialists assembled in Chicago to focus on preserving the natural dentition.

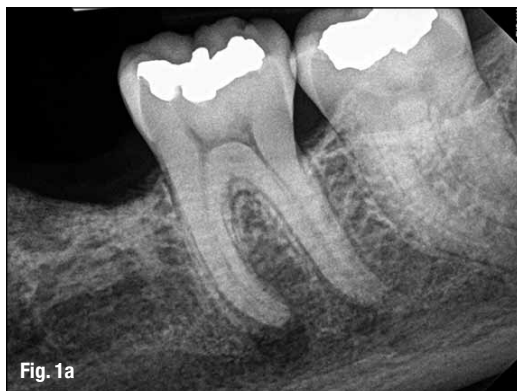The educational program included evidence-based presentations on advanced regenerative techniques, improvements in technology, minimally invasive restorative methods and best prac-

tices for interdisciplinary treatment planning. Dr. Alan Gluskin, chair of the 2014 Joint Symposium Planning Committee, concluded that the current evidence directs clinicians to consider saving the natural dentition as the first option when developing treatment plans.

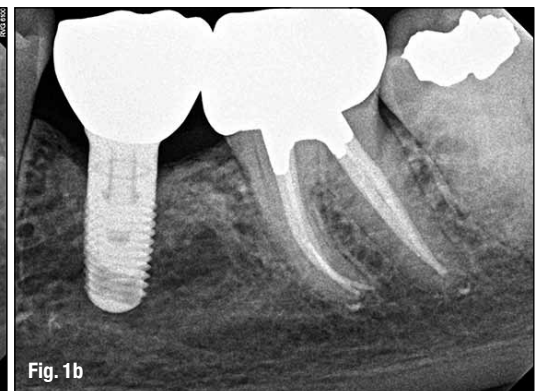
Dental implants are one of the most significant advancements in contemporary dentistry. This innovation has had profound effects on endodontic, periodontic and prosthodontic treatment planning for the rehabilitation of edentulous spaces and for teeth with an unfavorable prognosis.<sup>3</sup> Implant-supported restorations minimize unnecessary preparation of intact abutment teeth and allow fixed prosthodontic replacement when suitable abutments are absent. With appropriate usage and case selection, implant dentistry provides a viable option for the replacement of missing teeth.<sup>4,5</sup>

There has been an increasing trend toward replacing diseased teeth with dental implants. Often, an inadequate or inappropriate indication for tooth extraction has resulted in the removal of teeth that may have been salvageable.<sup>6</sup> Teeth compromised by pulpal or periodontal disease have value and should not be extracted without thoroughly evaluating restorability and potential retention therapies.<sup>7</sup>

**Fig. 1a** Pre-op image of tooth #19 with pulp necrosis and symptomatic apical periodontitis. The patient is interested in rehabilitation of the edentulous space. (Photos/Provided by American Association of Endodontists)



**Fig. 1b** Three-year recall image. The patient has benefited from both root canal treatment and implant therapy. Courtesy of Dr. Tyler Peterson and the University of Minnesota School of Dentistry.



A recent systematic review published in the Journal of the American Dental Association highlights a key question: "Is the long-term survival rate of dental implants comparable to that of periodontally compromised natural teeth that are adequately treated and maintained?"<sup>8</sup> Nineteen studies with a follow-up period of at least 15 years were included in the analysis.

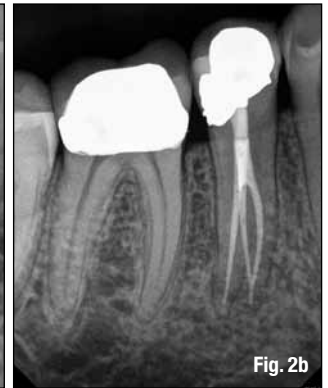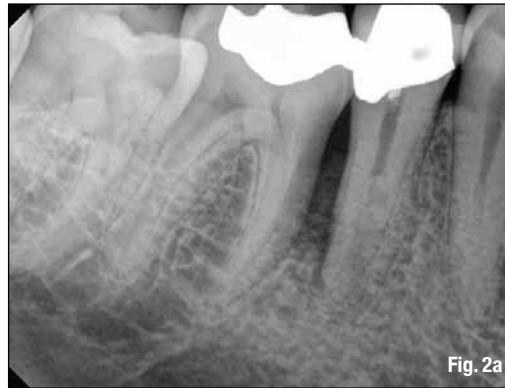The results show that implant survival rates do not exceed those of compromised but adequately treated and maintained teeth. These findings support other studies comparing long-term survival of implants and natural teeth,<sup>9,10</sup> providing an important message: Periodontally compromised teeth can be retained with quality treatment and appropriate maintenance. Therefore, it may be advisable to postpone implant consideration for the periodontitis-susceptible patient to fully utilize and extend the capacity of the natural dentition.<sup>11</sup>

### \_Treatment planning options

A key focus of the Joint Symposium involved treatment planning decisions regarding endodontic treatment and implant therapy. Should a tooth with pulpal disease be retained with root canal treatment and restoration, or be extracted and replaced with an implant-supported restoration? This assessment involves a challenging and complex decision-making process that must be customized to suit the patient's needs and desires.<sup>12-14</sup> The topic has received considerable attention in the literature, the media and at dental continuing education courses.

Endodontic treatment and implant therapy should not be viewed as competing alternatives, rather as complementary treatment options for the appropriate patient situation (Figs. 1a, b). Root canal treatment is indicated for restorable, periodontally sound teeth with pulpal and/or apical pathosis. Endodontic treatment on teeth with nonrestorable crowns or teeth with severe periodontal conditions is contraindicated, and other options such as implant placement should be considered.<sup>15</sup>

When making treatment decisions, the clinician should consider factors including outcome assessment, local and systemic case-specific issues, costs, the patient's desires and needs, esthetics, potential adverse outcomes and ethical factors.<sup>16</sup>



**Fig. 2a** Pre-op image of tooth #29. Note lateral radiolucency and complex canal anatomy.

**Fig. 2b** Two-year recall image reveals both excellent endodontic and restorative treatment. Note healing of lateral radiolucency. Courtesy of Dr. Joe Petrino.

### \_Outcome assessment: Success and survival

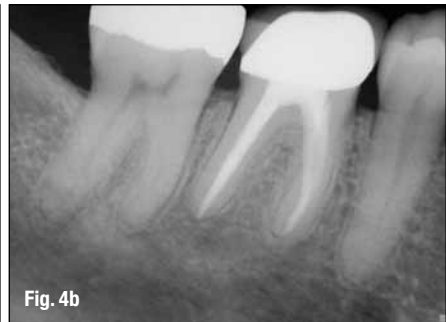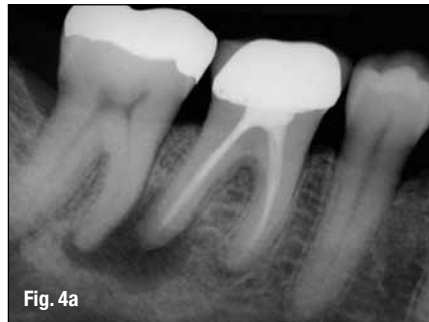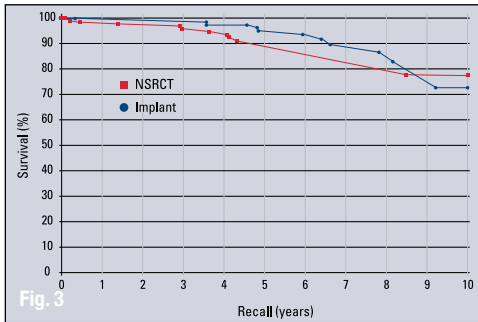
Treatment outcomes play a key role in the assessment of different treatment options. Patients often ask whether a procedure is going to be successful or not. This question can be challenging for a clinician to answer due to the variety of reported outcomes in the literature.<sup>17</sup> There are differences in the methodology and criteria used to evaluate the outcomes for root canal treatment and implant prosthetics, which makes comparisons between success rates difficult, if not impossible.<sup>18</sup>

Endodontic studies have historically used "success" and "failure" as outcome measures and have focused on a strict combination of radiographic and clinical criteria.<sup>19</sup> In contrast, the implant literature has primarily reported "survival,"<sup>20,21</sup> i.e., the implant is either present or absent. Therefore, implant studies that solely evaluate survival as an outcome measure will likely publish higher success rates than endodontic studies that rely on biologic healing and factors related to the entire restored tooth. To establish more valid and less biased comparisons, the same outcome measures should be used. A more patient-centered measure is to compare the outcome of survival, which is considered to be an asymptomatic tooth/implant that is present and functioning in the patient's mouth.<sup>22,23</sup>

Multiple large-scale studies including millions of teeth have used survival to assess the outcome following root canal treatment. An investigation using an insurance database of more than 1.4 million root canal-treated teeth demonstrated that 97 percent were retained within an eight-year follow-up period.<sup>24</sup> Other studies show similarly high survival rates

Authors	Number of Teeth	Follow-up (years)	Survival (percent)
Salehrabi and Rotstein (24)	1,463,936	8	97
Chen et al. (25)	1,557,547	5	93
Lazarski et al. (26)	44,613	3.5	94.4

**Table 1** Survival rates following initial nonsurgical root canal treatment. (Table/Provided by American Association of Endodontists)



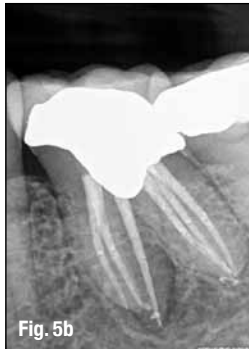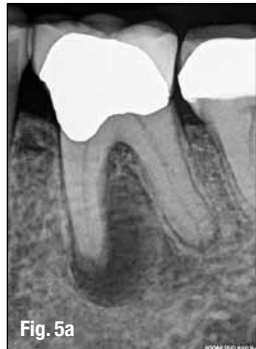**Fig. 3** A matched-case comparison of survival rates after treatment with either a restored endodontically treated tooth (n=196) or a restored single-tooth implant (n=196) performed at the same institution. *J Endod* 2006;31.

**Fig. 4a** Pre-op image of tooth #30 with previous endodontic treatment and persistent apical periodontitis.

A dentist initially recommended extraction and replacement of this tooth with an implant. The patient requested a second opinion from an endodontist who determined the tooth to be treatable.

**Fig. 4b** Four-year recall image demonstrates apical healing following nonsurgical retreatment.

Accurate diagnosis prevented the unnecessary treatment of tooth #31. Courtesy of Dr. Martin Rogers.



**Fig. 5a** Pre-op image of tooth #19 with pulp necrosis and chronic apical abscess.

**Fig. 5b** Two-year recall image demonstrates excellent endodontic treatment and healing of apical periodontitis. Courtesy of Dr. Deb Knaup.

(Table 1).<sup>25,26</sup> An epidemiological approach allows for the assessment of tooth retention from a large sample of patients experiencing actual care in private practices. Systematic reviews<sup>27</sup> and controlled studies from academic settings complement the previous findings. Two prospective trials each reported 95 percent survival rates at four years<sup>28</sup> and four to six years<sup>29</sup> for teeth after initial root canal treatment.

### Predictable tooth retention: Nonsurgical root canal treatment and restoration

The majority of endodontic treatment is performed by general dentists with a high degree of success.<sup>26</sup> For complex cases, referral to an endodontist with additional training and expertise may result in more favorable outcomes<sup>30</sup> and positive patient experiences.<sup>31</sup> Interdisciplinary care is important for the management of endodontically treated teeth. The restorative dentist plays a significant role in the outcome by providing an appropriate and timely restoration.<sup>32</sup> Root canal treatment is not complete until the tooth is coronally sealed and restored to function. Multiple studies have confirmed that a definitive restoration has a significant impact on survival.<sup>24,25,27,28,33</sup> Therefore, the likelihood of a favorable outcome increases with both skillful endodontic care and prompt restorative treatment (Figs. 2a, b).<sup>34</sup>

Advancements in technology aid in attaining high levels of tooth retention. The dental operating microscope, nickel-titanium instruments, apex locators, enhanced irrigation protocols and dentin

preservation strategies are examples of improvements that allow clinicians to predictably manage a greater range of treatment options. Additionally, cone-beam-computed tomography facilitates more accurate diagnosis and improved decision-making for the management of endodontic problems.<sup>35,36</sup>

### Comparative studies: Endodontically treated teeth and single-tooth implants

Large-scale systematic reviews have addressed the relative survival rates of endodontically treated teeth and single-tooth implants. The Academy of Osseointegration conducted a meta-analysis using 13 studies (approximately 23,000 teeth) on restored endodontically treated teeth and 57 studies (approximately 12,000 implants) on single-tooth implants. The outcome data demonstrated no difference between the two groups during any of the observation periods.<sup>37</sup> Another systematic review supported by the American Dental Association compared the outcomes of endodontically treated teeth with those of a single-tooth implant-restored crown, fixed partial denture and no treatment after extraction. At 97 percent, the long-term survival rate was essentially the same for implant and endodontic treatments. Both options were superior to extraction and replacement of the missing tooth with a fixed partial denture.<sup>38</sup>

Retrospective studies also have compared the outcomes for the two treatment options. A study conducted at the University of Minnesota compared the outcomes of 196 restored endodontically treated teeth with 196 matched single-tooth implants.<sup>39</sup> Both groups had 94 percent survival rates. The survival curves for these two groups are provided in Figure 3. Another investigation from the University of Alabama provided similar results.<sup>40</sup>

Based upon similar survival rates, the decision to treat a compromised tooth endodontically or replace it with an implant must be based on factors other than treatment outcome.<sup>37,41</sup> Several factors influence the decision-making process.<sup>42-44</sup> The following lists provide an overview of case-specific factors that should be considered in making this treatment decision.



## \_Systemic factors

- The list of potential risk factors for peri-implantitis or implant failure is extensive. It includes systemic disease, genetic traits, chronic drug or alcohol consumption, smoking, periodontal disease, radiation therapy, diabetes, osteoporosis, dental plaque and poor oral hygiene.<sup>45</sup>

- There are few medical conditions that directly affect endodontic treatment outcomes. Risk factors that may be associated with decreased survival of root canal-treated teeth include smoking,<sup>46</sup> diabetes,<sup>28,46</sup> systemic steroid therapy<sup>28</sup> and hypertension.<sup>47</sup>

- Patients taking antiangiogenic or antiresorptive (i.e., bisphosphonates) medications may have an increased risk for developing medication-related osteonecrosis of the jaw. This may affect treatment planning for both implant and endodontic treatment.

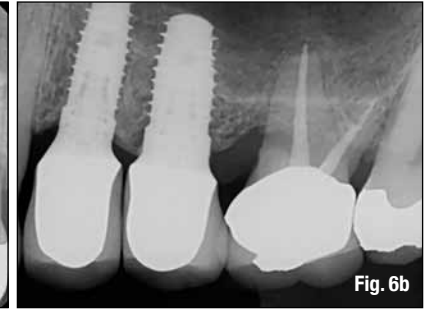
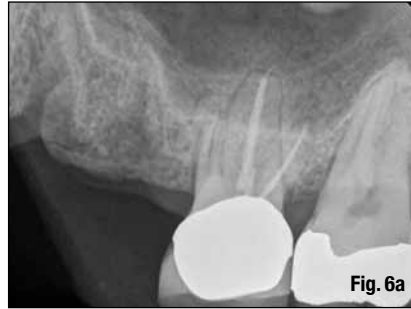- It is generally recommended to wait for the completion of dental and skeletal growth prior to implant placement.<sup>48</sup>

## \_Local factors

- Accurate diagnosis.
- Restorability assessment: removal of caries/restorations; adequate ferrule.
- Strategic nature of the tooth as it fits into the comprehensive restorative plan.
- Caries risk and oral hygiene.
- Periodontal assessment: tissue biotype, adequate biologic width.
- Presence of crack(s), root fracture(s), resorption.
- Occlusion and parafunction.
- Teeth with less than two proximal contacts and those serving as fixed partial denture abutments may have lower survival.<sup>27</sup>
- Need for adjunctive treatment (crown lengthening, orthodontic extrusion, sinus lift, bone graft, etc.), which may impact financial cost and time to function.
- Quantity and quality of bone.
- Proximity to anatomical structures (maxillary sinus, inferior alveolar nerve, etc.)
- Implant esthetics in the anterior region may be challenging.<sup>49</sup>

In addition to systemic and local factors, it is critical to include the patient's concerns during treatment planning. Common patient-centered factors include costs, treatment duration, satisfaction with treatment and the potential for adverse outcomes.

Financial considerations can influence a patient's decision when weighing treatment options. The availability of dental insurance may also impact choices.<sup>50</sup> Endodontic treatment and restoration



offer considerable economic advantages to the patient.<sup>51-53</sup> A benefit of root canal treatment is the short time frame required to completely restore both dental function and esthetics. In one study of about 400 patients, the restored single-tooth implant showed a longer average and median time to function than similarly restored endodontically treated teeth. Additionally, the implant group had a higher incidence of post-treatment complications requiring subsequent treatment interventions.<sup>39</sup> This increased post-operative care can impact patients in terms of additional visits, lost wages and unforeseen costs.

Clinicians should consider the patient's preferences, which are often related to function, comfort and esthetics. Tooth loss is associated with an impaired quality of life,<sup>54</sup> and surveyed patients express a clear desire to save their natural dentition whenever possible.<sup>2</sup> Large-scale surveys of post-endodontic patients have demonstrated that endodontic treatment not only preserves the natural tooth, but also significantly improves patients' quality of life.<sup>55</sup> More than 97 percent of patients report being satisfied with their endodontic treatment.<sup>31</sup> If an implant is used to restore an edentulous space, a similarly high percentage of patients have a positive experience with implant therapy.<sup>56</sup> Furthermore, comparative studies demonstrate that patients report a high degree of satisfaction with the overall experience following both procedures.<sup>2,15</sup>

Despite high survival rates, both endodontically treated teeth and implants are susceptible to complications. Nonrestorable caries, prosthetic failures, periodontal disease, crown/root fractures and specific endodontic factors are examples of complications following root canal treatment.<sup>57</sup> Complications associated with implants and related prostheses include: surgical, implant loss, bone loss, peri-implant soft-tissue, mechanical and esthetic/phonetic.<sup>58</sup> A retrospective study directly compared the rates of additional interventions related to complications. Implant cases had a substantially higher need for subsequent intervention and maintenance visits than endodontically treated teeth.<sup>40</sup> However, a more recent prospective study suggests that patients from both groups have minimal complications at one-year follow-up.<sup>15</sup>

**Fig. 6a** Pre-op image. Tooth #14 was determined to have a vertical root fracture of the MB root. The patient expressed a strong desire to retain the natural dentition but also to rehabilitate the edentulous space.

**Fig. 6b** Two-year recall image. Tooth #14 had retreatment and resective surgery on the MB root. Two dental implants have restored the edentulous space. Courtesy of Dr. Brian Barsness and the University of Minnesota School of Dentistry.