


# implants

international magazine of oral implantology



## research

L-PRF in different intraoral applications

## case report

Horizontal ridge augmentation and implantation

## interview

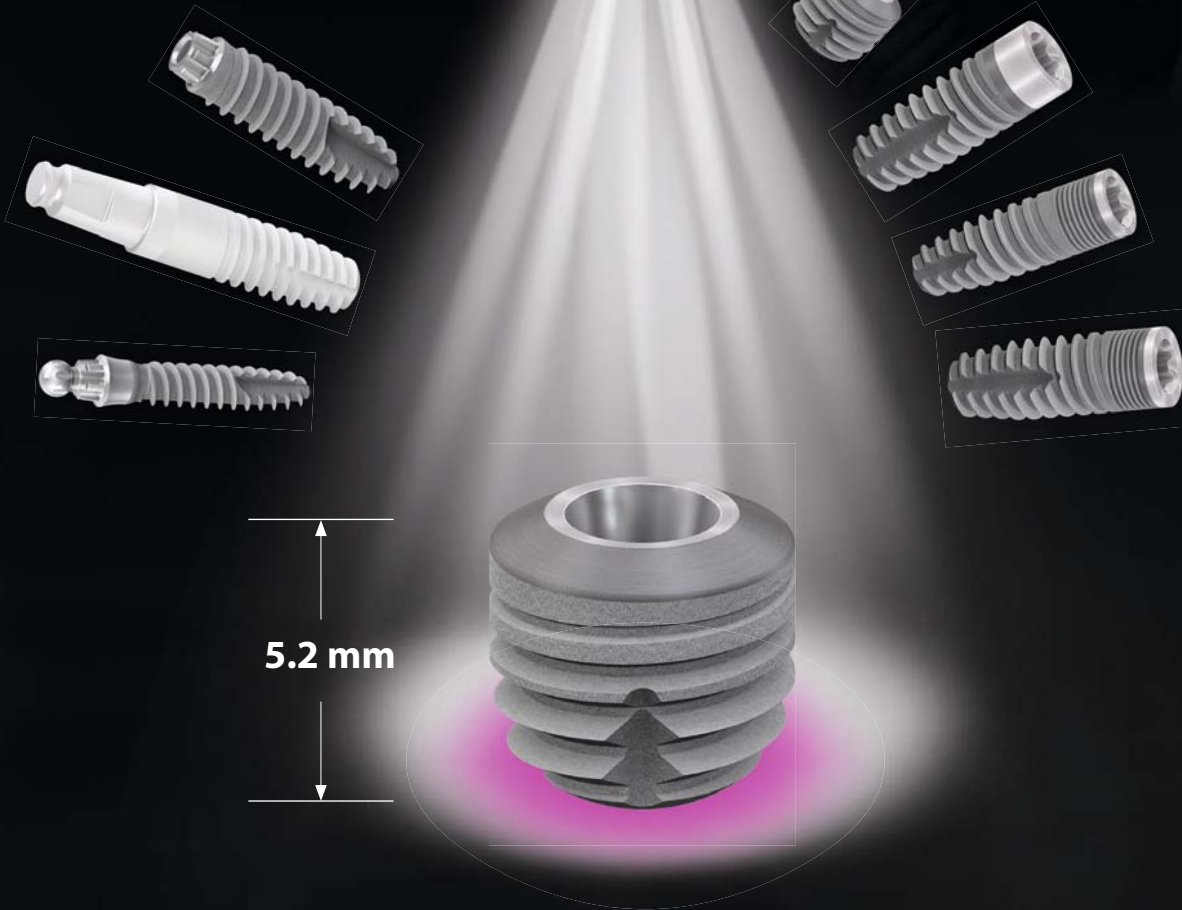
A pipeline filled with groundbreaking innovations



Limited bone quantity?

copaSKY ultrashort!

**SKY** 



Treat your patients with limited bone quantity with the ultrashort copaSKY and avoid bone augmentation.

This reduces costs and protects hard and soft tissue.

DENTAL INNOVATIONS  
SINCE 1974

bredent  
group

**Dr Georg Bach**

Scientific Director



# A glimpse into the future of implantology

Dear colleagues,

The German Association of Dental Implantology (DGZI) would like to cordially invite you to the second Future Congress for Dental Implantology, to be held on 4 and 5 October 2019 in Munich in Germany.

Granted, we were a little nervous when we first presented our new congress format to the public in Düsseldorf in Germany last year. By completely realigning our annual congress, we set ambitious goals for the grand challenges and were successful in meeting them. Here, we have succeeded particularly well in combining innovation with tradition.

We have demonstrated that we, as Europe's oldest expert association on dental implantology, stand for values, yet still have the courage to get new ideas off the ground and at times choose unconventional paths to do so. The implantology sector is being transformed and our field of work is evolving rapidly. The DGZI also faces up to this development.

Courage and visions are now more important than ever, because implantology, our own dental specialisation area, faces enormous challenges.

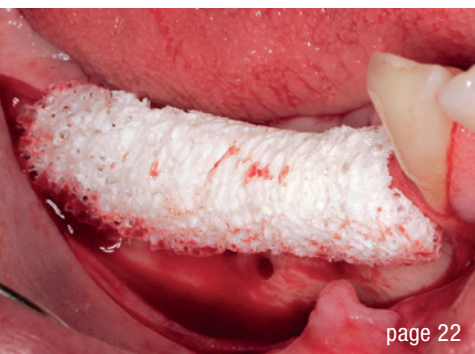## **Perio-Implantology: Implants, Bone & Tissue— Where are we today and where are we headed?**

That is the guiding theme of our second Future Congress for Dental Implantology. Or in other words, the implant in the context of bone and tissue. A top-class team of university lecturers, as well as numerous practitioners, will present the latest developments and discuss them with the participants in lectures, live broadcasts and within the framework of table clinics.

Our goal is clear: If you as an attendee of our second Future Congress for Dental Implantology leave the congress hall of the Munich Westin Grand Hotel after two top-level training days, you will not only know what works in implantology and why, no, you will also know what the future of implantology will be like.

I look forward to an exciting Future Congress with you!

Yours, Dr Georg Bach



page 22



page 28



page 44

Cover image courtesy of Bicon  
www.bicon.com



**editorial**

A **glimpse** into the future of **implantology** 03  
Dr Georg Bach

**research**

**L-PRF** in different intraoral **applications** (Part IV) 06  
Prof. Nelson R. Pinto, Dr Andy Temmerman, Ana B. Castro,  
Simone Cortellini, Prof. Dr Wim Teughels & Prof. Dr Marc Quiryren

**case report**

**Guided** implant **placement** in the **anterior** zone 12  
Drs Burzin Khan & Purvi Bhargava

Extraction, **tissue management** and **implant surgery** over the **long term** 18  
Dr Philippe Jourdan

Horizontal ridge **augmentation** and **implantation** 22  
Dr Orcan Yüksel

**interview**

A **pipeline** filled with groundbreaking **innovations** 28

**Finding** the missing pieces of the puzzle in **peri-implantitis** 32

The logic behind the Bicon **SHORT** implant 34

**events**

The **city of love** as backdrop for a  
successful **German–Italian** congress 44

**news**

manufacturer news 38

news 48

**about the publisher**

imprint 50

# MAKE NO BONES ABOUT IT.

CONFIDENCE IN ALL BONE QUALITIES:  
PROGRESSIVE-LINE



## SPECIALIST IN SOFT BONE:

- Apical conical area for high primary stability in soft bone
- Thread up to the apex, ideal for immediate implantation
- Thread design with deeply engaging thread flanks
- Flexible drill protocol for preferred stability

[WWW.CAMLOG.COM](http://WWW.CAMLOG.COM)

a perfect fit™

camlog

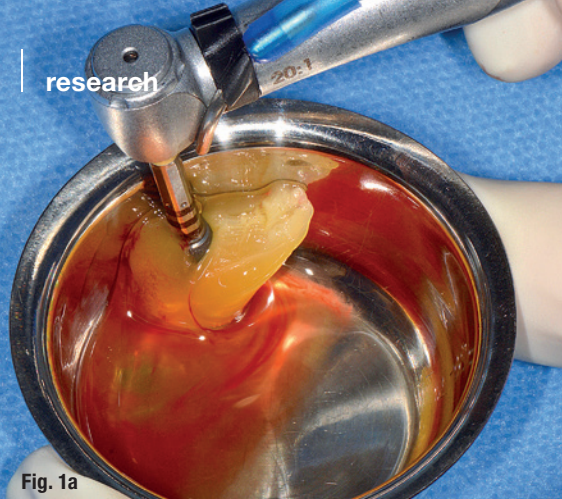

Fig. 1a

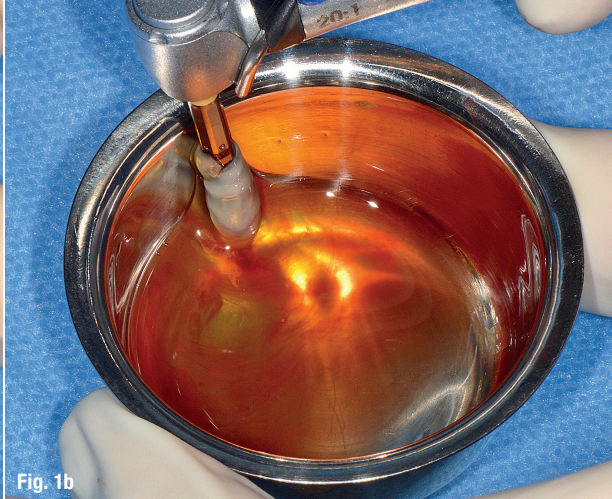

Fig. 1b

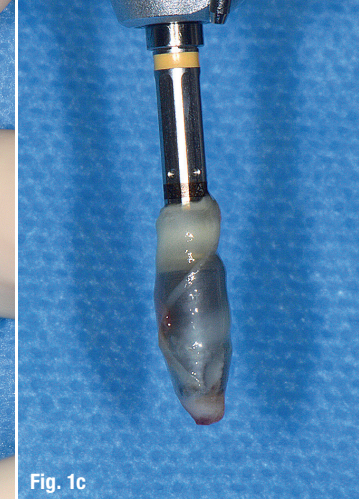


Fig. 1c

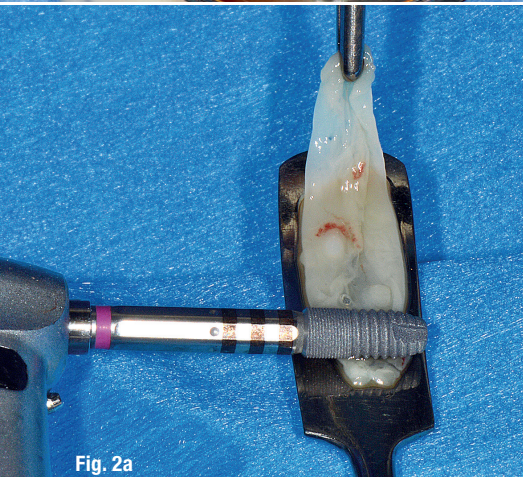


Fig. 2a

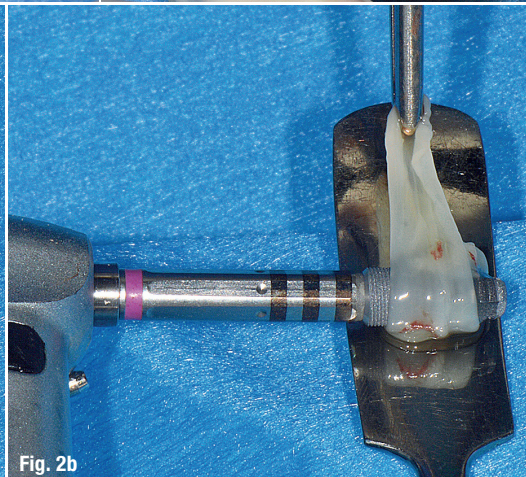


Fig. 2b

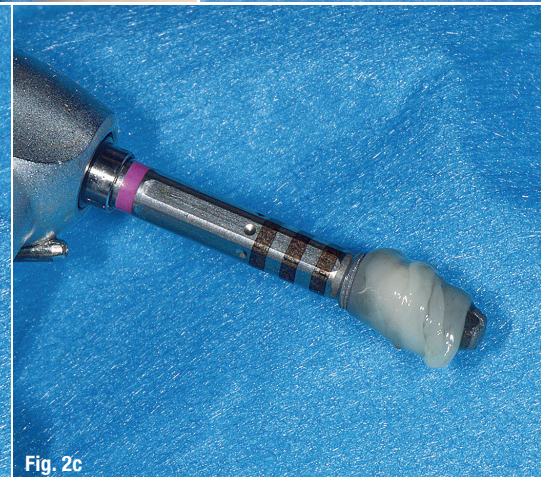


Fig. 2c

**Techniques for implant coating with L-PRF:** **Fig. 1a:** Placement of the implant against an L-PRF clot in a titanium dish. **Figs. 1b & c: b)** Slow rotation of the implant in contact with the clot while exerting pressure against the wall of the dish. **c)** The implant is wrapped in L-PRF. **Fig. 2a:** Placement of L-PRF membrane (carried on a titanium spatula) in contact with the implant. **Figs. 2b & c:** Membrane wrapped around the implant (via rotation) with the membrane face at the outside.

# L-PRF in different intraoral applications

## Part IV: Three preparation protocols

Prof. Nelson R. Pinto<sup>1</sup>, Dr Andy Temmerman<sup>2</sup>, Ana B. Castro<sup>2</sup>, Simone Cortellini<sup>2</sup>, Prof. Dr Wim Teughels<sup>2</sup> & Prof. Dr Marc Quirynen<sup>2</sup>

<sup>1</sup> Department of Periodontology and Oral Implantology, Faculty of Dentistry, Universidad de Los Andes, Santiago, Chile

<sup>2</sup> Department of Oral Health Sciences, Section of Periodontology, KU Leuven & Dentistry, University Hospitals, KU Leuven, Leuven, Belgium

**Favourable wound healing** has always been a major quest in dental surgery. It is a concern in both healthy and compromised patients. In an effort to improve and accelerate healing of both hard- and soft-tissue, substitutes, including growth factors and biomaterials, have traditionally been employed. Membranes were also introduced to separate tissue. Recent research clearly indicates that leukocyte- and platelet-rich fibrin (L-PRF; a second generation of platelet concentrates) significantly enhances wound healing in both soft- and hard-tissue. Evidence

now supports the assertion that this has the potential to replace the above-mentioned substitutes in many situations. Clinical procedures benefit from recent advancements in platelet concentrate protocols, including soft-tissue healing, plastic periodontal surgery, gingiva enlargement, medication-related osteonecrosis of the jaw, regeneration of infra-bony defects, ridge preservation, sinus augmentation, immediate implant placement and implant osseointegration itself. An added benefit is that these platelet concentrate protocols offer signifi-

cantly lower-cost treatment solutions to our patients, owing to their ease of use and inexpensive preparation.

Major indications for the use of L-PRF and the step-by-step preparation of L-PRF clots, membranes and plugs, as well as application approaches to open-flap debridement and ridge preservation, were introduced in the first two parts of this article series. In the third part, two treatment approaches to sinus floor elevation, in which L-PRF is used as grafting material, were presented. In this fourth and last part of the series, implant coating techniques with L-PRF, as well as a coronal advanced flap procedure with use of L-PRF as grafting material, will be described. In addition, a protocol for the preparation of a PRF-Block (Intra-Lock) will be presented.

### Step-by-step approach to implant coating with L-PRF

- Prepare implant osteotomy according to the required implant protocol.
- Use L-PRF exudate, obtained after compression of L-PRF clots, to irrigate and clean the osteotomy.
- Position the implant on the implant driver.

#### Option 1

- Place an L-PRF clot in a small titanium dish.
- Rotate the implant slowly in the clot while exerting a little pressure against the wall of the dish until the L-PRF is fully wrapped around the implant (Figs. 1a-c).
- Insert the implant into the osteotomy.

#### Option 2

- Place the implant in contact with the L-PRF membrane (Fig. 2a).
- Rotate the implant slowly and wrap the L-PRF membrane around it with the face side (the red side) of the membrane at the outside (Figs. 2b & c).
- Insert the implant into the osteotomy.

#### Option 3

- Place the L-PRF membrane in contact with the implant (Fig. 3a).
- Rotate the implant slowly until the entire implant surface has been in contact with the membrane; remnants of the L-PRF membrane become visible on the implant surface (Figs. 3b & c).
- Place the face side of the membrane into the osteotomy.
- Insert the implant into the osteotomy.

#### Option 4

- Collect the L-PRF exudate with a sterile syringe after compression of the clots (Fig. 4a).
- Rinse the implant surface with the L-PRF exudate before insertion (Figs. 4b & c).
- Place the face side of the membrane into the osteotomy.
- Insert the implant into the osteotomy.

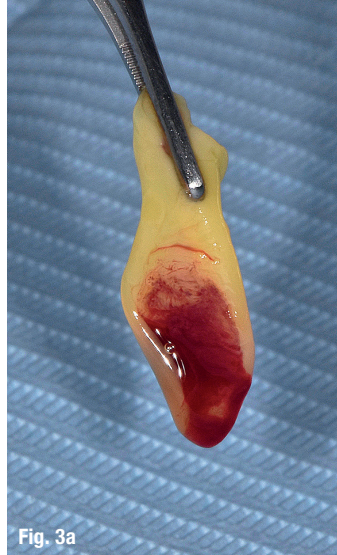


Fig. 3a

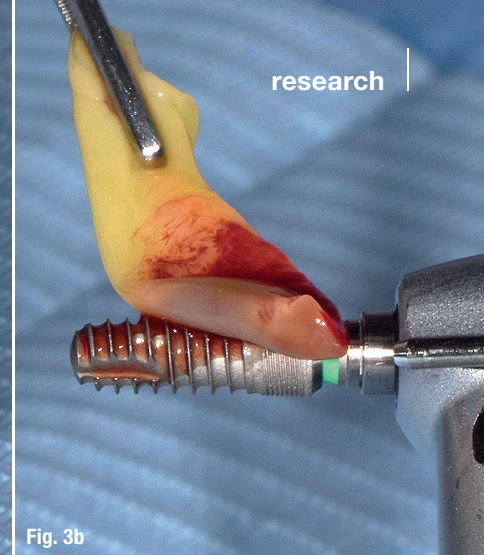


Fig. 3b




Fig. 3c

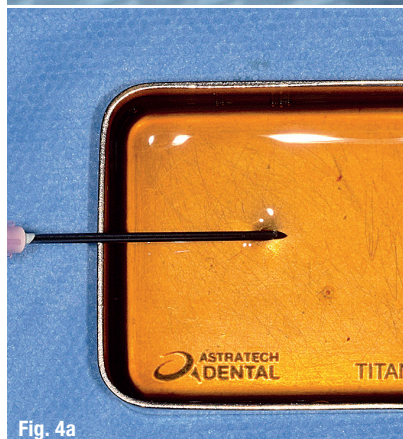

Fig. 4a

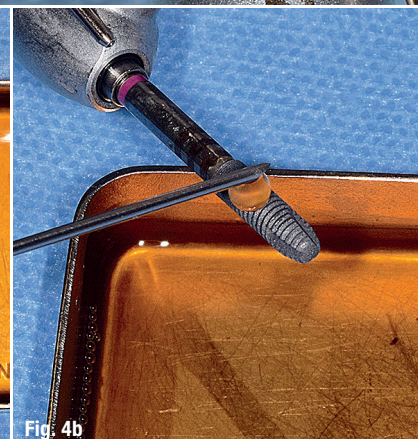
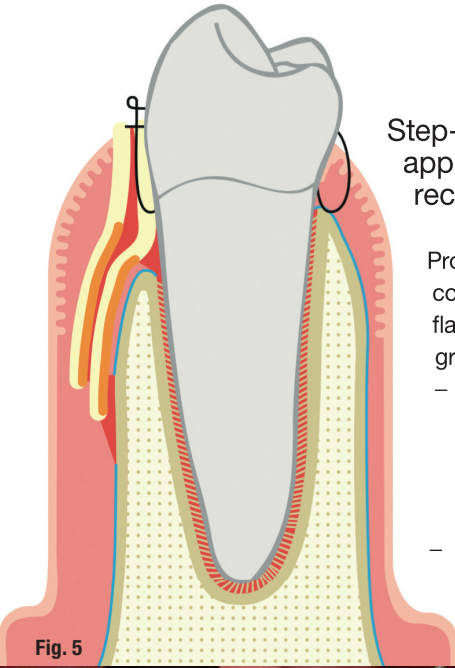


Fig. 4b



Fig. 4c

**Techniques for implant coating with L-PRF:** Fig. 3a: The L-PRF membrane needs to be placed in contact with the implant. Figs. 3b & c: Slow rotation of the implant in contact with the membrane. Fig. 4a: Collection of L-PRF exudate. Figs. 4b & c: The implant surface with the L-PRF exudate just before insertion.



### Step-by-step approach for gingival recession coverage

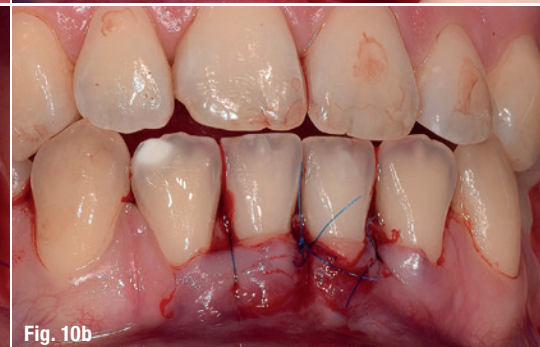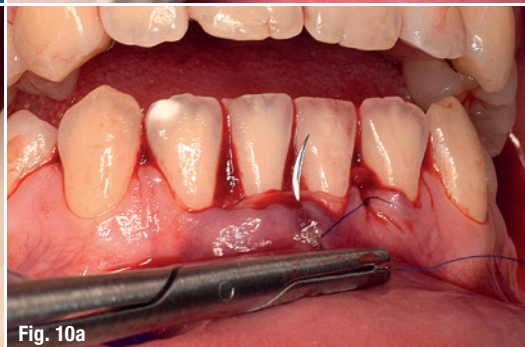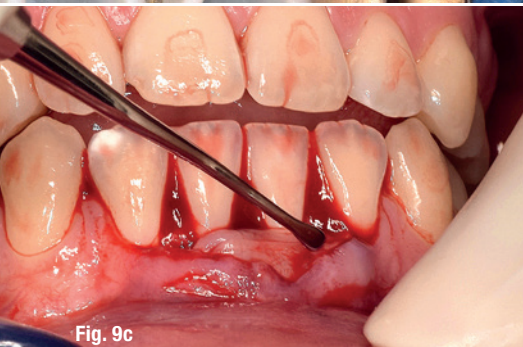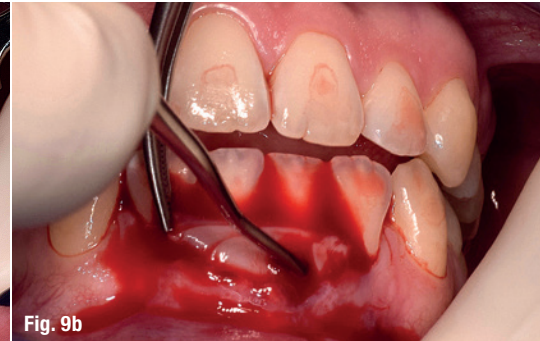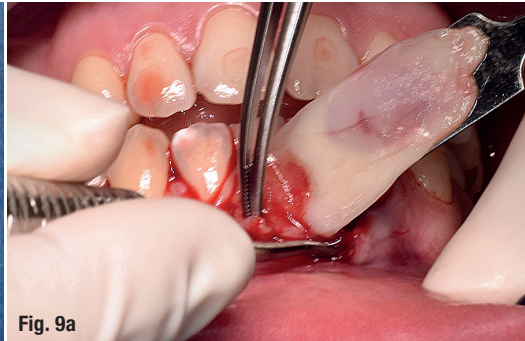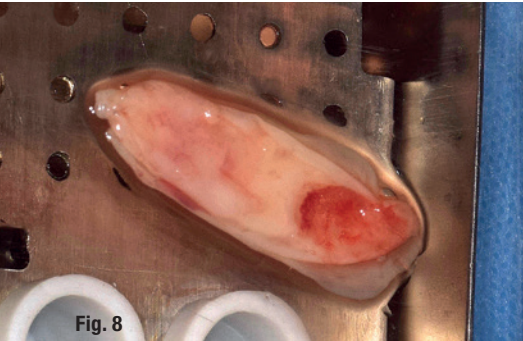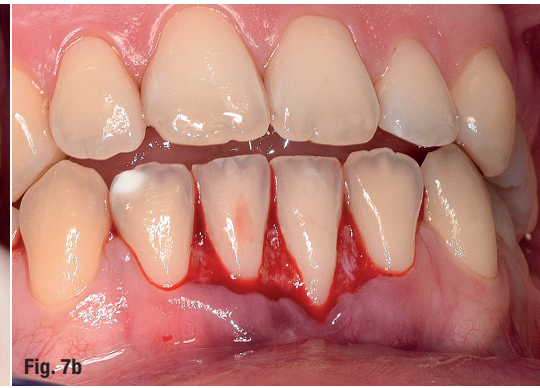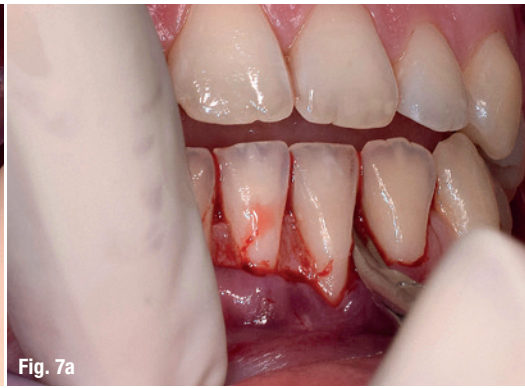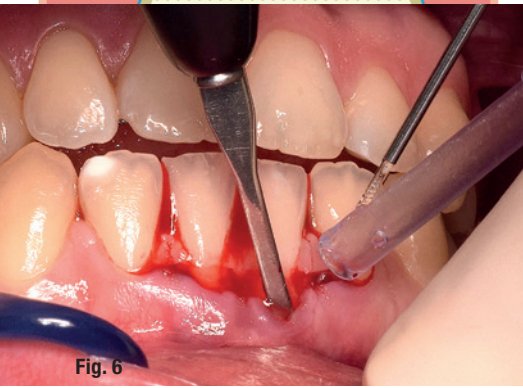
Protocol for gingival recession coverage with a coronal advanced flap procedure with L-PRF as grafting material (Fig. 5)

- Perform an incision following the coronal advanced flap protocol and full-split, full-thickness preparation of the receptor bed (Fig. 6).
- De-epithelialise the papillae (Figs. 7a & b).

- Suture a minimum of two or three L-PRF membranes (of the correct dimensions) together with resorbable 6/0 sutures (Fig. 8).
- Place the L-PRF graft on the exposed connective tissue (receptor bed) and over the recession and suture it to the periosteum (Figs. 9a-c).
- Suture with coronal advancement of the flap for coverage of the graft (Figs. 10a & b).

### Postoperative care

- No pressure or force must be exerted on the graft site for at least six months.
- Only soft food can be consumed and the patient must not bite or chew in the treated area. There must be no mechanical cleaning of the treated area. The patient



**Gingival recession coverage: Fig. 5:** Graphic representation of the final situation after gingival recession coverage with a coronal advanced flap and L-PRF membranes. Several L-PRF membranes (at least three) are placed on the receptor bed and over the recession. Suturing to coronally advance the flap over the recession is performed. (The periosteum, blue line, is cut in order to enable coronal advancement of the flap.) **Fig. 6:** Split-thickness preparation of the receptor site. **Figs. 7a & b:** De-epithelialisation of papillae. **Fig. 8:** Three L-PRF membranes (with the dimensions of the receptor bed) sutured together. **Figs. 9a-c:** Placement of L-PRF graft on exposed connective tissue (receptor bed) and over the recession. **Figs. 10a & b:** Suturing with coronal advancement of the flap for coverage of the graft.



should be careful to use his or her mouth only moderately. The patient must rinse with 0.12% chlorhexidine (from the third day post-operatively) three times per day for one minute for at least three weeks.

- Prescribe sufficient painkillers.

### Step-by-step approach for the preparation of a L-PRF Bone Block

Protocol for preparation of a L-PRF Bone Block using 0.5g of a biomaterial of your choice (allogeneic or xenogeneic or synthetic biomaterial; Fig. 11)

- Venepuncture: collect six tubes of blood in 9ml red-capped tubes following the L-PRF standard protocol and then two tubes in 9ml white-capped tubes (Fig. 12).

The blood for the latter is drawn last and the tubes placed last in the centrifuge (2,700rpm/408RCF).

- Interrupt centrifugation after three minutes to remove both white-capped tubes.
- Immediately restart the centrifuge with the red-capped tubes remaining for another nine minutes.
- Immediately aspirate the yellow fluid (liquid fibrinogen) in the white-capped tubes with a sterile syringe (Fig. 13). Get as close as possible

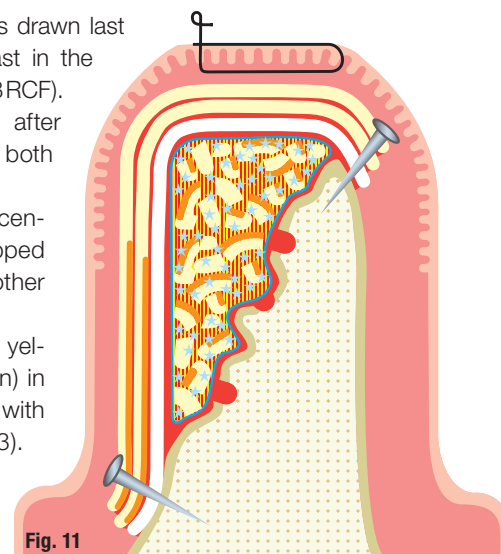


Fig. 11



Fig. 12

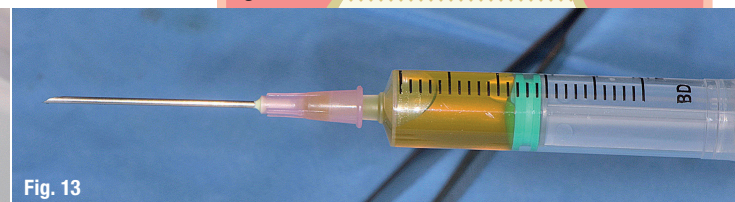

Fig. 13

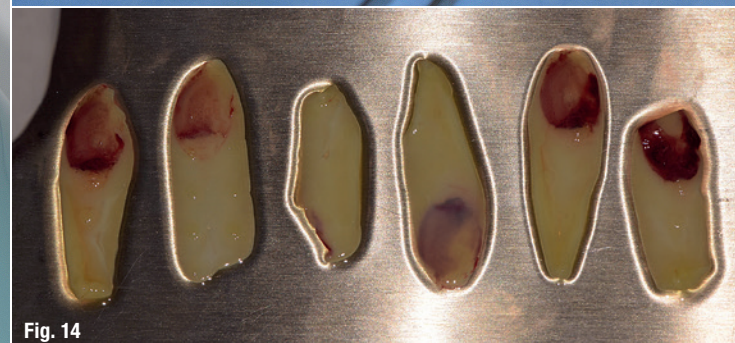

Fig. 14




Fig. 15a



Fig. 15b

**Clinical preparation of PRF-Block:** Fig. 11: Graphic representation of a L-PRF Bone Block for horizontal bone augmentation. The small holes in the cortical bone guarantee an optimal blood supply. The L-PRF Bone Block is quite well adapted to the bony defect, and the liquid fibrinogen is slowly transformed into fibrin. At least two membranes (face towards bony defect) are used to cover the block; they are fixed via membrane tacks. Primary closure by suturing is preferred. Fig. 12: Collection of six tubes (red cap, glass coating) of blood following the standard protocol and two tubes (white cap, plastic coating) collected last for liquid fibrinogen. Fig. 13: Collected liquid fibrinogen in a sterile syringe. Fig. 14: Clots gently compressed into membranes in the Xpression Box. Figs. 15a & b: a) Chopped membranes and bone substitute in a titanium dish; b) mixed.