

# CAD/CAM



international magazine of digital dentistry

## case report

Incorporating CAD/CAM solutions for full-mouth dental implant reconstructions

## industry report

Mill, polish, seat! Indirect procedures in the dental workflow

## cone beam supplement

Implant dentistry for complete maxillary rehabilitation

# Time spent milling could be time spent smiling.



The n!ce™ range will give you something to smile about. Building on our experience, we have developed an innovative glass-ceramic material that combines biocompatibility with esthetics. Our n!ce™ Fully Crystallized blocks deliver ease-of-use, quality and a natural finish for your CAD/CAM restorations.

- Simply mill, polish and seat, no crystallization process required
- Esthetic and natural restoration results

## It's n!ce™ to mill smiles.



[www.straumann.com](http://www.straumann.com)

**Dr Scott D. Ganz**

Editor-in-Chief



## Why the rush?

It's difficult to watch certain television commercials, read a newspaper, see an online advertisement, a webinar, social media content or a recorded video without hearing about "teeth in an hour", "teeth in a day", "teeth tomorrow", "immediate loading", "immediate restoration", or some variant. Patients are continually being told that they may be candidates for an "immediate" solution to their lifelong problems by having all of their "bad" teeth removed and replaced with an implant-supported restoration in one day, two days or a week. So, what is the rush? Are these concepts driven by science or strategic marketing by dental implant manufacturers, large group dental practices or individual practitioners, or due to patient demand?

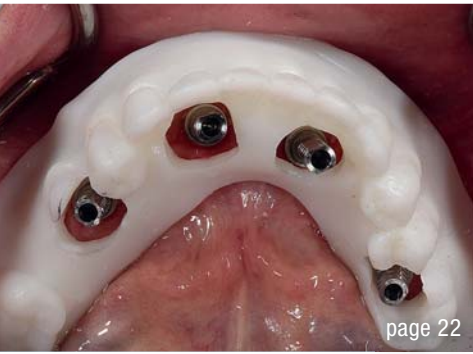Patients who have failing dentition generally have been in this condition for a long time. Certainly, there are individual tooth failures that occur owing to various circumstances, but when it involves a complete maxillary or mandibular arch, or both, the process of bone loss, tooth mobility, abscess formation or soft-tissue inflammation must have been chronic. Are we clinicians to expect that we can solve all of these problems with advanced technologies that will deliver the magic wand of instant rehabilitation?

For the past several decades, the scientific literature has supported immediate treatment protocols that can deliver single-tooth to full-arch reconstructions with ac-

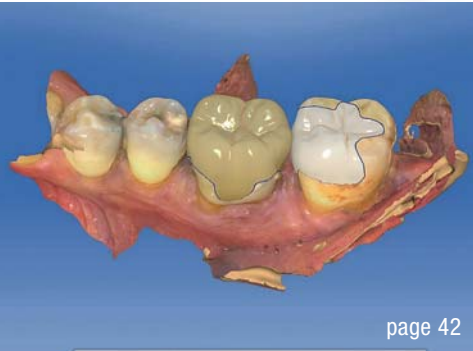curacy, consistency and predictability. Therefore, clinicians may want to deliver high-quality care to patients and significantly shorten the treatment time involved in dental implant procedures, but should these immediate implant-supported procedures be considered for every patient without consideration of conventional dental solutions such as root canal therapy, apicectomy, crown lengthening, or crown and bridge alternatives? Does the new digital workflow provide clinicians and dental laboratory technicians with improved tools to facilitate these accelerated treatment modalities? Is the rush justified?

Of course, these questions may relate mostly to an individual clinician's training and education in diagnosis, treatment planning, and surgical and restorative skill set. Perhaps education is the key, and today there are many opportunities to gain the skills necessary to make decisions for each patient, to determine whether immediate or delayed implant protocols are warranted. The goal of Dental Tribune International and this publication is to provide the readership with concepts, philosophies, clinical illustrations and treatment modalities currently available so that clinicians can make educated decisions. Don't rush! Take time to enjoy this latest issue and expand your universe.

Dr Scott D. Ganz  
Editor-in-Chief



page 22




page 42



page 50

Cover image courtesy of DenDor/Shutterstock.com



**editorial**

**Why the rush?**

Dr Scott D. Ganz

03

**cone beam supplement**

**Implant dentistry** for complete maxillary rehabilitation:  
**Two innovative protocols**

Drs Gilbert Tremblay & Scott D. Ganz

06

**case report**

Implant **retreatment**

Dr Philippe Leclercq, Jean-François Martinez & Michael Brüh

16

**Mandibular** dental reconstruction

Dr Lyndon Cooper, Dr Ghadeer Thalji, Dr Carly Park & Lee Culp

22

Incorporating **CAD/CAM solutions** for full-mouth dental  
**implant reconstructions**

Dr Ara Nazarian

26

**industry report**

**Digital workflow** and application of PRF and ozone therapy  
**in oral rehabilitation**

Drs Miguel Stanley, Ana Paz, Catarina Rodrigues & Diogo Mendes

32

Fast, functional **aesthetic solution** for anterior tooth trauma

Dr Martin Weber

38

**Mill, polish, seat!** Indirect procedures in the **dental workflow**

Dr Johannes Beiter

42

**news**

manufacturer news

46

**meetings**

Best of **EuroPerio9**

50

**“Knowledge changes everything”** Nobel Biocare invites dentists  
to 2019 Global Symposium in Las Vegas

52

**Upcoming IDS** puts emphasis on **technology and teamwork**

54

International events

56

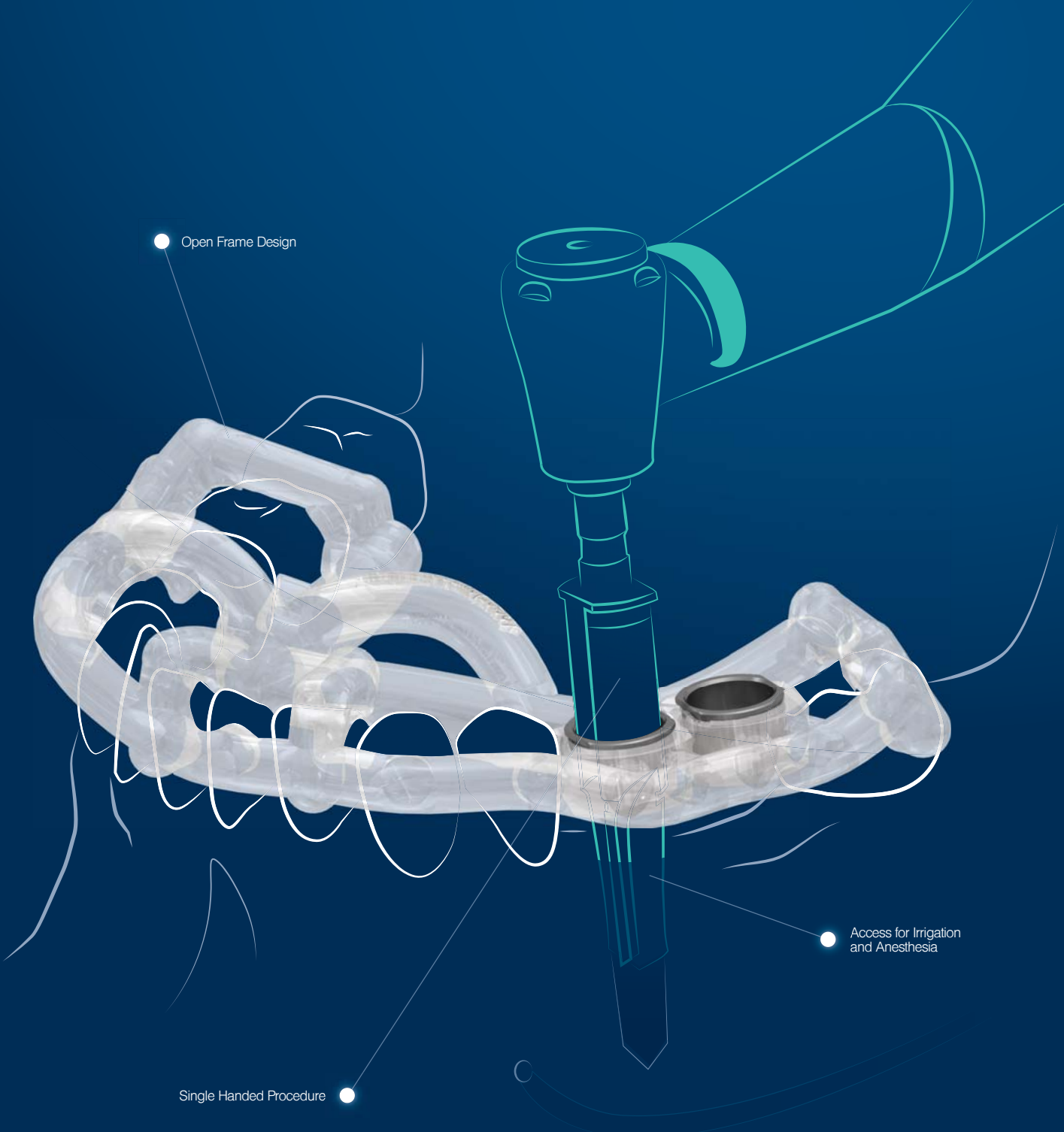
**about the publisher**

submission guidelines

57

international imprint

58



● Open Frame Design

● Access for Irrigation and Anesthesia

● Single Handed Procedure



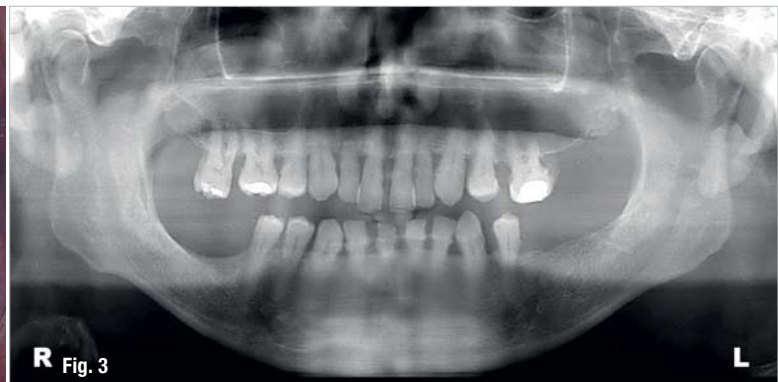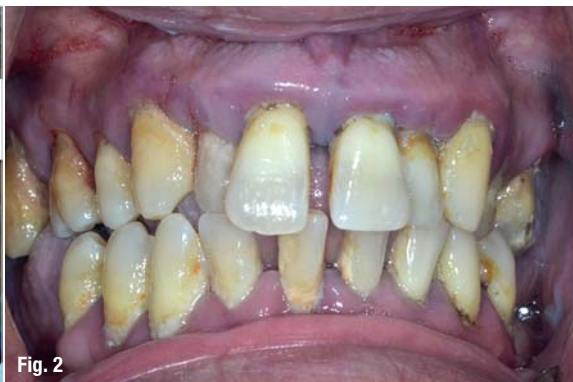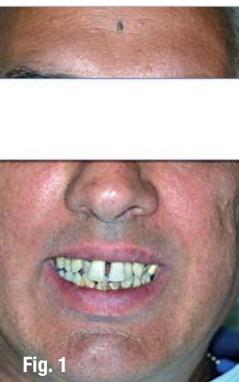## MAKE IT SIMPLE. WE KNOW HOW!

The innovative design of the MIS MGUIDE and its surgical kits simplifies digital dentistry. The use of CAD/CAM, allows for a prosthetically driven, safe and accurate procedure. To learn more about the MIS MGUIDE, go to [www.mis-implants.com](http://www.mis-implants.com)

**MIS** | **MGUIDE**  
PART OF THE M CENTER GROUP

# Implant dentistry for complete maxillary rehabilitation: Two innovative protocols

Drs Gilbert Tremblay, Canada & Scott D. Ganz, USA

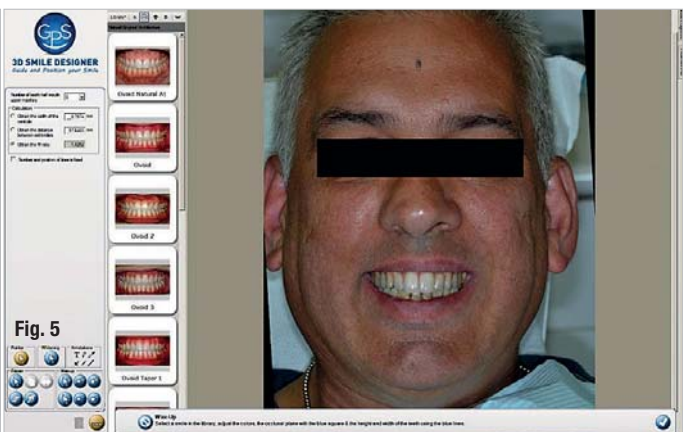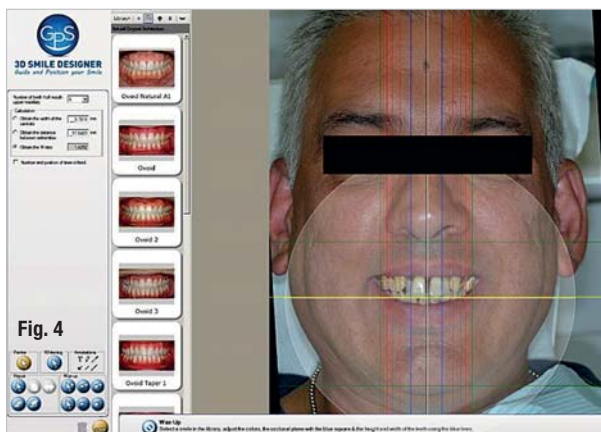


**Fig. 1:** Pre-op patient presentation. **Fig. 2:** Pre-op intraoral photograph, malocclusion, diastemas, cross-bite and acute periodontitis. **Fig. 3:** Pre-op panoramic X-ray. Generalised bone loss at the maxilla, overeruption of the molars and bilateral sinus pneumatization.

**Patients who present** with a terminal natural dentition in the maxillary arch offer both surgical and restorative challenges for the clinician. A formal diagnostic protocol is essential to determine viable treatment options and to facilitate the desired aesthetic and functional outcome. This can include impressions for study casts, two-dimensional periapical radiographs or panoramic radiography, medical history and current list of medications, and diagnostic wax-ups.

Traditional concepts have advocated first extracting the remaining teeth in a phased approach with socket

bone grafting to allow the ridge proper time to heal prior to placement of implants in strategic positions months later. During the interim, the patient would receive an immediate complete maxillary denture. It had been postulated that by allowing the ridge to heal after tooth extraction a certain percentage of bone resorption will occur, especially under the forces of mastication transmitted from the immediate denture. Ideally, the vertical dimension of occlusion will be maintained, as well as an acceptable aesthetic appearance based on sound prosthodontic conventions. The healing phase usually requires three to six months to allow the underlying bone to mature. If either a fixed



**Fig. 4:** Calibration of the 2-D photograph with the GPS software. **Fig. 5:** Virtual modelling of the patient's maxilla.

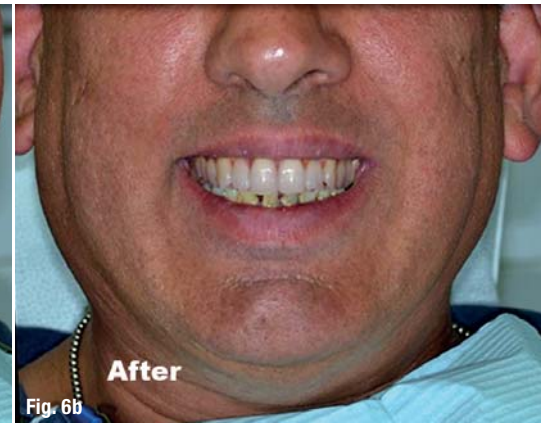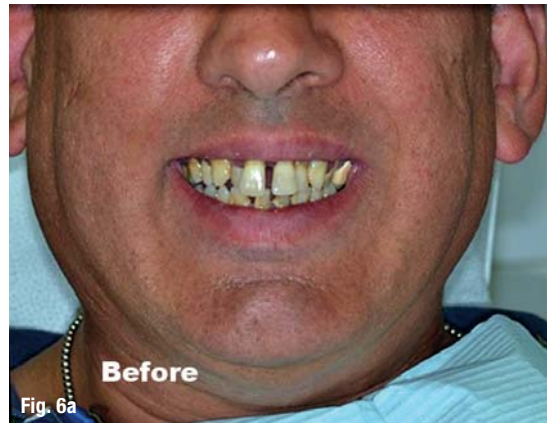or removable implant-supported restoration is desired, a CBCT scan will help determine ideal receptor sites based upon the volume and quality of the maxillary alveolar bone. Once the implants are placed a subsequent three- to four-month healing phase has been required to allow for osseointegration prior to loading and fabrication of a provisional and then final prosthesis.

Technology has evolved for both clinicians and dental laboratory technicians. The adoption of CBCT and interactive treatment planning software have empowered the implant team with state-of-the-art diagnostic tools and new digital workflows allowing for enhanced treatment alternatives and reduced treatment times for patients presenting with a terminal dentition in the maxillary arch.<sup>1</sup> While there may be teeth presenting with a hopeless prognosis, the use of three-dimensional imaging modalities may reveal enough bone volume and bone quality for implant placement after tooth extraction. If an appropriate number of implants can be placed in strategic positions and found to be stable enough at the time of insertion, the restorative plan can be accelerated. However, rehabilitating the maxilla directly with immediate extractions and an immediately loaded implant reconstruction takes careful collaboration with the dental laboratory and may lead to unpredictable aesthetic outcomes. The goal of this case presentation is to demonstrate that digital dentistry can help in predicting the aesthetic outcome before any surgical procedure is engaged.

## Case Presentation

### Clinical Assessment

A 46-year-old Caucasian male presented as a referral with a pre-existing failing condition of the maxillary dentition (Fig. 1). The patient complained of dental pain, bleeding gums and loose, mobile teeth. Clinically an oral examination revealed tooth mobility, generalised bone loss in both the maxilla and the mandible, generalised bleeding upon probing, multiple subgingival deposits and a malodor (Fig. 2). There was a diastema between the right and left central incisors and other spaces were evident upon inspection. Medically, he had an ASA 2 with Type 2 diabetes that was controlled with medication.

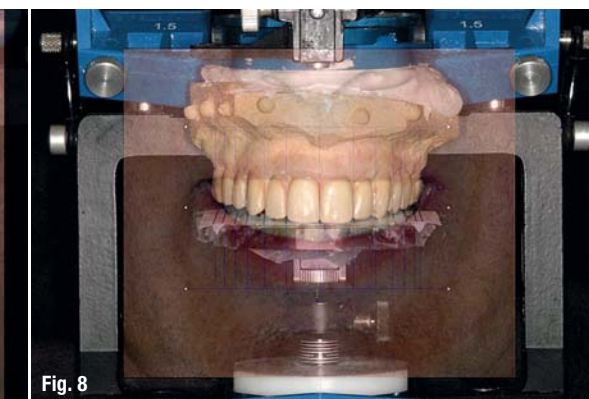
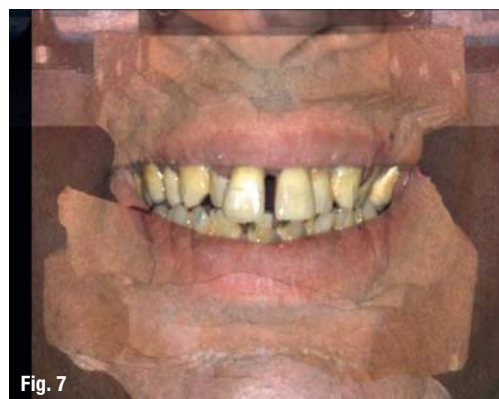

**Figs. 6a & b:** Presentation of the virtual design to the patient for discussion and acceptance.

The patient was evaluated for a surgical and restorative implant-supported solution for the hopeless prognosis of the maxillary arch. To accurately assess the patient's clinical reality a CBCT scan was obtained. The CBCT analysis revealed multiple alveolar bone deficiencies such as: dehiscence, fenestration, vertical and horizontal bone loss and periapical lesions (Fig. 3).

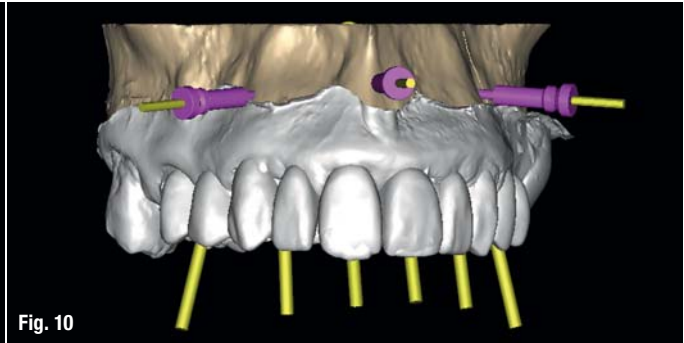
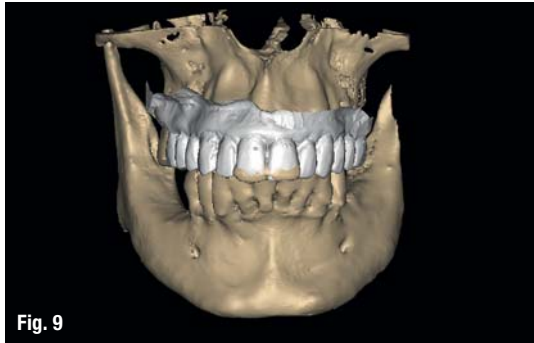
### Final diagnosis

Generalised acute periodontitis in both the maxilla and the mandible. The prognosis for the existing dentition was poor and further planning was necessary to determine the most acceptable course of treatment for either delayed or immediate implant placement and immediate restoration as per the patient's desires. The referring dentist had also disclosed that the patient had been inconsistent with his dental follow-ups. Therefore, before proceeding with any advanced treatment scenario, the patient's motivation needed to be assessed since complex treatments necessitate cooperation, time commitment, and compliance from the patient. After reviewing the requirements with the patient, consent was granted and the patient elected to start treatment for his maxillary arch and engaged maintenance treatment for his mandibular arch.

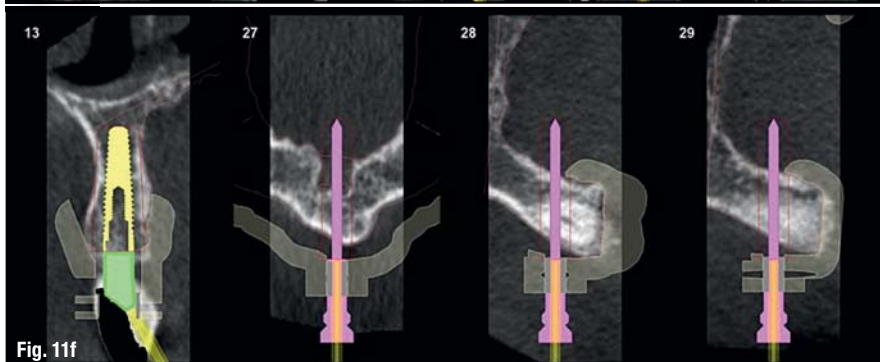
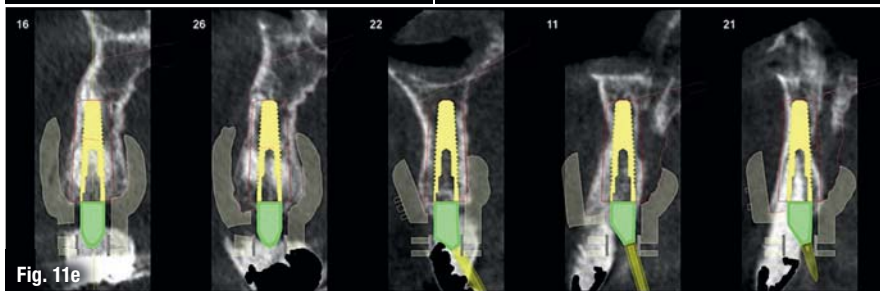
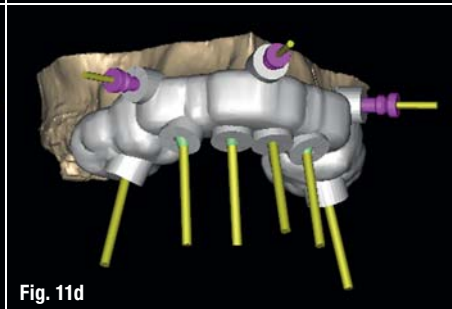
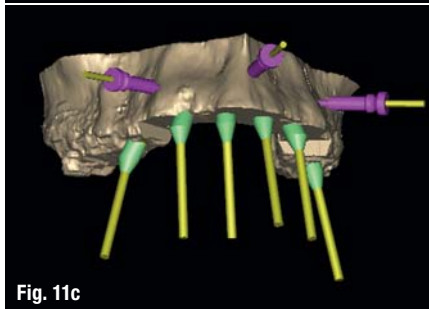
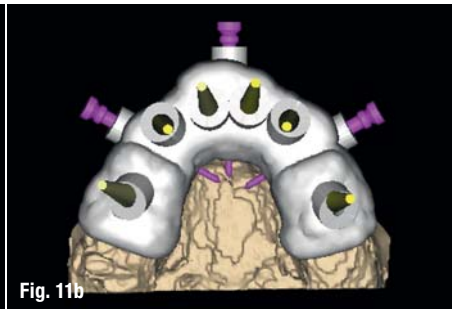
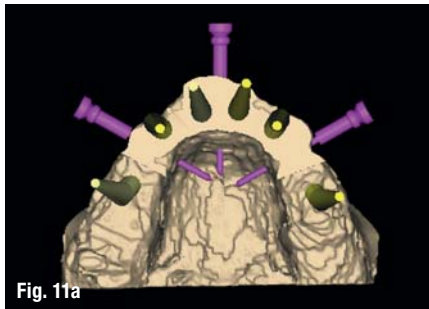


**Fig. 7:** GPS digital face bow transposition on the articulator. Calibration of the 2-D photograph by triangulation.

**Fig. 8:** Conversion of the GPS accepted proposition by the patient into a wax-up on the original study cast.



**Fig. 9:** 3-D superposition of CBCT and the GPS wax-up digital impression. **Fig. 10:** Computerised implant treatment planning. Anchor pins located in the pre-molars and mid maxilla.



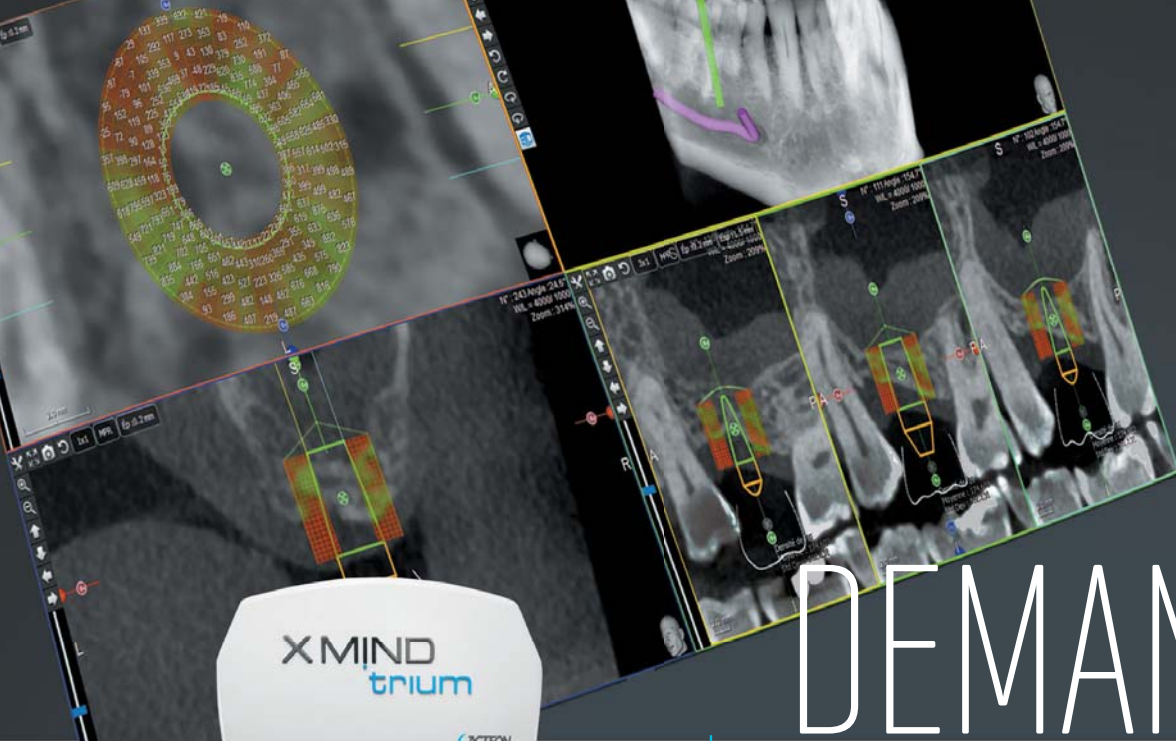
**Figs. 11a & b:** Computerised virtual bone reduction and implant positioning. **Figs. 11c & d:** Computerised virtual surgical implant guide design. **Figs. 11e & f:** Implants individual position into the available bone volume and retaining anchor pins.

Data collection included 2-D photographs, alginate impressions, a large field of view (FOV) CBCT scan (Carestream select 9600, Kodak) and a maximum intensity projection (MIP) bite registration. A smile analysis revealed that in maximal lip retraction position only a portion of his teeth were exposed, and no gingival tissue was present within the smile zone. Hence, it was determined that the transition line of the definitive patient's prosthesis transition would be under the upper lip. It is therefore critical to understand the existing and desired aesthetic condition to facilitate the diagnostic and treatment planning phase as a predictor of the eventual functional and aesthetic outcome.<sup>2</sup>

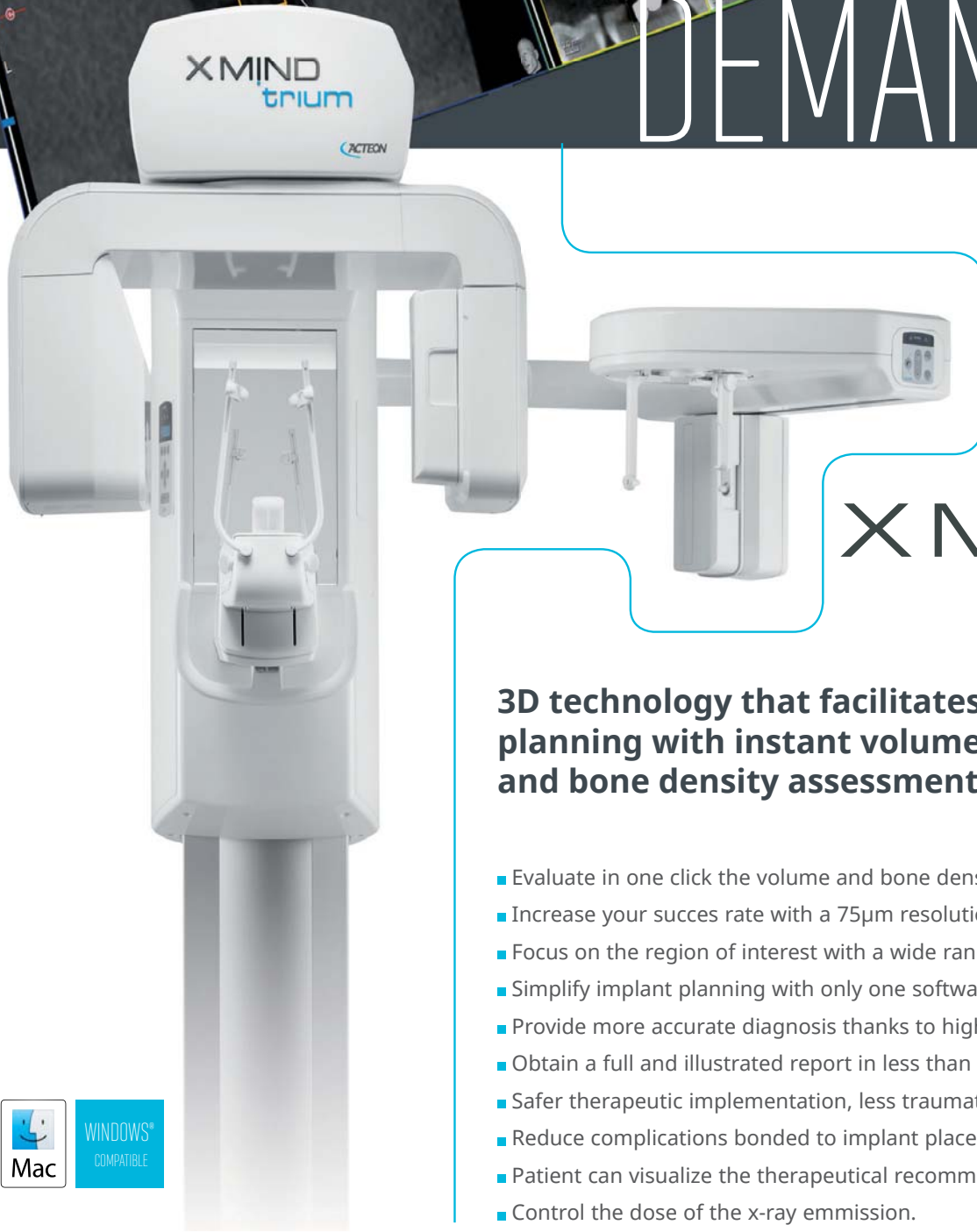When presented with hopeless teeth in the maxilla with the desire for an implant supported restorative solution, the treatment protocol often dictates a complete extraction scenario followed by the placement of an adequate number of root form implants needed to support an immediate provisional bridge.<sup>3-5</sup> However, the aesthetic outcome of this procedure can be unpredictable due to a lack of appreciation of the soft tissue and the uncertainty of the vertical and anterior-posterior position of the final fixed prosthesis.

Previously it was proposed that a "patient acceptance prosthesis" be used to simulate the desired restorative outcome<sup>6</sup> which has been followed with recent advances in computer simulation, intraoral scanners, and the merging of different datasets.<sup>7</sup> The purpose of this paper is to review two innovative protocols that address the accuracy and predictability of full arch extraction and immediate implant placement for fixed implant-supported restorations.





# I AM DEMANDING



## X MIND trium

### 3D technology that facilitates implant planning with instant volume measurement and bone density assessment

- Evaluate in one click the volume and bone density.
- Increase your succes rate with a 75µm resolution.
- Focus on the region of interest with a wide range of fields of view.
- Simplify implant planning with only one software.
- Provide more accurate diagnosis thanks to high-detail imaging.
- Obtain a full and illustrated report in less than one minute.
- Safer therapeutic implementation, less traumatic and stressful.
- Reduce complications bonded to implant placement .
- Patient can visualize the therapeutical recommandation.
- Control the dose of the x-ray emission.



X-MIND trium is a class 3R laser product per IEC 60825-1:2007. Avoid direct eye exposure to laser radiation. Viewing the laser output with magnifying optical instruments (for example, surgical microscope and binocular glasses) may pose an eye hazard and thus the user should not direct the beam into an area where such instruments are likely to be used.

SOPRO | a company of ACTEON Group  
ZAC Athélia IV | Av. des Génévriers | 13705 LA CIOTAT Cedex | FRANCE  
Tel. +33 (0) 442 980 101 | Fax. +33 (0) 442 717 690  
E-mail: info@sopro.acteongroup.com | www.acteongroup.com

