

implants

international magazine of oral implantology

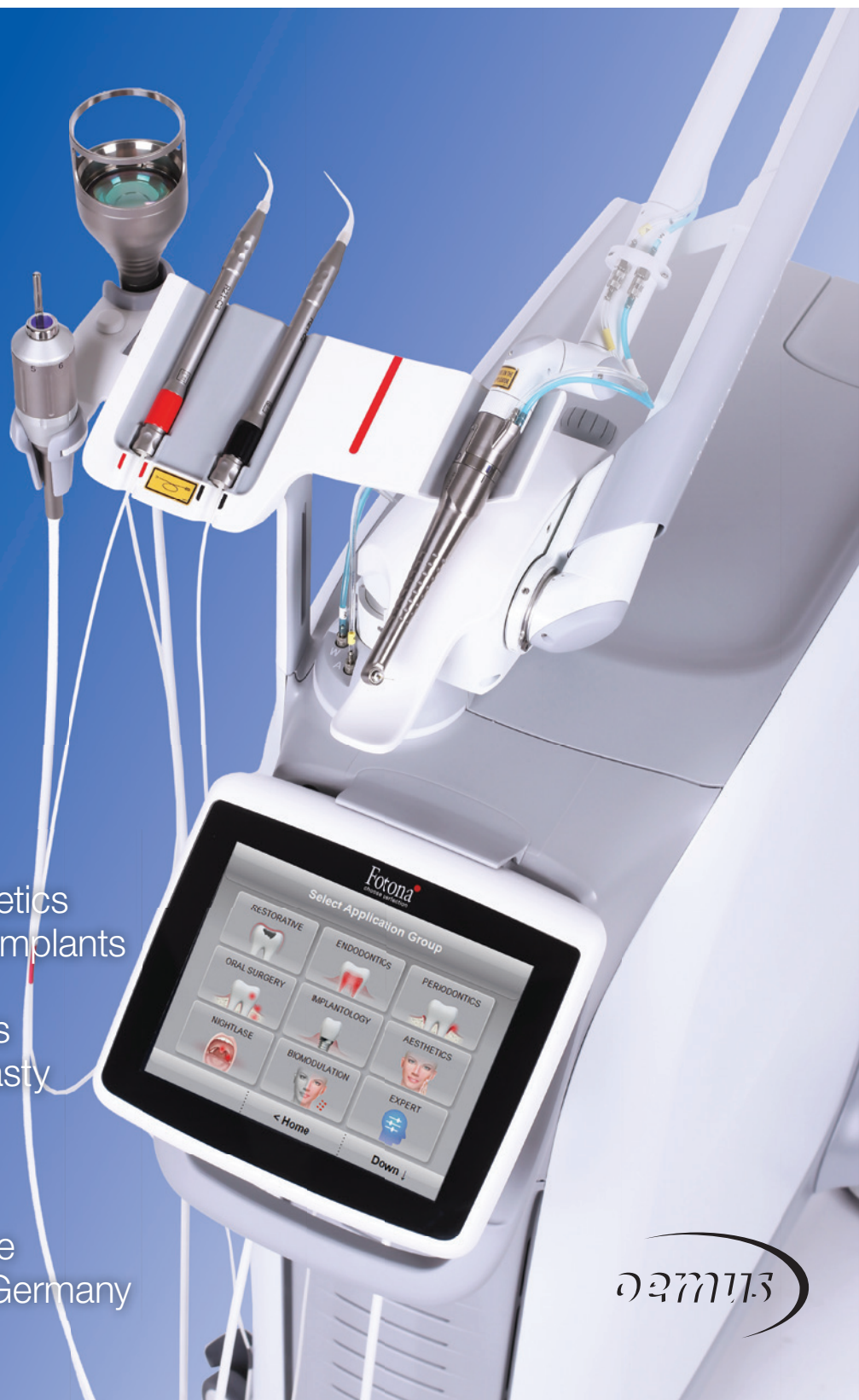case report

Restoring anterior aesthetics with two-piece zirconia implants

Resective peri-implantitis therapy with implantoplasty in Crohn's disease

industry

Economic success in the implantology market in Germany





REVOLUTION
IN A BOX!

mis[®]|c1 XD[™]

FULL PROCEDURE IN EVERY IMPLANT PACKAGE. **MAKE IT SIMPLE**

Every MIS C1 implant is now supplied with XD Single-Use drills. These single-use drills are designed for optimal implant-drill compatibility and high initial stability, while ensuring safe and simplified procedures. Learn more about MIS at: www.mis-implants.com

Dr Rolf Vollmer
First Vice President
and Treasurer of DGZI



Implantology in the team

Dear colleagues and friends,

At the very beginning of oral implantology at the end of the sixties and beginning of the seventies of the past century, it was already clear that implantology is a team effort, and this is just as relevant today.

The challenges of the early days are certainly very different from those of the present time, and the associated tasks for the team are just as varied. Whereas in the past the focus was on insecurities regarding a successful implantation, today completely different requirements such as technical conditions, patient expectations or the digital workflow are coming to the fore.

Therefore, I am pleased to invite the international implantological community on behalf of the DGZI to this year's 52nd Annual Congress in Hamburg on 6 and 7 October.

The event will take place this time under the motto "Implantology in the team", the focus will be on the dentist, his practice team, and the dental technician. The congress offers a unique international platform for the exchange of expertise, experience, and best practices. Traditionally, at the beginning of the congress we will look into the future and offer our young DGZI friends a podium. Regarding the scientific programme, we have also succeeded not only in attracting renowned speakers, but also in setting up a programme that covers the entire range of facets of dental implantology. Naturally, the popular "Table Clinics"

will not be missing either, a format with a unique possibility of directly imparting expert information in small groups and direct implementation of what has been learnt.

Especially in recent years, the annual congress of the DGZI has been established as an important, international scientific and practice-relevant event.

In addition to the scientific programme, the host city of Hamburg offers a rich culture, a picturesque landscape and excellent gastronomy. Take the opportunity to network and explore this impressive city!

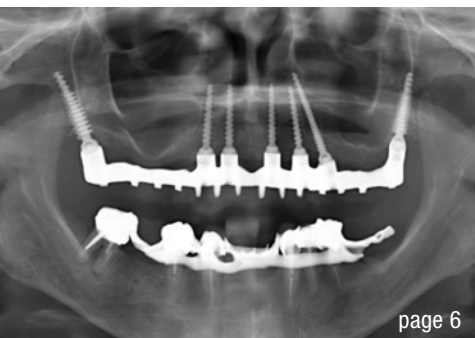
We are looking forward to meeting you again and to a vivid collegial interchange.

Yours,

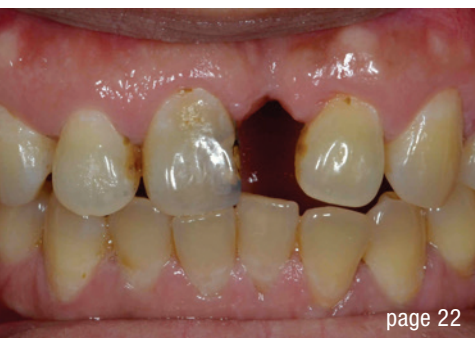A handwritten signature in black ink, appearing to read "Dr Rolf Vollmer".

Dr Rolf Vollmer

First Vice President and Treasurer of DGZI



page 6



page 22



page 38

editorial

Implantology in the team 03
Dr Rolf Vollmer

case report

The added value of the **pterygoid implant** in the management of edentulous patients 06

Dr Henri Diederich

Restoring **anterior aesthetics** with two-piece zirconia implants 12

Dr Saurabh Gupta

Resective peri-implantitis therapy with **implantoplasty** in **Crohn's disease** 16

Lucas A. Greilich, Dr Mischa Krebs, PD Dr Maximilian Moergel

Interdisciplinary approach for a **missing maxillary incisor** 22

Dr Tran Hung Lam

research

Immediate or delayed loading in the fully edentulous maxilla 28

Drs Yassine Harichane, Rami Chiri & Benjamin Droz Bartholet

industry

Economic success in the **implantology market** in Germany 32

Andreas Halamoda

"Clean" medical products 35

news

manufacturer news 36

events

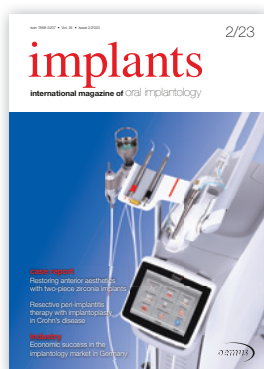Cheers to new beginnings: celebrating **oral tissue regeneration** 38

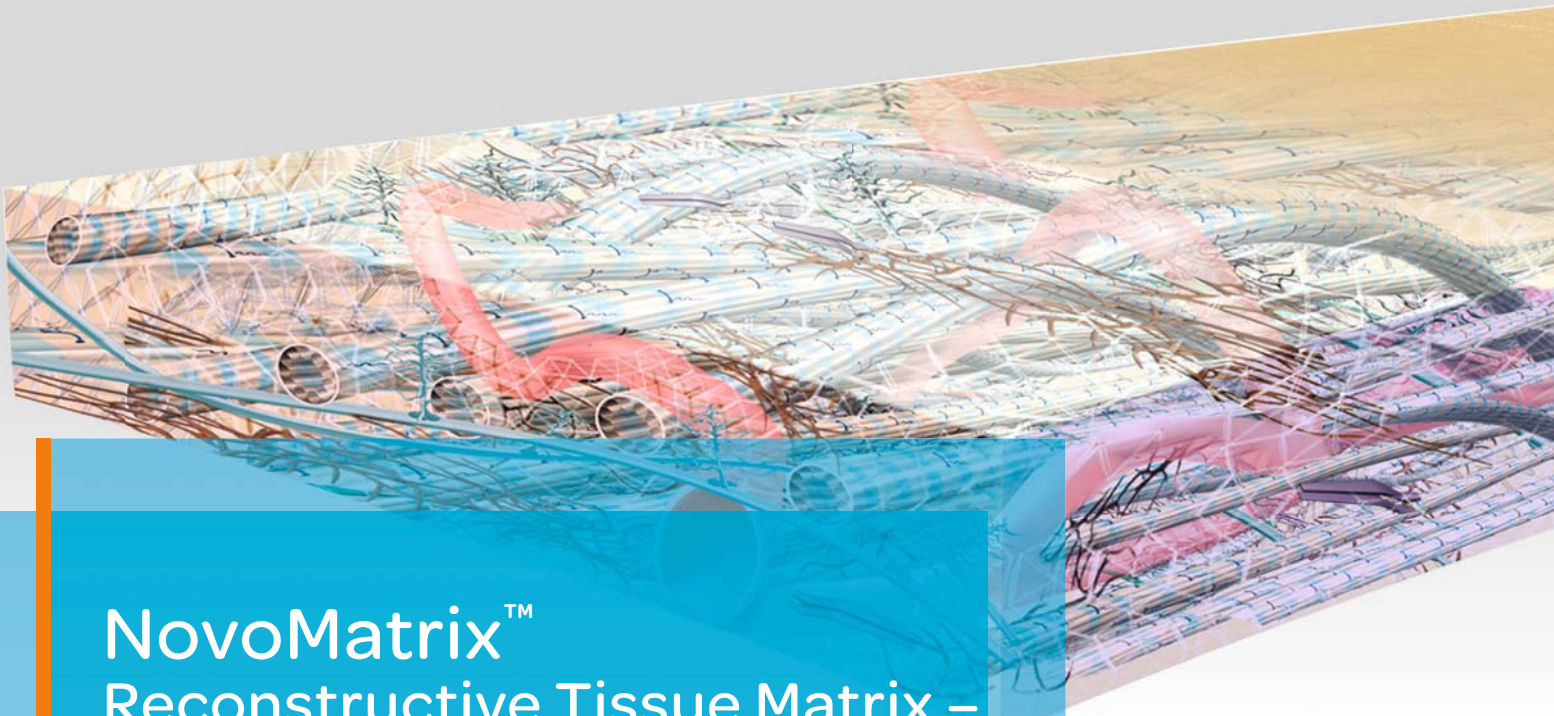
Cutting edge **science and innovation** 40

about the publisher

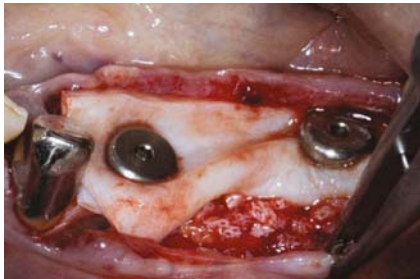
imprint 42

Cover image courtesy of Fotona d.o.o.
www.fotona.com

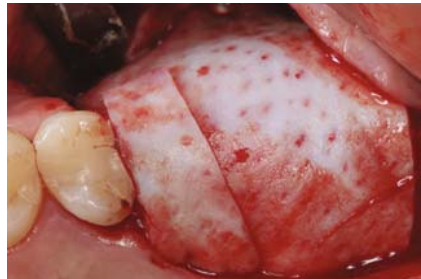



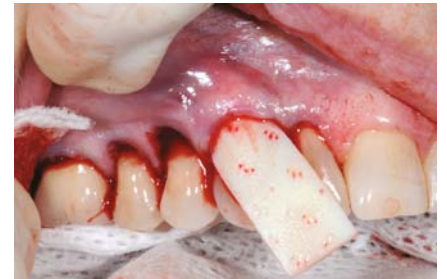NovoMatrix[™] Reconstructive Tissue Matrix – the next generation material



Ridge reconstruction



Gingival augmentation



Root coverage

NovoMatrix[™] Reconstructive Tissue Matrix is an acellular dermal matrix derived from porcine tissue intended for soft tissue applications. The proprietary LifeCell[™] tissue processing is designed to maintain the biomechanical integrity of the tissue, which is critical to support tissue regeneration.

Benefits of NovoMatrix[™]

- shorter surgery time¹
- lower patient morbidity^{1, 2, 3}
- excellent tissue integration^{4, 5, 6, 7}
- natural tissue and color structure⁸
- rapid and complication-free healing of soft tissue^{4, 6, 7, 9}

www.biohorizonscamlog.com/novomatrix



References available at: www.biohorizonscamlog.com/references_novomatrix
Before use, physicians should review all risk information, which can be found in the Instructions for Use attached to the packaging of each NovoMatrix[™] Reconstructive Tissue Matrix graft. NovoMatrix[™] is a trademark of LifeCell[™] Corporation, an AbbVie.
©BioHorizons. All rights reserved. Not all products are available in all countries.

The added value of the pterygoid implant in the management of edentulous patients

Dr Henri Diederich, Luxembourg

Pterygoid implants were first proposed by Linkow in 1975, and the method was first described by French maxillofacial surgeon J.F. Tulasne in 1992.^{1,2} Tulasne and Tessier were the first to describe the technique for implant placement in the pterygoid plate. Pterygoid implants are relatively long and specifically manufactured with the characteristics of the pterygoid region in mind.³

The pterygoid implant enables rehabilitation in the posterior maxilla in cases of poor and limited bone quantity as well as the presence of the maxillary sinus when such cases cannot be treated with standard implants.⁴⁻⁶ Expertise and a thorough understanding of the anatomy of the posterior maxilla are crucial for successful placement of pterygoid implants. The pterygoid implant placement method has been previously documented in the literature.⁷

The following case studies showcase the use of pterygoid implants to restore function in patients with edentulous jaws. The pterygoid implant employed in this case series is a new generation of pterygoid implant, designed by the author in collaboration with the Swiss company TRATE. It is a one-piece tissue-level conical implant with compressive threads and undergoes a surface treatment with hydroxyapatite and tricalcium phosphate. The implant neck has a wide thread profile, providing compression in areas of low bone density, such as the maxillary tuberosity. Its pointed, self-tapping apex ensures strong anchorage when inserted.^{3,8} The pterygoid implant ranges from 16 to 26 mm in length, ensuring that the implant apex engages the cortical bone of the medial wall of the pterygoid plate⁹ and is 3.5 or 4.5 mm in diameter.

Case presentations

Case 1

A 45-year-old female patient sought to have missing teeth on the right side of her upper jaw replaced (Fig. 1). Owing to the narrow width of the upper jaw ridge, conventional implant options were not feasible. The patient also had a history of chronic sinus infection and did not wish to undergo a sinus lift procedure. To rehabilitate her missing teeth, ROOTT C3516m, C3514m and C3520mp implants were placed in positions #18, 15 and 14. The procedure was performed under local anaesthesia after flap elevation, and a 2.5 mm pilot drill was used to prepare all three osteotomies. The implants were loaded after a three-month delay, and a screw-retained metal–ceramic bridge

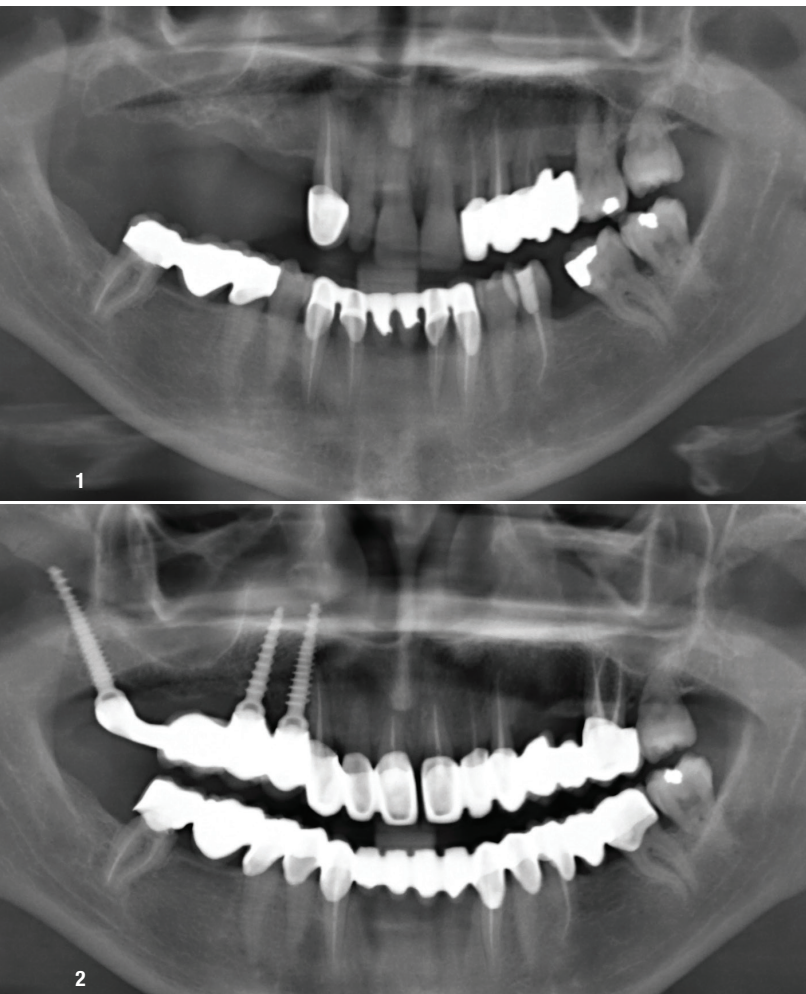


Fig. 1: Case 1—panoramic radiograph of the patient at presentation. **Fig. 2:** Radiograph of the patient after bridge delivery.


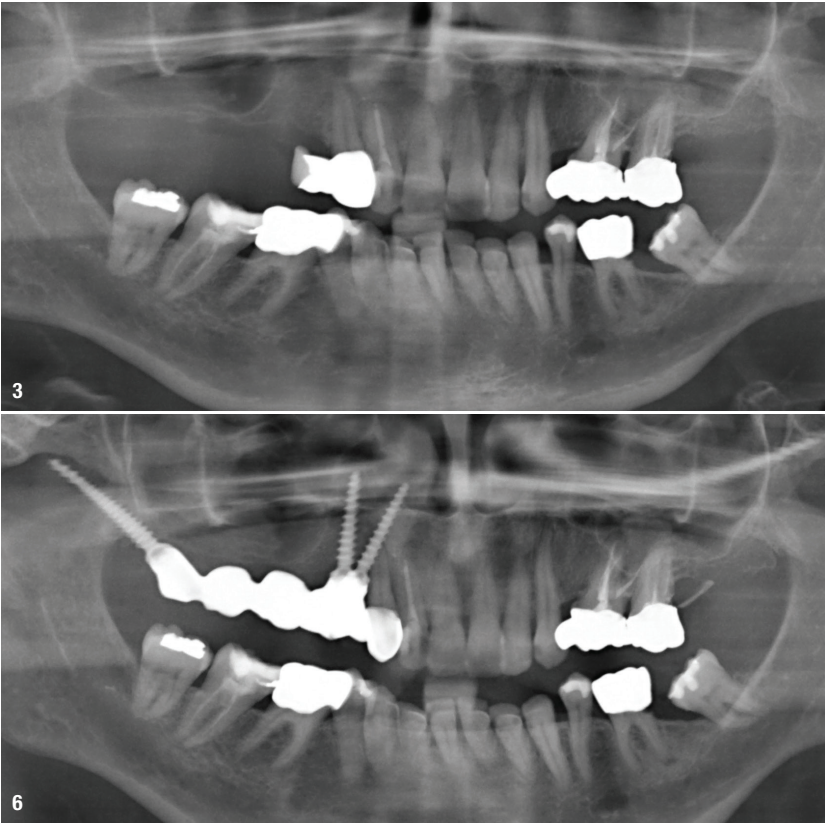


Fig. 3: Case 2—panoramic radiograph of the patient at presentation. **Figs. 4 & 5:** Traditional implant options were not feasible owing to the narrow ridge. ROOTT C3016ms implants were placed in positions. **Fig. 6:** Radiograph of the patient after bridge delivery.

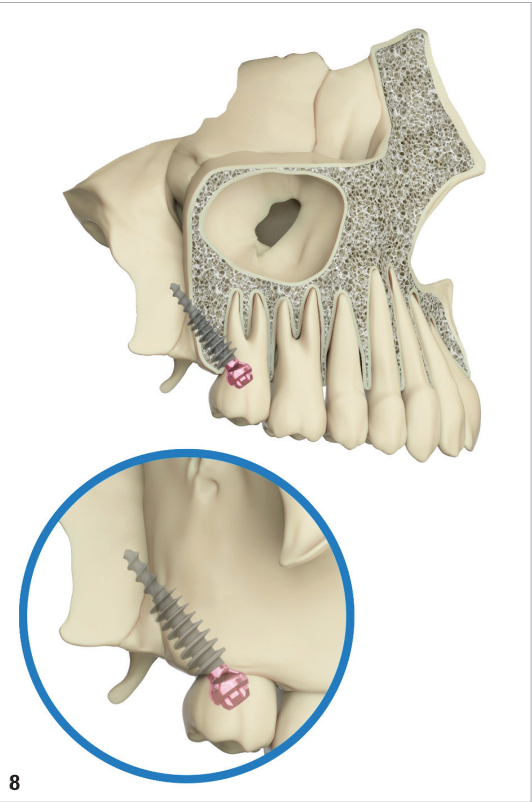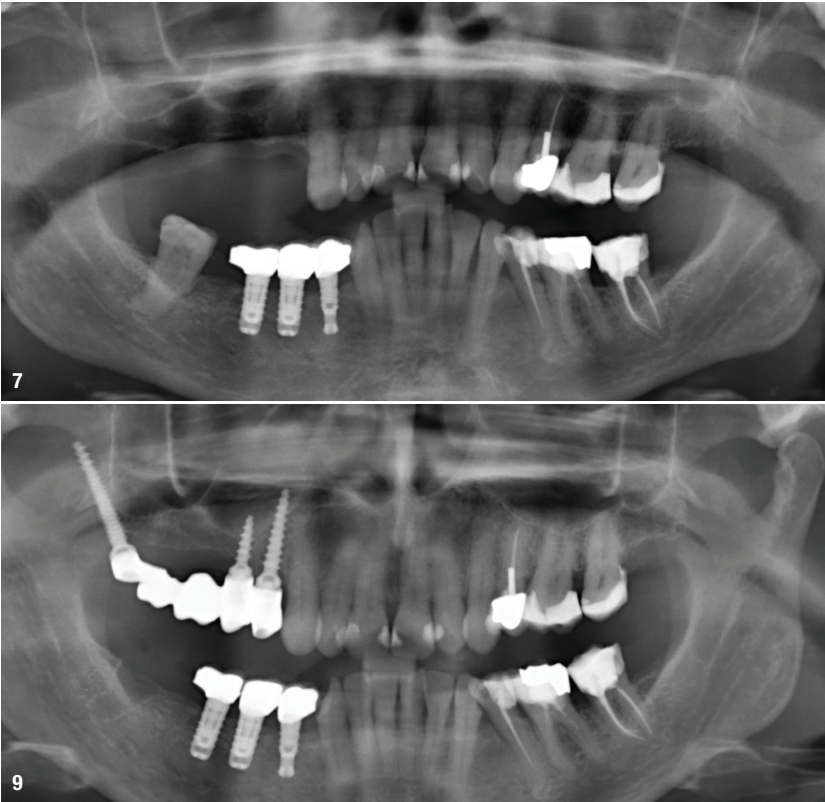


Fig. 7: Case 3—panoramic radiograph of the patient at presentation. **Fig. 8:** Placement of pterygoid implant into the maxilla. **Fig. 9:** Radiograph of the patient after bridge delivery.

was seated 14 days after impression taking with screwed impression copings (Fig. 2).

Case 2

The next case involved a 64-year-old female patient who sought to have missing teeth on the right side of her upper jaw replaced (Fig. 3). The patient had extensive maxillary sinus pneumatisation and a narrow alveolar ridge. Owing to her history of chronic sinus infection, a sinus lift procedure was not a desired option. Traditional implant options were not feasible owing to the narrow ridge. ROOTT C3016ms implants were placed in positions #15

and 14 (Figs. 4 & 5). The patient received an immediate temporary bridge constructed at the chairside after the surgery (Fig. 6). Three months after the surgery, impressions were taken with screwed impression copings, and a screw-retained metal bridge was seated three weeks later.

Case 3

In a similar case, a 54-year-old female patient sought a solution for missing teeth on the right side of her upper jaw (Fig. 7). ROOTT C3514m, C3008ms and C3520mp implants were placed in positions #18, 15 and 14 (Figs. 8 & 9).

Case 4

A 34-year-old female patient presented with missing teeth in her right upper jaw (Fig. 10). A similar treatment approach was taken to that used in the previous cases, involving the placement of ROOTT C3512m, C3508m and C3520mp implants in positions #18, 15 and 14 (Fig. 11).

Case 5

A 54-year-old female patient sought to have her complete denture replaced with a fixed solution, without undergoing extensive surgical procedures such as bone grafting or sinus lift (Fig. 12). Owing to her narrow alveolar ridge, it was decided to use standard one-piece tissue-level implants and pterygoid implants for rehabilitation of the upper jaw. The procedure was performed under local anaesthesia after flap elevation. A 2.5 mm pilot drill was used for preparation of all the osteotomies. ROOTT C4520mp implants were placed in positions #18 and 28, ROOTT C3016ms implants with short necks were placed in positions #13, 12, 22 and 23, and a ROOTT C3522mp implant was placed in position #24 (Fig. 13). Early loading was carried out with a temporary denture fabricated at the chairside (Fig. 14). After five days, the key was tried in. One week later, a trial of the metal frame was done, and a further week later, an aesthetic trial was conducted. At the fourth appointment, the metal–resin denture was screwed in (Fig. 15). The patient left the clinic with a fixed solution without having to undergo extensive surgical procedures.

Discussion

These case reports demonstrate the use of pterygoid implants for restoration of the maxilla in various cases. With this approach, atrophic jaws could be rehabilitated without the need for additional surgical procedures such as sinus lift and bone grafting.¹ The use of pterygoid implants allows for the resolution of many cases that cannot be managed with standard implants within a short period, effectively solving the patients' problem of edentulism.^{3,6,8,10–12} The high success rates of pterygoid implants in patients with minimal bone levels and minimal complications make them an attractive option for treating such patients.^{6,13,14}

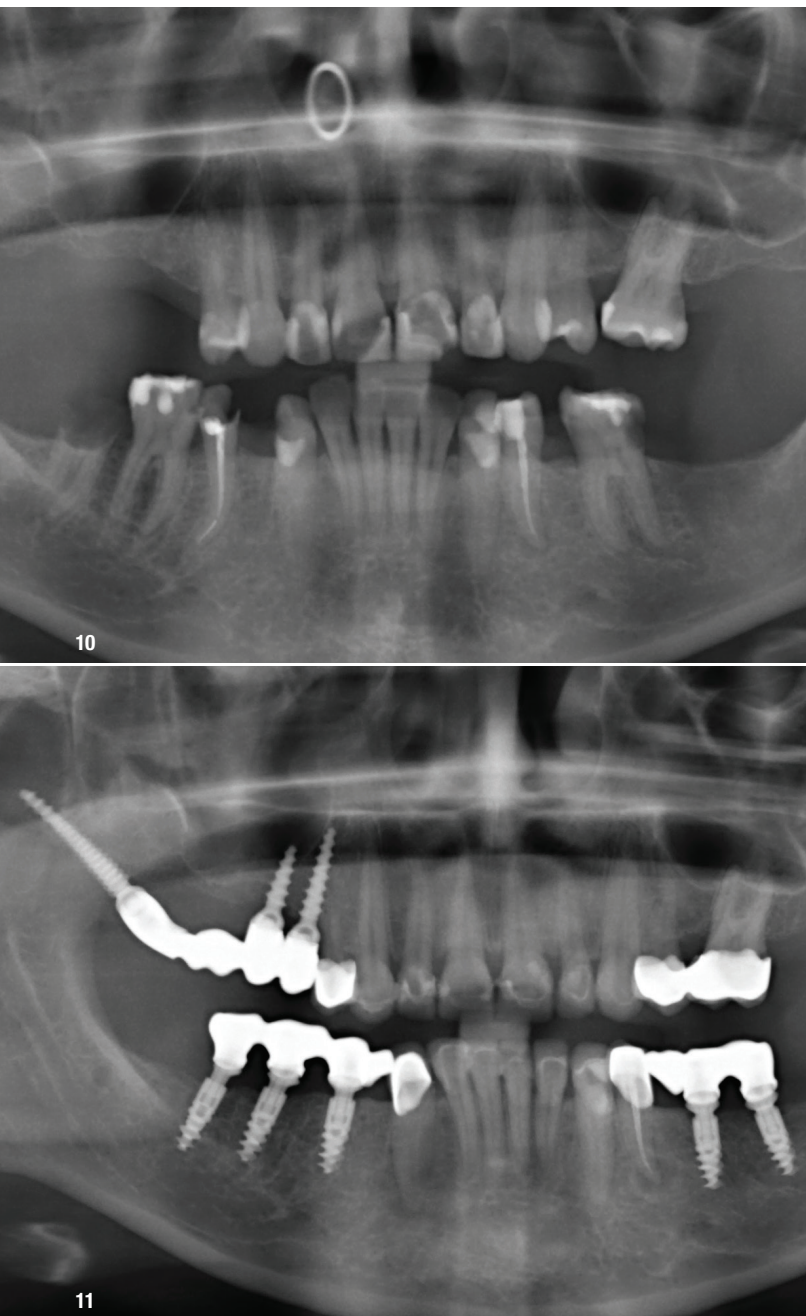


Fig. 10: Case 4—panoramic radiograph of the patient at presentation.
Fig. 11: Radiograph of the patient at the completion of treatment.

STRAUMANN® **BLX** IMPLANT SYSTEM

Confidence beyond Immediacy.



BLX unifies progressive functional design with our high-performance Roxolid® material and the clinically proven SLActive® surface, designed to provide you with confidence for all clinical situations. Innovations like the VeloDrill™ system, Straumann® Dynamic Bone Management and our Esthetic Ease Concept are aimed to significantly improve surgical and restorative workflows.

→ Contact your local Straumann representative or visit:
www.confidence-in-you.com



DYNAMIC BONE MANAGEMENT

Redistribution of native bone and control over insertion torque to achieve optimal primary stability.



ESTHETIC EASE CONCEPT

Simplified but versatile portfolio, featuring one connection and under-contoured prosthetics.



REAL CONFIDENCE

Swiss precision and quality with Roxolid® material and SLActive® surface.