

implants

international magazine of oral implantology

research

Development of a new guided sleeve made of zirconia dioxide

interview

The X factor in implant dentistry


events

New directions in oral implantology





PERFECT
MATCH



mis[®]

MIS CONICAL CONNECTION. MAKE IT SIMPLE

MIS conical connection feature a 12-degree friction fit which ensures a secure seal and minimal micro-movements. Visit MIS Blog to get tips from experienced, world-renowned implant specialists on optimizing working with conical connection implants and restorative components: www.mis-implants.com/blog

Dr Georg Bach

President of the DGZI



Minimally invasive implant therapy can be implemented in many ways

We can look back with gratitude and pride on the successful international annual congress of the German Association of Dental Implantology, which took place this year in Berlin in Germany. A common theme ran throughout many of the contributions to the scientific programme: the demand for a minimally invasive procedure that is as gentle on the tissue as possible.

The reality has already become apparent in the past few years: the digital workflow is increasingly being integrated into oral implantology. The digital impression—whether from an intra-oral scan or derived from the dental model—the individual CAD of the required prosthetic elements and their CAM, as well as the 3D diagnostics and planning of the surgical procedure, can all be seamlessly combined digitally. The possibilities offered by reliable planning, achieved through backward planning, and consistent teamwork between the surgeon, prosthodontist and dental technician enable aesthetic, functional and durable dental restorations.

From the patient's point of view, in addition to these possibilities, the invasiveness of the planned intervention plays a decisive role. For the practitioner, the aim is to treat the patient as painlessly and quickly as possible in order to minimise additional stress for the patient, and there are very different minimally invasive approaches to employ for the individual case. Besides the use of

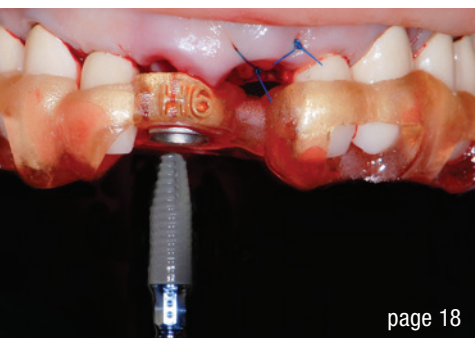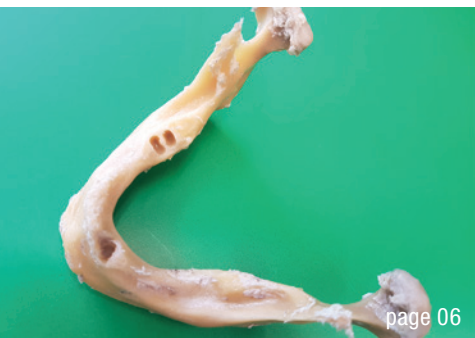reduced-diameter one-piece screw implants with self-tapping threads, there are very different minimally invasive approaches to employ for the individual case. Both the patient's state of health and the desired implant restoration are central starting points for a sound therapy. In the end, which path to take is the joint decision of the practitioner and patient.

I would like to wish you an engaging read of this year's last issue of **implants—international magazine of oral implantology**, as well as a time of introspection leading up to the festive season!

Warm and friendly greetings,

Dr Georg Bach

President of the German Association of Dental Implantology



Cover image courtesy of CleanImplant Foundation / www.cleanimplant.com



editorial

Minimally invasive implant therapy can be implemented in many ways 03
Dr Georg Bach

research

Development of a new **guided sleeve** made of **zirconia dioxide** 06
Leonard Vollmer, Dr Rainer Valentin, Dr Rolf Vollmer, Prof. Werner Götz

case report

Snake technique in the **treatment** of posterior **peri-implant** soft-tissue defects 12
Drs Cosmin Dima, Iulia Florea

Guided **one-stage** and **two-stage** implant placement in the anterior zone 18
Dr Paula Corvello

Peri-implant bone augmentation using the subperiosteal peri-implant augmented layer technique and bovine derived bone block 24
Prof. Leonardo Trombelli

Simultaneous implantation and augmentation of a **buccal bone defect** with biologised bone substitute material 28
Dr Haki Tekyatan

Screw-retained restoration of maxillary right first molar and second premolar 32
Dr Anthony Bendkowski

interview

The **X** factor in implant dentistry 34
An interview with Dr Dirk U. Duddeck and Dr Ken S. Serota

news

manufacturer news 36

news 48

events

2022 international annual congress of the DGZI 38
New directions in oral implantology: Where is the journey taking us?
Dr Georg Bach

Nations united by innovation 42
2022 EAO congress celebrates comeback in new hybrid format
Janine Conzato

about the publisher

imprint 50

TRULY CONICAL PRECISION

CONOLOG[®]
SYSTEM

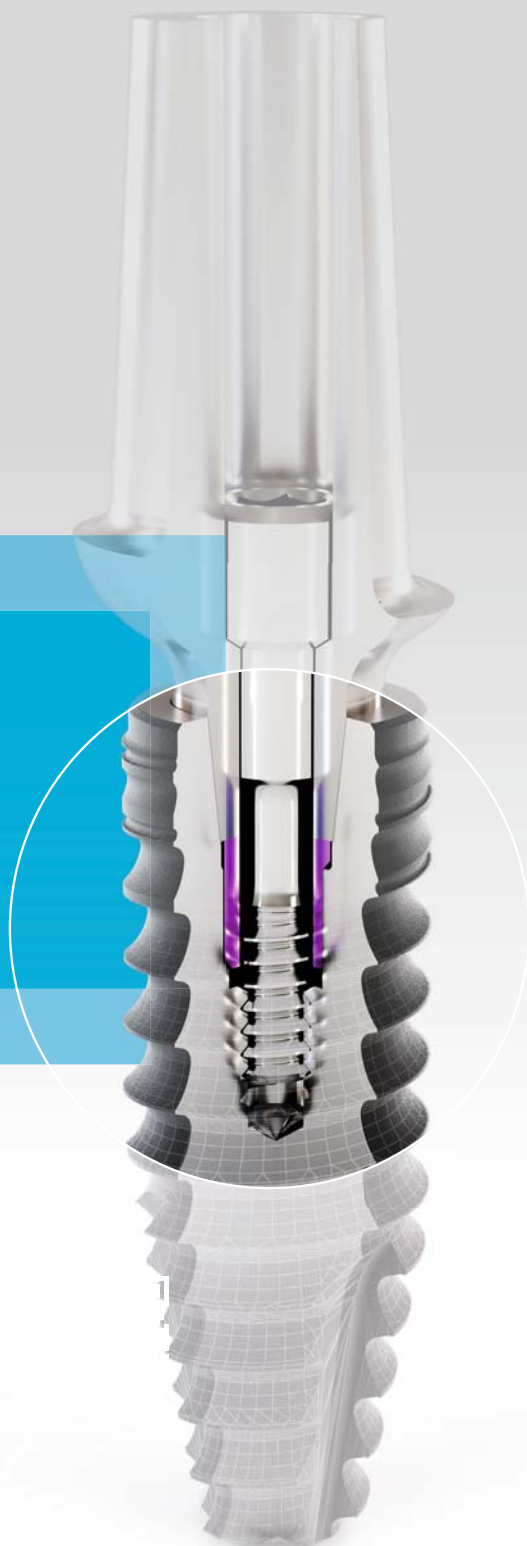

CONOLOG[®] PROGRESSIVE-LINE conical performance^{1,2} at bone level

Precise conical connection

- long conus for reduced micromovements
- superior positional stability in comparison to other conical systems^{1,2}
- easy positioning with excellent tactile feedback
- integrated platform switching supporting the preservation of crestal bone

[1] Semper-Hogg, W, Kraft, S, Stiller, S et al. Analytical and experimental position stability of the abutment in different dental implant systems with a conical implant-abutment connection Clin Oral Invest (2013) 17: 1017
[2] Semper Hogg W, Zulauf K, Mehrhof J, Nelson K. The influence of torque tightening on the position stability of the abutment in conical implant-abutment connections. Int J Prosthodont 2015;28:538-41



Development of a new **guided sleeve** made of **zirconia dioxide**

Application for surgical guides in dental implantology

Leonard Vollmer, Dr Rainer Valentin, Dr Rolf Vollmer, Prof. Werner Götz, Germany



The field of dental implantology has developed enormously over the last 50 years. Not only the actual dental implants but also the placement techniques and the possibilities of predictable planning have changed and improved greatly. In order to make implant placement in the jaw safer and as accurate as possible, methods have been developed to use 3D data obtained in advance. This technique became possible after the development of CT by Hounsfield in 1972 and the introduction of reduced-radiation CBCT.¹⁻³

With the help of the data obtained, surgical guides can be produced with appropriately incorporated guided sleeves. This enables the most precise implantation possible.⁵ In this regard, Schnutenhaus et al. found that implants placed with surgical guides were positioned more precisely than those placed freehand.⁶

Generally, metal drills paired with metal guided sleeves are used in dental implantology.⁷ However, this can cause abrasion during guided drilling and contamination of the

surgical site.⁸ Experience in hip arthroplasty shows that metal-metal pairings are unfavourable in their abrasion behaviour. The metal particles can cause inflammation of the surrounding tissue, abrasion disease or particle disease.⁹ In dentistry, the abrasion in the surgical area also poses risks in terms of wound healing and eventual peri-implantitis.^{10,11} Titanium ions from the titanium particles indirectly evoke an inflammatory reaction, and it is assumed that the osteoblasts are damaged.^{12,13} In orthopaedics, a ceramic-ceramic pairing offers an alternative with lower biological activity and a 27-fold reduction in abrasion. The following article presents the development of a new guided sleeve of zirconia for surgical guides for accurate drilling while avoiding chipping or particle abrasion that can cause peri-implantitis or particle disease.

Objective

The objective of the research was to test the chip abrasion of a combination of a zirconia sleeve with a zirconia drill and compare it with that of a titanium guided sleeve used in combination with a steel drill in order to prevent or minimise the risks associated with chip abrasion. For this purpose, test drillings were carried out on an anatomical specimen and subsequently compared histologically and by means of energy-dispersive X-ray spectroscopy (EDS).

Materials and methods

Ten drillings with the combination of a zirconia guided sleeve and zirconia drill and one drilling with a titanium guided sleeve and steel drill were carried out and subsequently examined (Table 1).

Bone material

An anatomical edentulous macerated mandibular specimen fixed in paraformaldehyde was used for the experiment (Fig. 1). This preparation was chosen to simulate an *in vivo* situation. The portions of the cortical bone were broad and the cancellous structures dense. The

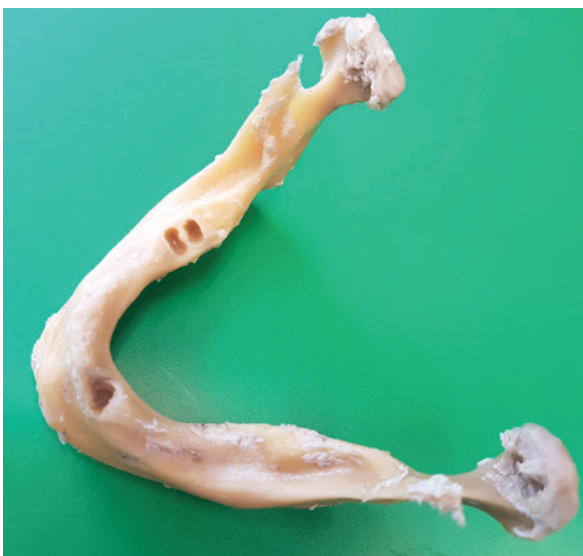

Fig. 1: Lower jaw preparation before drilling. (© Leonard Vollmer)

EXCELLENCE IN IMMEDIACY

Straumann® TLX Implant System Iconic Tissue Level meets Immediacy.



DESIGNED FOR IMMEDIATE PROTOCOLS

Fully tapered implant design for optimized primary stability.



PERI-IMPLANT HEALTH PRESERVATION

Reduced risk of nesting bacteria and optimized cleansability.



SIMPLICITY AND EFFICIENCY

One-stage process with restoration at soft-tissue level allows to use chair time more efficiently.

The design of the Straumann® TLX Implant takes into account key biological principles of hard and soft tissue healing. It is designed to significantly reduce the risk of inflammation and bone resorption as the implant-abutment interface is moved away from the bone. Contact your local Straumann representative now or visit www.straumann.com/tlx



References on www.straumann.com/tlx

A0025/en/A/01-IIM 08/22

bone quality corresponded to the D2 classification according to Lekholm and Zarb.¹⁴ The ramus of the mandible was separated from the body of the mandible to keep the drilling of the steel drill in conjunction with the titanium guided sleeve and the zirconia drills in conjunction with zirconia guided sleeves separate and to exclude contamination.

CBCT scanning of mandibular bone for planning and positioning of the drills

The fixed jaw sections were scanned in a CBCT unit (CS 9300, Carestream Dental; Fig. 2). This was followed by digital planning (CS 3D, Version 3.8.6, Carestream Dental). Eleven implants were planned and positioned in the bone, ten in the body of the mandible (Fig. 3) and one in the ramus. The data was then imported into the coDiagnostiX technical program (Dental Wings) to produce both the jaw model and the bone-supported surgical guides.

Fabrication of the jaw model and the guides

The model and guides were fabricated using the NextDent 5100 printer (3D Systems). NextDent Model 2.0 in grey was used for printing the jaws, and NextDent SG was used for the surgical guide. Since surgical guides are made of plastic and direct drilling through plastic leads to extremely strong abrasion of this by sharp implant drills, the guided sleeves must be made of a

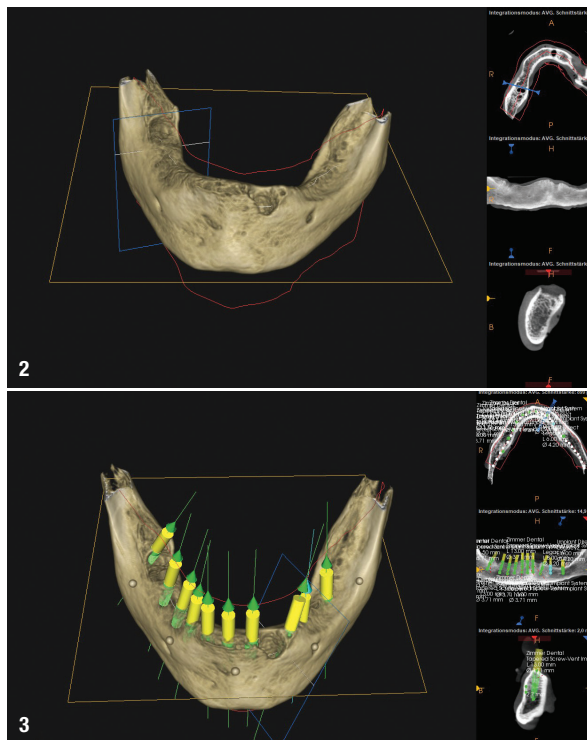


Fig. 2: CBCT scan of the body of the mandible in the planning program, showing broad portions of cortical bone and dense cancellous structures.

Fig. 3: CBCT scan of the body of the mandible in the planning program showing ten implants positioned. (© Leonard Vollmer)

Implant planning

CBCT device	CS 9300 (Carestream Dental)
Planning program	CS 3D, Version 3.8.6 (Carestream Dental)
Design program	coDiagnostiX (Dental Wings)

3D-printing

Printer	Nextdent 5100 (3D Systems)
Model material	Nextdent Model 2.0/grey (3D Systems)
Guide material	Nextdent SG (3D Systems)

Guided sleeves and drills

Titanium guided sleeve	M.27.31.D200L5 (Steco)
Zirconia guided sleeve	Utility model no. 202020103184.8
Adhesive for sleeves	BLUE FIX (FLUSSFISCH)
Steel pilot drill	210L16.204.020 (Komet Dental)
Zirconia pilot drill	K210L19.204.020 (Komet Dental)

Histological examination

Separation unit (large diamond disc)	333C450 (HORICO)
Plastic infiltrate	2-hydroxyethylmethacrylate
Plastic infiltrate	Technovit 7200 VLC (Kulzer)
Light polymerisation unit	EXAKT
3-component resin	Technovit 4000 (Kulzer)
Vacuum precision adhesive press	EXAKT
Grinding machine	EXAKT 400 CS
Diamond bandsaw	EXAKT 300 CP
Light microscope	ZEISS AxioScope 2
Video camera	ZEISS AxioCam MRC
Dye	Toluidine blue

Table 1: Overview of the materials used.


correspondingly harder material. The guide was therefore provided with titanium or zirconia guided sleeves.

Guided sleeves

A M.27.31.D200L5 titanium guided sleeve (Steco) with an inner diameter of 2 mm was glued (BLUE FIX, FLUSSFISCH) into the surgical guide for the ramus. No guided sleeve of zirconia is commercially available, so new guided sleeves were made from yttrium tetragonal zirconia polycrystals according to our specifications:

- collar according to our own design;
- inner diameter of 2 + 0.02 mm or + 0.04 mm;
- length of 8 mm;
- chamfer of 0.5 × 45° on the opposite side of the collar.

To ensure quality control, the outer dimensions of the sleeves were measured with a micrometre screw and the inner diameter was checked with test pins. A 2.02 mm diameter test pin, but not a 2.04 mm diameter test pin, had to be able to pass through the inner drill hole. Furthermore, the manufacturer declared that the



Figs. 4a & b: Histological preparation of the tissue of the drill hole made with the titanium sleeve and steel drill combination. The arrows indicate the metal particles. (© Werner Götz, University of Bonn)

sleeves were compliant with the requirements of Directive 2011/65/EU of the European Parliament and of the Council of 8 June 2011 on the restriction of the use of certain hazardous substances in electrical and electronic equipment. The zirconia guided sleeves were glued into the surgical guide.

Drilling

Eleven holes were drilled using the surgical guides. Drilling was carried out without cooling at a low speed of a maximum of 400 rpm. A steel pilot drill (210L16.204.020, Komet Dental) was used for drilling in the ramus of the mandible up to the stop, and a zirconia pilot drill (K210L20.204.020, Komet Dental) was used for drilling ten holes (drilling depth of 8–12 mm) in the body.

Histological preparation for the examination

For the histological examination, the fixated mandible was cut into narrow bone slices (approximately 5 mm thick) with a large diamond separating disc (333C450, HORICO), and numbered. These were further processed using a sawing-grinding technique. The sections were first dehydrated in an ascending alcohol series (70%, 90%, 96% and 100%), followed by infiltration in two steps.¹⁵ The specimens were infiltrated with a one-to-one mixture of 2-hydroxyethylmethacrylate and Technovit 7200 VLC (Kulzer) for seven days and then infiltrated with Technovit 7200 VLC for another seven days. Both steps were carried out under vacuum (500 kPa) and light exclusion. For polymerisation, the infiltrated preparations were left in a light polymerisation unit (EXAKT) under yellow light for 4 hours and under blue light for 4 hours.

Subsequently, the resulting discs were trimmed and attached to a plastic carrier with a three-component resin (Technovit 4000). Grinding using a micro-grinder (EXAKT 400 CS) was carried out until the holes were reached. Another plastic carrier was fixed to the ground surface, which was the surface to be examined. With a diamond bandsaw (EXAKT 300 CP), a 100–150 µm thick section of the block was removed and ground down to a thickness of 10–15 µm with the micro-grinder. In this way,

between one and three preparations could be obtained per bone block. A total of ten segments were prepared. The ground sections were then stained with toluidine blue.

Histological evaluation

The sections were examined under a light microscope (ZEISS AxioScope 2) at different objective magnification (50×, 100×, 200×, 400× and 500×). The images were digitised via a connected digital video camera (ZEISS AxioCam MRc). All histological preparations were examined for artifacts, possible heat damage and other foreign bodies (e.g. caused by abrasion).

Energy-dispersive X-ray spectroscopy

Owing to unclear structures in the histological preparations of Segment 3, they were additionally subjected to

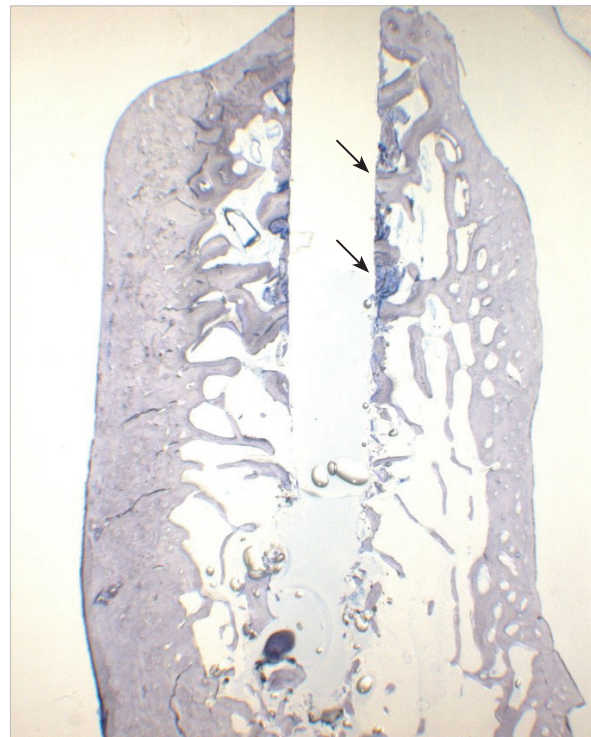


Fig. 5: Histological preparation of segment 3. Compacted debris (marked with arrows). Small granular fragments at the bottom; 500× magnification. (© Werner Götz, University of Bonn)