

ceramic implants

international magazine of ceramic implant technology

case report

Full-arch rehabilitation using ceramic implants in guided surgery protocol

interview

The long-term success rate of two-piece ceramic implants has been around 97%

overview

For the benefit of patients





Straumann® PURE Ceramic Implant System
Discover natural PURE white.
Love your smile.



**OUTSTANDING
ESTHETICS**

Favorable soft tissue attachment, high-end esthetic restorations



**PROVEN
QUALITY**

High performance zirconia ceramic, 100% proof tested



**EXCEPTIONAL
SURFACE**

ZLA® surface with revolutionary osseointegration features



METAL-FREE

A metal-free alternative to titanium implants



INNOVATIVE

A new system that helps you expand your patient pool



Contact your local Straumann representative now or visit www.straumann.com/pure.



A0005/en/B/01-CI 02/22

Dr Rodrigo Beltrão

Founding Member of ABICeram, Brazil

Dr Enrique Reinprecht

President SADIC, Argentina



The future has arrived, and we are art and part of it

Oral implantology, whether metallic or ceramic, has undoubtedly had a global impact on the profession and on the daily lives of our patients. In the early days, implants were only placed by a few dentists, trained in specific centres, and for a few patients, who had the means to access the treatment. In recent decades, most educational institutions specialised in oral health offer training, and this is increasing not only the number of dental professionals who are considering oral implantology as a specialisation but also the number of patients, who have more access than ever to information regarding dental implants and are therefore increasingly requesting metal-free solutions for their long-term well-being.

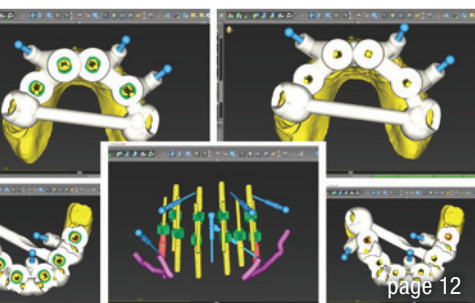
According to major opinion leaders and media surveys, in years to come, there will be a significant conversion to ceramic implantology in dentistry. In our opinion, the training of dentists is extremely important in order to be prepared for this new era. In the South American region, the latest trends from Europe and the US are always closely watched, and today it has been almost a decade since we have introduced metal-free implantology to our daily practice. It has been a difficult road for us, because until several years ago, we did not have the necessary supplies or the training in South America. Thanks to access to international websites with medical science papers and publications such as *ceramic implants—international magazine of ceramic implant technology*, promoted worldwide, it has become a little bit easier, considering the outstanding information being made very accessible for every dentist wishing to enter the field of ceramic implantology.

Those difficulties forced us to find a plausible solution. With a group of colleagues with experience in metal-free

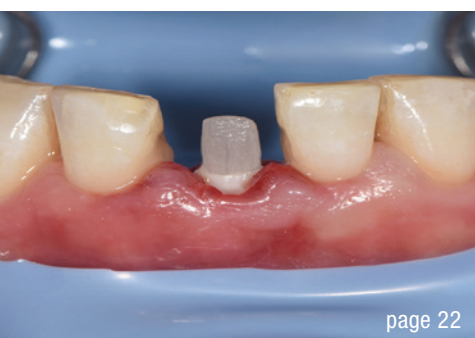implantology, the Sociedad Argentina de Implantología Cerámica (Argentine society of ceramic implantology; SADIC) and Academia Brasileira de Implantologia Cerâmica (Brazilian academy of ceramic implantology; ABICeram) were created with the objectives of the promotion of ceramic implantology in our region and the transmission of knowledge to other dentists. In addition, it has been of great importance for our organisations to have received intense support from the only company in South America with proprietary technology and knowledge in the development and production of ceramic implants using the ultimate technology of ceramic injection moulding that allows production of 3D native impurity-free implantable surfaces with nano-, micro- and macro-roughness.

The company donates its products to our non-profit organisations for medical and scientific purposes and, through this corporate philosophy, also helps to improve our economy, having positive social and environmental results. Without this support, it would have been impossible to develop and accelerate our missions and actions. The experience we have gained in collaboration with SADIC and ABICeram dentists has allowed us to make recommendations on one-piece and, currently, two-piece ceramic implant systems that are quickly being incorporated into the growing community of dental professionals and university curricula in our region.

There is still a long way to go, but the good thing is that we know where we want to go. We are convinced that we are on the right track, especially when we see the joy of patients who have searched for metal-free dental implant solutions and see their final result. Finally, the future has arrived, and we are proud to say that we are art and part of it.



page 12



page 22



page 32

Cover image courtesy of Straumann
www.straumann.com



editorial

The future has arrived, and we are art and part of it 03
Drs Rodrigo Beltrão and Enrique Reinprecht

case report

Two-piece zirconia implant for global metal-free restoration 06
Dr Riccardo Scaringi

Full-arch rehabilitation using ceramic implants in guided surgery protocol 12
Dr Alexandr Bortsov

Immediate implantation with platelet-rich fibrin and immediate loading 16
Prof. Belir Atalay & Dr Beril Atalay

Immediate implant placement and function in the aesthetic zone 22
Dr Roland Glauser

Tricortical stabilisation in severely atrophic buccal bone 26
Drs Leon Chen & Jennifer Cha

industry

Patients come to us because they know we focus heavily on their health and well-being 32
An interview with Dr Holger Scholz

interview

The long-term success rate of two-piece ceramic implants has been around 97% 34
An interview with Dr Elisabeth Jacobi-Gresser

overview

For the benefit of patients 38
Janine Conzato

events 44

news

manufacturer news 42

news 48

about the publisher

imprint 50

Zeramex XT

The two-piece screw-retained ceramic implant system

Experts
with **17 years**
experience in
ceramic
implants

Get to know the proven Zeramex XT ceramic implant system with the metal-free Vicarbo® screw that counteracts tensile and bending forces.

Convincing osseointegration, excellent red-white aesthetics, low plaque affinity, no material-related inflammatory reactions, optimal for conventional & digital workflow.

Made in Switzerland
– since 2005

Learn more on www.zeramex.com

www.zeramex.com

ZERAMEX

Two-piece zirconia implant for global metal-free restoration

Dr Riccardo Scaringi, Italy

Zirconia in dentistry has historically been known for its strength and biocompatibility characteristics in simple or complex prosthetic rehabilitation. Only in the last decade has it become more widely used in implantology as well. Zirconia is a mixture of composites based on zirconium dioxide. Zirconium is the metal from which the eponymous dioxide is derived. The powders used to obtain zirconia have a very high degree of purity and are obtained through complex chemical and co-precipitation procedures.¹ The crystalline structure of zirconia occurs in different geometric shapes depending on the temperature to which it is subjected and reversibly changes from a monoclinic state at room temperature to a tetragonal state up to 1,100 °C and a cubic state at around 2,400 °C. Therefore, the density of the material is determined by the shape and size of the geometric state, which determines a different final size and a different physical property, depending on the heat treatment.²

Sintering takes place at temperatures above 1,170 °C, determining a change of state from tetragonal to monoclinic. This causes stress that leads to fracture of the artefacts, which is why oxides were introduced to stabilise the composite and prevent fracture. In the medical field, various oxides, such as magnesium oxide, titanium dioxide, alumina, yttrium oxide and ceric oxide, are used in small percentages combined with zirconia, creating stability in various sintering processes and cre-

ating a family of zirconia-based ceramics with different chemical, physical and structural characteristics.³

Advancement in dental implantology occurred with the addition of yttrium oxide to zirconia, generating yttrium tetragonal zirconia polycrystals (Y-TZP). Although this achievement has only recently been translated to clinical practice, the initial studies date back to the early 1960s with ceramic materials that allowed such maturation and knowledge that today allow a degree of excellence for biomechanics and integrative biocompatibility with the hard and soft tissue of the oral cavity.⁴ Zirconia does not cause systemic or local cytotoxicity, and cytocompatibility *in vivo* and *in vitro* has been reported.⁵ In order to accelerate the healing time, osseointegrative properties were achieved through surface treatment by increasing hydrophilicity with different procedures.¹¹ Bacterial colonisation and adhesion to the implant surface are related to the material type used, Y-TZP having significant advantages over titanium.¹⁰ *In vitro* tests have shown less accumulation of the various bacterial strains present in the oral cavity, and significant results of less adhesion on zirconia or titanium abutments has been demonstrated *in vivo*.^{12–16} The absence of metal oxides allows for improved biological response of the gingival tissue, resulting in reduced bacterial formation and subsequent inflammatory onset.¹⁸

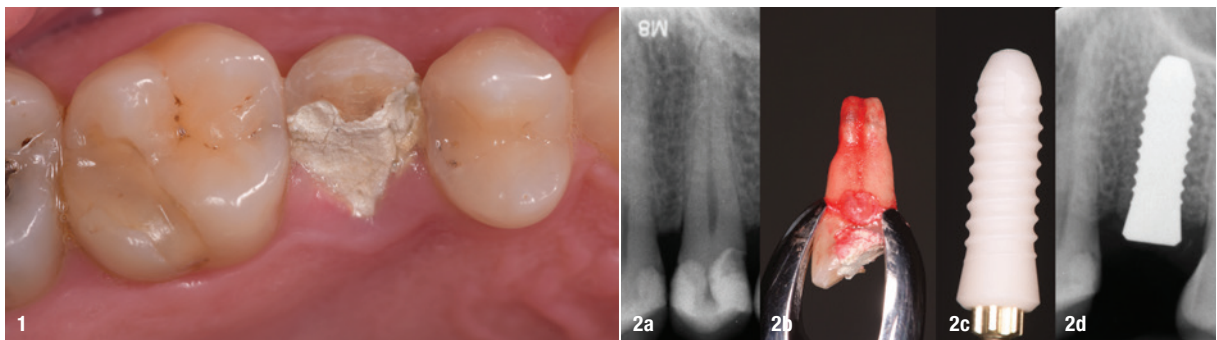


Fig. 1: Occlusal image of the coronal fracture of the partially medicated tooth to soothe the thermal sensitivity caused by uncovering of the pulp chamber. **Figs. 2a–d:** Initial radiographic image showing the close proximity to the floor of the maxillary sinus in addition to the viability of the tooth and the absence of periradicular infection (a). Extracted root (b). CERALOG Hexalobe implant (c). The result of implant placement with respect to the sinus floor and the osseous and interradicular relationship (d).



**STRAUMANN
WORLD CLASS CUP
2022**



CUTTING-EDGE CLINICAL SCIENCE, WORLD-CLASS COMPETITION

The Straumann World Class Cup is a leading innovative hybrid event that brings together top clinicians from around the globe to showcase their expertise on key topics in dentistry: Immediacy, Regenerative, Digital and Esthetics. From September through December 2022, follow along as 20 teams present high-quality clinical cases over 3 virtual rounds. Straumann World Class Cup culminates in a 4th and final round in which the highest scoring teams will compete face-to-face in the **ESTHETIC DAYS** event.

HIGH-QUALITY CLINICAL CONTENT IN A FRESH, FUN FORMAT

Straumann World Class Cup is the premium clinical education event for dental professionals in 2022! Over the course of 4 months 80 experienced clinicians will share their best cases as they compete to win the World Cup.

Twenty teams – each composed of 4 clinicians – will demonstrate their expertise and clinical skill while educating the audience at the same time. Matches will consist of a clinical case presentation by each team that applies evidence-based treatments and showcases valuable real-world clinical applications ready to use in your daily practice. The variety of clinical approaches and topics will open new perspectives and present tools for more efficient and predictable solutions for your patients.



REGISTER NOW ON
www.straumann.com/swcc

EACH ROUND OF MATCHES WILL FOCUS ON A KEY TOPIC IN DENTISTRY:

- Qualifying Round 1 (Virtual) – September 6th–9th:
Immediacy
- Qualifying Round 2 (Virtual)– October 4th–7th:
Regenerative
- Qualifying Round 3 (Virtual) – November 8th–11th:
Digital
- Final Match (In person) – December 3rd:
Esthetics

A jury of 12 world-renowned experts will evaluate the cases and assign points. The winner of each virtual round – and the chance to participate in the final face-to-face match in Palma de Mallorca – will be determined by both the expert jury and audience voting.

To become the winner of the Straumann World Class Cup, the 4 clinicians composing a team will have to work together and indispensable to their success will be the loyal fans back home who engage, share, and vote for their team.

Attractive prizes will be awarded throughout the entire competition to recognize the efforts and skill of as many teams as possible.

Make sure to follow the Straumann World Class Cup online, where scores and team rankings will be available 24/7.

This is the 2022 event you can't miss! Sharpen your skills while learning from the world's finest clinicians in an innovative format. Whatever your level of expertise, you're sure to discover a tip, tool, or treatment approach that you can apply in your own clinical practice.

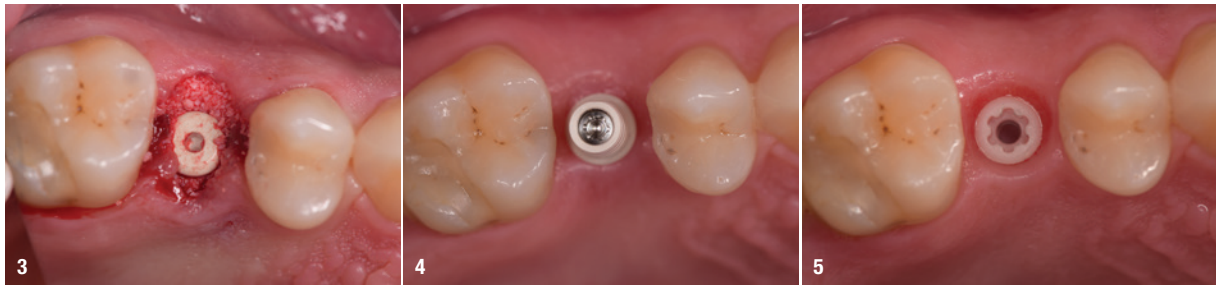


Fig. 3: Occlusal view of the CERALOG implant placed using a flapless technique and filling of the spaces between the bone and implant. **Fig. 4:** Provisional PEEK abutment *in situ*, to which the provisional crown produced by CAD/CAM was to be bonded. **Fig. 5:** The tissue conditioning and bone healing situation after 56 days of functional loading with the provisional crown.

The characteristic white colour of zirconia implants blends in better below the gingival tissue, especially in thin phenotypes, avoiding those unsightly grey shadows peculiar to titanium implants, especially for those implant designs with a smooth collar. Moreover, even in the case of gingival recession, no exposure of metal portions occurs.¹⁷

An important aspect that characterised the first generation of zirconia implants was the frequency of fracture, being about 4%, especially in the first year of loading, in cases of particular tightening of the abutments with metal screws and in two-piece implants with a diameter of less than 3.5 mm.¹⁹ The rate has dropped below 0.5% owing to advancements in the manufacturing process, in material preparation and in implant fabrication whether by milling or isostatic pressing.²⁰

As an additional fact to be noted in the knowledge of this new implant material concerns the ageing of the structure, better known as hydrothermal degradation (low-temperature degradation), that occurs at temperatures above 150 °C in an environment with the presence of water.²¹ In order to fully control such degradation, ceric oxide or alumina was added to the zirconia powder composite.²² Based on the experience gained in these 30 years of research and development, we can now consider zirconia implants a viable substitute for titanium implants, especially in highly

aesthetic areas or in those patients in whom tissue quality or particular susceptibility to bacterial colonisation may require a greater guarantee of long-term outcome.^{23, 24}

Clinical case report

The male patient was a 53-year-old non-smoker in an excellent state of health, ASA I, with vertical fracture of the crown of tooth #25 associated with spontaneous pain. In the first phase of treatment, we conducted an accurate clinical and diagnostic diagnosis in which we ascertained the possible therapeutic variables aimed at coronal restoration after crown lengthening, root canal therapy and core reconstruction on which to finalise a clinical crown. The patient presented to the clinic with masticatory trauma that had caused a clear fracture of the palatal cusp of the vital tooth restored according to a direct composite technique. The fracture was extensive in depth to at least 1 mm subcrestally, in addition to uncovering the pulp chamber (Fig. 1). After careful evaluation and comparison of procedures, the patient was shown the various treatment options and opted to have the fractured tooth replaced with an implant. The choice of a ceramic implant was considered for a number of factors, including global metal-free restoration and an aesthetic outcome. We decided on a two-piece Y-TZP implant (CERALOG™, BioHorizons Camlog) made using a high-tech production process for molding (Ceramic Injection Molding–CIM).

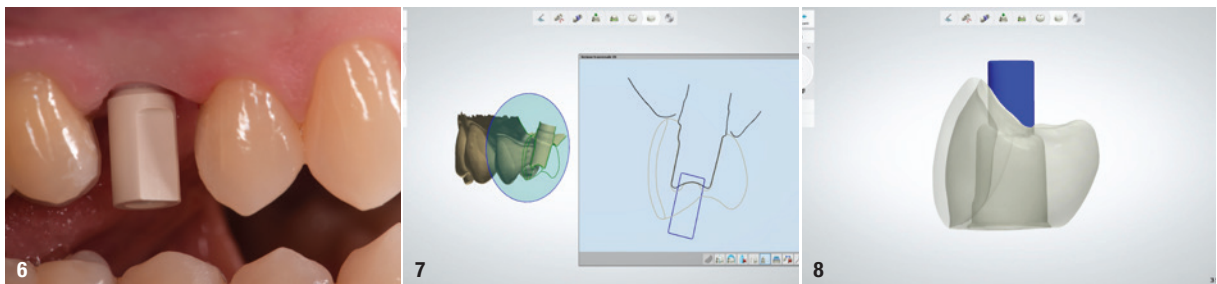


Fig. 6: The scan body on the implant. **Fig. 7:** The sectional design of the crown allowed for a broad evaluation. **Fig. 8:** The design showing subtraction from the vestibular aspect to accommodate the ceramic layering.

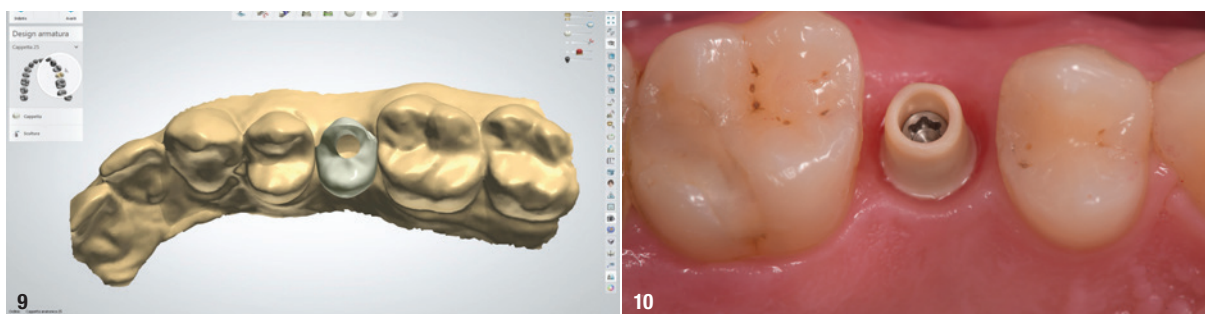


Fig. 9: View of the design in the context of the virtual model, showing the transition points in the adjacent contacts and the access hole in the occlusal aspect, avoiding compromise of aesthetics and of resistance to masticatory forces. **Fig. 10:** The final abutment of PEKK, a biocompatible material that is resistant to oral fluids and masticatory forces.

Root extraction was performed according to a flapless technique, avoiding injury to the cortical bone. The use of piezo-surgery allowed for facilitated removal without cortical compression (Fig. 2). Site preparation is a delicate step in implant surgery, especially for zirconia implants. In fact, ceramic implants tolerate screwing stresses poorly; therefore, the site must be carefully prepared with adequate irrigation and possible tapping of the site, especially in cases of Class D1 and D2 compact bone. In the present case, subcortical insertion was not necessary, but in the event of need, there is a countersinking function available in the CERALOG system, which allows placing the implant subcrestally while avoiding cortical compaction that usually induces vertical resorption.

Like with titanium implants, placement of zirconia implants requires primary stability. The difficulty is initially associated with the point of engagement of the first drill to match the centre of the implant with the inter-coronal distance. It is not always possible to use this point for implant insertion because of the variables associated with root shape and the number of roots present. The maxillary second premolar usually presents a single root or in some cases two fused roots, and therefore it lends itself more easily to a contextual replacement. The only problem is associated with the upper boundary with the cortical floor of the maxillary sinus that could limit the excursion of the pilot drill beyond the apex in search of greater primary stability (Fig. 2).

In this case, a cylindrical body zirconia two-piece implant of 12.0mm in length and 4.1mm diameter was used considering that the prosthetic collar had a diameter of 4.5mm. The spaces between the bone and the implant were filled with slowly resorbing biomaterial to better preserve the alveolar bone. The implant was deliberately not restored immediately, because although the primary stability achieved was 55 ISQ, we preferred to leave the implant to heal naturally and not expose it to further occlusal trauma (Fig. 3). A healing abutment was placed on the implant.

After eight weeks, we removed the healing abutment and took a digital impression for the preparation of a provisional restoration placed on a PEEK temporary abutment for an additional four weeks (Fig. 4), at the end of which we removed the screw-retained provisional crown and noted the degree of peri-implant mucosal conditioning. We took a new impression with an intra-oral scanner using a scan body (Figs. 5 & 6). By using the implant system's scan body, we were able to capture the implant's specifications or the dental technician. The scan body stops at the implant connection and does not interfere with the soft tissue. The digital impression also allows for excellent reading of the conditioned tissue so that the aesthetic margins achieved can be followed. The file was sent to the dental laboratory after filling out the attached data sheet listing the implant type and model, the type of restoration desired, whether screw-retained or cemented, and the material with which it was to be finalised. The software is able to detect colour values so that an initial colour indication can be defined.

The choice of a two-piece zirconia implant allows a single restoration or possibly a multi-unit cemented restoration thanks to the design of dedicated frameworks utilising CAD/CAM and the DEDICAM CAD libraries. The data collected is supported by photographic status and spectrophotometric images. Digital data has great versatility of use and limited cost and offers great potential for use and communication effectiveness even at a distance. The dental technician was able to make a careful assessment of the implant position, the possibility of making a screw-retained prosthesis, the aesthetic margins, and the prosthetic components to be used. The dental technician is able to determine the feasibility of the restoration according to the prescription, sharing with the clinician the potential and limitations present in the specifications. It is not always possible to have an angulated screw-retained abutment allowing an access hole in a region congruous with the aesthetics and function of the implant in case the implant-abutment connection is modified by inclining the bearing surface of the implant shoulder (Fig. 7).