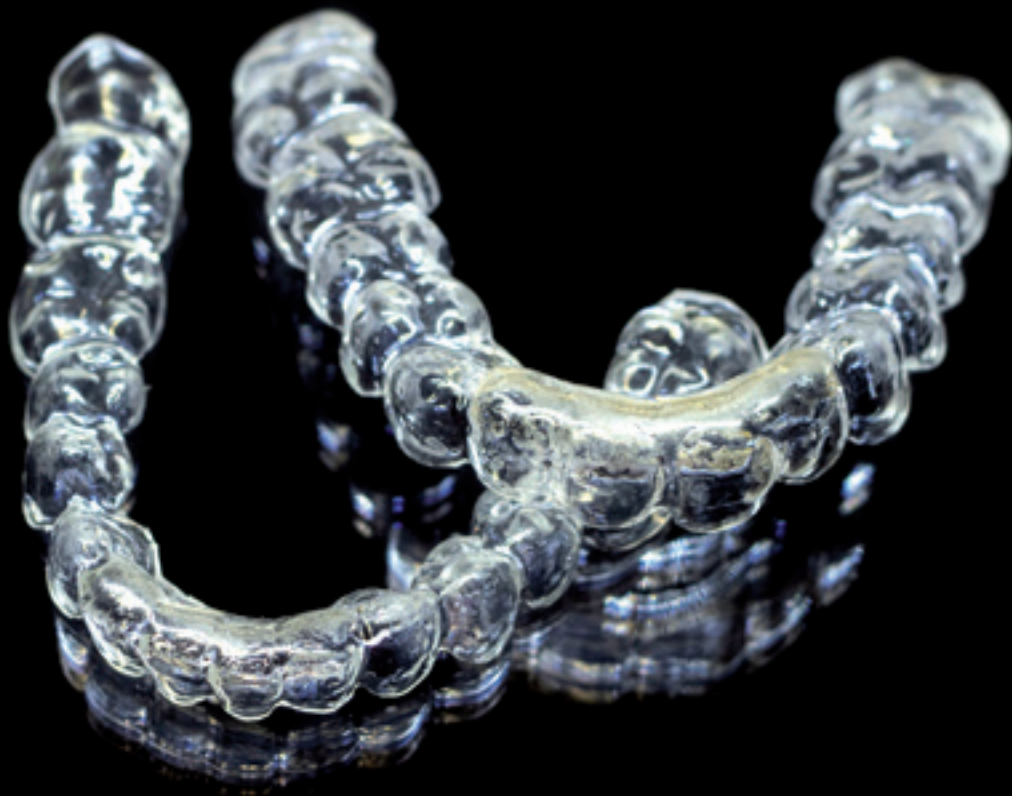

ortho

international magazine of orthodontics



case study

Provisional restoration of missing anterior teeth: A 3-D printing application

case report

Mouth-breathing, malocclusion and the restoration of nasal breathing

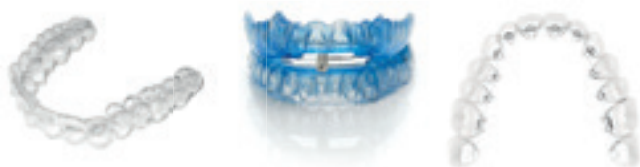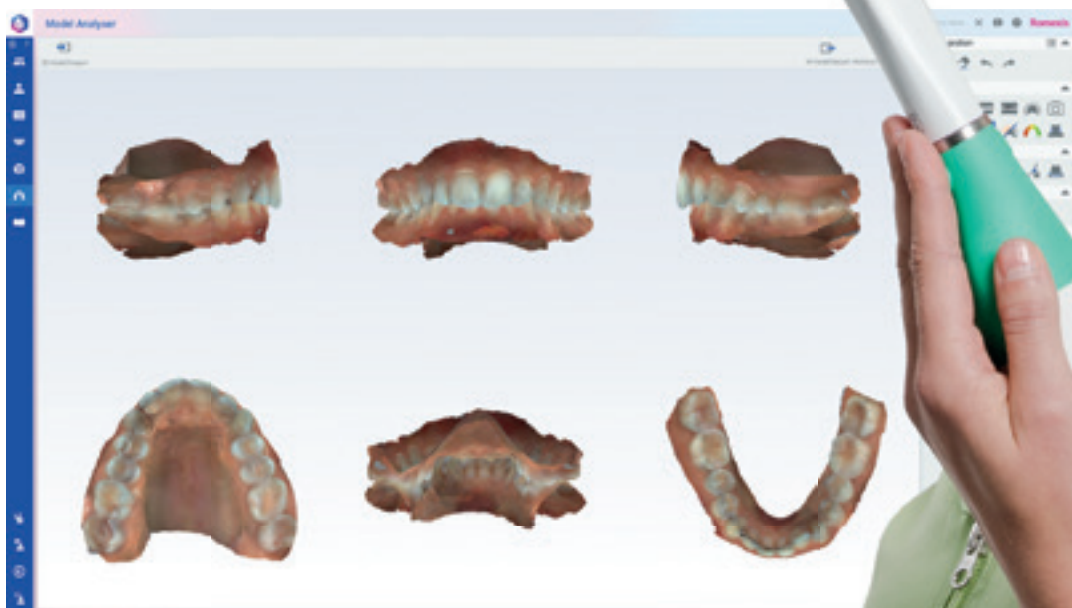
interview

Three-dimensional “technologies are going to become the standard of care”

Planmeca Emerald™ intraoral scanner

Smooth and fast workflow for orthodontics

- Fast and accurate full arch scanning with Planmeca Emerald™
- Comprehensive orthodontic design software
- Compatibility with several orthodontic solutions



Orthodontic solutions:

DW Lingual Systems GmbH

orthocaps[®]
creating smiles

clearcaps[™]

ClearCorrect[™]

BIOTECH DENTAL
SMILERS

F22ALIGNER
aligner teeth aligner

OrthoApnea

alineadent
ENJOY YOUR SMILE

SLX[™] Clear Aligners

Full list of compatible providers: planmeca.com/orthocompliance



PLANMECA

Planmeca Oy Asentajankatu 6, 00880 Helsinki, Finland. Tel. +358 20 7795 500, fax +358 20 7795 555, sales@planmeca.com, www.planmeca.com

Prof. Carlo Fornaini

Researcher, Université Nice Sophia Antipolis, Nice, France
 Researcher, University of Parma, Parma, Italy



Dear Readers,

Consider the following fable ("Monkeys on a trip") by Italian writer Gianni Rodari:

One day the zoo monkeys decided to make an educational trip. They walked and walked, then they stopped and one asked:

- *What do you see?*
- *The lion's cage, the seals' pool and the giraffe's house.*
- *What a big world, and how instructive is travelling.*

They started again their journey and stopped only at midday.

- *What can you see now?*
- *The giraffe's house, the seals' pool and the lion's cage.*
- *What a strange world and how instructive is travelling.*

They started travelling again and stopped at sunset.

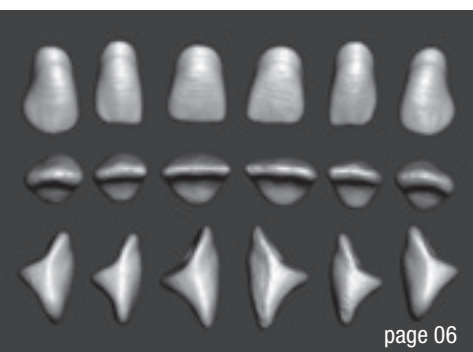
- *What is to be seen?*
 - *The lion's cage, the giraffe's house and the seals' pool.*
 - *What a boring world: you always see the same things.*
- And travelling is no use at all.*

Of course! They travelled and travelled, but they had not gotten out of their cage and did nothing but going round and round as do the horses in a merry-go-round.

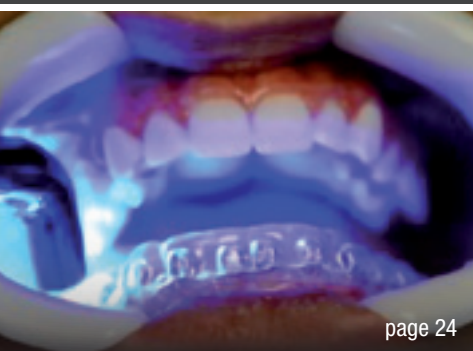Sometimes, we too do not explore beyond the technique we use daily for our treatments because we think it is the only one possible and the best solution for each situation. But read on to see that it is not so...

We have to put a great deal of effort into pushing past the limitations we set ourselves, to change our minds and to look for and find what is good and positive in the work of our peers. And that will be the key to our success! This issue of *ortho* contains some interesting and original approaches for you to consider and learn from and perhaps even apply in your practice!

Prof. Carlo Fornaini



page 06




page 24



page 38

Cover image shutterstock_1266384271



editorial

Dear **Reader**

Prof. Carlo Fornaini

03

case study

Provisional restoration of missing anterior teeth:

A 3-D printing application

Dr Christopher Riolo & Cali Kaltschmidt

06

case report

Mouth-breathing, malocclusion and the restoration of nasal breathing

Dr Derek Mahony & Roger Price

08

clinical study

New **JVBarre maxillary segmental distalizer** and **BiTurbo2 System** for greater aesthetics, effective and efficient skeletal Class II treatment: **Control of canine over-extrusion and bodily maxillary molar distalisation**

Dr John C Voudouris & John Dean Voudouris

14

interview

Three-dimensional “technologies are going to become the standard of care”

Dr Sean K. Carlson

20

industry report

Maestro 3D

Three ways to create transfers for indirect bonding

Dr Terence Whitty

24

industry report

I choose **high**; this is **why...**

Dr Jonathan Nicozisis

28

manufacturer news

Planmeca orthodontics—The right digital workflow for you

34

meetings

European Aligner Society Spring Meeting back in Venice

ICD and **DTI** sign media partnership agreement

36

38

International Events

40

about the publisher

submission guidelines

41

international imprint

42

MAESTRO 3D

Innovative solutions for dental applications

www.maestro3d.com



2 x 5.0 MEGAPIXEL

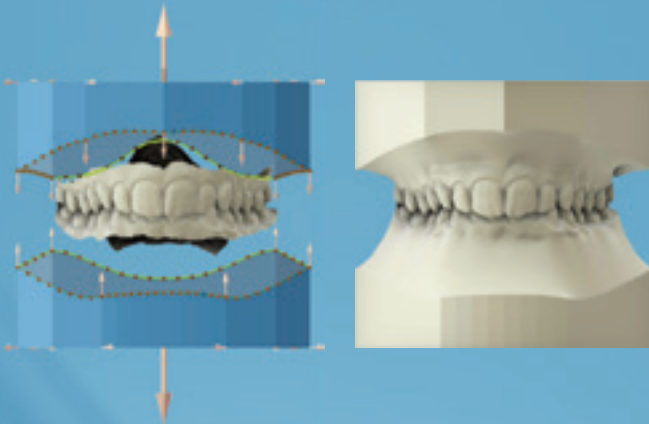
Plug & Play 

Smart Impression Scanning

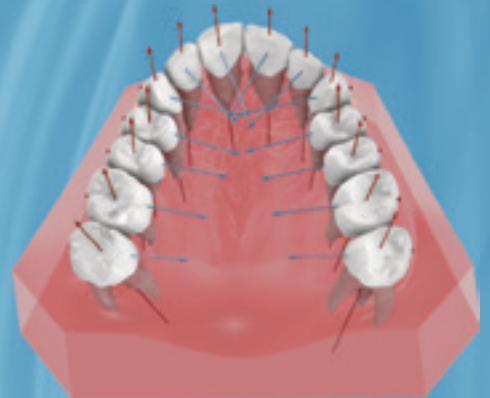
Accuracy less than 8 micron

Texture Superimposition

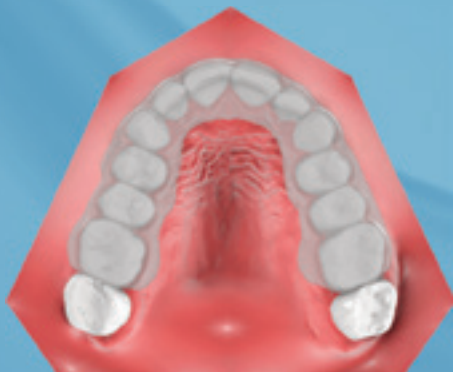Study Models



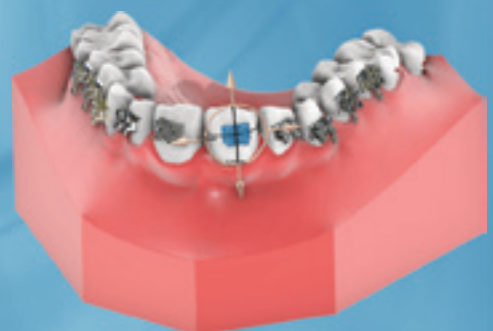Virtual Setup



Clear Aligner



Indirect Bonding



Provisional restoration of missing anterior teeth: A 3-D printing application

Dr Christopher Riolo & Cali Kaltschmidt, US

Introduction

Provisional replacement of anterior teeth is problematic when using custom orthodontic appliance systems. A digital pontic library can be used to integrate provisional teeth into the treatment set-up and, therefore, efficiently into orthodontic appliance systems. The same digital workflow can be applied during treatment with custom fixed appliance systems and to create custom pontics for thermoformed retainers. In this paper, we will use a case example to illustrate the use of a custom pontic library for the replacement of anterior teeth.

Case study

The patient presented to our office with the chief request for replacement of missing teeth. The treatment plan consisted of maxillary and mandibular fixed orthodontic appliances, and interproximal reduction to gain the required space for the implant replacement of the maxillary lateral incisors. A custom fixed orthodontic appliance system was used. The amount of interproximal reduction was determined using the initial digital treatment set-up that was used to plan and fabricate the custom orthodontic appliance. After idealising the space for implant placement, we gave the patient the choice of leaving the fixed appliances in place during implant integration in order to continue to support his lateral incisor pontics or debonding the fixed appliances and provisionalisation of lateral incisors using a removable orthodontic thermoformed retainer.

The patient opted for the latter choice, to provisionally restore the maxillary lateral incisors using a thermoformed retainer. This retainer was delivered with pontics on the same day as the debonding of the fixed appliances. After removal of the orthodontic fixed appliances, the patient was scanned with an intra-oral optical scanner in order to obtain STL files of the arches. Both the upper and lower arches were prepared for printing using Meshmixer, free 3-D sculpting software (www.meshmixer.com), to repair defects in the mesh and

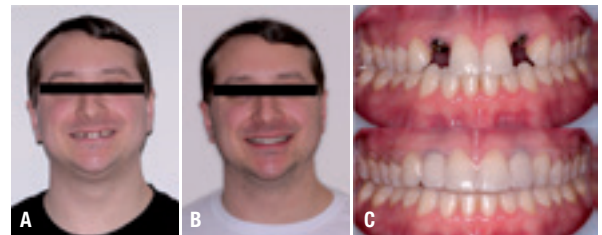

Fig. 1: The patient from the frontal facial smiling view (A & B) and the intraoral anterior view (C) before and after the delivery of the thermoformed retainer with the custom provisional pontics.

base of the models. The editing process is outlined in detail in a tutorial available.¹ The lower arch was immediately printed in photosensitive resin using a digital light processing (DLP) printer, while the upper arch was edited again using Meshmixer to insert pontics from the digital pontic library into the lateral incisor positions.

Discussion

Incorporating the digital pontics into the treatment set-up streamlines the workflow associated with the use of pontics when using custom orthodontic appliance systems. We have created a complete digital pontic library to utilise when provisionalisation of missing anterior teeth is required. Figure 2 displays our digital pontic library from the facial, incisal and profile views. Each of these digital pontics is a separate STL file that can be edited or integrated with other STL files.

The editing process for the replacement of the anterior teeth entails importing a digital lateral incisor pontic into the scene that already contains the repaired and based upper arch. The aspect ratio of the digital pontic can be adjusted in two ways: if the exact size of the space for the lateral incisors has been predetermined, the dimensions can be typed in directly; or the transform tool in Meshmixer can be used to adjust the proportions by hand. In order to obtain the proper mesiodistal width, the pontic is adjusted along the x-axis. A tutorial outlining this workflow step by step is available.^{2,3}

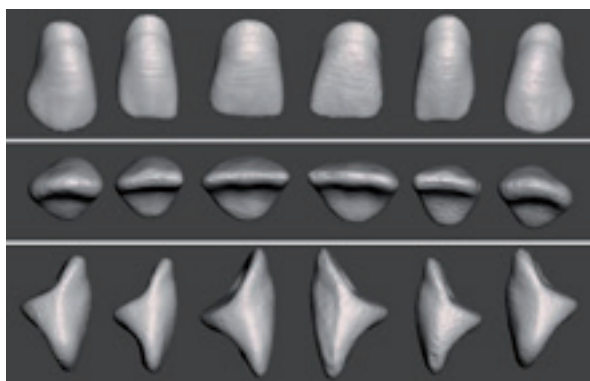


Fig. 2: The digital pontic library from the facial, incisal and profile views.

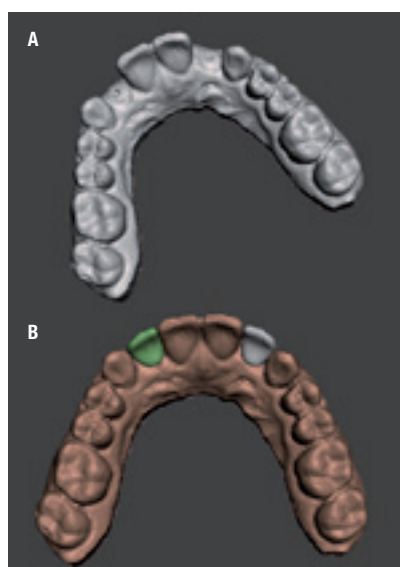


Fig. 3: The STL file after editing in Meshmixer before (A) and after placement of the digital pontics (B).

Not only is the aspect ratio adjusted, but the torque, angulation and buccolingual offset are also accounted for in the positioning of the pontic. Once the digital pontics are in position, all three parts are combined into one STL file using the combine tool. This solid, single STL file is then exported and the model printed in photo-sensitive resin with a DLP printer. A thermoformed retainer is then created with the plastic of your choice, such as BioStar (Great Lakes Dental Technologies) or Druformat (Dentsply Sirona).

The lateral incisors in the thermoformed retainer can be filled with tooth shade-appropriate polyvinylsiloxane adhesive material or composite. There are many ways to do this; Reliance Orthodontic Products supplies the Perfect A Smile pontic aligner paint, available in the new Light (PASL) and Medium (PASM) shades and the original shades Light (PPB1), Medium (PPA2) and Dark (PPA3). It is important to use the materials that work in your hands. This procedure can be completed in a single appointment if working with a 3-D printer that is sufficiently fast.

The JUELL 3D printer (Park Dental Research) we use in our office is capable of printing this model in approximately 30 minutes, making it possible to deliver a thermoformed retainer with the anterior teeth provisionalised to the patient in about one hour after debonding.

The same workflow can be used to duplicate a tooth shade-appropriate pontic for most custom lingual fixed appliance systems, such as Incognito (3M Unitek), HARMONY (ASO International) and SureSmile (Dentsply Sirona). If the system uses CAD software to design the appliance; the bracket can be custom-made for the pontic and the wire can be robotically bent accordingly in three planes of space. Digital technology and 3-D printing grant a unique benefit to orthodontic specialists, providing value to the treatment set-up and overall care to our patients.

Editorial note: A list of references is available from the publisher.

about



Dr Christopher Riolo has an undergraduate degree in mathematics, a DDS, a master's degree and certificate in orthodontics, and a PhD in epidemiology. Currently, he is an affiliate associate professor at the University of Washington in the US and course director of both the interdisciplinary seminar and interdisciplinary clinic

segment. He is certified by the American Board of Orthodontics and an affiliate member of the Edward H. Angle Society. He maintains an all-digital private practice in downtown Seattle specialising in adult aesthetic orthodontics. Dr Riolo lectures nationally on topics related to digital orthodontics, custom orthodontic appliances and in-house orthodontic workflow.



Cali Kaltschmidt has been the clinic manager at Dr Riolo's private practice in downtown Seattle for the last six years and has developed the digital workflow necessary to operate both resin and metal printers in the orthodontic environment. She specialises in digital design using Meshmixer and other 3-D modelling software. Cali is a

published author on topics related to custom orthodontic appliances and 3-D printing, and has lectured nationally to all members of the dental team on the topic of 3-D printing and digital orthodontics.

Mouth-breathing, malocclusion and the restoration of nasal breathing

Dr Derek Mahony & Roger Price, Australia

Introduction

Most dentists and orthodontists are aware of the impact that mouth-breathing has on the development of the maxilla. Most are also aware of the fact that, even after successful realignment of teeth, unless a retainer is used, relapse usually occurs. The tongue is nature's retainer and, at the lateral force exertion of 500 Gm, provides the balance required against the inward force pull of the cheek muscles, also at around 500 Gm. In an ideal world, these two forces would balance each other, and normal maxillary development would take place. The primary teeth would erupt smoothly and evenly, and even in the mixed dentition stage, there should not be overcrowding or malalignment of teeth.

What causes mouth-breathing to occur and what can be done about it? The answer to this lies in the basic physiology that we all studied during the early part of our careers. At the time that we learnt it, we were not able to see its overall importance, as we had yet to study the full gamut of anatomy and physiology to see how it all inter-related. By the time this happened, we had forgotten most of it. So, it should not come as any surprise that the information that follows will certainly strike a chord and probably elicit the usual comment "But I knew that!"

Discussion

Before attempting to discuss what constitutes functional as opposed to dysfunctional breathing, it is necessary to understand the mechanism of breathing in all its complexity. Functional breathing is initiated when the carbon dioxide (CO_2) level in the arteries (PaCO_2) reaches 40 mm Hg and stimulates the medullary response at the base of the brain. This in turn sends a signal to the diaphragm, causing it to contract and relax, and so the breathing cycle is maintained. So what goes wrong (Fig. 1)?

There are norms for blood pressure, pulse, temperature, chemical content of the blood and so on, but there is no such thing as normal breathing. Breathing has to be ap-

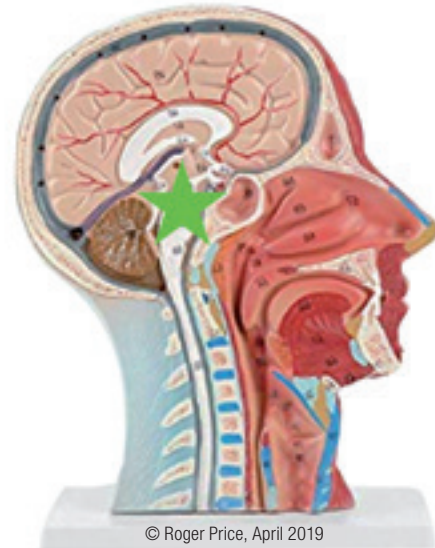


Fig. 1: What makes us breathe?

One of the prime roles of breathing is to maintain the pH of arterial blood at the optimal chemical axis, which ranges from 7.35 to 7.45.

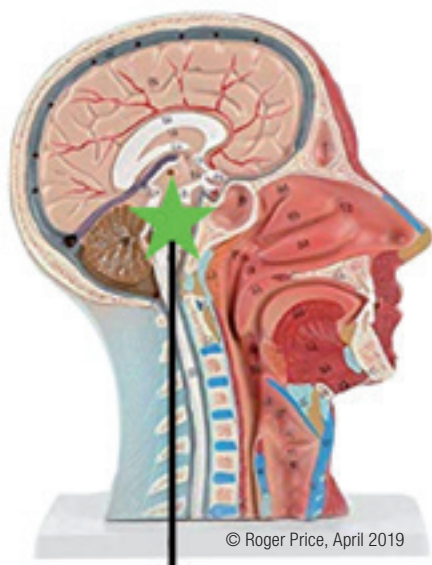
This is a critical function, as it controls the transport and release of oxygen throughout the body.

When the chemoreceptors in the brainstem sense an imbalance in the chemical axis, breathing is adjusted automatically to restore optimal function.

This can increase or decrease breathing rate, depth, volume, mechanics, dynamics and behaviour patterns.

appropriate for the activity at the time, and what might be okay when running around the football field, is certainly not okay when sitting on a couch watching a football game, beer in hand and loads of high-fat, salt-laden snack food at hand.

Therefore, in the absence of normal breathing, the best we can hope for is the determination of functional breathing at rest (Fig. 2).



Optimal alveolar pressure of CO₂ should be 40 mm Hg.

Fig. 2: Functional breathing at rest.

THERE IS NO SUCH THING AS NORMAL BREATHING
Breathing is directly linked to activity, nutrition, stress levels and other external factors. The chemical axis requires constant monitoring and reacts instantaneously to any pH imbalance.

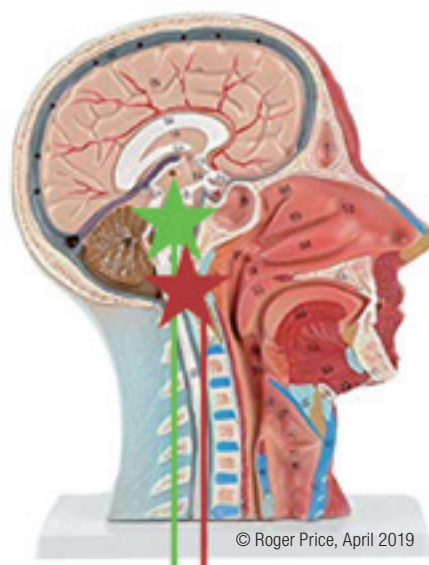
There is however a definition for functional breathing at rest, which is:

- Breathing in and out through the nose
- Driven by the diaphragm, not the chest
- 8–12 breaths per minute
- Minute volume of 5–6 litres
- Silent

Under these conditions optimal alveolar pressure of CO₂ will be close to 40 mm Hg.

In the 64 years since starting my studies as a pharmacist, and moving on to many other “-ology” and “-opathy” modalities, I have seldom come across a doctor or dentist who has looked at a patient, counted the number of breaths he or she takes per minute and commented that he or she is breathing for two or three people. The medical professional surely enough comments about overeating or excessive drinking, but breathing is never even noticed.

Anything that happens to the human body that the system wants to resist or reject sets up a stress re-



Alveolar pressure of CO₂ drops below 40 mm Hg.

Fig. 3: Why breathing changes.

The constant exposure to stressors of various natures initiates the flight–fight response, which automatically triggers responses.

Among these are:

- Larger and faster breaths, which reduce the amount of CO₂ stored in the lungs.
- The tendency to mouth breathe in anticipation of threat or escape.
- Changes in blood clotting levels, endorphin release, blood flow away from vital organs to the muscles of flight or fight, and the body prepares for action.
- This action usually never occurs, as the dangers are perceived rather than real, and the body then has to resettle. If this is a regular occurrence, then symptoms appear.

sponse. This stress response, or mini-flight or fight, causes the release of adrenalin from the adrenal glands, and our breathing rate subsequently rises. This applies to what we ingest, what stressors we encounter factually, as well as emotionally or perceptually, and what physical stresses are placed on the body through poor posture and other anatomical abnormalities.

The constant messages of increased breathing rate or hyperventilation cause the chemoreceptors in the brainstem to reset themselves at what is now regarded as the “new normal”, and the standard breathing rate subse-