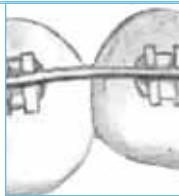




Opportunity awaits
Tips for landing the perfect associate job

▶Page 10



Calling all residents
How to get Wired For Success next year

▶Page 18



All about education
New clinics change the way practices operate

▶Page 21



The University of Michigan Campus in Ann Arbor. (Photos/University of Michigan)

Michigan bound

GORP brings residents, orthodontists and exhibitors together

By Kristine Colker, Managing Editor

The 22nd annual Graduate Orthodontic Residents Program (GORP) is heading back to the University of Michigan in Ann Arbor. From Aug. 6–8, orthodontic residents from across the United States and Canada will gather together to attend the yearly event.

More than 400 students are expected to attend this year's meeting, which will feature three days of sessions from such speakers as Dr. James A. McNamara, Dr. Vincent G. Kokich and Dr. John Graham,

→OT page 16

Miniscrews: a focal point in practice

Part 2 of 6:
Clinical examples

By Dr. Björn Ludwig, Dr. Bettina Glasl, Dr. Thomas Lietz and Prof. Jörg A. Lisson

Horizontal tooth displacement

Lack of space is one of the main reasons for the oblique positioning of teeth. One way to solve this problem is to create the necessary space.

Conversely, premature loss of teeth or anatomical abnormalities may result in gaps that require modification for various reasons. For the correction of horizontal tooth displacement, miniscrews can be used as these produce no undesirable reactive effects.

Distalization

The first case (Figs. 1a–c) presented involves a frequently encountered problem: the patient's molars had migrated in a mesial direction. This resulted in a marked loss of space in the region of the canines.

The two treatment options in such a case are extraction or distalization. In this case, distalization

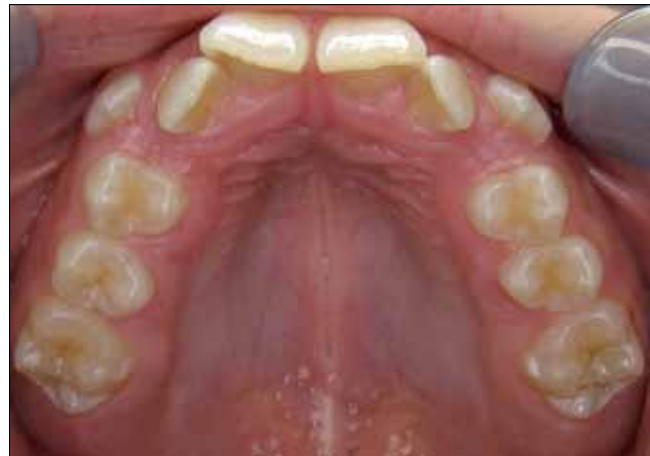

Fig. 1a: Distalization of the upper molars. Mesial positioning of teeth #16 and #26, showing clear displacement of the canines.

was a viable option and extraction was unnecessary.

Conventional techniques for distalization (apart from the use of headgear) require support from other groups of teeth. Creating anchorage in this way has negative reactive effects.

In the example under consideration, it is highly probable that protrusion of the anterior teeth would have resulted should a conventional method for distalization have been

employed. Such negative results can be avoided by the use of miniscrews

Miniscrews can be inserted in the vestibular and — as in this example — palatal areas. Vestibular insertion of a miniscrew (e.g., between the premolars) is always associated with the miniscrew's eventual interference with tooth migration. When this occurs, the miniscrew must be extracted and a conventional form

→OT page 4

AD

Dental Tribune America
213 West 35th Street
Suite #801
New York, NY 10001

PRSR STD
U.S. Postage
PAID
Permit # 306
Mechanicsburg, PA

MOTIVATE CHALLENGE

CONNECT

September 16-18, 2010

For a new generation of orthodontists who are passionately making their mark on our profession! REGISTER TODAY AT: www.orthoVOICE.com

Some thoughts on expertise and wisdom in practice

By Dennis J. Tartakow, DMD, MEd, PhD,
Editor in Chief



“I may not always do everything right, but I always try to do the right thing!” This was an extraordinary thought that Dr. Arlene Sack shared with me many years ago. It forever became the guiding principle throughout my years in practice, a set of values to conduct myself, and it always proved to be appropriate.

With this in mind, here are some doctor skills and guiding concepts to consider.

Doctor skills

- *Always make eye contact with your patients, be friendly and smile.* It doesn't matter if you see 50 patients or 150 patients per day; make each and every patient feel he or she is special to you.
- *Always talk to your patients.* Patients must also be reminded about what you are doing for them. If an impacted maxillary cuspid is brought down into occlusion with simple mechanics, tell the patient that you did it without the need for surgery — and that you saved him or her lots of money. Before-and-after photographs are effective reminders because they tell the story.
- *Are you defensive?* If the patient complains that a fee is too high, you might respond by saying, “Yes, our fee is higher than other orthodontists, and here's why we are higher ...” When an issue is openly acknowledged, individuals are often more receptive to your message.
- *Are you prepared for unexpected questions that patients may ask?* Have you and your staff worked on answering such familiar questions and statements as: “Why must I come in for appointments so often?” “My child can only come in after school for appointments.” “Why are your fees so high?” “We're divorced. Can you speak to my ex-husband about your fee?” “My insurance has changed. Can you recommend a dentist on my company's list?” “Will I be in pain?” Your answers to these predictable questions can make or break your schedule

and, indeed, your entire practice.

- *Are you sure the office telephone is answered properly?* The phone is an exceptional office tool — poor communication skills from an office staff member may turn someone away who could have been your new patient. Most of us aren't great at “winging it.” Scripting dialog is about preparing a few key words and short phrases that can instill understanding for both you and your staff members and which may instill even greater understanding and confidence in your patients.
- *We all assume we say the right things at the right times and have the right answers for our patients. However, how many of us listen to what we say to our patients?* Too often we forget to say the simple things such as: “Thank you!” or “What problems are you having today?” or “How can I help you?” or, especially, “I appreciate your confidence.” Consider tape-recording some of your conversations with patients to get an idea of the dialogue. This can be a great learning technique for your staff members: What are they saying and what are patients hearing?

Guiding concepts

- *Trust without accountability is really blind faith.* Does your office have a system of accountability? Does each staff member know that he or she is accountable and that you have clear expectations of everyone? Do you monitor results or hear what is being told to your patient?
- *Train your team to recognize unusual or improper behavior from either fellow staff or patients.* Let them know that it is their job to report any and all improprieties. Staff members see and hear more than you do, and it is essential for you to be knowledgeable about your practice.
- *Let all employees know your embezzlement policy.* Define embezzlement and make it known in your employee manual that you will prosecute. Such a statement by itself may deter a potential embezzler. Preventing embezzlement helps protect not only you but honest staff members as well. Trustworthy team members take pride in following ethical and moral business procedures.
- *We never get a second chance to make a good first impression.* Sometimes we take ourselves, or our work, too seriously. Patients look to us for reassurance every day; they want to believe what we say and do are in their best interest. They are attracted to success — show them you are successful!
- *Real leadership is about telling the truth; it is visible to every-*

one — staff and patients alike. We have one chance to make a good impression. Our word is our character, and we rarely get a second chance to redeem ourselves. Treat all patients, children or adults, the way you would want to be treated. Success, therefore, begins with you, in and out of your office!

- *Never criticize other orthodontists or other professionals.* When we criticize our colleagues, especially without knowing all the facts, we are telling our patients, “Doctors cannot be trusted.” As in every profession, there are individuals who cannot be trusted. However, most doctors are caring and committed, and that is the message we should be sending. Think of the “Eleventh Commandment”: Thou shall not speak ill of our fellow colleagues!
- *Act with diligence; practice with courage, conviction, tenacity and, above all, attention to details.*

Finally, keep in mind the five “A” principles: aware, alert, anticipate, action and avoid. These words may prove beneficial.

“The Greeks didn't write obituaries. They only asked one question after a man died: ‘Did he have passion?’” (“Serendipity,” Miramax, 2001).

Do you have the passion needed for success in your practice? **OT**

OT Corrections

FORESTADENT was spelled incorrectly in a headline on Page 10 of Ortho Tribune, AAO Daily (Special Edition). Ortho Tribune regrets the error.

Ortho Tribune strives to maintain the utmost accuracy in its news and clinical reports. If you find a factual error or content that requires clarification, please report the details to Managing Editor Kristine Colker at k.colker@dental-tribune.com.



Image courtesy of Dr. Earl Broker.

Member Publication
AADE
American Association
of Dental Editors

ORTHO TRIBUNE

The World's Orthodontic Newspaper - U.S. Edition

Publisher & Chairman
Torsten Oemus, t.oemus@dental-tribune.com

Vice President Global Sales
Peter Witteczek
p.witteczek@dental-tribune.com

Chief Operating Officer
Eric Seid, e.seid@dental-tribune.com

Group Editor & Designer
Robin Goodman
r.goodman@dental-tribune.com

Editor in Chief Ortho Tribune
Prof. Dennis Tartakow
d.tartakow@dental-tribune.com

International Editor Ortho Tribune
Dr. Reiner Oemus
r.oemus@dental-tribune.com

Managing Editor/Designer Ortho Tribune & Show Dailies
Kristine Colker, k.colker@dental-tribune.com

Managing Editor/Designer Implant, Lab & Endo Tribunes
Sierra Rendon, s.rendon@dental-tribune.com

Online Editor
Fred Michmershuizen
f.michmershuizen@dental-tribune.com

Account Manager
Humberto Estrada
h.estrada@dental-tribune.com

Account Manager
Mark Eisen, m.eisen@dental-tribune.com

Account Manager
Gregg Willinger
g.willinger@dental-tribune.com

Marketing Manager
Anna Wlodarczyk
a.wlodarczyk@dental-tribune.com

Marketing & Sales Assistant
Lorrie Young, l.young@dental-tribune.com

C.E. Manager
Julia Wehkamp
j.wehkamp@dental-tribune.com

Dental Tribune America, LLC
213 West 35th Street, Suite 801
New York, NY 10001
Phone: (212) 244-7181, Fax: (212) 244-7185



Published by Dental Tribune America

© 2010, Dental Tribune International
All rights reserved.

Dental Tribune makes every effort to report clinical information and manufacturer's product news accurately, but cannot assume responsibility for the validity of product claims, or for typographical errors. The publishers also do not assume responsibility for product names or claims, or statements made by advertisers. Opinions expressed by authors are their own and may not reflect those of Dental Tribune International.

OT Editorial Advisory Board

Jay Bowman, DMD, MSD
(Journalism & Education)

Robert Boyd, DDS, MEd
(Periodontics & Education)

Earl Broker, DDS
(T.M.D. & Orofacial Pain)

Tarek El-Baily, BDS, MS, MS, PhD
(Research, Bioengineering & Education)

Donald Giddon, DMD, PhD
(Psychology & Education)

Donald Machen, DMD, MSD, MD, JD, MBA
(Medicine, Law & Business)

James Mah, DDS, MSc, MRCD, DMSc
(Craniofacial Imaging & Education)

Richard Masella, DMD (Education)

Malcolm Meister, DDS, MSM, JD
(Law & Education)

Harold Middleberg, DDS
(Practice Management)

Elliott Moskowitz, DDS, MSD
(Journalism & Education)

James Mulick, DDS, MSD
(Craniofacial Research & Education)

Ravindra Nanda, BDS, MDS, PhD
(Biomechanics & Education)

Edward O'Neil, MD (Internal Medicine)

Donald Picard, DDS, MS (Accounting)

Howard Sacks, DMD (Orthodontics)

Glenn Sameshima, DDS, PhD
(Research & Education)

Daniel Sarya, DDS, MPH (Public Health)

Keith Sherwood, DDS (Oral Surgery)

James Souers, DDS (Orthodontics)

Gregg Tartakow, DMD (Orthodontics)
& Ortho Tribune Associate Editor

AAO elects new officers

Dr. Lee W. Graber of Illinois takes over as president

The AAO House of Delegates met on April 30 and May 3 during the AAO Annual Session in Washington, D.C. Items of business included election of officers for 2010-11 and the installation of a new member of the board of trustees.

Officers are: Lee W. Graber, DDS, MS, PhD, of Vernon Hills, Ill. — president; Michael B. Rogers, DDS, of Augusta, Ga. — president-elect; and John F. Buzzatto, DMD, MDS, of Allison Park, Pa. — secretary-treasurer.

Buzzatto also represents the Great Lakes Association of Orthodontists on the board of trustees.

DeWayne B. McCamish, DDS, MS, of Chattanooga, Tenn., was installed as the new trustee on the board. He succeeds Rogers as the representative of the Southern Association of Orthodontists.

In addition to Graber, Rogers, Buzzatto and McCamish, the AAO Board of Trustees includes: Gayle Glenn, DDS, MSD, Southwestern Society of Orthodontists; Brent E. Larson, DDS, MS, Midwestern Society of Orthodontists; Nahid Maleki, DDS, MS, Middle Atlantic Society of Orthodontists; Hugh R. Phillis, DMD, Northeastern Society of Orthodontists; Morris N. Poole, DDS, Rocky Mountain Society of Orthodontists; and Robert E. Varner, DMD, Pacific Coast Society of Orthodontists.

Also on the AAO Board of Trustees are Robert James Bray, DDS, MS, of Somers Point, N.J., immediate past president; David L. Turpin, DDS, MSD, of Federal Way, Wash., editor in chief of the American Journal of Orthodontics and Dentofacial Orthopedics; Keith Levin, DMD, MS, of Winnipeg, Manitoba, speaker of the AAO House of Delegates; and Vincent G. Kokich Sr., DDS, MSD of Tacoma, Wash., editor-designate of the American Journal of Orthodontics and Dentofacial Orthopedics.

(Source: AAO)

Watch the ‘This Is Your Mouth’ video and help support NCOHF

By Fred Michmershuizen, Online Editor

“This Is Your Mouth,” a new video from Johnson & Johnson Healthcare Products that is narrated by Neil Patrick Harris, takes a closer look at the potential effects of rapidly multiplying bacteria in the mouth and illustrates how LISTERINE Antiseptic destroys the millions of germs that are left behind from brushing alone.

Each time the documentary is viewed, a \$1 donation will go from Johnson & Johnson to the National Children’s Oral Health Foundation: America’s Toothfairy.



A screenshot of www.listerine.com/yourmouth.

“I never realized how much goes on ‘behind the scenes’ in our mouths, and that brushing and flossing alone isn’t enough to keep germs at bay,” said Neil Patrick Har-

ris, announcing the new video.

In the video, which blends pop culture with science and a good dose of humor, dental professionals and scientists explain how bacteria multiply and collect in the mouth to form a thick layer called plaque biofilm, which is more harmful than free-flowing bacteria and may increase the potential for bad breath and gingivitis.

The video also depicts when LISTERINE Antiseptic was first formulated in 1879 and offers rare glimpses of retro advertisements.

The video may be viewed at www.listerine.com/yourmouth.

AD

Go beyond just treating malocclusion

Malocclusion

Poor oral habits

Soft tissue dysfunction

New techniques

Financial gain

Compliance

With the high demand from parents for early treatment, it is vital to arm yourself with the most cost effective treatment.

TAKE YOUR PRACTICE TO THE NEXT LEVEL

The majority of children from six years of age will show signs of malocclusion. In many cases, the underlying causes are never addressed. Just treating malocclusion with either a fixed or functional appliance does not address these problems.

Myofunctional Research Co. (MRC) has spent the last 20 years educating Doctors; teaching them how to go beyond the treatment goal of just straightening teeth. Myofunctional treatment with MRC’s appliances adds another dimension into dental and facial development.

Once educated, most parents and their children would prefer this approach - less braces, better facial development and a stable result without retainers.

MRC has a comprehensive range of myofunctional appliances, designed to treat the real causes of malocclusion. By attending an **MRC Educational Program**, you can learn how to effectively incorporate these appliances into your practice, delivering the best results for your patients, while maximising your financial gain.

NEW: MRC training facility now in Southern California.

MYOFUNCTIONAL RESEARCH CO.
www.myoresearch.com
a BETTER way

Information Ph 1866 550 4696
Web www.myoresearch.com

Training Attend an MRC Course
www.myoresearch.com/courses

1114 OTTB 06/10

← page 1

of anchorage/blocking (e.g., a ligature) must then be used.

In this case, the presence of the primary molars represented a contraindication for insertion on the vestibular side of the premolar region.

The paramedian insertion of two miniscrews has several advantages. Firstly, the miniscrews provide a very solid basis for anchorage of the distalization appliance.

Secondly, they will never impede the movement of the lateral teeth. Even after successful molar distalization, they can be used to stabilize the situation achieved for the remainder of the treatment.

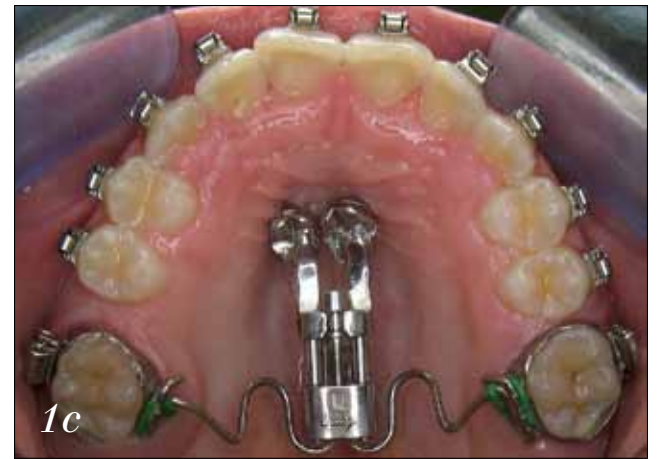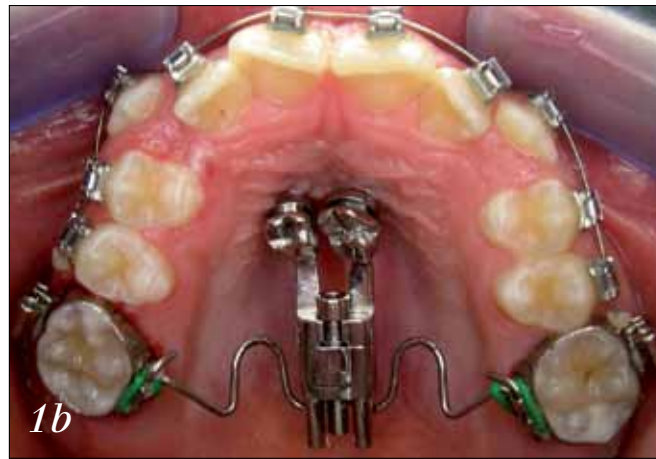Thirdly, there is no risk of damaging other teeth because of an unfavorable spatial situation and/or incorrect insertion.

One disadvantage of the coupling necessary between the Walde Frog Appliance used (FORESTADENT) and the miniscrews (see Figs. 1a-c) is that cleaning becomes difficult. As large areas of the mucous membrane are covered, there is the risk of the development of peri-mucositis. If this develops further into peri-implantitis, premature loss of the miniscrews could result.

A possible future alternative could be the use of "laboratory abutments" (Figs. 2a-d), which contain no plastics and can be used to couple the appliance with the miniscrews hygienically.

Mesialization

One of the most problematic areas of orthodontic therapy is

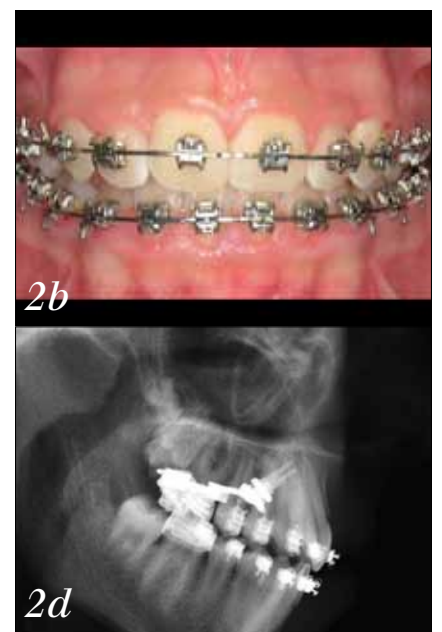
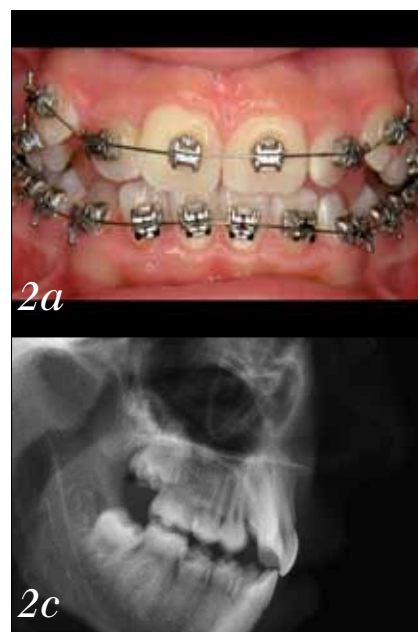
Figs. 1b, 1c: Walde Frog Appliance (FORESTADENT) anchored to two miniscrews (b). Distalization by approximately 6 mm after three months' treatment, providing sufficient space for the correct repositioning of the canines (c).

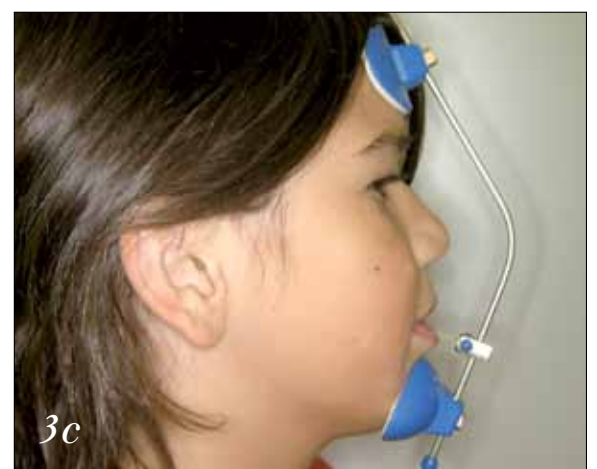
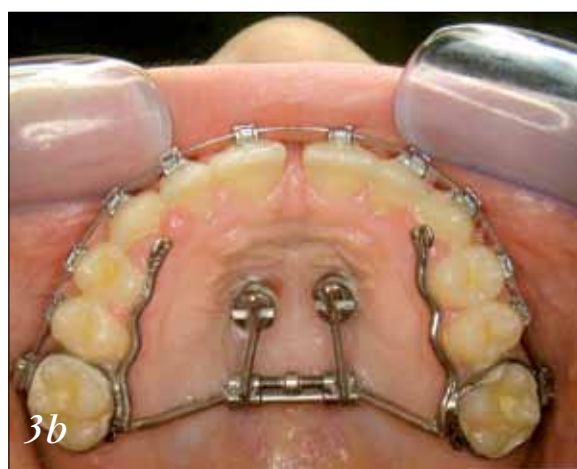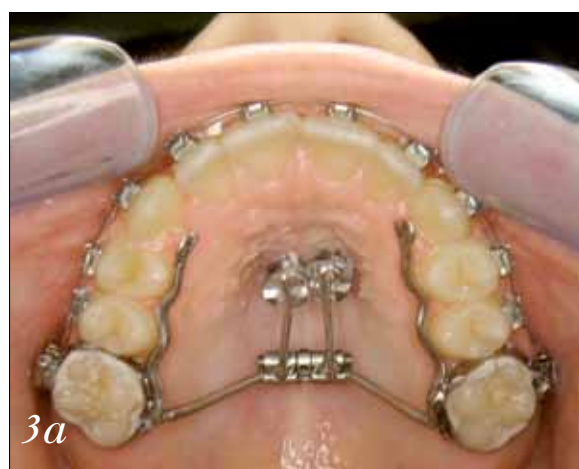the correction of the anterior displacement of teeth and particularly of jaw segments. It might seem that the availability of miniscrews means that conventional appliances no longer need to be used at all.

However, depending on the baseline situation and the nature of the required correction, the use of a combination of devices and appliances is recommended. This is often advisable and may even be necessary for biomechanical reasons, such as in a Class III situation.

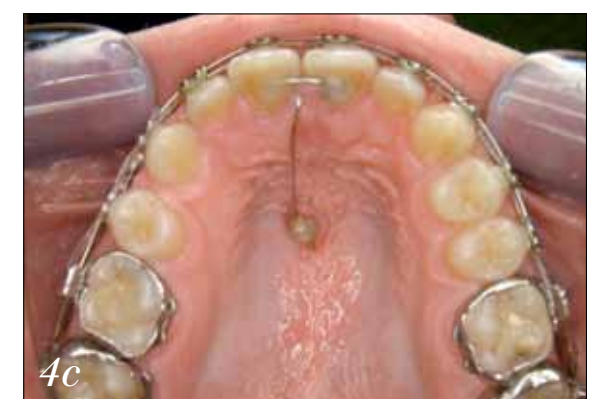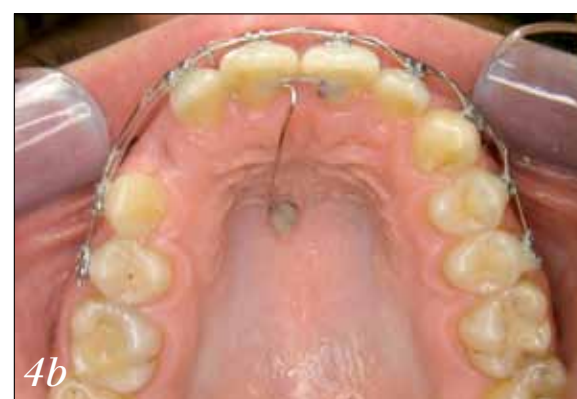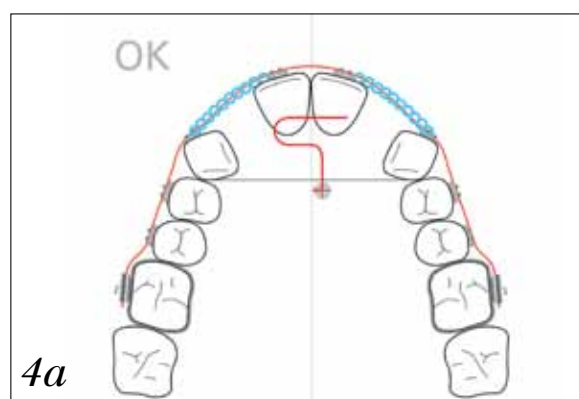
In the case shown in figures 3a-c, forced transverse expansion of the palatine suture was used in combination with mesial traction, applied by means of a Delaire facial mask. The support provided by two miniscrews inserted in the paramedian region redirected the forces of sagittal and transverse movements almost entirely onto the bones. Dental side effects were markedly reduced.



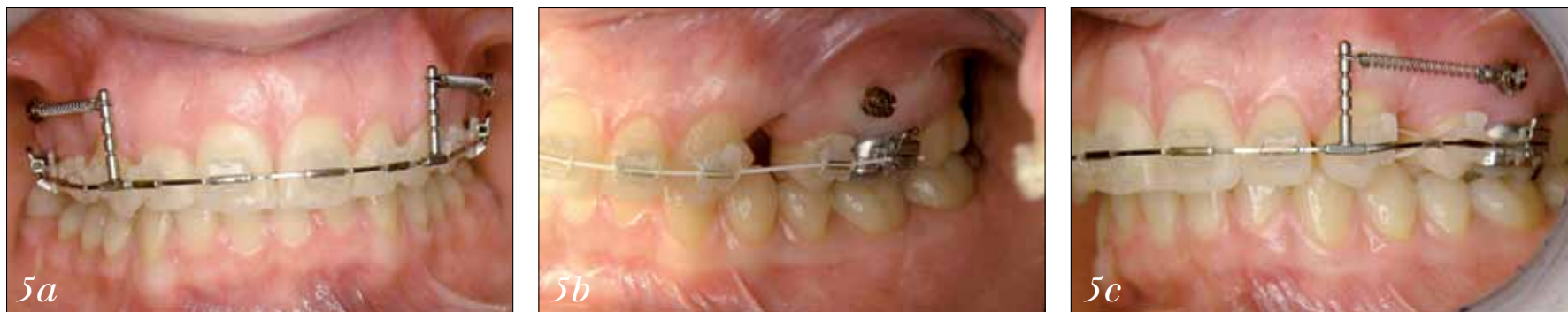Figs. 2a-d: Distalization of the upper laterals. Miniscrews were inserted in the paramedian region (OrthoEasy, FORESTADENT) (a). OrthoEasy with attached laboratory abutments (b). The Frog Appliance was lashed to the laboratory abutments (c). Lateral X-ray showing the ideal positioning of miniscrews, laboratory abutments and Frog Appliance (d).



Figs. 3a-c: Mesialization of the upper molars. Miniscrews inserted in the paramedian region with laboratory abutments (FORESTADENT) and transverse screw with hook for a Delaire facial mask (a). Status after transverse expansion and formation of a median diastema (b). Extra-oral view of the appliance with a Delaire mask (c).



Figs. 4a-c: Space closure in the region of the upper anterior teeth. Diagram showing the anchorage principle (a). Baseline situation: The central frontal teeth were held in place using a steel arch (19 x 25) fixed to a miniscrew with additional frontal dental torque (b). After nine months, the anchorage is stable (c).



Figs. 5a–c: Space closure in the region of the upper anterior teeth. *En masse* retraction with the aid of miniscrews and a Power Arm (FORESTADENT), which has been crimped here (a). Status after extraction of the premolars, showing OrthoEasy miniscrew (b). The Power Arm is used as a sliding mechanism, in order to distalize the canine further (c).

Space closure

Owing to the availability of miniscrews, new therapeutic techniques can now be used, particularly for the management of the partially edentulous situation that obviates the need for compensatory extractions and the problem of the loss of stability of the units used for anchorage support.

It is here the effect of Newton’s Third Law is particularly apparent, and the interception of the opposing forces is a major consideration within the therapeutic strategy. The orthopedic closure of dental spaces using miniscrews is highly recommended if:

- there are no alternative, viable conventional methods and/or there is insufficient certainty that these will be effective;
- the extensive use of braces is to be avoided for cosmetic or functional reasons;
- a short-term treatment or partial treatment is required that does not involve correction and realignment of the basic dental arch;
- asymmetrical treatments are associated with the risk of midline displacement and the possibility of compensatory extraction;
- or a suitable dental baseline situation is to be created for pre-prosthetic treatments.

It is important to note that in cases in which space closure treatment is proposed, it must be ensured the patient is aware of not only the costs and risks of the treatment, but also of the available alternative options, such as the use of bridges or implants.

There are three types of space closure.

- *Anterior space closure* (e.g., in displacement of the lateral incisors). Orthodontic space closure is frequently indicated if there is a gap in the anterior row of teeth, particularly in the region of the lateral incisors.

The undesirable effects of conventional therapeutic techniques are the displacement of the midline and/or negative inclination of the anterior teeth.

If miniscrews are used for the stabilization of the median incisors (Figs. 4a–c), such effects can be avoided. A stable, rigid steel arch with a size of at least 0.48 mm by 0.64 mm attached to two miniscrews inserted in the median or paramedian region can be used to

stabilize the anterior teeth.

Using the standard vestibular mechanical techniques, the gap can be closed without altering the position of the incisors.

- *En masse* or canine retraction (e.g., where the premolars are miss-

ing). Miniscrews can also be used as an aid in this form of treatment (Figs. 5a–c). In contrast with the conventional appliances, there is no loss of anchorage but rather a biomechanical benefit in terms of more favorable direction of forces.

If the miniscrew and the fitting for the active element (traction spring or elastic chain) are positioned at the same level as the resistance center of the canines, physical

→ OT page 6

AD

JOIN THE REVOLUTION!

EDGE

The future of successful practice management is here.

Get the revolutionary Edge™ to maximize your practice efficiency and profitability. Ortho2 brings you the latest in state-of-the-art management, imaging, and communications software that's supported by an industry-leading customer service team.

<p>Leading Edge Technology</p> <ul style="list-style-type: none"> • Web-enabled application with offsite data hosting option • Convenient drag-and-drop design • Customizable widget library • Next-generation imaging • PC, Mac, and multi-monitor support 	<p>Cutting Edge Efficiency</p> <ul style="list-style-type: none"> • Staff "roles" customize available features and views • Workflows auto-sequence tasks • Online patient forms and images • Flexible patient reminders • HR Manager tools 	<p>The Edge in Profitability</p> <ul style="list-style-type: none"> • Motivational Goal Tracker • Effective Collections Assistant • Powerful Smart Scheduler • Animations for case presentation • Multi-year graphs and trends
---	--	--

Join the revolution. Take your practice to the Edge today.
www.TheEdgeRevolution.com

800.678.4644 • www.ortho2.com

ORTHO2
Practice Complete Management.

Edge, Ortho2, Practice Complete Management, and the Ortho2 logo are trademarks of Ortho Computer Systems, Inc. ©2010 Ortho Computer Systems, Inc. All rights reserved.

← 01 page 5

movement of the tooth (or teeth) is possible.

- *Space closure in the molar region* (e.g., to avoid the need for prosthetic measures). Premature loss of the primary molars has not yet been eradicated despite all the advances made in prophylactic treatments. There may be a need for appropriate therapy, particularly in cases in which the adjacent teeth are not carious (Fig. 6a–c).

What should the patient be offered: implants, bridges or space closure treatment? With a view to the realistic long-term prognosis for the anchorage teeth, conservation of the surviving natural teeth and the minimization of the effects on the existing materials, a prosthetic solution would not appear to be appropriate.

The basic concept of restorative dentistry — first destroy, in order to reconstruct — is frequently not the best solution.

Let us assume that the strategy adopted is to mesialize tooth #27, in order to compensate — using a natural method — for the loss. The skeletal anchorage means that undesirable side effects, such as reciprocal space closure, are avoided. Only a few elements (brackets, springs, etc.) are needed to support the mesial movement.

The treatment remains invisible in comparison with the stated alternatives, it is very cost-effective and provides for a high level of conservation of the natural elements. The prognosis for the long-term preservation of the natural teeth is very good.

Vertical tooth displacement

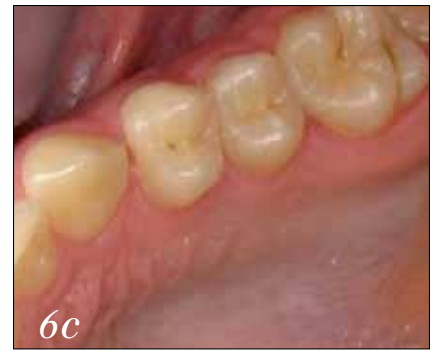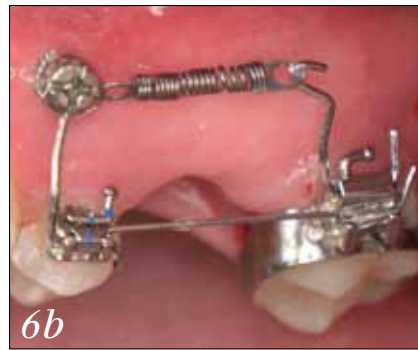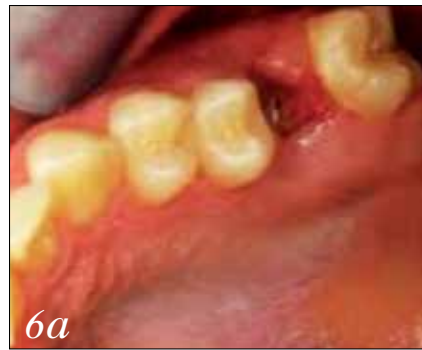Any displacement of the teeth along the vertical axis can present a cosmetic and/or functional problem. The solution is extrusion or intrusion using skeletal anchorage. This technique is very simple to implement and very cost-effective.

Extrusion

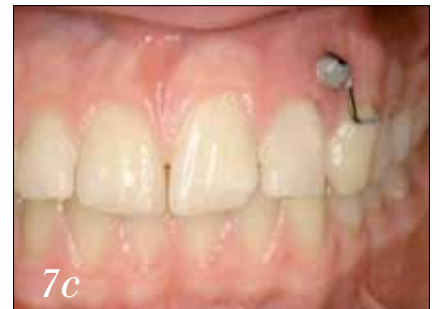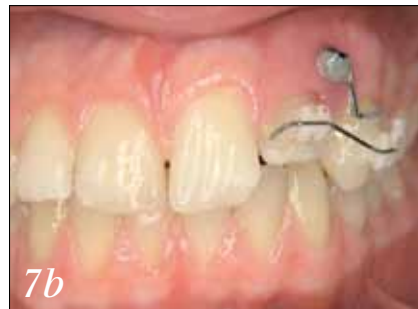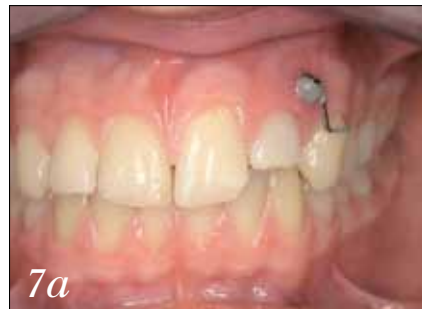Extrusion using miniscrews may be used for single teeth (Figs. 7a–c) and for groups of teeth (Figs. 8a, b). Trauma had caused the intrusion of tooth #22 (Figs. 7a–c). The tooth was returned to its original position within three months by means of the indirect anchorage of tooth #23 to a miniscrew using a straight wire appliance.

In the case of a bite that exposed tongue and bone (Figs. 8a, b), the approach adopted was to provide transverse expansion and extrusion of the anterior teeth. Intermaxillary rubber traction braces connected to miniscrews in the lower jaw were used.

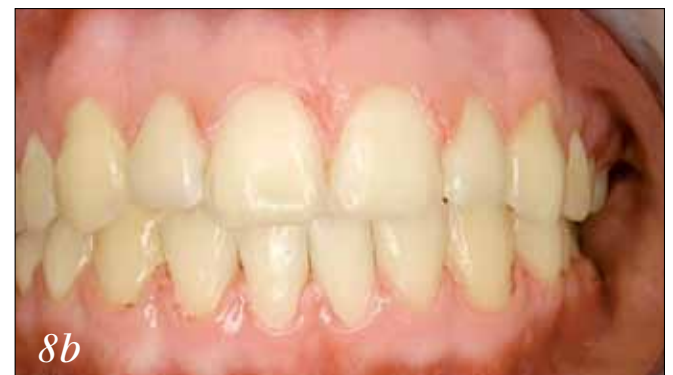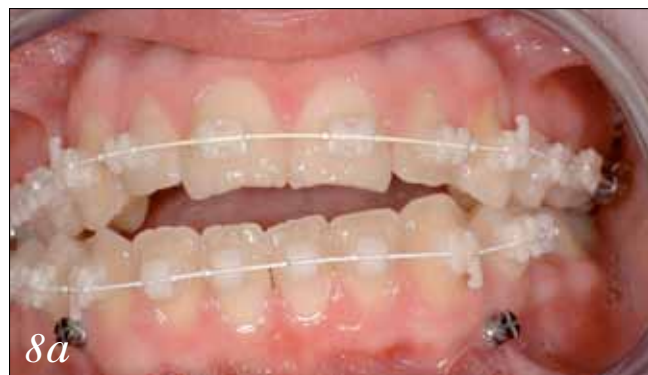If the braces had been connected to the lower anterior teeth, undesirable extrusion of these would have resulted (every action has an equal and opposite reaction). Because of the small root surface, this process would have occurred in a much



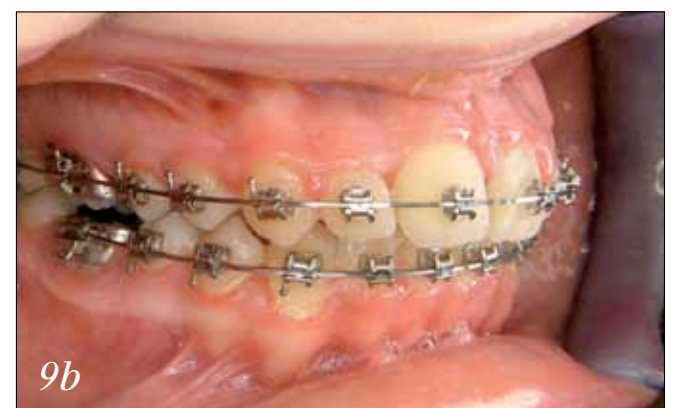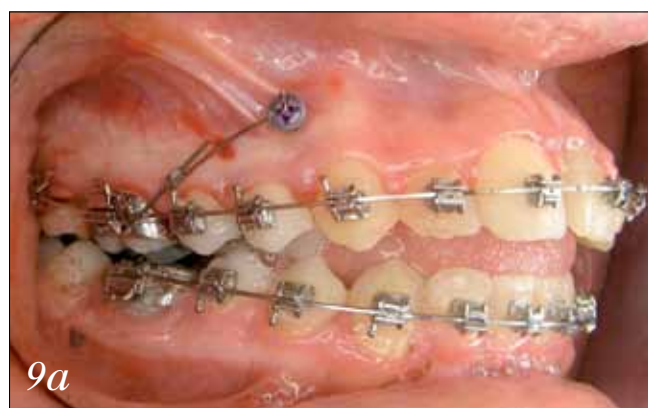Figs. 6a–c: Space closure in the region of the upper laterals. Baseline situation: Teeth #25 and #27 are free of caries (a). Using miniscrews (OrthoEasy, FORESTADENT), it is possible to provide ‘invisible’ treatment (b). Very few elements are required for mesialization (c).



Figs. 7a–c: Extrusion of a single tooth. Viable lateral incisor following intrusion due to trauma (a). Miniscrew with indirect anchorage of the canine and straight arch technique, in order to extrude tooth #22 (b). Status after three months (c).



Figs. 8a, b: Extrusion in order to close an open bite caused by tongue thrust, with deterioration of the upper jaw. The aim was to extrude the upper frontals over the miniscrew in the lower jaw (a). Status after 12 months (b).



Figs. 9a, b: Intrusion in order to close a tongue and skeletal open bite. Intrusion of the molars was effected using a Titanol Uprighting Spring (FORESTADENT) (a). Status after six months (b).

shorter space of time than in the case of the upper anterior teeth. The opposing bone in the lower jaw prevented this undesirable reactive effect.

Intrusion

This open bite with extrusion of the tongue (Figs. 9a, b) was treated by means of intrusion of the molars and consequent caudal rotation of the maxilla. Miniscrews were inserted in the first and second quadrants in each case between the canine and the first premolar.

A Titanol Uprighting Spring (FORESTADENT) was attached to the capstan of the miniscrew, and the screw was set to intrusion. There was even some over-

correction of the positioning of the first molars on both sides after five months’ intrusion, resulting in closure of the frontal bite.

Conclusions

It may be necessary for therapists to overcome logistical and emotional barriers before they can begin to employ miniscrews, but it is only when they are used that their versatility becomes apparent.

Miniscrews make our routine work that much simpler. They enhance the efficiency and effectiveness of many dental appliances, resulting in an overall improvement in treatment quality. 01

(Editorial note: A complete list

of references is available from the publisher. This article first appeared in *Dental Tribune Asia Pacific*, Vol. 7, No. 4, 2009. The next edition of *Ortho Tribune* will feature “Part IV — More clinical examples.” All photos were provided by the authors.)

OT About the author

Dr. Björn Ludwig
Am Bahnhof 54
56841 Traben-Trarbach
Germany
Phone: +49 (654) 181-8381
Fax: +49 (654) 181-8394
E-mail:
bludwig@kieferorthopaedie-mosel.de

“I have seen a remarkable transformation in my patients’ oral health with this program!”

—John Kelley, DDS, MS, Fort Worth, TX



Introducing...OrthoEssentials

The premier program specifically designed to inspire excellent oral hygiene among your patients throughout their treatment...*and beyond*



ortho :)
essentials
wire your world

To learn more about this exciting program, contact your **Crest Oral-B** representative, visit www.dentalcare.com/ortho, or call 1-800-543-2577.

Makeover: one system at a time

This is the second article in the Levin Group Total Ortho Success Practice Makeover series

By Jennifer Van Gramins and Cheri Bleyer

A practice transformation doesn't occur overnight. Instead, it's a series of small steps consistently implemented that yield huge gains in terms of efficiency, referrals and production, while reducing stress and increasing professional satisfaction.

In a few short months, Dr. Michelle Gonzalez and her team have made huge strides in streamlining practice operations, but they realize they still have a ways to go to reach their full practice potential.

"We've made some progress ... small changes can make a big difference. We are dedicated to making the practice the best it can be," said Gonzalez, the winner of the second Levin Group Total Ortho Success™ Practice Makeover.

The consulting experience

Earlier this year, we conducted the first phase of the yearlong consulting program — two days of teaching, breakout sessions and interactive learning, where we met Gonzalez and her experienced team, whose four full-time members are:

- Laurie, RDA
- Irene, RDA
- Mary, financial coordinator
- Kris, scheduling coordinator

Combined, they have 33 years working with Gonzalez, who started the practice in 1995.

"A strong team is a critical asset in moving the practice forward," said Dr. Roger P. Levin, chairman and CEO of Levin Group. "When your team 'buys in' to the consulting process, your practice is poised for extraordinary success."

During the two-day training, we focused on improved systems and processes in the following areas:

- Scheduling
- Practice communication
- Referral marketing

The schedule has the largest impact on daily operations. A more efficient schedule sets the stage for major practice improvements in the areas of customer service, team stress and morale, and scheduling capacity.

After redesigning their schedules, most practices can increase scheduling capacity, which allows the orthodontist to see more patients and increase production.

Practice communication keeps everyone on the same page. In a busy ortho practice, strong practice



Dr. Michelle Gonzales, clockwise from bottom left, and her team: Kris, Mary, Laurie and Irene. (Photo/Bruce Cook Photography, San Rafael, Calif.)

Levin Group Total Ortho Success™ Practice MAKEOVER

communication ensures everyone is working toward the same goals. Miscommunication has negative repercussions for customer service and team stress.

Referral marketing determines the practice's ability to grow. A structured referral marketing program generates a steady stream of referrals from referring dentists and patients, expands the number of referrers and leads to increased starts and production.

Gonzalez's practice had been growing for a number of years but had recently experienced a decline in the number of new patients being seen. Focusing on these three areas would put in the missing structure that would allow the practice to start growing again.

Change is under way

Gonzalez and her team have embraced the mantra of practice improvement. In scheduling patients, the practice is now using PowerScripting™ to direct patients to available slots. Previously, patients often would set their own appointments, which led to overbooking at times.

In addition, the practice is conducting time studies of its top procedures. This information will be used to devise a more accurate schedule. With the advent of new technologies, Levin Group recommends practices perform procedural time studies every two years.

The team implemented several changes that have resulted in improved communication and customer service. The front desk worked with Ortho II to better utilize the capabilities of its scheduling software. Using "the reason for visit" function has given clinical staff more information about visits by emergency patients.

In addition, the clinical staff is using a written routing slip to keep the front desk team better informed about the patient's next visit. Previously, the practice relied on verbal communication, which wasn't as effective.

Gonzalez hired LeAnn as a part-time practice coordinator (what Levin Group calls a professional relations coordinator, or PRC), a position that will handle the practice's referral marketing activities.

"Having a dedicated staff person will help us more consistently market our practice," Gonzalez said.

To celebrate its 15th anniversary, the practice will host an open house this summer for referring dentists and their teams. Strengthening relationships with referring dentists is key to maintaining practice growth.

Leading the practice

With the help of her team, Gonzalez is working to create the practice's mission and vision statements. These are two critical documents that set the tone and direction of the practice.

A vision statement is about looking ahead three to five years or even farther. A vision statement is not where you are today or even where you will be in the near future. Instead, it is focused on where the practice will be some years down the road.

The mission statement explains the purpose of the practice. While the vision statement is about where the practice will be in the future, the mission statement is focused on where the practice is today. Having and sharing them with the team are key stepping stones for the practice to achieve its goals.

Conclusion

Gonzalez and her team are on their way to making over the practice. Success starts by revamping current systems, which sets the foundation for greater success. Persistence is paying off for their team.

"We're excited about what we've accomplished, but we're even more excited by what we can still achieve," Gonzalez said.

To jumpstart your own Total Success Ortho Practice Makeover, come experience Dr. Roger Levin's next Total Ortho Success Seminar being held Oct. 28–29 in Orlando. Ortho Tribune readers are entitled to receive a 20 percent courtesy. To receive this courtesy, call (888) 973-0000 and mention "Ortho Tribune" or e-mail customerservice@levingroup.com with "Ortho Tribune Courtesy" in the subject line. [OT](#)

OT About the authors

Cheri Bleyer, Levin Group senior consultant

Bleyer joined Levin Group in 2003 as a Levin Group orthodontic management and marketing consultant. As a senior consultant, Bleyer has played a key role in the development of Levin Group's ever-expanding marketing program, and she regularly lectures at the Levin Advanced Learning Institute.

Jen Van Gramins, Levin Group consultant

Van Gramins has spent the last four years working as a Levin Group orthodontic management consultant. Prior to that, she managed medical and dental practices for 12 years. She served as practice manager for the Oral Health



Cheri Bleyer, left, and Jen Van Gramins

Clinic at Loyola University Medical Center in Maywood, Ill.

Visit Levin Group on the Web at www.levingrouportho.com. Levin Group also can be reached at (888) 973-0000 and customerservice@levingroup.com.



UNIVERSITY OF MINNESOTA DIVISION OF ORTHODONTICS

