

• implants

the international C.E. magazine of oral implantology

2²⁰¹³

_c.e. article

Implant site
preservation using
a novel post and crown

_events

ICOI Spring
Symposium set for
Las Vegas in May

_industry

Implant position
in the esthetic zone



Stay on top of new techniques, products with *implants*



Torsten Oemus
Publisher
Dental Tribune International

Thanks to rapidly advancing technology, the field of implant dentistry is always changing and evolving. Clinicians must be vigilant in their efforts to keep up with new techniques, new products and new technology that could affect treatment planning.

And that's what makes the publication you are holding right now so valuable.

For this issue of *implants*, we've assembled a collection of articles from a variety of respected names and companies in dentistry. These expert clinicians are sharing their first-hand knowledge and expertise with you. In this issue, you can read about implant site preservation, and you can also learn about blade implants. We also have news on implant events and technology.

But there's more.

Every issue of *implants* magazine also contains a C.E. component. By reading the set of three articles (beginning on Page 6) on "Implant site preservation using a novel post and crown" by Dr. Kalman, "Clinical and diagnostic advantages of PreXion 3-D imaging system" (page 10) by Dr. McEwen and "Blade implants in the treatment of thin ridges" (page 15) by Dr. Dal Carlo, and then taking short online quizzes on each article at www.DTStudyClub.com, you will gain one ADA CERP-certified C.E. credit.

Keep in mind that because *implants* is a quarterly magazine, you can actually chisel *at least* four C.E. credits per year out of your already busy life without any lost revenue and time away from your practice. To learn more about how you can take advantage of this C.E. opportunity, visit www.DTStudyClub.com. Annual subscribers to the magazine (\$50) need only register at the Dental Tribune Study Club website to access these C.E. materials free of charge. Non-subscribers may take the C.E. quiz after registering on the DT Study Club website and paying a nominal fee.

Finally, if you are interested in becoming a published author, we are always looking for experienced clinicians to write C.E. articles and offer their expertise to our readers. Contact Managing Editor Sierra Rendon at s.rendon@dental-tribune.com for more information on submitting an article.

I hope you enjoy this issue and that you get the most out of it.

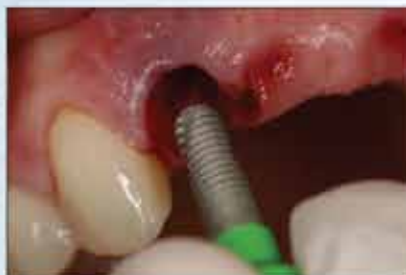Sincerely,

A handwritten signature in black ink, appearing to read 'Torsten Oemus'.

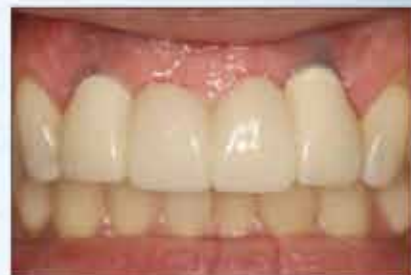Torsten Oemus
Publisher

Controlled tissue contouring for immediate loading including BioTemps® Provisionals

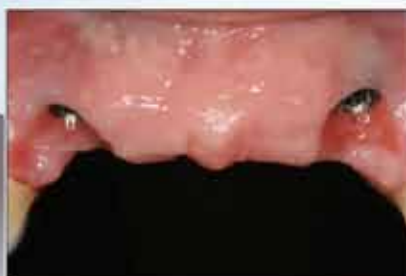INCLUSIVE® Tooth Replacement System



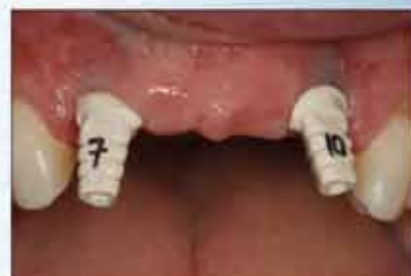A 3.7 mm X 11.5 mm Inclusive® Tapered Implant was placed in the surgical site for tooth #7, as well as tooth #10.



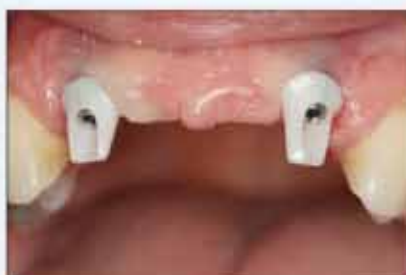The BioTemp bridge #7-10 was seated, allowing for nice tissue healing prior to the final impressions.



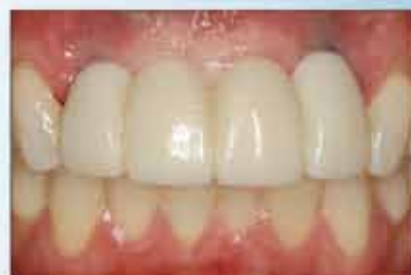After four months of integration, the BioTemp and patient-specific abutments were removed, revealing very healthy pink tissue with trained tissue contours.



The custom impression copings match the patient-specific soft tissue contours of the custom temporary components.



The final zirconia abutments were fabricated by the dental laboratory and torqued into place.



The final implant-retained bridge was cemented into place.

Clinical dentistry by Timothy F. Kosinski, DDS, MAGD

\$695* Single Tooth Replacement
(Case as shown: \$1,646*)

System includes: implant, drills, custom healing abutment, custom temporary abutment, BioTemps Provisional, custom impression coping, final custom abutment and ceramic crown.

The Inclusive Tooth Replacement System is a convenient and effective method of promoting and preserving the ideal tissue contours throughout the treatment process. It includes treatment options for these clinical situations:

- ◆ Immediate loading with custom temporary abutment and BioTemps® Provisional
- ◆ Single-stage implant placement with custom healing abutment

*Price does not include shipping or applicable taxes.

For more information

800-786-2177

www.inclusivedental.com

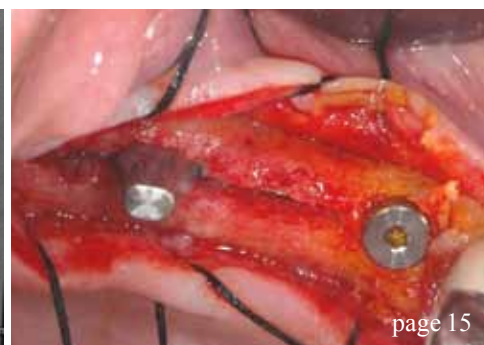
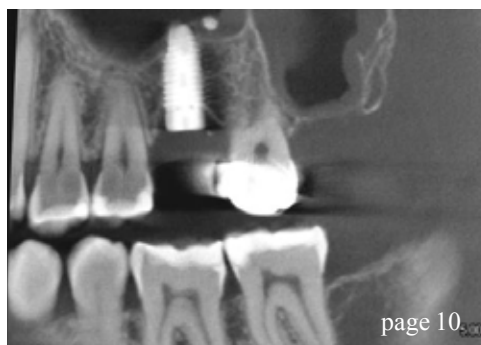
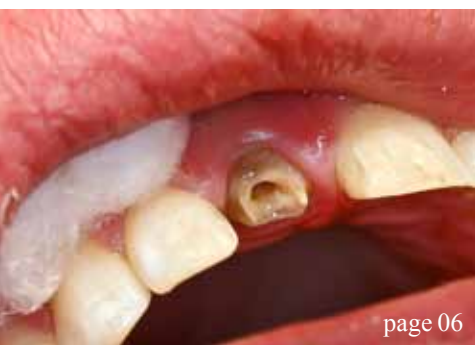
All Inclusive implants, abutments and components are manufactured in our Irvine, Calif., facility.



**GLIDEWELL
LABORATORIES**

Premium Products - Outstanding Value



| c.e. articles

- 06 Implant site preservation using a novel
post and crown
_Les Kalman, BSc (Hon), DDS
- 10 **Clinical and diagnostic advantages** of PreXion
3-D imaging system
_Dan McEowen, DDS
- 15 **Blade implants** in the treatment of thin ridges
_Luca Dal Carlo, DDS; Marco E. Pasqualini, DDS;
Michele Nardone, Medical Officer, Ministry of Health,
Rome, Italy; and Prof. Leonard I. Linkow, DDS

| events

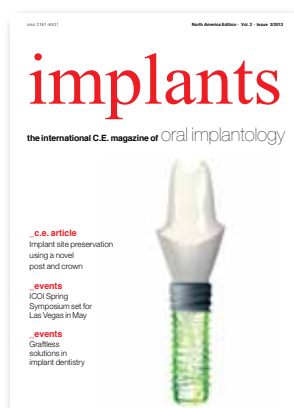- 22 **ICOI Spring Symposium** set for Las Vegas in
May
_Craig Johnson, ICOI Executive Director

| industry

- 26 DENTSPLY offers **SmartFix restorative**
solution
- 28 **Implant position** in the esthetic zone
_Siamak Abai, DDS, MMedSc
- 32 Introducing **Roxolid for All**
_Straumann staff

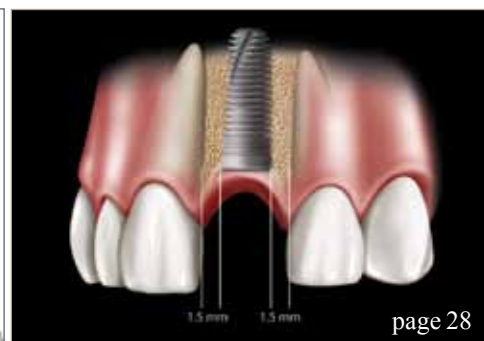
| about the publisher

- 33 _submissions
- 34 _imprint



| on the cover

*Cover image provided
by Straumann*



ATLANTIS™

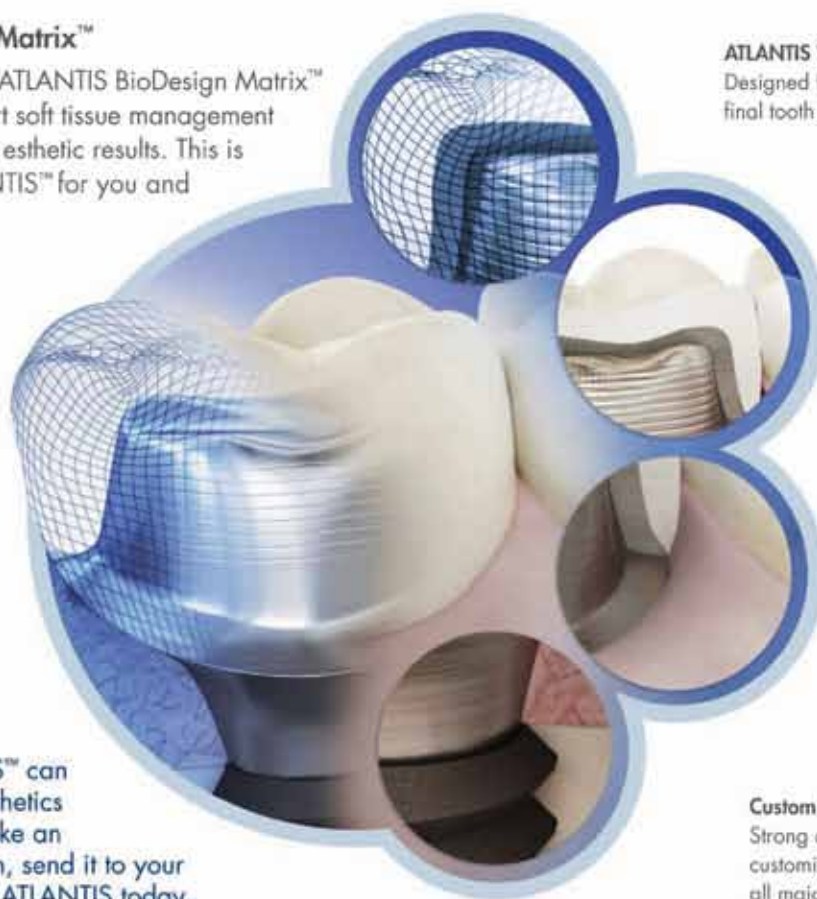Abutments as individual as your patients

Available for all major implant systems and in your choice of titanium, gold-shaded titanium and four shades of zirconia, ATLANTIS™ patient-specific

CAD/CAM abutments help to eliminate the need for inventory management of stock components and simplify the restorative procedure.

ATLANTIS BioDesign Matrix™

The four features of the ATLANTIS BioDesign Matrix™ work together to support soft tissue management for ideal functional and esthetic results. This is the true value of ATLANTIS™ for you and your patients.



ATLANTIS VAD™

Designed from the final tooth shape.

Natural Shape™

Shape and emergence profile based on individual patient anatomy.

Soft-tissue Adapt™

Optimal support for soft tissue sculpturing and adaptation to the finished crown.

Find out how ATLANTIS™ can bring simplicity and esthetics to your practice. Just take an implant-level impression, send it to your laboratory and ask for ATLANTIS today.

Custom Connect™

Strong and stable fit – customized connection for all major implant systems.

DENTSPLY
IMPLANTS

800-531-3481 • www.dentsplyimplants.com

Implant site preservation using a novel post and crown

Author _Les Kalman, BSc (Hon), DDS

_c.e. credit part I

This article qualifies for C.E. credit. To take the C.E. quiz, log on to www.dtstudyclub.com. Subscribers to the magazine may take this quiz for free and will be emailed an access code after the magazine's release. If you do not receive the code, please write to support@dtstudyclub.com. Non-subscribers may take the quiz for \$20. You can access the quiz by using the QR code below.



_Abstract

Implant site preservation is an important component of diagnosis and treatment planning. Through CAD (computer aided design), prosthesis can be designed with ideal characteristics. By utilizing CAM (computer aided manufacturing), the clinician has the ability to mill the designed prosthesis with great accuracy.

IPS e.max has been selected as the material for this investigation due to strength and esthetics. The combination of IPS e.max and in-office CAD/CAM technology allows the clinician the ability to create an esthetic and predictable moderate-term provisional to preserve a site for future implant placement.

_Introduction

Implant placement in the esthetic zone is the ideal treatment option when diagnostic criteria are

satisfied.¹ Finances, however, can act as a barrier to treatment. A moderate-term, esthetic provisional would allow the patient the opportunity to overcome barriers. In-office CAD/CAM technology would allow for immediate prosthesis fabrication.

CAD/CAM stands for computer-aided design and computer-aided manufacturing, respectively. CAD allows the clinician to digitally capture an image of a preparation and then design an indirect (out of the mouth) restoration by using software.²

After the ideal restoration has been produced, the design is then fabricated out of a material by a milling machine. E4D is an in-office dental unit (D4D Technologies). IPS e.max is a metal-free, esthetic dental material used in indirect restorations. IPS e.max is composed of lithium disilicate, and its ideal physical and esthetic properties allow it to be the first choice for CAD/CAM restorations.³ IPS e.max has the ability of detailed CAM production and has strength second only to gold.³

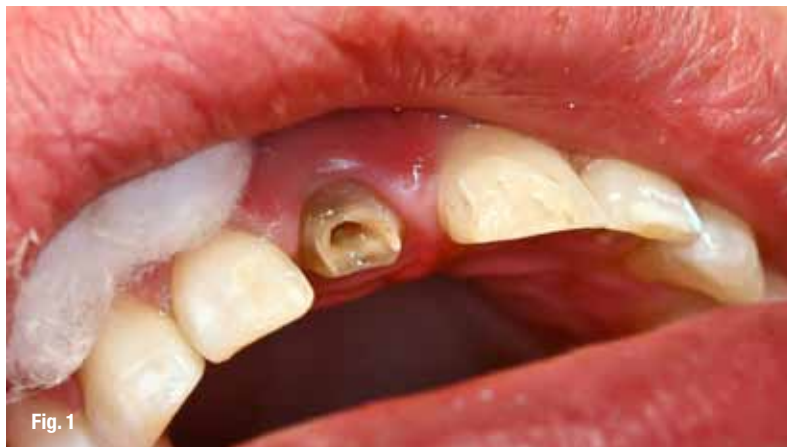

Fig. 1 Preparation of tooth #11.
(Photos/Provided by Dr. Les Kalman)

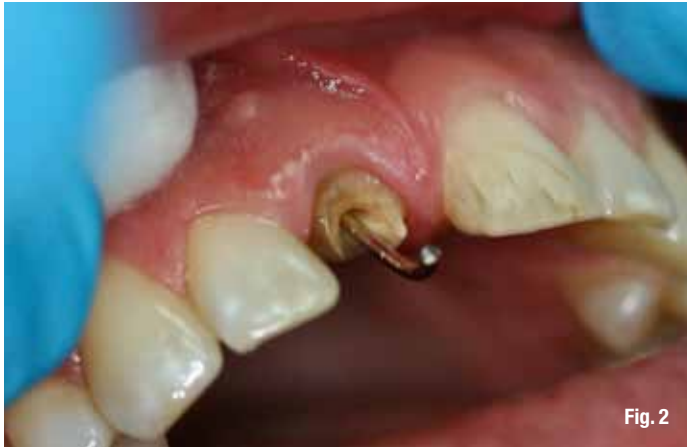

Fig. 2

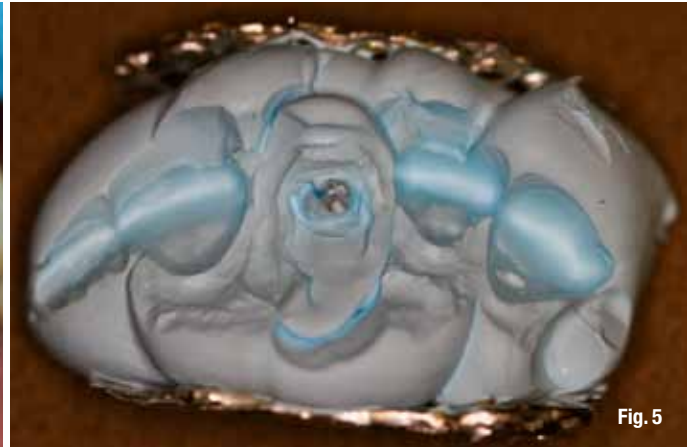

Fig. 5



Fig. 3

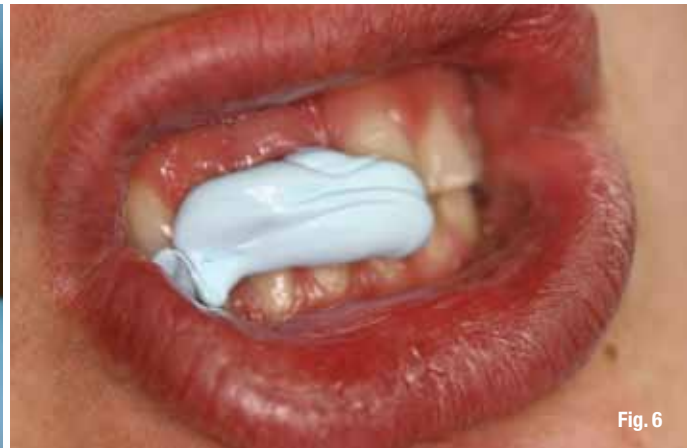

Fig. 6

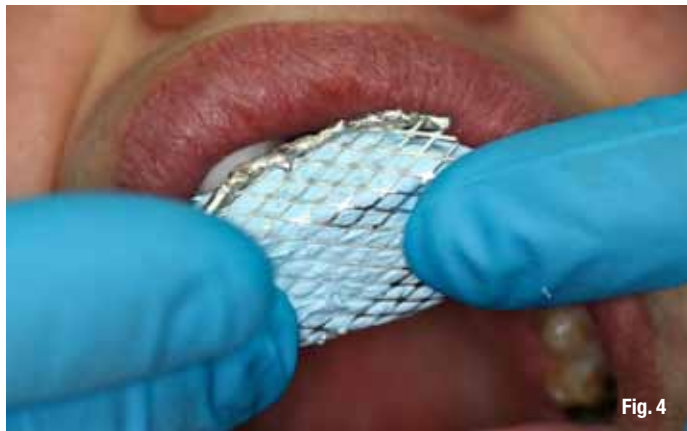

Fig. 4

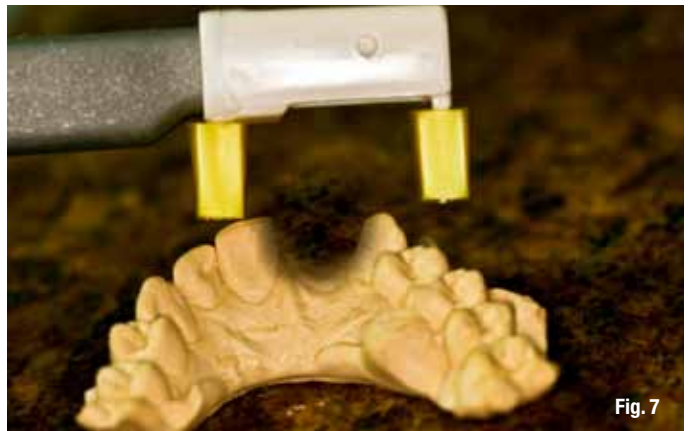

Fig. 7

Clinical case

Presentation

A 28-year-old male patient presented with a failed post and core and porcelain fused to metal (PFM) crown. His chief complaint was that the 'fake tooth' has become dislodged several times and he requested a long-term solution.

Medical history was non-contributory. Clinical and radiographic examination indicated an endodontically treated central incisor with no apical pathology and a failed post and core/crown restoration. The PFM crown was still cemented to the post

and core and lacked a ferrule effect. The post and core/crown had been re-cemented several times in the past.

Diagnosis indicated: endodontic treatment, failed post and core and caries on tooth number #11. Treatment options to replace the missing tooth included: an implant supported crown, a bridge, a removable partial denture and no treatment.

The patient had interest in the implant option but requested that the old unit be re-cemented. He had several professional and personal obligations that required an esthetic provisional. Finances were a limiting factor. The existing post and core/crown

Fig. 2 Use of paper clip.

Fig. 3 Q-tray loaded with VPS material.

Fig. 4 Segmental Q-tray impression.

Fig. 5 Detail of Q-tray impression.

Fig. 6 Bite registration for CAD/CAM prosthesis.

Fig. 7 Digitization of preparation with E4D camera.

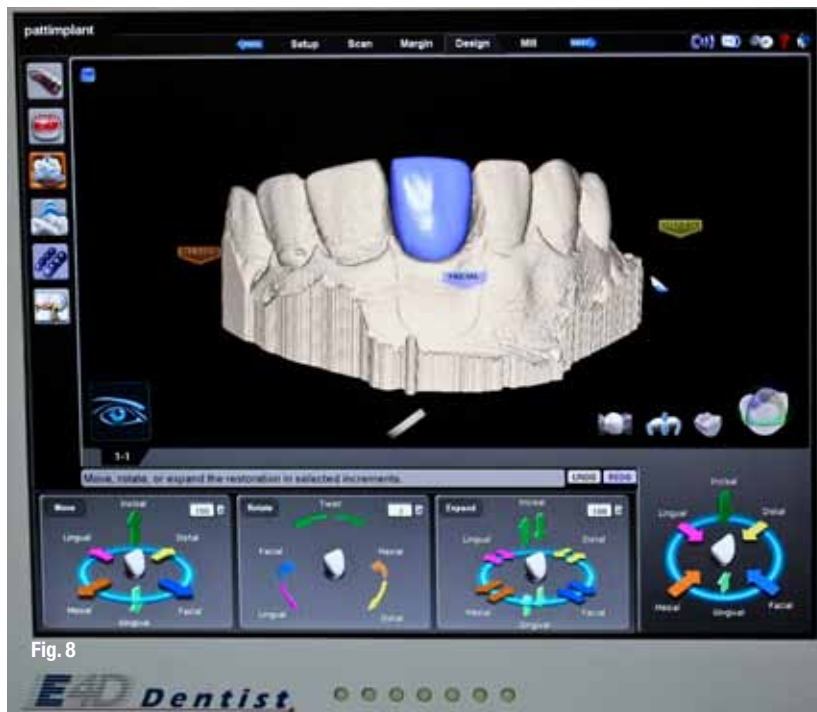


Fig. 8



Fig. 9



Fig. 10




Fig. 11

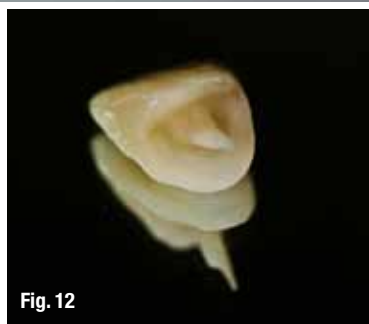

Fig. 12

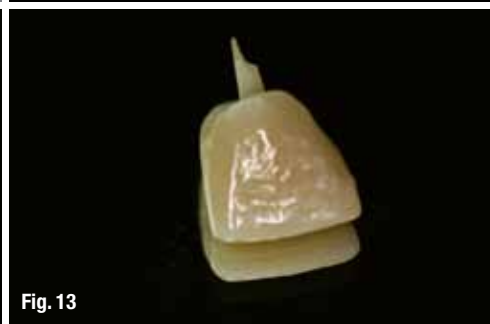

Fig. 13

Fig. 8_Digitized delineation of prosthesis.

Fig. 9_IPS e.max block for milling of prosthesis.

Fig. 10_E4D CAD/CAM milling unit.

Fig. 11_Prosthesis fired in furnace.

Fig. 12_Post-crown IPS e.max prosthesis.

Fig. 13_Post-crown prosthesis-facial view.

was deemed poor and could not be used. Based on the situation, an alternative option was presented to the patient: an indirect IPS e.max CAD/CAM post and core/crown moderate-term provisional that would be fabricated using an in-office E4D unit. Treatment-specific informed consent was given, and the patient agreed. It was decided to generate an indirect CAD/CAM prosthesis due to the investigative nature of the clinical case.

Preparation

Tooth # 11: the canal space was cleaned of cement and the remaining tooth structure was prepared as per full porcelain coverage specifications (Fig. 1). A paper clip was inserted into the canal space (Fig. 2).

A final PVS impression (Ivoclar) was taken, utilizing a Q-Trays (Research Driven) segmental tray (Figs. 3–5). A bite registration was taken for the CAD/CAM scan (Fig. 6). The patient was dismissed to the waiting room while the prosthesis was fabricated.

Indirect CAD/CAM component

The impression was poured with stone and then

digitized by taking several scans of the area with the E4D scanner (Fig. 7). Utilizing CAD technology, the prosthesis was delineated. The CAD software then presented a rudimentary prosthesis based on the parameters selected. Material thickness was then evaluated.

The prosthetic design was further manipulated using the provided software tools until an acceptable result was achieved (Fig. 8).

The CAD design was executed on an IPS e.max block (Fig. 9) utilizing CAM technology (Fig. 10). The prosthesis was removed from the block and assessed for morphology and fit on the cast.

The prosthesis was then stained and glazed (Fig. 11) and fired in the furnace. After firing, the color of IPS e.max changes from purple to tooth colored (Figs. 12 and 13).

The patient returned for prosthetic delivery. The post and crown prosthesis underwent intraoral assessment (Fig. 14). The patient approved the esthetics. The prosthesis was cemented with Multilink (Ivoclar); occlusion was refined and the restoration was cleaned and polished (Fig. 15).

Discussion

This report represented a clinical investigation; as IPS e.max blocks supplied for in-office CAD/CAM dentistry have not been recommended for posts or post and core/crown combinations. This was due to the fact that block application for posts has been unexplored and that the strength of IPS e.max for posts had yet to be determined.

The CAD software was quite limited and did not have the capability to generate an intra-canal projection. The optical scanner also had limitations, as the angle of acquisition had to be manipulated to acquire digitized data. Finally, the CAM unit's ability to generate a complex crown unit with a canal projection (post) had yet to be determined.

Several factors were evident that allowed for the completion of this case. The patient requested a "temporary," highly esthetic procedure until financials permitted the ideal treatment. The inability to use his existing restoration opened up the opportunity for this investigative trial.

The patient's occlusion exhibited mild overlap and overjet; therefore, occlusal forces would be minimized. The patient was committed to wearing his occlusal appliance. That the adjacent teeth had no other restorations present reinforced the necessity for minimally invasive dentistry.

Conclusions

CAD/CAM technology has been harnessed utilizing IPS e.max to provide for an investigative moderate-term, predictable and esthetic anterior provisional. Further studies are required to: quantify the strength of IPS e.max, assess its role as an intra-canal projection (post) and develop the technology for CAD/CAM procedures.

The potential seems to exist for IPS e.max to act as a predictable, moderate-term and esthetic canal-retained prosthesis. This novel approach will enable site preservation and optimize clinical condition for future implant placement.

Disclosure: Dr. Les Kalman is the co-owner of Research Driven and the developer of the Q-Tray.

References

1. Martin, W.C., Morton, D. and Buser, D. Pre-operative analysis and prosthetic treatment planning in esthetic implant dentistry. In Buser, D., Belser, U. and Wismeijer, D. editors: Implant Therapy In The Esthetic Zone-Single Tooth Replacements (Volume 1) p11–19, Berlin, 2007, Quintessence.
2. Berlin, M. Wowing The Patient With Chairside CAD/

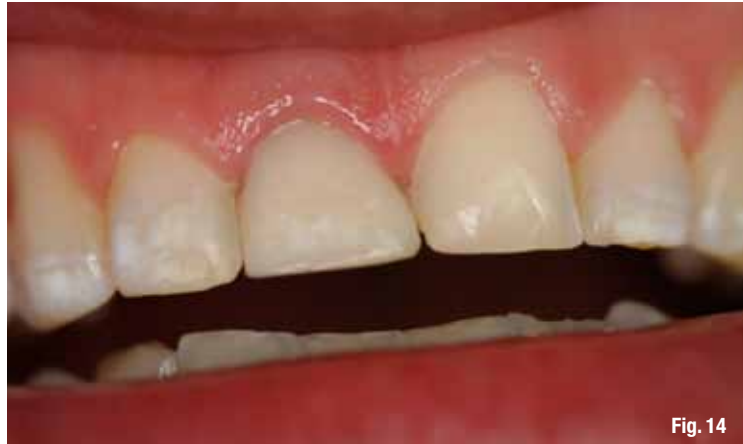

Fig. 14

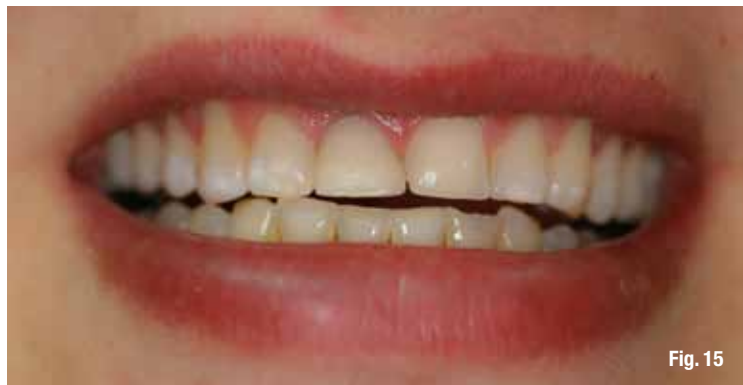

Fig. 15

CAM. Dental Economics: 2008;98(4):92–96.

3. Ivoclar Vivadent: IPS e.max lithium disilicate – The Future of All-Ceramic Dentistry. 2009; 1–15.
4. Kalman, L. Prosthodontic Impressions Simplified: The Rebite Technique. Oral Health 2006; 96(11): 29–36.

Fig. 14_Prosthesis try-in.

Fig. 15_After: final cemented prosthesis.

_about the author



Les Kalman, BSc (hon), DDS, has served as the chief of dentistry at the Strathroy-Middlesex General Hospital. In 2011, he transitioned to full-time academics as an assistant professor at the Schulich School of Medicine and Dentistry. Kalman is also

the coordinator of the Dental Outreach Community Services (DOCS) program, which provides free dentistry within the community. Contact him at:

Assistant Professor of Restorative Dentistry
Schulich School of Medicine & Dentistry
The University of Western Ontario
London, ON N6A 5C1
Canada
(519) 661-2111, ext. 86097
lkalman@uwo.ca