

# roots



the international C.E. magazine of endodontics

3<sup>2012</sup>

**\_C.E. article**

Invasive cervical  
resorption

**\_trends**

Laser-assisted  
endodontics

**\_interview**

Redefining endodontic  
education

# One tough foam...



## Introducing e-Foam Rotary HD

Our new **e-Foam® Rotary HD** inserts are specially designed for cleaning rotary instruments.

A rotating file secured in a hand piece can be placed directly into the high density foam to assist in cleaning debris from rotary flutes. Our Rotary HD foam minimizes tearing or shearing of the foam while a file is in motion.

Precisely engineered to fit Jordco's Endoring II organizer.

**Jordco e-Foam Rotary HD, endodontic foam inserts,**

REF: ERFBHD-s (48 high density blue inserts)

Joins the file lubricant designed to reduce waste.



**EndoGel®** endodontic lubricant contains EDTA and is formulated to aide in the negotiation of root canals by endodontic instruments. EndoGel endodontic lubricant is the perfect companion to the Endoring® II's Gelwell system.

Each single-use 1ml MicroDose® tube has a long-necked design makes dispensing easy. The Endoring® II, e-Foam® Rotary HD, EndoGel®—the trifecta in improving efficiency and patient safety.

**EndoGel, file lubricating gel,**

REF: EG-s (12 tubes); EG-24 (288 tubes)



Manufactured by Jordco, Inc. USA • [www.jordco.com](http://www.jordco.com) • TEL 800-752-2812 • FAX 503-531-3757

QUALITY DENTAL PRODUCTS MANUFACTURED IN THE U.S.A.

To order, please contact your dental supply dealer. Or visit us @ [www.jordco.com](http://www.jordco.com) or call **800-752-2812**

To view a video on Jordco's new e-Foam Rotary HD point your smartphone here:



# Fall means back to school



Fred Weinstein, DMD, MRCD(C),  
FICD, FACD

The leaves are starting to come down, and that means it's back-to-school time for our children, grandchildren, nieces, nephews and all the other young people in our lives. Even for those of us whose school days are long past (like me!), fall is a time of year that probably brings back memories of what it was like to have new teachers, fresh textbooks, brand-new pencils with unused erasers – and, most important of all, ever-expanding academic horizons.

Of course, no matter how far in the past one's school days might be, nobody's education is ever complete. That's why the magazine you are holding in your hands is so valuable. This is a C.E. magazine, and by reading the article on invasive cervical resorption by John Stropko, DDS, beginning on Page 6, then taking a short online quiz about this article at [www.DTStudyClub.com](http://www.DTStudyClub.com), you will gain one ADA CERP-certified credit. Remember that because *roots* is a quarterly magazine, you can actually chisel four C.E. credits per year out of your already busy life without any lost revenue or time away from your practice.

To learn more about how you can take advantage of this C.E. opportunity, visit [www.DTStudyClub.com](http://www.DTStudyClub.com). Annual subscribers to the magazine (\$50) need only register at the Dental Tribune Study Club website to access these C.E. materials free of charge. Non-subscribers may take the C.E. quiz after registering on the DT Study Club website and paying a nominal fee.

Also presented within the pages of this publication, you will find a report on laser-assisted endodontics by Steven R. Polhaus, DDS, FAGD; and an account of apical resection by Prof. Marcel Wainwright, DMD, plus many other articles.

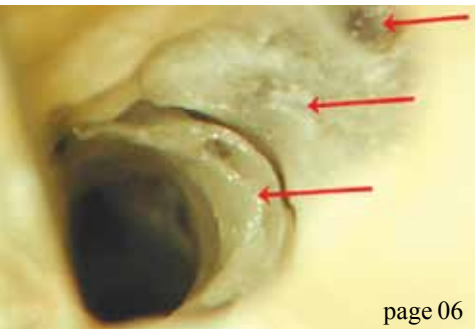
I hope that you will take advantage of the C.E. opportunity in this issue of *roots*, and that you will also benefit from clinical expertise being shared in the other articles as well.

For those of you who will be attending the American Dental Association meeting this October in San Francisco, I look forward to seeing you in person. If you will not be at the meeting, please do not hesitate to get in touch via email with your feedback and ideas. I can be contacted at [f.weinstein@dental-tribune.com](mailto:f.weinstein@dental-tribune.com).

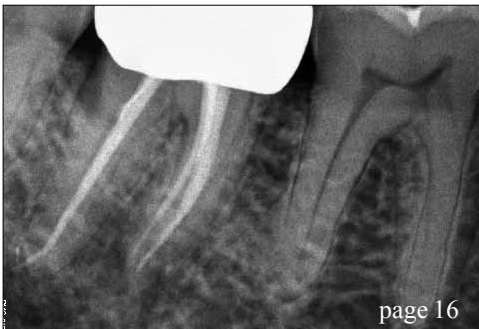Until then, I wish you the very best.

Sincerely,

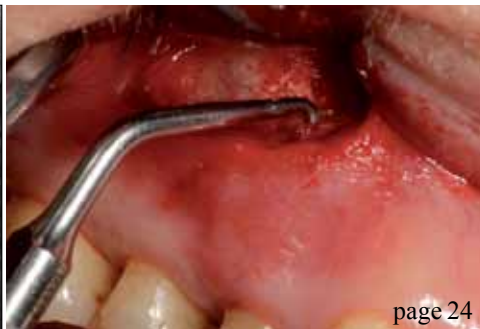Fred Weinstein, DMD, MRCD(C), FICD, FACD  
Editor in Chief



page 06



page 16



page 24

**C.E. article**

06 **Invasive cervical resorption:** A description, diagnosis and discussion of optional management — a review of four long-term cases  
\_John Stropko, DDS

38 Wykle Research and Nordiska Dental offer **Calasept Endo** line

40 **Stropko Irrigator** removes debris, making many procedures easier

**trends**

16 **Laser-assisted endodontics** in general practice, or: How I learned to stop worrying and love root canals  
\_Steven R. Pohlhaus, DDS, FAGD

**about the publisher**

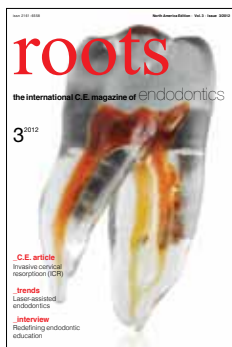
41 \_submissions

42 \_imprint

20 Well-thought-out simplicity leads to **superior obturation**  
\_Barry Lee Musikant, DMD

**case report**

24 Efficient and ergonomic **apical resection** using the Kaiserwerth algorithm  
\_Prof. Marcel Wainwright, DMD



**interview**

30 Redefining **endodontic education**  
\_Fred Michmershuizen, Managing Editor

**on the cover**

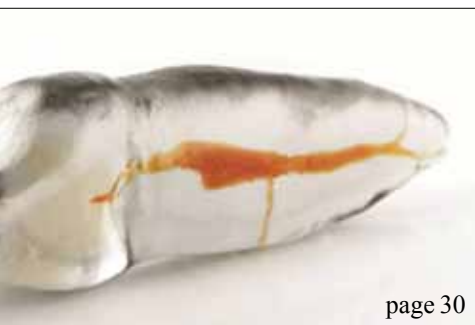*The image is of a TrueTooth™ training replica. Designed by L. Stephen Buchanan, DDS, FICD, FACD, and re-created by a 3-D printer, these are authentic replicas of the internal and external anatomy of CT-scanned extracted teeth, with bleach-dissolvable material in the root canal passageways. TrueTooth training replicas are available exclusively from www.DEEndo.com and are patent pending.*

**meetings**

34 **Microscopic dentistry** is focus of AMED event

**industry**

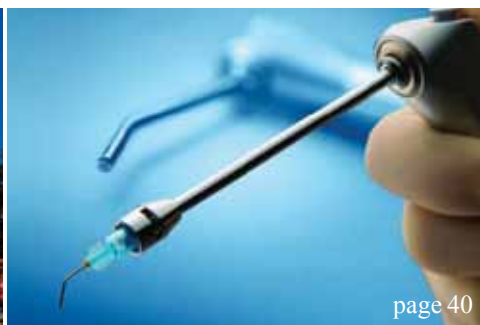36 The **Jordco** System



page 30



page 34



page 40

Technology **4** Medicine™

# LIGHTWALKER

Dual Wavelength, Er:YAG & Nd:YAG

The 2 leading **LASERS**, 1 superior package. Invest Less. **Do More.**



**Best of Class**  
Pride Institute

**"red dot" Design Award 2012**  
Superior Design & Technology



red**dot**



**Dentistry Today's**  
Top 100 Products

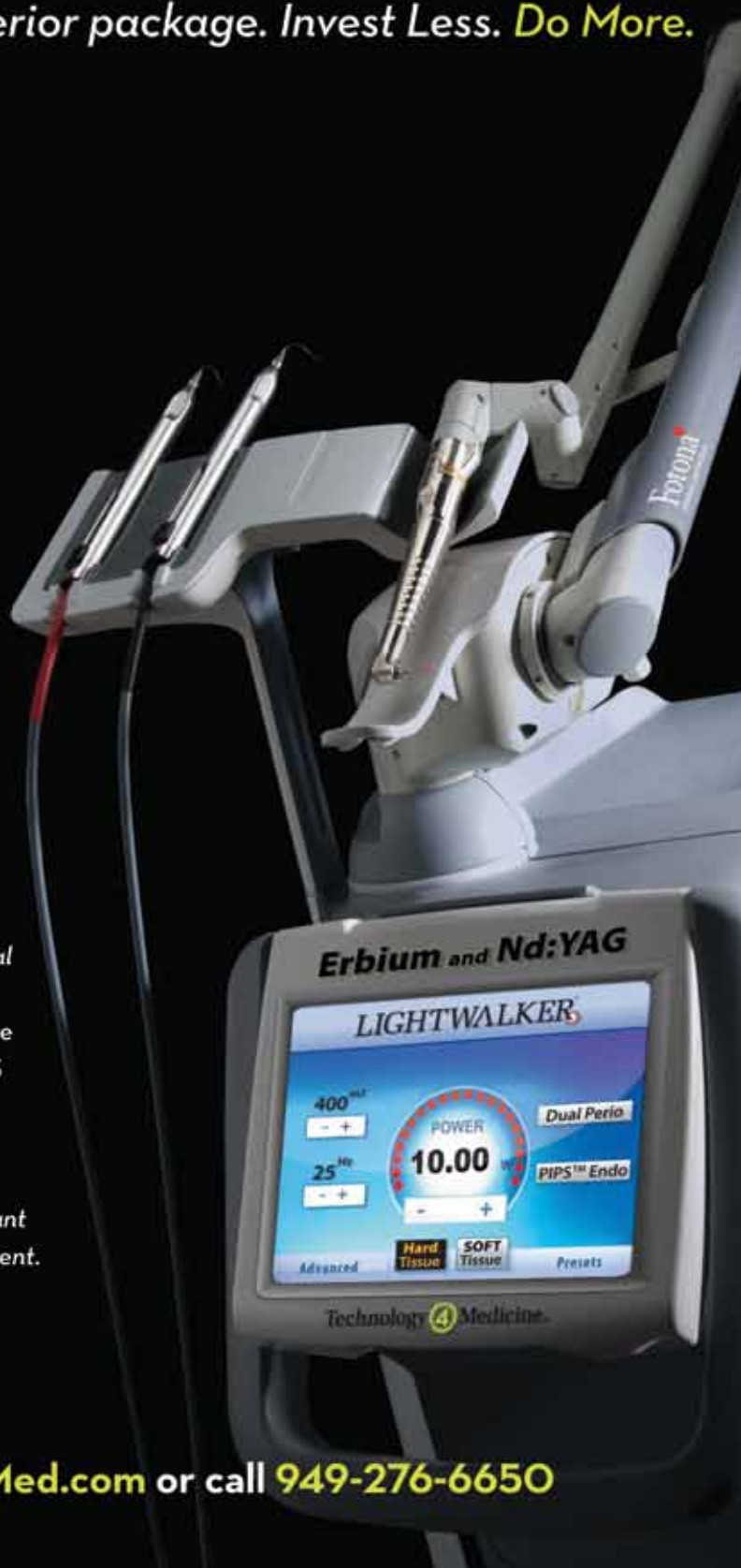## PIPS™ - Photon Induced Photoacoustic Streaming™

A Dramatic Breakthrough in Endodontics  
Available Exclusively with the Lightwalker

*"I have been using PIPS for over a year on most of my cases. Herb Schilder stated that endodontic cases had the potential of 100% success minus X. The X factor being the complexity of the root canal system and the operator's ability to manage the cleansing and shaping of that system. I believe that PIPS enhances my ability to reduce this X factor to as close to 0 as is possible today. The Dual Wavelength LightWalker has also proven to be very valuable to my implant cases. Having both the Er:YAG and the Nd:YAG in one system is an important advancement which allows you to get more for your investment. I recommend this product without reservations."*

Bryan M. Beebe D.D.S.  
Endodontist, Sarasota, FL

For More Information, visit [www.T4Med.com](http://www.T4Med.com) or call **949-276-6650**



# Invasive cervical resorption: A description, diagnosis and discussion of optional management — a review of four long-term cases

author\_John J. Stropko, DDS

**\_c.e. credit**

This article qualifies for C.E. credit. To take the C.E. quiz, log on to [www.dtstudyclub.com](http://www.dtstudyclub.com). The quiz will be available on Oct. 1, 2012.

## \_Abstract

**The external resorptive process of the permanent dentition referred to in this article has been labeled several different names over the years;** therefore, some confusion exists. Just a few popular labels are: extra canal invasive resorption (ECIR), invasive cervical resorption (ICR), external cervical resorption (ECR), subepithelial external root resorption, idiopathic external resorption, etc. They all refer to a relatively uncommon form of dental resorption.

If left undiagnosed, misdiagnosed, mistreated or untreated, it will usually be quite devastating for a tooth. Australian dentist Geoffrey Heithersay has contributed much to the literature regarding all facets of this type of dental resorption. His work has become

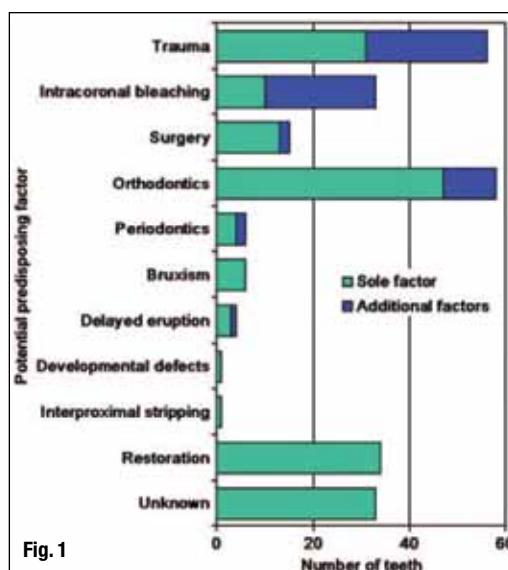
the basis of research and treatment. With few changes over the past several years, the etiology, predisposing factors, classification, clinical and radiologic features, histopathology and the treatment of this resorptive process he described are still used without much change in our practice today.<sup>1-4,6</sup> In respect, this article will use the same nomenclature appearing in his numerous publications: invasive cervical resorption (ICR).

The author will present treatment of four cases — two class 2 cases, one class 3 and a class 4 — in an attempt to share some experiences, both good and bad, accumulated over the years when dealing with ICR. Hopefully this article will be successful in removing some barriers that may currently prevent the dentist from taking on the challenge presented by the next case of ICR.

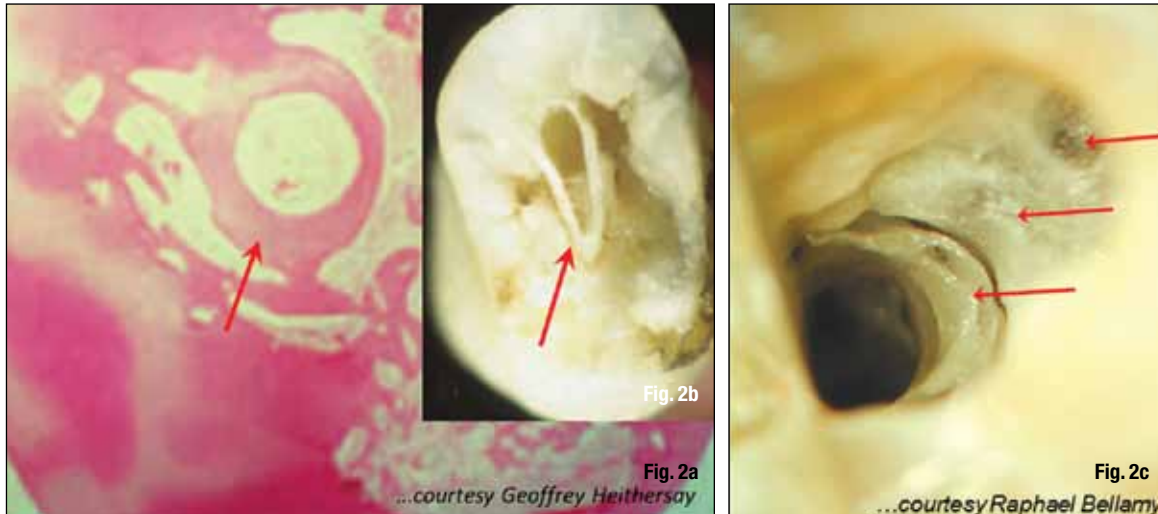
## \_Etiology of invasive cervical resorption

Not a common occurrence, ICR is an insidious and often aggressive form of external tooth resorption and can occur in any tooth in the permanent dentition.<sup>4</sup> External resorption can be divided into three broad groups: 1) trauma-induced tooth resorption; 2) infection-induced tooth resorption; and 3) hyperplastic invasive tooth resorption.<sup>5</sup> Invasive cervical resorption is one form of hyperplastic invasive tooth resorption.<sup>6</sup> It results in the loss of cementum and dentine by an odontoclastic type of action.<sup>7</sup>

The ICR lesion begins just apical to the epithelial attachment of the gingiva at the cervical of the tooth, but can be found anywhere on the root.<sup>8</sup> Due to its location, the beginning lesion is difficult or almost impossible to recognize. The exact mechanism of ICR is still not clearly understood. Microscopic analysis



**Fig. 1** Invasive cervical resorption: Distribution of potential predisposing factors for patients.<sup>2</sup> (Graphic/ Reproduced with permission from Quintessence Publishing.)



of the cervical region of teeth has shown that there appears to be frequent gaps in the cementum in this area, leaving the underlying mineralized dentin exposed and vulnerable to osteoclastic root resorption.<sup>9</sup> It is broadly accepted that either damage to, or deficiency of, the protective layer of cementum apical to the gingival epithelial attachment exposes the root surface to osteoclasts, which then resorbs the dentin.<sup>7</sup>

In general, an area of radicular dentin around the cervical area of the tooth may be devoid of the protective covering of cementum, exposing the root surface to be colonized by osteoclast-like cells, allowing the resorptive process to begin. Osteoclastic action on that area of the radicular dentin eventually results in a hyperplastic resorptive lesion containing fibro-osseous tissue. In order for dental resorption to occur, three conditions have to be present: a blood supply; breakdown or absence of the protective layer; and a stimulus. In the case of ICR, the external protective layer is the cementum, and the internal layer is the predentin of the pulp.

Several potential predisposing factors have been identified. They are: trauma, intracoronal bleaching, surgery, orthodontics, periodontics, bruxism, delayed eruption, developmental defects, interproximal stripping and restoration. Heithersay used a group of 222 patients with a total of 257 teeth with various degrees of invasive cervical resorption. From the subjects' dental histories, it was determined whether there was a sole predisposing factor or a combination of factors. The results are shown diagrammatically in Fig. 1.<sup>2</sup>

The results indicated that a history of orthodontic treatment was the most common sole factor, found in 47 patients, while other factors, mainly trauma and/or bleaching, were present in an additional 11 subjects. Trauma was the second most common sole factor, with 31 teeth. Intra-coronal bleaching, combined with other factors, had the third most affected teeth.<sup>2</sup> The pulp plays no role in the etiology of ICR and remains normal until the ICR becomes very advanced.<sup>1,7,10</sup>

An interesting study was recently published indicating there might be a connection between

human and feline ICR. Four cases of were presented of multiple invasive cervical resorption (mlCR). There was direct contact with cats in two cases and indirect contact in the other two cases. Neutralized testing was done for feline herpes virus type 1 (FeHV-1). Two of the cases were neutralized, and two were partly inhibited. The study indicated a possible transmission of FeHV-1 to humans and the possibility of a role as an etiologic (co)factor in ICR.<sup>11</sup>

### Histology

An interesting observation is that even in extensive lesions, the pulp is protected from the surrounding resorptive process by a narrow band of dentin (Figs. 2a–c). In some cases of ICR, the clinical and histological views of the lesion substantiate that bone-like tissue has replaced the fibro-vascular tissue located within the resorptive cavity (Figs. 3a,b). In the larger Class 3 and Class 4 lesions, communicating channels can be seen communicating with the periodontal ligament. Other channels can also occur within the internal aspect of the radicular dentin (Figs. 4a,b).

The larger, more advanced lesions can be described as consisting of granulomatous bonelike fibro-osseous material with a canalicular structure that has extensions into the radicular dentin and periodontal tissue. Osteoclasts might be observed on the resorbing surface within the lacunae.<sup>2</sup> Over varying amounts of time, the lesion expands apically and coronally, encircling the pulpal tissue that is protected by a thin wall of predentin and dentin.

### Clinical classification

Heithersay's clinical classification was developed as a guideline for treatment planning and for comparative clinical research.<sup>2</sup> The classification is shown diagrammatically in Fig. 5. The classification allows the operator to more precisely determine the probable extent of treatment. The more extensive

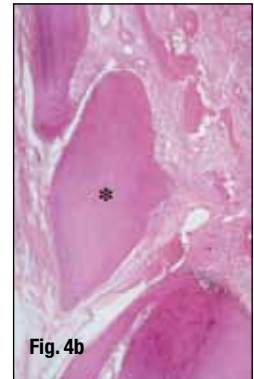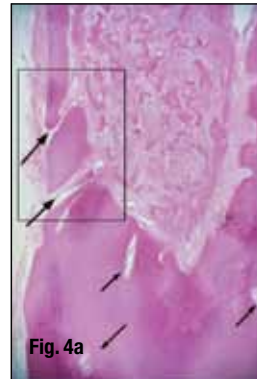
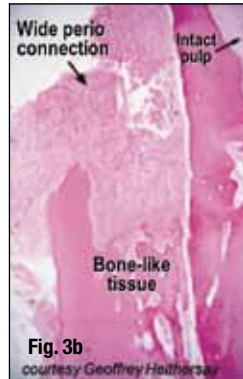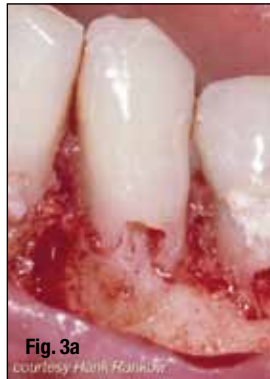**Figs. 2a, 2b** The pulp remains intact, encircled by a narrow band of dentin (red arrows). Histologically, the pulp remains intact and is protected from the extensive resorptive lesion by a narrow wall of dentin (a). A low powered photograph shows the walling off of the pulp by dentin, protecting it from the surrounding extensive resorptive process (b). (Slide adaptation reproduced with permission from Dr. Geoffrey Heithersay.)

**Fig. 2c** High magnification of the distal orifice of a lower second molar being treated for ICR. The pulp remains intact, encircled by a narrow band of dentin (bottom arrow). The involved dentin (middle arrow) and a possible distal penetration area (top arrow) can be observed. (Slide adaptation reproduced with permission from Dr. Raphael Bellamy.)

**Figs. 3a,3b** Both the clinical picture (a) and histological view (b) show how the dentin has been extensively replaced by a bone-like tissue.

A mass of fibrovascular tissue infiltrated with inflammatory cells is located within a large resorptive cavity that has a wide connection with the periodontal tissue (large arrow). The dentin has been extensively replaced by bone-like tissue. A small section of intact pulp can be seen on the superior aspect of the section (small arrow).

Hematoxylin-eosin stain; original magnification X 30.<sup>1</sup> (Reproduced with permission from Quintessence Publishing and Dr. Henry Rankow.)



**Figs. 4a,4b** Histologic appearance of an extensive invasive cervical resorption with radicular extensions. Masses of ectopic calcific tissue are evident both within the fibrovascular tissue occupying the resorption cavity and on resorbed dentin surfaces. In addition, communicating channels can be seen connecting with the periodontal ligament (large arrows). Other channels can be seen within the inferior aspect of the radicular dentine (small arrows). Hematoxylin-eosin stain; original magnification X 30.

Higher magnification (b) shows communication channels from the periodontal ligament to the resorbing tissue. An island of hard tissue remains (\*), consisting of an external surface of cementum and cementoid; some residual dentine; but the bulk has been replaced with a bone-like material with canalicular structure.

Although some red blood cells are evident near the deeper channel no inflammatory cells can be seen.

Hematoxylin-eosin stain; original magnification X 50.<sup>1</sup> (Reproduced with permission from Quintessence Publishing.)

the lesion, the more complex the treatment options become.

Class 1: Small invasive resorptive lesion with shallow penetration into dentin.

Class 2: Well-defined invasive resorptive lesion close to the coronal pulp chamber.

Class 3: Deeper invasion extending into the coronal third of radicular dentine.

Class 4: A large invasive lesion extending beyond the coronal third of the root.

Normally, a Class 1 lesion can be successfully treated without much difficulty. But Class 2 lesions often require minor gingival flap surgery for retraction to achieve adequate access, removal of the affected dentin and restoration of the defect. Class 3 lesions usually involve a surgical approach and/or orthodontic extrusion. Class 1 and 2 lesions can be treated predictably, but the success rate in treating Class 3 and 4 lesions drops dramatically. So, in general, as the classification increases, the prognosis decreases.

## \_Diagnosis

The earlier the diagnosis, the more predictable the outcome of treatment will be. Due to the nature of the lesion, treatment based on an incorrect diagnosis will usually result in continued progression of the resorptive process and eventual loss of the tooth.

Unfortunately, the smaller Class 1 lesion is often not discovered due to its location beneath the gingival attachment; but it will usually show a small radiolucency on a radiograph. The dental examination may reveal a slight irregularity in the gingival contour, which will bleed upon probing.<sup>4</sup> It is the author's experience that Class 1 lesions, at this early stage, are seldom found during routine dental examinations.

One of the problems with early diagnosis is the lesion is asymptomatic and can remain so even in the more advanced stages. Pulp testing will be of no value, because the pulp remains unaffected until late in the process. On the other hand, the larger Class 2 lesion can present with more obvious clinical signs. For example, a patient notices a pinkish area on an anterior tooth. The discoloration is the result of os-

teoclastic activity replacing the radicular structure of the tooth with reddish granulation tissue that is showing through the more translucent enamel.

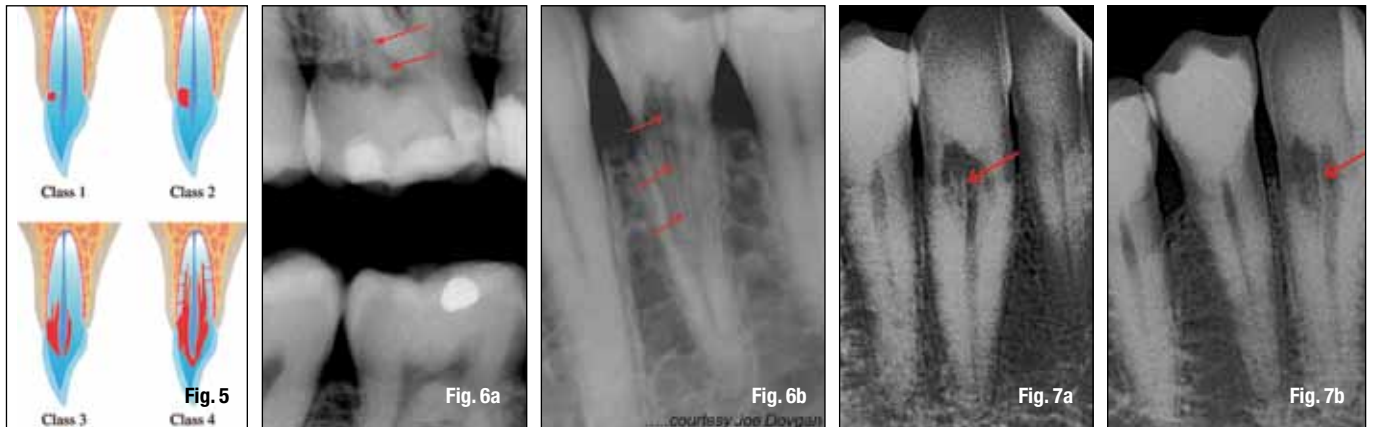
Radiographically, the smaller Class 1 lesion can be confused with a carious lesion, internal resorption or adumbration (cervical burnout) of the radiograph. If the lesion is a Class 2, Class 3, or Class 4, bitewing radiographs will often present an atypical radiolucency and the examining dentist will be more inclined to believe that it isn't just a carious lesion. If the lesion is on the proximal of the tooth, the outline of the pulp can usually be observed.

The larger lesions can also be misdiagnosed as caries, or internal resorption. The usual indication that the lesion is not carious is the irregularity of the radiolucency and/or the radiopaque outline of the protective predentin layer of the pulp (Figs. 6a,6b). By utilizing varying angulation of the radiographs, internal resorption can be ruled out. If the lesion is internal resorption, it will remain centered whatever the direction, or "off-angle," the radiograph is taken. However, if the lesion is one of ICR, Clark's Rule, or SLOB Rule, can be used to determine the location of the lesion (the most lingual object moves with the direction of the X-ray head) (Figs. 7a,7b).

With the advent of cone beam computed tomography (CBCT), the clinician is given the opportunity to view teeth and anatomical entities in three dimensions. Compare with the typical periapical radiographs (Fig. 8a). Even if numerous angles are taken, a complete view of the extent of the lesion cannot be established with any definitive accuracy. The extracted tooth #3 was a hopeless Class 4 lesion involving most of the cervical half of the lingual and extending into the area (Fig. 8b).

Three planes of sections can be evaluated with CBCT: the frontal/coronal (X), sagittal (Y) and axial (Z) (Fig. 8c). The "X"-frontal/coronal plane moves anterior-posterior (B-L in the anterior teeth and M-D in the posterior). The "Y"-sagittal plane moves left-right (M-D in the anterior and B-L in the posterior). The "Z"-axial plane moves coronal-apical for all teeth in the dental arch. Depending on the machine, up to 512 slices of the field of view (FOV) can





be visualized. The slice thickness is variable, again depending on the machine, from nearly 0.1 to several mm. However, generally speaking, the thinner the slice the higher the spacial resolution.<sup>12</sup> When evaluating resorptive defects, higher resolution and three-dimensional images allow the experienced clinician to make a more definitive diagnosis, a confident and realistic plan for treatment, with a higher predictability of success.

So, in a nutshell, the characteristic diagnostic signs that indicate the lesion is a result of ICR are as follows: 1) The tooth is asymptomatic; 2) The pulp tests are within normal limits; 3) The ICR defect moves with varying X-ray angulations; 4) The protective pulpal wall is often intact and can be seen on the radiographs; 5) The portals of entry are near the osseous crest; and 6) The portals of entry are hard to locate clinically.<sup>13</sup>

During the initial dental examination, the author suggests the patients should be asked if any of the three major predisposing factors have occurred in their past dental history: bleaching, trauma or orthodontics. And, as a side note, "Do you have any cats?" ICR can occur in any permanent tooth and once found in a patient, it is important to initiate regular follow-up visits to be sure no further lesions occur.

## Treatment

After the diagnosis of ICR has been confirmed, the treatment should be scheduled as soon as possible. If, for some reason this is not practical, the tooth should be monitored closely. The lesion can be very aggressive, so best not to "wait and watch" for too long a time, never more than two to three months (Figs. 9a–c).

The Heithersay Classification is of great help to advise the patient of the extent of treatment and get a better idea of the possible prognosis. The patient and doctor together can decide: 1) No treatment and extraction if the tooth becomes symptomatic; 2) Extraction and possible replacement with an implant; or 3) To begin endodontic treatment in an attempt to eliminate the lesion and restore the tooth for as long

as possible. In Class 1 and Class 2 cases, the patient is advised the treatment will probably be nonsurgical, but the surgical approach may be necessary. In the more advanced Class 3 and Class 4 cases, the patient is advised that both the non-surgical and surgical approach will be necessary. Dental implants have become popular, and unfortunately, have led to a greater percentage of patients choosing options one and two.<sup>8</sup> However, there are still enough patients who want to save their natural teeth, "no matter what"!

Heithersay developed what has become the standard guide for the treatment of ICR. Depending on the extent of the lesion, it is accessed either nonsurgically, or surgically. The granulation tissue is removed either with curettes, or a round bur of varying sizes. During the removal of the bone-like tissue, 90 percent trichloroacetic acid (TCA) is applied with a small cotton pellet numerous times, with increasing pressures, to achieve coagulation necrosis.

Using magnification, the fibro-osseous granulation tissue is removed until no communication channels are observed and the defect is lined with unaffected dentin, then restored with an appropriate restorative material. Endodontic treatment is performed when indicated. The basic aim of treatment is to eliminate all active resorbing tissue and restoration of the defect so the tooth can be maintained as long as possible.<sup>4</sup> It has been the author's experience that all cases of Class 2–4 required endodontic treatment.

The author wishes to make something very clear. In the following cases, the 90 percent TCA was not used. There was absolutely no disagreement about the use of TCA, but at the time the following cases were treated, it was not available. The cases were treated with what was on hand. As a matter of convenience and necessity, Monsel's Solution (MS), a 72 percent solution of ferric sulfate with sulfuric acid, was used. It had been used for many years as a coagulant while performing apical microsurgery. The use of MS to achieve coagulation necrosis when treating ICR over the years appeared to work just fine. As a result, the use of use of MS was continued.

**Fig. 5** Clinical classification of invasive cervical resorption.<sup>2</sup> (Reproduced with permission from Quintessence Publishing.)

**Figs. 6a,6b** The outline of the pulp can usually be observed radiographically. The bitewing X-ray (a) will show the ICR lesion and the predentin layer (red arrows). The predentin protective layer can exist even in the advanced Class 4 lesions (red arrows) (b).

**Figs. 7a,7b** A definitive way to avoid a misdiagnosis of ICR is to take the X-ray from varying angles, including at a normal position (a). However, when the X-ray is taken from a different, more distal angle (b), the radiograph clearly demonstrates the lesion is not internal resorption and is positioned to the lingual. The protective predentin layer surrounding the pulp is clearly visible.