

ortho

international magazine of orthodontics



technique

Accelerated treatment modalities
in clear aligner treatment

industry report

Indirect bonding: Digital technique
vs conventional method

industry report

Hybrid Aligner Therapy

Register Today!

European Carriere Symposium

September 20-22, 2018

Paris, France

World-Renowned Speakers



Dr. Luis Carrière



Dr. John Graham

More Speakers To Come!

Learn more about the
European Carriere Symposium
and register at CarriereSymposium.com

INNOVATION
happens here



HENRY SCHEIN®
ORTHODONTICS

The New Movement In Orthodontics™



Dr Luis Carrière

Specialist in orthodontics and dentofacial orthopaedics

The power of orthodontics

Dear Readers,

Sometimes as orthodontists we tend to simplify what our specialty is about. Behind the simplicity—straightening teeth—there is a wide spectrum of facial, functional and physiological effects that we will generate, all of them intimately interconnected. The patient's soft tissue is not self-supported, so an adequate volumetric amount of hard tissue underneath sculpts the facial harmony. Orthodontics affects important dental, skeletal, functional, postural, physiological, articular, facial and psychological areas for the patient. It is a powerful specialty in which the teeth are only a part.

As orthodontists, we are responsible for accomplishing a balanced mid- and lower third of the face by managing a correct functional and anatomical relation between the maxillae and mandible, harmonising the position of the teeth into an aesthetic interrelation, achieving a functional occlusion. Ultimately, we sculpt the patient's soft tissue, providing facial proportion and a harmonic smile design.

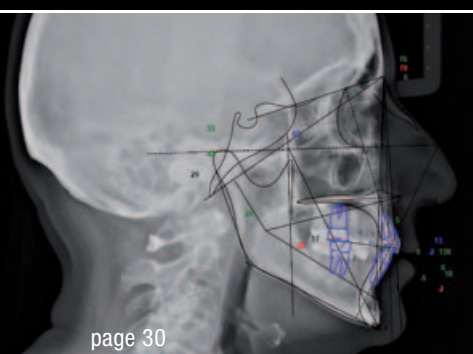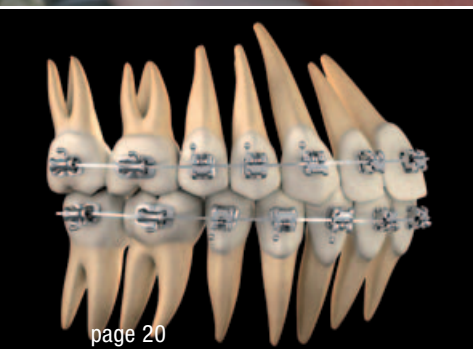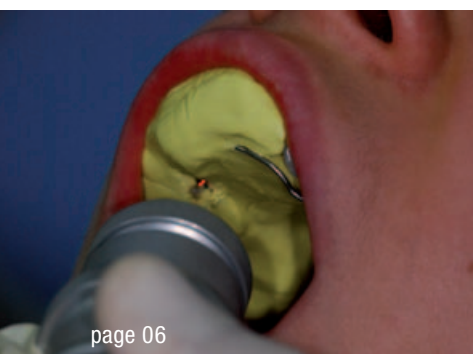
In addition to aesthetics, correct functional occlusion and tooth alignment will promote a healthy condition of the maxillae and mandible, gingivae and teeth, preventing many potential systemic diseases related to periodontal or dental sickness.

This rare ability of our specialty to change the extrinsic traits, the facial features, and maintain simultaneously the facial icon, while enhancing the patient's positive facial features, can also achieve the opposite effect by promoting the patient's negative facial features, maybe obstructing the patient's airway or ending up with incorrect functionality of the stomatognathic system.

Today, a new treatment modality has arisen in orthodontics, commonly known as “do it yourself”. This development signals that it is time to start teaching society about the real power of orthodontics.

Dr Luis Carrière

Specialist in orthodontics and dentofacial orthopaedics



Cover image courtesy of Ortho Caps GmbH
www.orthocaps.com



editorial

The **power** of **orthodontics**

Dr Luis Carrière

03

case series

In-office welding by Nd:YAG laser

Prof. Carlo Fornaini & Prof. Caroline Bertrand

06

case report

Surgical crown lengthening and botulinum toxin in the **management of the orthodontic patient** with gummy smile

Dr Irineu Gregnanin Pedron

10

Non-surgical treatment **of a Class III malocclusion** with missing laterl incisors

Dr Ana Maria Cantor

14

research

Six keys to effectively **using alveolar corticotomy**:

A different perspective on surgically assisted tooth movement

Dr Raffaele Spena

20

technique

Accelerated treatment modalities in **clear aligner treatment**

Dr Gary Brigham

30

industry report

Indirect bonding: Digital technique vs conventional method

Drs Arturo Fortini, Alvise Caburlotto, Elisabetta Carli, Giulia Fortini & Francesca Scilla Smith

38

Hybrid **Aligner Therapy**

Dr Wajeeh Khan

42

interview

Digital smile design meets orthodontics:

Full-day course closes second EAS Congress

Interview with Dr Christian Coachman

46

manufacturer news

48

meetings

Second EAS Congress **proves its worth**

International Events

50

52

about the publisher

submission guidelines

53


international imprint

54

BT₂

RAPID DEEP OVERBITE CORRECTOR (RDC)

BT2 treats severe, skeletal deep overbite malocclusion. Bonded palatally on the upper central incisors, it is the key for Rapid Deep bite Correction (RDC). Its patented curvature designed by Dr. J. Voudouris, reduces muscle hyperactivity, parafunction and permits anterior guidance of the lower incisors that lift the bite preventing anterior interferences during forward grinding.



1. Patented curvature

for an early development of the anterior guidance neural pathway and to prevent incisor interferences during grinding, by jaw-open reflex.

2. Bondable 80 gauge mesh base

anatomically designed to fit incisors surface lingually.

3. Vertical groove (split)

to facilitate bonding and debonding.

TS₂

RAPID OPEN BITE CORRECTION (ROC)

With this innovative product designed by Dr. John Voudouris, Open Bite is resolved in 4-6 months. Placed palatally and lingually from 3-3 it is totally invisible. Its star-protrusions are comfortable reminders to efficiently prevent Anterior Tongue Positioning, while generous undercuts allow the use of intraoral elastics for the crossbite correction.



1. Nine rounded reminder

protrusions prevent tongue thrusting.

2. 80-gauge mesh bonding pad

for increased shear bond strength.

3. Six Undercuts

for crossbite elastics in lateral open bite treatment that commonly require maxillary expansion.



In-office welding by Nd:YAG laser

Prof. Carlo Fornaini & Prof. Caroline Bertrand, France

Introduction

Just after the introduction of the first laser by Maiman in 1960,¹ there was a very fast evolution of this new technology, characterised by constant progression in techniques and applications, increasing the possibility to have smaller and cheaper devices and introducing ever-new wavelengths. Laser welding was first introduced in the jewellery industry during the 1970s and soon after successfully used by dental technicians as well.² The first lasers used were the carbon dioxide and Nd:YAG lasers, but the market was rapidly conquered by the second, owing to the results that could be obtained with it.^{3, 4}

Laser welding offers a great number of advantages compared with traditional welding. Firstly, the laser device saves time in the commercial laboratory because all welding is done directly on the master cast. Inaccuracies in assembly caused by transfers from the master cast along with investment are reduced.⁵ The heat source is a concentrated light beam of high power, which can minimise distortion problems in metals.⁶ By using laser technology, it is possible to weld very close to acrylic resin or ceramic parts with no physical (cracking) or colour damage.⁷ This means it is possible to save time and money during the restoration of broken prostheses or orthodontic appliances, because it is not necessary to remake the non-metallic parts. This welding technique may be used on every kind of metal, but its property of being very active on titanium makes it particularly advisable for prostheses supported by endosseous implants.⁸

Many laboratory tests have demonstrated that laser-welded joints have a high reproducible strength for all metals, consistent with that of the substrate alloy.⁹ All these advantages led to this method being extensively used in dental technicians' laboratories and stimulated companies to put on the market increasingly upgraded appliances. Some aspects, such as large dimensions, high costs and delivery systems, today still characterise those machines that use fixed lenses, strictly limiting their use to dental technicians' laboratories.

The aim of this study is to show, through the description of a series of clinical cases, the utilisation of a laser device normally used for surgery in the dental office to weld orthodontic appliances and to demonstrate the advantages of this technique. The appliance used, the Fidelis Plus III (Fotona), is a combination of two dif-

ferent laser wavelengths, the Er:YAG ($\lambda = 2,940$ nm) and Nd:YAG ($\lambda = 1,064$ nm). The first allows the dentist to treat hard tissue (enamel, dentine and bone) with a mechanism that, utilising the affinity of this laser for water and hydroxyapatite, induces the explosion of intracellular water molecules and so causes the ablation of the tissue.¹⁰ Its utilisation may be extended also to dermatology, where it can be employed in the treatment of keloid scars and wrinkles with resurfacing, in addition to the elimination, by vaporisation, of lesions such as condyloma, naevi, warts and mollusca contagiosa.¹¹ The Nd:YAG laser allows the dentist to perform surgery with complete haemostasis, utilising the affinity of this wavelength for haemoglobin and thus avoiding the use of sutures.¹² The delivery system for this laser is provided by optic fibres of different sizes, chosen according to the kind of application needed, ranging from 200 μ m (endodontics) to 900 μ m (whitening).

In addition to a pulse duration of microseconds, which is necessary during dental interventions, the peculiarity of the Fidelis Plus III appliance is the possibility of pulse durations of milliseconds (15 or 25), which can be utilised in phlebology, in the treatment of lesions of vascular origin, owing to the affinity of this wavelength for haemoglobin.¹³

In our previous work,¹⁴ we demonstrated, by *in vitro* tests on different metal samples, the good quality and high resistance of a joint welded by this device, while in this paper we demonstrate the clinical application of this technique.

Material and methods

The laser device used was, as already stated, the Fidelis Plus III, with a 900 μ m fibre and a 2 mm spot handpiece (R32, Fotona), normally utilised in dermatology, or in some cases a prototype provided by Fotona itself. The parameters that we normally use for welding are:

- Wavelength: 1,064 nm
- Energy: 9.9 J
- Frequency: 1 Hz
- Spot diameter: 1 mm
- Pulse duration: 15 m/s
- Fluence: 1,260 J/cm²
- Working distance: 8 mm



Fig. 1



Fig. 2

Fig. 1: The damaged appliance removed from the mouth. **Fig. 2:** The repaired appliance.

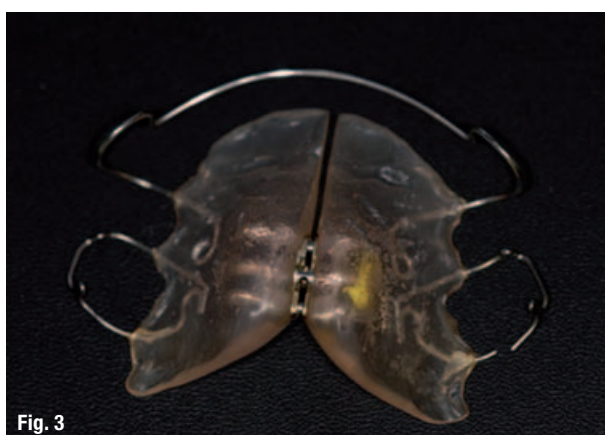


Fig. 3

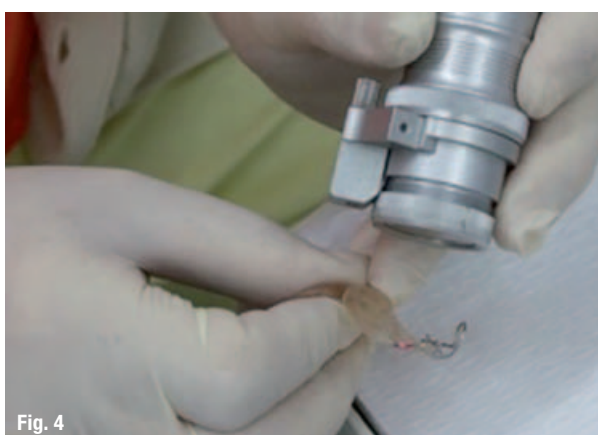

Fig. 4

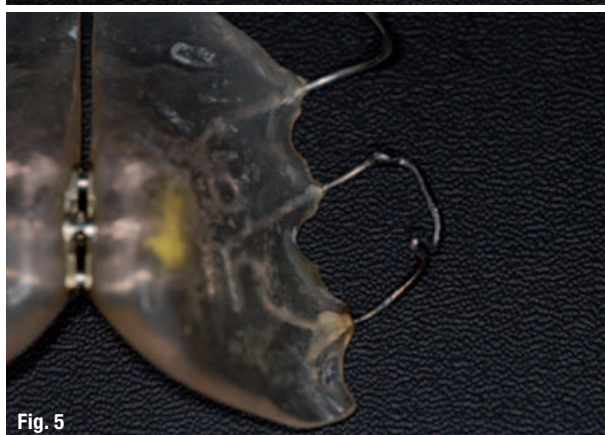

Fig. 5

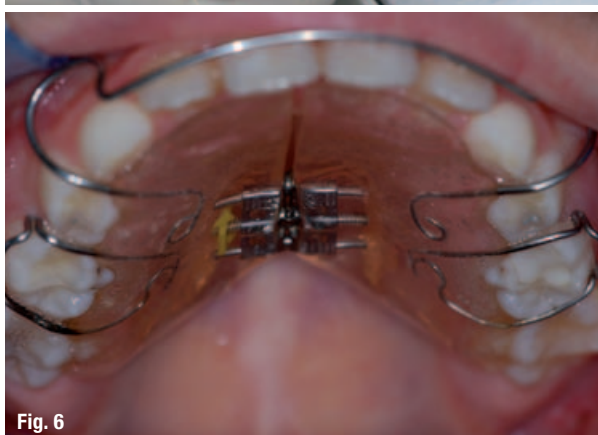


Fig. 6

Fig. 3: The Schwartz appliance with a broken Adam's hook. **Fig. 4:** Laser welding process without filler metal. **Fig. 5:** The hook repaired without damaging the nearby acrylic part. **Fig. 6:** The appliance replaced into the mouth.

Clinical cases

Case 1

A 9-year-old female patient in orthodontic treatment in our office came in urgently owing to damage to the rapid palatal expander applied to her maxillary molars. The clinical examination revealed that the brace had been damaged close to the connection with the arm (Fig. 1). The patient had just finished one stage of the expansion, and since it was very risky to leave her without an appli-

ance, we decided to weld it directly in the office with the Fidelis laser.

The expander was prepared with the conventional procedure required before laser welding (sandblasted with alumina powders of 50 μm in diameter using the Mini-blaster, Deldent; cleaned with acetone and both parts dried). The appliance was directly welded in the office using CoCr-Schweißdraht welding wire (DENTAURUM). After a few minutes only, the appliance was ready to be recemented into the patient's mouth (Fig. 2).

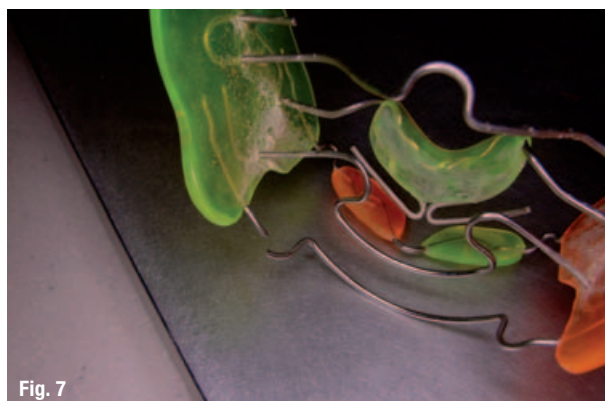


Fig. 7



Fig. 8

Fig. 7: The Frankel orthodontic appliance with a fractured wire. **Fig. 8:** The orthodontic appliance repaired.

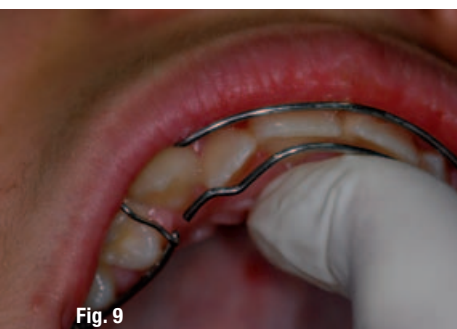

Fig. 9

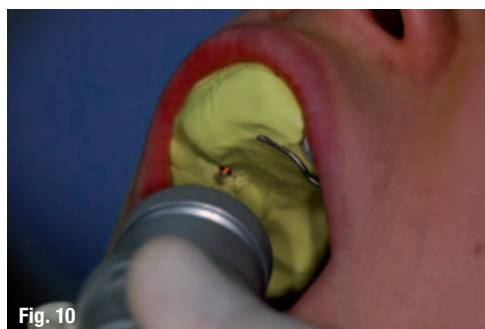


Fig. 10

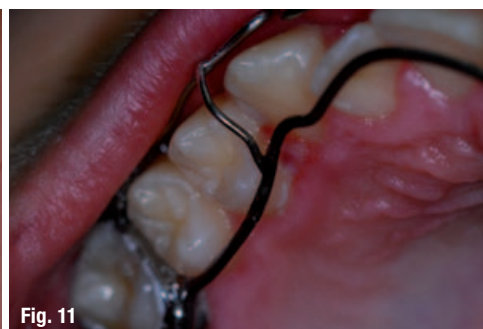

Fig. 11

Fig. 9: The Delaire appliance with a broken wire arm. **Fig. 10:** Laser welding of the appliance. **Fig. 11:** The appliance repaired.

Case 2

An 8-year-old male patient in treatment in our office with a Schwartz removable orthodontic appliance came to us for periodic checking of the appliance, and we saw that one of the Adam's hooks had broken (Fig. 3). We welded it without filler metal (Fig. 4), and the plastic shield, although very close to the welding zone, was not damaged or modified (Fig. 5). We were able to reseat the repaired appliance in the patient's mouth after only some minutes (Fig. 6).

Case 3

An 8-year-old male patient in treatment in our office with a Frankel removable orthodontic appliance came to us for periodic checking of the appliance, and we saw that one of the wires had broken (Fig. 7). We welded it without metal filler (Fig. 8), and the plastic shield, although very close to the welding zone, was not damaged or modified. We were able to reseat the repaired appliance in the patient's mouth after only some minutes.

Case 4

A 14-year-old male patient came to our office with the lingual wire of his appliance broken. The appliance was

an orthodontic appliance called Delaire consisting of two wires, one vestibular and one lingual, connected to two braces on first maxillary molars (Fig. 9). Owing to the presence of a sizable restoration on the first maxillary right molar, we decided not to remove the appliance and to perform an intra-oral laser welding. A previously made screen in silicone was used to protect the soft tissue, and the appliance was welded without filler metal; the entire operation lasted 4 minutes; the welding was done in 75 s (Fig. 10). After a few minutes, without having to send it to the dental laboratory and with no discomfort to the patient, the appliance could be repaired (Fig. 11). The follow-up was done monthly for six months and showed that the appliance was active and strength-proof.

Case 5

A 14-year-old female patient, in orthodontic treatment with a Veltri fixed appliance to open the space in the upper arch in order to insert the second premolar, came to us for a normal check of the appliance, and it was observed that an arm had broken near the brace of the first premolar (Fig. 12). The removal of the appliance in order to send it to the laboratory was deemed as having too many risks, since the treatment was still in the activation phase. Therefore, it was decided to perform an intra-oral laser welding. In order to protect the soft tissue, a silicone film

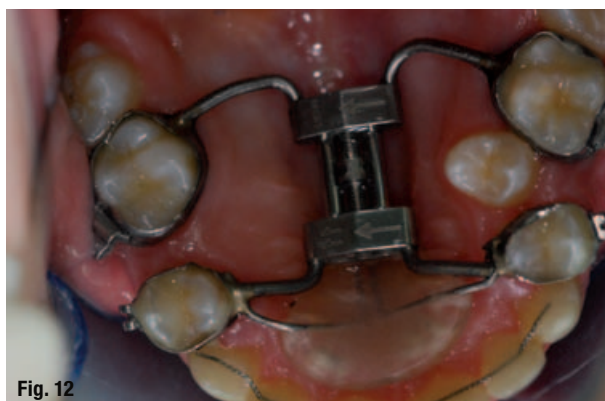

Fig. 12



Fig. 13

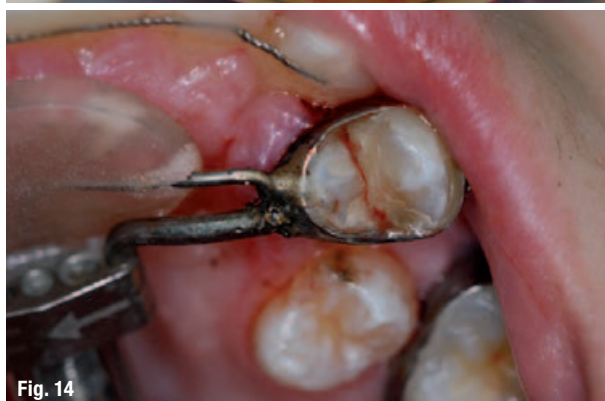

Fig. 14

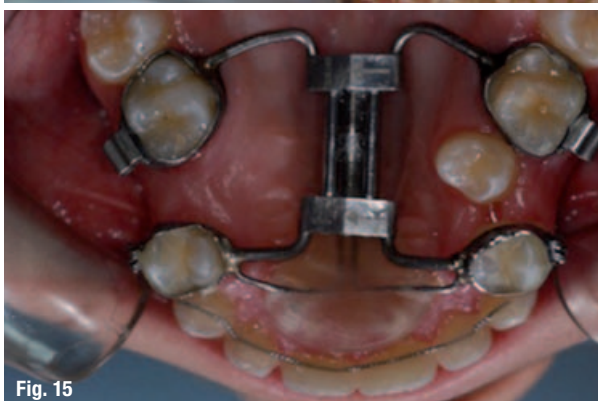

Fig. 15

Fig. 12: The Veltri appliance with a broken arm. **Fig. 13:** Intra-oral laser welding. **Fig. 14:** The wire of the appliance repaired. **Fig. 15:** The appliance reactivated after welding of the wire.

was employed (Fig. 13). The procedure was performed without filler metal and took 2 minutes, and the irradiation time was 20 s (Fig. 14). After the reparation, the therapy was continued, turning the screw until the required space was achieved (Fig. 15).

Conclusion

The ability to weld broken orthodontic appliances directly in the office represents for the dentist a new prospect, allowing the restoration of appliances extremely quickly without additional costs (the welding appliance is the same used for dental therapies). Being able to maintain the integrity of plastic, acrylic and ceramic parts close to the welding zone and the ability to make the reparation while the patient is sitting in the chair and in one visit only are, in our opinion, the great advantages in terms of costs, marketing, patient satisfaction and efficiency of the office. Moreover, as shown in the clinical cases presented, the welding process may also be performed intra-orally without risks and discomfort to the patient. The period of learning for dentists is very short, owing to the simple and fast procedure, because the parameters are standard and it is not necessary to change or adapt them to different clinical situations. We think that this technique represents a valid aid in our daily practice and, simultane-

ously, opens a new chapter in laser dentistry, bringing new possibilities we intend to analyse and test in further research.

about



Prof. Carlo Fornaini

is researcher in the MICORALIS Laboratory at the University of Nice and teacher of the Diplôme Inter-Universitaire (DIU) in "Oral Laser Applications" of the Universities of Nice and Bordeaux. He can be contacted at carlo@fornainident.it.



Prof. Caroline Bertrand

is the Dean of the Faculty of Dentistry of the University of Bordeaux and Director of the Diplôme Inter-Universitaire (DIU) in "Oral Laser Applications" of the Universities of Nice and Bordeaux. She can be contacted at caroline.bertrand@u-bordeaux.fr.