

# DENTAL TRIBUNE

The World's Dental Newspaper • Pakistan Edition



PUBLISHED IN PAKISTAN

www.dental-tribune.com.pk

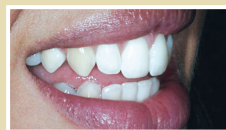JULY, 2016 - Issue No. 04 Vol.3

Researchers examine how providers implement ...



NEWS

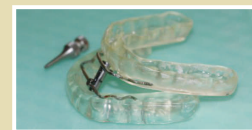► Page 4



The New Frontier of Interceptive Aesthetic Orthodontics

CLINICAL PRACTICE

► Page 6



Intraoral Device for the treatment of Sleep Apnea

CLINICAL PRACTICE

► Page 7

## Pakistani Dentists win at APDF

DT Pakistan Report

**K**ARACHI - Pakistan's three renowned dental surgeons - Dr Mahmood Shah, Dr Anwar Saeed and Dr Asif Niaz Arain - have brought laurels to the country by winning coveted posts in the APDF's (Asia Pacific Dental Federation) recent elections held in Hong Kong. The APDF office-bearers' elections took place on the last day of the 38th Asia Pacific Dental Congress (APDC 2016) held at Hong Kong Convention and Exhibition Centre from June 17 to 19.

According to the details, Dr Mahmood Shah, whose opponent was from the Philippines, clinched the post of APDF's Chairman for Oral Diseases Commission, Dr Anwar Saeed bagged the post of APDF's Chairman for Dental Public Health Commission after defeating his counterpart from Taiwan, while Dr Asif Niaz Arain became the APDF's vice president. All of them were re-elected.

Sources said that the three Pakistani surgeons got the APDF's prestigious posts although a number of delegates of the congress, belonging to the Muslim countries such as Saudi Arabia, Jordan,



Lebanon, etc., did not participate in the APDF's election process owing to the Holy month of Ramadan.

The 38th Asia Pacific Dental Congress APDC was hosted by Hong Kong Dental Association in collaboration with the APDF and supported by FDI World Dental Federation.

As the theme of the congress was "Advancing Dentistry with Modern Science and Technology", distinguished international speakers shared significant new developments and scientific advancements.

The APDC-2016 also featured a comprehensive trade exhibition, showcasing newest materials and technology in dentistry.

## Punjab streamlines PG induction system

DT Pakistan Report

**L**AHORE - Punjab's healthcare and medical education department has centralised its postgraduate induction system so that doctors seeking training in teaching hospitals across the province could be inducted purely on merit. Admissions under the new policy will be made through Centralised Admission Test (CAT) to be conducted by the Joint Admission Commission (JAC) once a year for entrance into MD/MDS programmes.

The other salient features of the policy are as follows:

- Now every candidate will have to join his/her place of induction for training in accordance with the new merit formula whether his/her institute falls in south Punjab or other city.

- There shall be no test for candidates who already passed FCPS Part-I and aspiring for induction as PG trainee for FCPS -II. There shall be merit determination formula for the candidates (Academic and Experience Marks 50+ Examination Marks 35=85 marks).

- The stipendiary PG trainee seats allocated by the

### MARKETS FLOODED WITH OVER 100 BRANDS OF INFERIOR QUALITY BETEL NUTS

## Oral cancer increasing 'geometrically' in Pakistan: Dr Sajjad

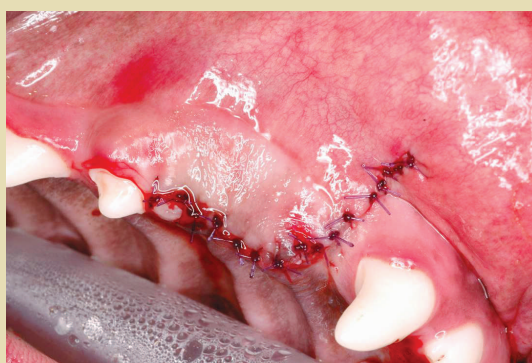DT Pakistan Report

**K**ARACHI - Prominent ENT surgeon Dr Qaiser Sajjad has said that oral cancer is increasing 'geometrically' in Pakistan and attributed the disease to the habit of eating betel nuts (Chalia) in different forms, gutka, J.M and Panprag and use of tobacco.

Underscoring the need for creating awareness about health hazards of chalia, sweet supari, gutka, Dr Sajjad, who is also finance secretary of Pakistan Medical Association (Centre), demanded of the government to impose a ban on the import of chalia and bring an immediate halt to the sale, manufacturing and marketing of gutka and sweet supari across the country

Talking about the hazards of betel nut, he said: "Even a good quality chalia can cause problems like cancer as the juice of betel nut is carcinogen (any substance that, when exposed to living tissues, may cause the production of cancer).

In support of his contention that even good quality chalia could cause oral cancer, Dr Sajjad recalled that though the renowned playwright and a former adviser to Sindh chief minister on cultural affairs,



Fatima Surayya Bajia, popularly known as Bajia Aapa, died a natural death, she had earlier developed oral cancer because of her habit of chewing betel nut and the stuff she used to take was of best quality. "Bajia Aapa was fully recovered from her oral cancer problem because she timely contacted doctors and had successful treatment," he added.

Citing another example in this regard, he said that prominent radio artiste and broadcaster, Imtiaz Saheb, who too used to eat good quality chalia and smoke cigarettes had become victim of cancer of vocal cord.

Terming fungal-infested betel nuts and sweet

supari 'poison', Dr Sajjad said that betel nuts are highly dangerous because it is adulterated with chemicals, blood, charas, while sweet supari contains artificial colour which is nothing but textile colour -, a carcinogen.

Dr Sajjad, who had been practicing in Karachi for the last 35 years and had collected data about the victims of gutka, chalia, etc., deplored that though the country's market is flooded with as many as 122 different brands of inferior quality chalia and sweet supari, there is no check and balance on their sale. "We don't produce betel nuts, but a huge amount of precious foreign exchange was being wasted on the import of fungal-infested betel nuts in the country and the same is being sold in markets in attractive packing.

Elaborating, he said that it has also been proved that when fungus-infested betel nut is routinely taken, it acts as a carcinogen and thus causes liver cancer. "Juice of betel nut and artificial colour are carcinogen, he warned.

At the outset, Dr Sajjad, who had wide experience of treating oral cancer patients, said that the disease is, definitely, hundred per cent curable provided it

*Continued on page 10*

# A case for single-use hand instruments in general dental practice

By Robert Jagger

A wide range of single-use disposable dental and surgical instruments is now produced by a number of manufacturers. Instruments are available for purchase either singly or as procedure kits and are priced to be a realistic alternative to decontaminating reusable instruments.<sup>1</sup> Paradoxically, single-use instrumentation is rarely seen as a viable alternative by dental professionals, who typically associate single-use instruments with cheap unreliable plastic devices and a very limited product range.

In reality, there are mirrors, probes, restorative instruments, endodontic instruments, minor oral surgical instruments and extraction forceps for both adult and paediatric use. Procedure packs too are available for specific procedures and contain all of the necessary instruments. Examples of packs include those for dental and periodontal examination, restorative procedures, maxillofacial biopsy, minor oral surgery, and periodontal microsurgery. This article seeks to challenge current clinician perceptions of single-use instrumentation by examining the potential benefits of high-quality single-use instruments in daily practice.

## Quality

Single-use instruments can be of extremely high quality and may be almost indistinguishable in use from reusable instruments. Clinicians often comment that they are impressed by their quality and functionality and that they appear far too good to throw away after just one use. These instruments are a significant step forwards from the poorer quality equipment that was previously available.

Before selecting a supplier of single-use instruments, however, it is critical to ensure that they comply fully with all relevant British and European medical device regulatory standards and that they are manufactured from medical-grade surgical steel and undergo rigorous in-process quality assurance checks and batch testing. Purchasing instruments from a supplier approved by the British Dental Industry Association will provide practitioners with assurance that they are dealing with an appropriately regulated manufacturer.

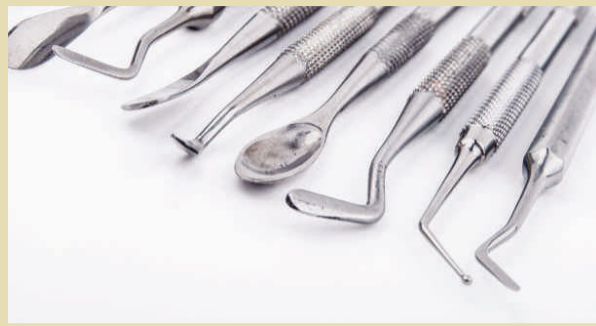## Sterilisation

One of the most significant changes to have affected the dental profession in recent years has been the adoption of rigorous sterilisation and cross-contamination procedures (HTM 01-05: Decontamination in Primary Care Dental Practices).<sup>2</sup> Dangers posed by prion diseases, such as variant Creutzfeldt-Jakob Disease (vCJD), remain even with the most effective dental sterilisation processes. The prion associated with vCJD is able to survive steam autoclaving under standard exposure conditions,<sup>2</sup> suggesting that some reusable surgical instruments are potentially being utilised in a contaminated state. Use of single-use disposable instruments ensures that instruments are not contaminated, protecting patients and clinical staff alike.

## Costs

Most general dental practices are now equipped with HTM 01-05-compliant equipment. Reprocessing dental instrument trays, however, inevitably leads to significant wear and tear and ultimately instrument damage. Regular sharpening (and replacement) of reusable instruments too is necessary for instruments such as luxators, chisels and elevators. This can add substantial costs to the reprocessing of reusable instruments. Reprocessing protocols dictate that a dental practice must hold significant stock of expensive reusable instruments, much of which often lies redundant at any given point in time.

Single-use instruments can provide a cost-effective contingency to cover unexpected emergency situations in which reusable instruments may be unavailable, for example when managing unplanned surgical complications



or when washer disinfectors or sterilisers are inoperable and significant clinical time may be lost while waiting for the arrival of a skilled service engineer. Single-use instruments enable clinicians to forecast true procedure costs accurately, as there are no hidden costs associated with the decontamination, sterilisation and packaging of reusable instrumentation.

## Convenience

Among other applications, single-use packs allow rapid and efficient management of dental extractions that become complicated by, for example, crown fracture. Contingency stock of single-use surgical packs (comprising integral single-use scalpel handles and blades, tissue retractors, periosteal elevators, dental elevators and suture packs) enables highly convenient, efficient and cost-effective management of complications.

Single-use conservation and examination packs provide a cost-effective means of extending the length of daily clinic treatment sessions, especially towards the end of the day, when access to sterile reusable instruments may be compromised owing to sterilisation equipment downtime or cleaning routines (when nursing staff are therefore unavailable for clinical duties).

In endodontics, clinicians can more effectively identify and control procedure costs and maximise their return on time-consuming and costly procedures with the use of single-use rubber dams and root canal obturation packs. Safety-conscious patients are increasingly requesting that single-use instruments be used for their treatment because they feel more comfortable if the hand instruments used to perform their procedure are brand new and have never been used on another patient. Single-use instruments eliminate infection prevention concerns associated with the reprocessing of reusable instruments.

Single-use dental scalers are an efficient solution for dentists, dental hygienists and dental therapists, since every instrument is guaranteed to be sharp for every procedure, enabling reduced treatment times and less patient discomfort. The Instrapac Periodontal Microsurgery Pack (Robinson Healthcare) is designed to facilitate complex periodontal surgical procedures in a cost-effective way, ensuring that instruments are always functional and sterile. Robinson's soft-tissue biopsy packs provide an off-the-shelf sterile, cost-effective solution for performing intra-oral tissue biopsies, particularly in general practice, where these procedures are often performed infrequently.

In implant dentistry, single-use periostomes and microsurgery packs provide a cost-effective solution for procedures that require precision and speed.

Moreover, single-use conservation and surgical packs offer benefits when managing medically vulnerable patients, including those with immunocompromising conditions and those requiring dental treatment before elective cardiac and renal surgery and pre- and post-head and neck radiotherapy and chemotherapy.

## Environmental impact

It is often forgotten that decontamination and sterilisation procedures consume large amounts of energy, water, cleaning fluids and consumables, with associated significant environmental impact. Single-use surgical instruments are designated as a specialist clinical waste stream and as

Continued on page 14

## DENTAL TRIBUNE

The World's Dental Newspaper - Pakistan Edition

**Publisher/CEO**  
Syed Hashim A. Hasan  
hashim@dental-tribune.com.pk

**Editor Clinical Research:**  
Dr. Inayatullah Padhiar

**Editors Research & Public Health**  
Prof. Dr. Ayyaz Ali Khan

**Editor - Online**  
Haseeb Uddin

**Designing & Layouting**  
Sh. M. Sadiq Ali

**Dental Tribune Pakistan**  
3rd floor, Mahmood Centre, BC-11, Block-9  
Clifton, Karachi, Pakistan.  
Tel.: +92 21 35378440-2 | Fax: +92 21 35836940  
www.dental-tribune.com.pk  
info@dental-tribune.com.pk

Dental Tribune Pakistan cannot assume responsibility for the validity of product claims or for typographical errors. The publisher also does not assume responsibility for product names or statements made by advertisers. Opinions expressed by authors are their own and may not reflect of **Dental Tribune Pakistan.**

## International Imprint

Group Editor  
**Daniel Zimmermann**  
newsroom@dental-tribune.com  
Tel.: +44 161 112 1830

Clinical Editor  
**Magda Wojtkiewicz**

Online Editors/Social Media Manager  
**Claudia Duschek**

Editor  
**Anne Faulmann**  
Editorial Assistant  
**Kristin Hübner**

Copy Editors  
**Sabrina Raaff**  
**Hans Motschmann**

Publisher/President/CEO  
**Torsten Oemus**

Chief Financial Officer  
**Dan Wunderlich**

Chief Technology Officer  
**Serban Veres**

Business Development Manager  
**Claudia Salwiczek-Majonek**  
Jr. Manager Business Development  
**Sarah Schubert**

Project Manager Online  
**Tom Carvalho**

Event Manager  
**Lars Hoffmann**  
Education Manager  
**Christiane Ferret**

International PR & Project Manager  
**Marc Chalupsky**

Marketing & Sales Services  
**Nicole Andriä**

Event Services  
**Esther Wodarski**  
Accounting Services  
**Karen Hamatschek**  
**Anja Maywald**  
**Manuela Hunger**

Media Sales Managers  
**Matthias Diessner** (Key Accounts)  
**Melissa Brown** (International)  
**Antje Kahnt** (International)  
**Peter Witteczek** (Asia Pacific)  
**Weridiana Mageswki** (Latin America)  
**Maria Kaiser** (North America)  
**Hélène Carpentier** (Europe)  
**Barbora Solarova** (Eastern Europe)

Executive Producer  
**Gernot Meyer**  
Advertising Disposition  
**Marius Mezger**

**Dental Tribune International**  
Holbeinstr. 29, 04229 Leipzig, Germany  
Tel.: +49 341 48 474 302 | Fax: +49 341 48 474 173  
info@dental-tribune.com | www.dental-tribune.com

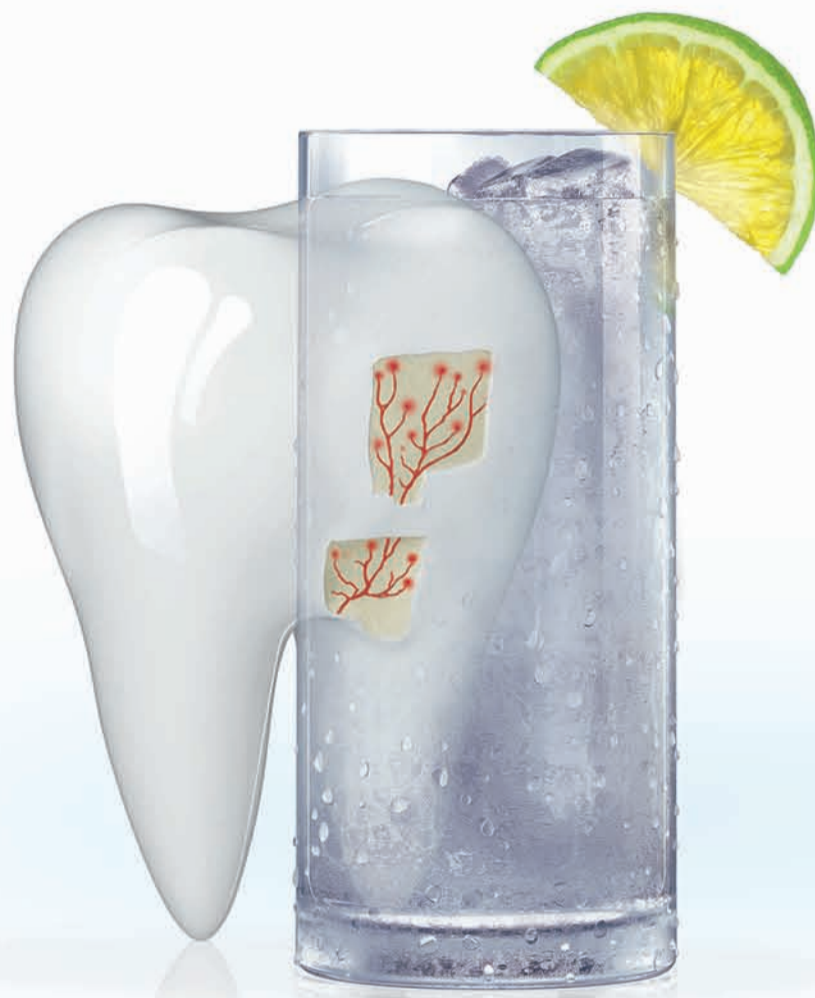## Regional Offices

**Asia Pacific**  
Dental Tribune Asia Pacific Limited  
Room A, 20/F, Harvard Commercial Building,  
105-111 Thomson Road, Wanchai, Hong Kong  
Tel.: +852 3113 6177 | Fax: +852 3113 6199

## The Americas

Tribune America, LLC  
116 West 23rd Street, Ste. 500, New York, N.Y.  
10011, USA  
Tel.: +1 212 244 7181 | Fax: +1 212 244 7185

# DAMAGED ENAMEL CAUSES SENSITIVITY.



## REBUILDS ENAMEL FOR LASTING SENSITIVITY RELIEF

**Colgate®**

PAKISTAN'S #1 SENSITIVITY TOOTHPASTE  
RECOMMENDED BY DENTISTS\*

\*Based on Professional Dentists Tracking Study - IPSOS Pakistan Nov 2015

# Researchers examine how providers implement caries risk assessment protocol

By Robert Jagger

**S**AN FRANCISCO, USA - New research has shown that assessment of individual risk of developing dental caries can help dentists effectively tailor prevention and treatment efforts. The study focused on how providers implemented a protocol that combines risk assessment with personalized preventive care and regular monitoring. The researchers also investigated how risk assessments affected patients' course of treatment and oral health.

The Caries Management by Risk Assessment (CAMBRA) protocol was developed at the University of California, San Francisco School of Dentistry. In the current study, a baseline sample of 3,810 pediatric patients at UCSF were assessed using a 17-item form that records multiple environmental and behavioral factors known to contribute to caries, such as the patient's access to fluoridated water, frequency of snacking, and

socio-economic status. The predictive value of these risk assessments was then evaluated in a follow-up group of 1,315 patients from 6 months old to 6 years old from a largely low-income urban population.

The researchers found that dental care providers' risk assignments were correlated with the risk of future decay, said study author Dr. Benjamin Chaffee, assistant professor and Director of the Global Oral Health Program at the dental school. At the follow-up visits, only about 20 percent of the low-risk patients presented with tooth decay; however, nearly 70 percent of those in the high-risk group had decay.

"Risk assessment is predictive—it tells you what kinds of outcomes are going to occur in a patient population," Chaffee said. "Together with other studies, our work has shown that providers are willing and able to use CAMBRA accurately, that it doesn't take a lot of time to do it, and that it is effective."

Caries risk assessments like

CAMBRA help providers account for factors known to influence oral health and to then tailor their approaches to care according to the designated risk level. For example, a patient considered as being at a high risk of developing dental caries may require more frequent radiographs and dental checkups than a patient designated low risk.

"Dental caries, like so many chronic diseases, follow a social gradient," Chaffee further explained. "We want providers to recognize that our patients who come to us from a lower socioeconomic position are more likely to face a heavier burden of disease. It's important to consider that what is going on beyond the dental chair is contributing to the health status of our patients." CAMBRA has the potential to fundamentally change dentistry, but this will be gradual, Chaffee said. "The traditional approach to dental caries for the last 100 years has been when a dentist sees a cavity to fill it and restore the tooth's function, and that's



*An individualized risk assessment of an infant for developing caries serves as the foundation for health care providers to identify and understand a child's risk of early childhood caries*

a critical aspect of what dentists should be doing. But in and of itself, this approach doesn't do anything to prevent the disease from occurring again. It treats the symptom—the consequences of disease—but it doesn't get after the causes of the disease," he concluded.

"More than half of the schools and colleges of dentistry in the US have adopted CAMBRA in one form or another as part of their standard curriculum," said Dean of the School of Dentistry Prof. John Featherstone, who led the research teams that devised the protocol. "There are also increasing numbers of face-to-face and online courses that teach the CAMBRA methods. I am encouraged by the accelerated adoption of CAMBRA in the field." According to the Centers

for Disease Control and Prevention, approximately 23 percent of children aged 2–5 had dental caries in their primary dentition in 2015. Untreated tooth decay in primary teeth among children aged 2–8 was twice as high for Hispanic and non-Hispanic black children compared with non-Hispanic white children. In addition, about three in five adolescents aged 12–19 had experienced dental caries in their permanent dentition and 15 percent had untreated tooth decay.

The study, titled "Caries risk assessment item importance: Risk designation and caries status in children under age 6," was published online and in the July print issue of the JDR Clinical and Translational Research, a new offshoot of the Journal of Dental Research. —DT USA

## Study: Gum disease may increase lung cancer risk

**C**hinese researchers have found that individuals with periodontal disease might be at an increased risk of developing lung cancer. The report, published ahead-of-print in the Journal of Periodontology, found that individuals with periodontal disease have a 1.24-fold increased risk of developing lung cancer. In the report, titled "Periodontal Disease and Incident Lung Cancer Risk: A Meta-Analysis of Cohort Studies," the authors assess the findings of five cohort studies that evaluated 321,420 participants.

The analysis notes an increased risk even after adjusting for participants' alcohol consumption and smoking habits, both of which are common risk factors for periodontal disease. Study participants who were drinkers, smokers and had been diagnosed with diabetes — which is an independent risk factor for both lung cancer and periodontal disease — demonstrated a 1.36-fold increase in lung cancer risk.



*Individuals with periodontal disease have a 1.24-fold increased risk of developing lung cancer.*

The data also indicate that women with periodontal disease are more likely than males to develop lung cancer.

One of the studies cited in the report suggests that certain oral bacteria may be involved in the development of cancer cells in the lungs, while another indicates successful treatment of periodontal disease may lead to a substantially reduced lung cancer risk. Further research is needed to fully understand the link between lung cancer development and periodontal disease.

"This report can be added to the

*Continued on page 12*

## New biomaterial research aims to increase safety of metal implants

**S**AN ANTONIO, USA - Two new research projects investigating biofilm corrosion in pipelines and an ultrasound drug delivery methodology have each received \$125,000 in funding. Although initially geared toward the petroleum industry, where problematic biofilms occur in many of the production and distribution processes, the study findings will have broad implications in other areas, such as dental and other types of implants.

The projects, which are scheduled to launch on Sept. 1 this year, will be conducted by the Southwest Research Institute (SwRI) and the University of Texas at San Antonio (UTSA) as part of the Connecting through Research Partnerships Program.

As part of the first project, SwRI and UTSA will collaborate to gain a better understanding of microbiologically influenced corrosion by collecting genomic and metabolic data from biofilms. These data will be used to develop models



*A new research project will launch in September to provide insights into management of biofilms.*

that can predict corrosion and identify potential novel inhibitors of biofilm formation.

Biofilms are increasingly recognized as an important issue in dental health care, as they can cause dental plaque, sinusitis and serious infections, particularly around implants. Periodontal and periimplant inflammation, which can lead to dental implant failure, are associated with biofilms.

In the second project, UTSA and SwRI researchers will explore new ways to monitor a drug once it has

*Continued on page 10*

new



## Dentine hypersensitivity protection, now in a daily mouthwash

The first Sensodyne® mouthwash containing 3% potassium nitrate and fluoride, clinically proven to provide ongoing protection from the pain of dentine hypersensitivity with twice-daily rinsing.<sup>1-4\*</sup> Recommend Sensodyne mouthwash to your patients after dental procedures and as a daily use mouthwash



\*Rinse twice daily after brushing with a fluoride toothpaste.

GSK is committed to the effective collection and management of human safety information relating to our products and we encourage healthcare professionals to report adverse events to us on +92(21)111-475-725 or pk\_pharmasafety@gsk.com.

References: 1. Gillam DG et al. J Clin Periodontol 1996;23:993-997. 2. Morris A et al. Efficacy of a Potassium Nitrate Mouthrinse for Relieving Dentinal Hypersensitivity, IADR/AADR/CADR 87th General Session and Exhibition, April 1-4 2009. 3. Pereira R et al. J Periodontol 2001;72(12):1720-1725. 4. GSK Data on File (Study RH01751): A Clinical Study Investigating the Efficacy of a Mouthwash in Providing Long Term Relief from Dentinal Hypersensitivity. Prepared November 2015. CHPAK/CHSENO/0050/15.

# The New Frontier of Interceptive Aesthetic Orthodontics

By Dr. Tif Qureshi

How the simple “3 –Step Smile” can offer far more than you might realize. Dr. Tif Qureshi, discusses how the treatment of mild and moderate crowding has far more than just cosmetic orthodontic objectives.

Currently in the market of dentistry it seems as if they are 1000 short-term orthodontic systems out there. The term “cosmetic orthodontics” has been around for a little while but in this article we are going to take an alternative view of what we can achieve. The problem with the term “cosmetic” is that it often suggests things are being done just for visual reasons. This article will argue that in treating mild and moderate crowding

need to pick up a drill or damage any teeth.

This three-step approach we call the ‘three step smile’ through alignment bleaching and bonding. With the right components carried out at the right time it is possible to make the patient’s own teeth look more beautiful without the need for porcelain veneers or other irreversible procedures.

The most important article in dentistry that the profession seems to miss! Br J Orthod. 1990 Aug; 17(3):235-41. Stability and relapse of dental arch alignment.

**Little RM**

1. Arch length reduces following orthodontic treatment, but also does so in untreated normal occlusions. 2. Arch width measured across the mandibular canine teeth typically

orthodontics is for life.

The second point is even more important- that in adults with mild or moderate crowding, the arch length will reduce regardless of whether the patient had orthodontics or not.

This is a critical point for all dentists to understand especially anyone carrying out restorative treatment. That is the teeth you have restored, that you may expect to remain same position through life will keep moving and the functional contacts will change. It is one typical reason why composite fillings classically chip on the front teeth. Basically if you have crowded it will get worse and arch width will collapse which may have an effect on the patient’s guidance. It also means that lower incisors, which have wear facets due to

This patient was treated 10 years ago for mild crowding having relapsed 3 years after comprehensive treatment. There was differential tooth wear already visible and at the 10 years follow up there’s been no irregular wear because the teeth have been held in the correct position. Her teeth were aligned with an Inman Aligner in 4 weeks and fixed retained. The original retainer has remained in place for 10 years. Being a regular patient, in GDP practice, the retainer can be reviewed at correct intervals. (Fig-5-7- Lucy)

This patient was only 21 and her crowding was getting worse, as was the differential tooth-wear on her lower teeth. Her canine guidance was collapsing and she was slowly moving into group function. Her lower incisors were starting the wear differentially.

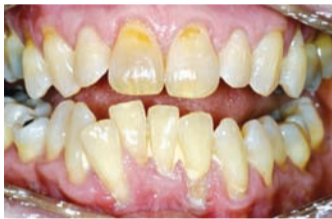

Fig 1: Uppers treated lowers left 30 years on

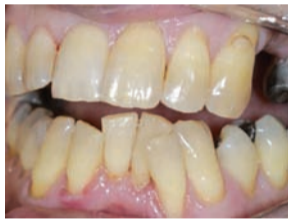

Fig 2: Uppers treated lowers left 25 years on

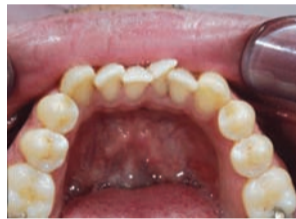

Fig 3: Relapsed comprehensive treatment

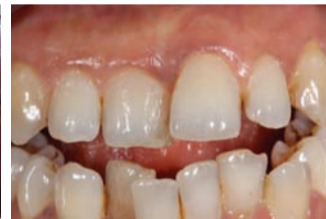

Fig 4: relapsed comprehensive treatment

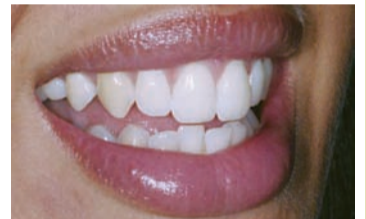

Fig 5: Before treatment 2004

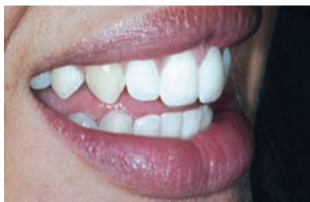

Fig 6: After treatment weeks later 2004

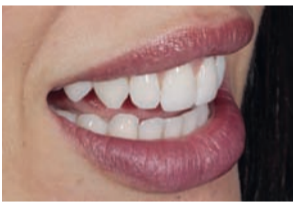

Fig 7: 10 years after IA treatment 2015

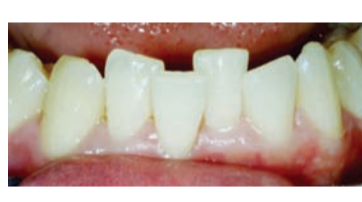

Fig 8: Before treatment 2007

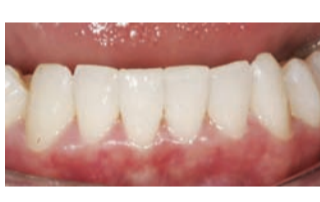

Fig 9: 9 weeks later 2007

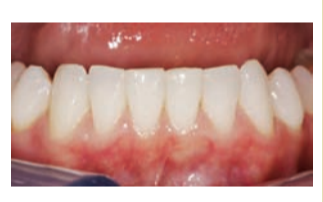

Fig 10: 7 years later

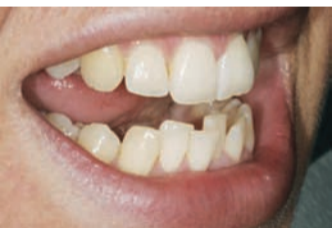

Fig 11: Before treatment

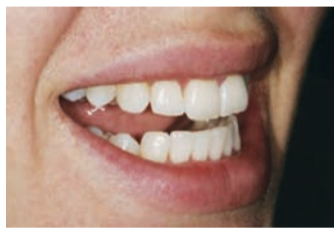

Fig 12: 9 weeks later

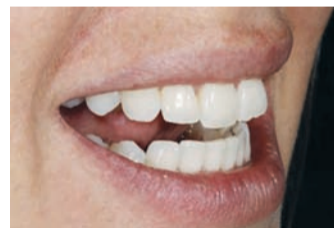

Fig 13: 7 years later 2014

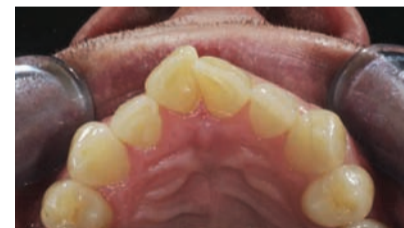

Fig 14: Occlusal view

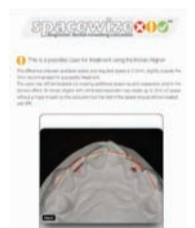


Fig 15: Spacewize through landmark points

cases we are potentially carrying out an interceptive functional treatment.

There have been criticisms from people suggesting that the cosmetic orthodontics and short term orthodontics causes anterior flaring and loss of control of the anterior occlusion. This may be true if there has been no arch evaluation/ planning or space creation strategy. If these things have been carried out then actually the opposite is true, and arguably every better control of the anterior occlusion than in any other form of orthodontics.

This article will also look how simple three-step approach can massively improve the patient’s appearance, their function and intercept the continual crowding life causes more problems without the

reduces post-treatment whether the case was expanded during treatment or not. 3. Mandibular anterior crowding during the post-treatment phase is a continuing phenomenon well into the 20-40 age bracket and likely beyond. 4. Third molar absence or presence, impacted or fully erupted, seems to have little effect on the occurrence or degree of relapse. 5. The degree of post-retention anterior crowding is both unpredictable and variable and no pretreatment variables either from clinical findings, casts, or cephalometric radiographs before or after treatment seem to be useful predictors.

This 40 year study is so important for two main reasons. The first highlights the point now widely accepted that retention after

crowding caused by irregular dynamic contacts, will get worse and wear faster causing more dentine exposure and darkening from the soaking of stain.

These two patients were told 25-30 years ago that the upper teeth needed treatment but the lowers were not crowded enough to treat. At the time they were not that crowded, but over time as per the findings of Little’s study the teeth have continued to crowd causing the evident result. (Fig. 1,2)

These two patients both had comprehensive orthodontics but no fixed retainers were used and no long-term follow-up was carried out by their orthodontist -as a result the patient teeth relapsed almost to the original position. (Fig 3,4)

After aligning her teeth in 9 weeks and fix- retaining, her canine width was increased and held, function returned and 7 years later there has been barely any increase in wear in the lower edges Fig. 8 Cara.

**Detailed case**

This case example will go through the steps needed for the three-step smile, and outlined planning and consenting processes involved.

This patient presented originally wanting porcelain veneers. However he was aware of the high costs and that it would involve heavy preparation on his teeth so he decided to consider aligning his teeth. When he was shown the results possible with combined bleaching and bonding the patient decided against veneers altogether.

*Continued on page 12*

# Intraoral Device for the treatment of Sleep Apnea

By Dr. Luis Gavin

Bad sleep is the new boogeyman, threatening the overstimulated, overworked masses with disease and even an early death. Numerous scientific studies from researchers around the world have demonstrated the harmful effects of sleep deprivation on human health. When stress levels go up, people gain weight and forget things.

Without shut-eye, the body doesn't have a chance to produce enough growth hormones to build itself back up.

Sleep Apnea (SA) is a disorder that causes pauses in breathing during sleep that expose the heart to oxygen deprivation. It is common in patients with heart failure (HF) where it is associated with increased risk of hospitalizations and death.

In the treatment of snoring and sleep-disordered breathing the mandibular repositioning devices are an increasingly important instrument.

Its mechanism is based on the advancement of the mandible, which increases the dimensions of the upper airways and the air flow during sleep. Aim of this study was the investigation of the efficiency and tolerability of two types of adjustable devices: one with screw jaw lateral excursion, opening and jaw protrusion, and TAP, custom made appliances placed in 34 patients (24 men and 10 women), mean age 47 years old, undergoing an ambulatory, uncontrolled sleep screening before and after using the appliance during one month (placed onto the teeth during sleep).

**Key Words**

OSAS, sleep apnea, snoring, protrusion

**Introduction**

The OSA Syndrome (obstructive sleep apnea syndrome) is one of the clinical pictures that play an important role in the chronic diseases. It has been demonstrated that a timely diagnosis and an adequate treatment can decrease neurological consequences and have a favorable effect on the cardiovascular health status of affected patients. Clinically it consists in the obstruction of the air flow during sleep that is caused by a partial or total collapse of the upper airway structures. These respiratory obstructions are accompanied by "snoring" and frequent arousals.

Patient have a number of symptoms: daytime sleepiness and fatigue, due to a restless sleep; morning headache, loss of intellectual capacities and nighttime micturition. Sleep apnea affects approximately 7% of the adult population, but the problem may be underestimated, due to the growing global prevalence of obesity. For decades the continuous positive airway

pressure (CPAP) mask has been the treatment option of choice, but its' disadvantages, rejection and intolerance on part of the patients complicate the optimum compliance of the therapy and it has lost its therapeutic hegemony compared to other available alternatives. This resulted in the necessity of working on other solutions that are equally effective but more tolerable. New option of this new therapeutic line is based on the increasing interest in the application of oral appliances, especially of mandibular advancement devices. The use of these devices is a simple, noninvasive and completely reversible treatment option that achieves many advantages in comparison to other treatment solutions by an easy and immediate therapeutic way. These systems underwent technological developments in the last years the treatments of choice for patients who suffer from with snoring and mild or moderate sleep apnea.

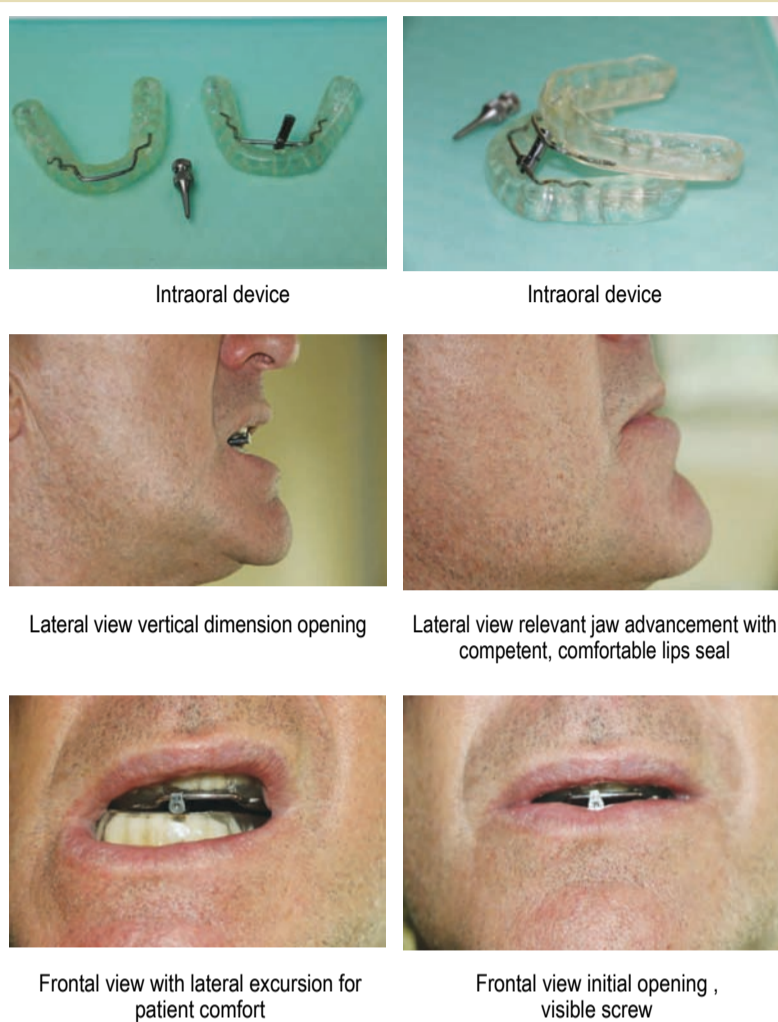
Why is important the treatment of snoring and sleep apnea? Importance is based on the following reasons:

1. High prevalence in today's society, as various studies have demonstrated in the last years. There exists an incidence of 28% for snoring, approximately 49% of adults snore frequently and 35% habitually. The prevalence of OSA ranges from 6-8% in males and 4-6% in women among the general adult, middle aged population and this numbers increase markedly with age.

2. It represents a problem in two aspects, the social that converts these patients in intolerable bed partners and the more serious clinical impact of significant morbidity. These impacts can reach a noise level of about 78-88dB (equal to the noise of a truck at high speed on a highway). The limit for hearing damages is estimated at an intensity of 75 dB. Snoring disturbs social and family relationships of patients. Its psychological pressure influences both lives, the daily routine of people who snore, as well as the every day life of people, who suffer from the noisy consequences causing problems in the partnerships.

3. Disordered breathing by sleep is very habitual and, therefore, a constant source of problems regarding health and economic impacts. Poor sleep habits aggravate the impairments of health and quality of life causing countless traffic accidents, labor accidents and accidental home injuries. The majority of these disorders lead to drowsiness in its clinical description, disabling affected patients to drive. In all countries the number of fatal accidents increases constantly.

It s the first cause in men aged between 16 and 25.



	DAM 1	DAM 2	P
Age median (Standar Deviation)	49.1 (10.5)	48.2 (9.2)	0.644
SARISFACTTION Median (Standard Deviation)	4.5 (0.7)	4.6 (0.6)	0.983
Sex (% women)	27	27	0

Table 2

	Before DAM 1	After DAM 2	P (Wilcoxon)
IAM	7.7	5.17	0.002
IR	9.17	8.23	0.001
IDO	3.93	2.93	0.01
EPW	8.6	6.07	0.006

Table 2

	Before DAM 1	After DAM 2	P (Wilcoxon)
IAM	12.3	7.17	0.001
IR	14.23	10.67	0.001
IDO	6.43	4.47	0.003
EPW	11.63	6.73	0.001

Table 3

	DAM 1	DAM 2	P
Difference IAH	-3.43	-4.17	-0.333
Differene IR	-4.23	-4.57	-0.783

Table 4

4. The access to diagnosis possibilities is the major problem facing the specialists, as only about 6 to 9% of the population with relevant OSA is diagnosed. Clinical researchers seek for diagnostic alternatives to the costly polysomnography that is currently the first diagnosis commendation (6). The OSAS is rarely known to the public. The lack of diagnosis is the main medical problem to solve.

Recent studies show that in only 7% of medical examinations of primary care, explicit references regarding possible sleep disorders are included. This incorrect diagnosis involves fatal consequences because the pathology is ignored by patients that, without being diagnosed, do not know how to justify and cope with the symptoms that they face day by day.

Continued on page 14

# Two approaches and one goal

By Dr. Eduardo Mahn

State-of-the-art CAD/CAM materials are offering clinicians the possibility of producing certain types of restorations in the dental practice using a semi-direct technique. Ceramic veneers, for example, are easy to fabricate in-office with IPS CAD Multi, without the need for glazing.

Recently developed restorative materials have opened up a myriad of exciting possibilities for dental practitioners. In the restoration of anterior teeth, clinicians have to select the most appropriate material for the case at hand on the basis of specific criteria. In situations where teeth show signs of erosion, abrasion, abfraction or a combination of these phenomena, practitioners will tend towards using ceramics or composite resins, depending on how much intact tooth structure remains available. Traditionally, composites are used for Class III, IV and V defects. However, ceramic veneers are preferred in cases where a large amount of tooth structure is missing or a major change is planned (e.g. smile makeover).

### The challenge

When two central incisors need esthetic enhancement, the choice of approach is not so clear. Irrespective of the material used a minimally invasive route involving very little preparation of the tooth structure can be taken nowadays due to the high strength of modern materials (e.g. lithium disilicate glass-ceramic). Nevertheless, it is important to remember that minimal preparation is an option, only if the teeth are properly aligned. As long as the desired changes of the tooth shape and shade are small, preparation can be limited to the enamel.

In many cases, however, orthodontic treatment is needed before the tooth position and/or shape can be optimized by means of restorative procedures. This minimally invasive approach requires the dental practitioner to convince the patient of the necessity of undergoing preliminary orthodontic treatment.

### The solution

It is our aim to remove as little of the tooth structure as possible in every case that we treat. With modern materials such as lithium disilicate or leucite-reinforced ceramics, we can confidently press or mill veneers that are as thin as 0.5 mm and even 0.3 mm. One of the main advantages offered by this type of ceramic is its wide range of applications. Until a few years ago, the treatment with indirect restorations required at least two appointments.

Ceramic materials such as IPS Empress CAD allow dental practitioners to produce polychromatic

monolithic veneers and crowns in less than one hour, without having to glaze them. Nonetheless, many dentists still believe that dental technicians with their well-honed manual skills produce better esthetic results than a machine, and they do not see the need to embrace digital technology. As a result of this point of view and the high acquisition costs of the milling machines some clinicians are reluctant to invest in this technology. On the basis of the present clinical case study we would like to highlight the following aspects: the importance of having the right treatment plan, the possibilities currently available for the fabrication of veneers, the potential of the press and CAD/CAM techniques and the latest improvements made in the field of cementation.

### Clinical case

#### Patient history

A thirty-one-year-old female patient came to our office because she was dissatisfied with her anterior teeth. She complained about the misalignment of the upper and lower central incisors (Fig. 1). A detailed clinical examination revealed that the composite restorations in these teeth were defective. As a result of erosion, a considerable amount of tooth structure had been lost. In addition, the misalignment of tooth 21 and 41 in particular was quite obvious. The treatment plan presented to the patient included initial orthodontic treatment followed by minimal preparation of the two central incisors for two ceramic veneers. The patient was subsequently referred to an orthodontist for treatment. Unfortunately, it took more than a year before she presented to the practice again. At this consultation, we were quite surprised to find that the two central incisors had been restored with poorly finished direct composite veneers (Fig. 2). Many clinicians simply underestimate the challenging nature of this type of restoration, and this was a case in point. In addition to preventing any contamination of the working field, the clinician must also accomplish the arduous task of creating an appropriate emergence profile, proper contours and contact areas and producing a suitable micro and macro-texture, and all this within a single appointment.

#### The treatment

The composite veneers had to be removed and replaced with new ones. In this particular case, the advantages of using the indirect technique were obvious. The patient agreed to have two ceramic veneers made for her. For this purpose impressions were taken and a master cast was produced. This working model provides the dental technician with the opportunity to evaluate the situation in detail. He or

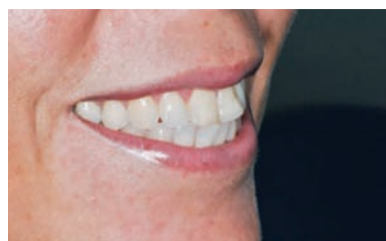

Fig 1: Initial situation: The patient was referred to an orthodontist.

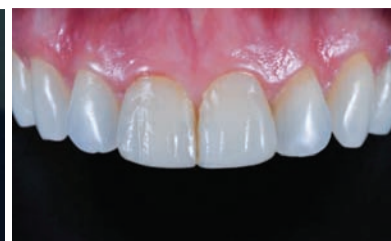

Fig 2: One year later when the patient returned to the practice, the teeth showed unsatisfactory composite veneers.

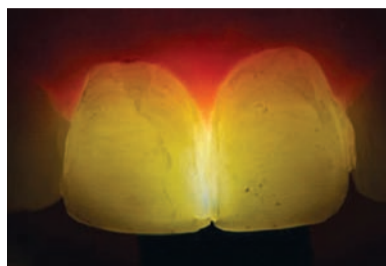


Fig 3: The veneers were removed and the teeth were transilluminated to identify any composite residue.

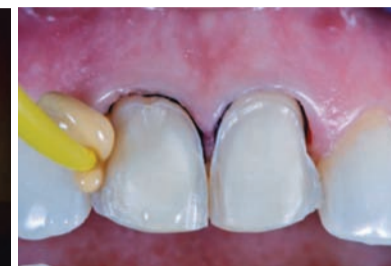

Fig 4: The two-cord technique was used for the impression. The retraction cords remained in the sulcus.

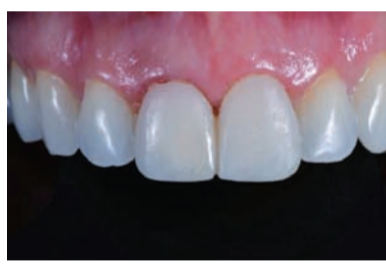

Fig 5: Temporary restoration



Fig 6: Try-in of the IPS e.max Press HT A1 veneers (fabricated in the laboratory)



Fig 7: Try-in of the polished IPS e.max CAD A1 veneers (fabricated in the dental office)

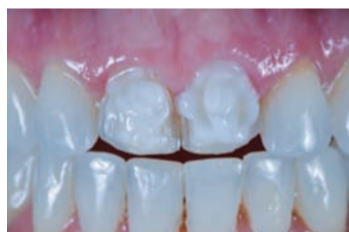

Fig 8a: Try-in of the veneers with a light try-in paste (Light+)

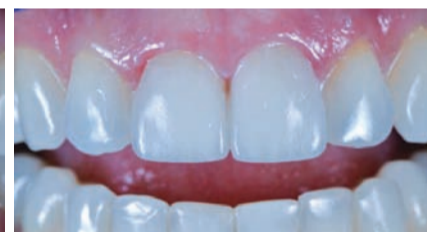

Fig 8b: Try-in of the veneers with a light try-in paste (Light+)

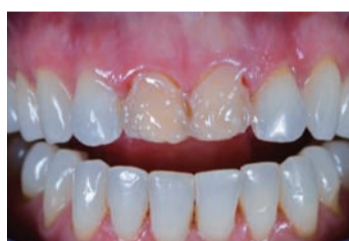

Fig 9a: Try-in of the veneers with a dark try-in paste (Warm+)

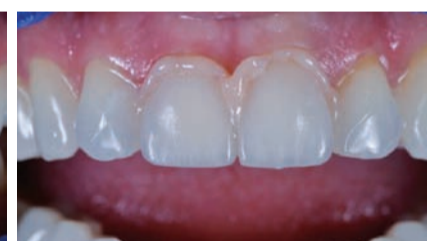

Fig 9b: Try-in of the veneers with a dark try-in paste (Warm+)

she has the time to think about possible ways of correcting the misalignment. Dentists do not have this "luxury" of time when they are treating a patient in the dental chair. They have to finish the restorations as quickly as possible in order to prevent contamination of the treatment field and keep chair time to a minimum for the comfort of the patient. In the present case, an additional hurdle had to be overcome: Any composite material that might have remained on the tooth structure had to be clearly identified and carefully removed without damaging the healthy tooth structure. Transillumination with white LED light came in useful for this purpose (Fig. 3). Next, the teeth were prepared, retraction cords were placed and an impression (Virtual) was taken (Fig.

4). The patient was provided with a temporary restoration, which was made with a temporary crown and bridge material (Telio® CS C&B, shade A1) and cemented with a dual-curing luting composite (Telio CS Link) (Fig. 5).

#### Fabrication of the restorations

Two different routes were pursued in the fabrication of the veneers. We instructed our lab technician to make two ceramic veneers using the press technique with IPS e.max Press (shade HT A1, stained). At the same time, we milled two ceramic veneers with our in-office CAD/CAM machine using an IPS Empress CAD Multi block (shade A1). The veneers made in the dental office were not glazed, just polished. Figures 6 and 7 allow the

Continued on page 14



Under the Patronage of  
**H. H. Sheikh Hamdan Bin Rashid Al Maktoum**  
Deputy Ruler of Dubai, Minister of Finance  
President of the Dubai Health Authority

تحت رعاية  
سمو الشيخ حمدان بن راشد آل مكتوم  
نائب حاكم دبي، وزير المالية  
رئيس هيئة الصحة بدبي

## مؤتمر الإمارات الدولي لطب الأسنان ومعرض طب الأسنان العربي 21<sup>st</sup> UAE INTERNATIONAL DENTAL CONFERENCE & ARAB DENTAL EXHIBITION

# إيكد AEEEDC DUBAI

Education & Innovation Transfer

TUE | WED | THU | 2017  
7 | 8 | 9 | FEBRUARY

مركز دبي الدولي للمؤتمرات والمعارض  
Dubai International Convention & Exhibition Centre

Organised by



Strategic Partner



Stay connected

BlackBerry  
PIN: 286FC1C7



@AEEEDCDubai



AEEEDCDubai



AEEEDC Dubai



AEEEDC\_Dubai



INDEXHolding1928

[www.aeedc.com](http://www.aeedc.com)

INDEX® Conferences & Exhibitions Organisation Est.

Dubai Healthcare City, Ibn Sina Medical Complex #27, Block B, Office 203 | P.O. Box: 13636, Dubai, United Arab Emirates  
Tel: +971 4 3624717, Fax: +971 4 3624718 | E-mail: info@aeedc.com, Website: www.index.ae