

implants

international magazine of oral implantology

2²⁰¹⁷



research

Immediate restoration in the digital workflow—Part I

case report

Sinus elevation with short implant

industry

Augmentation and defect filling in oral surgery



BE MORE

We offer you more effective solutions with;



T6 much more implant

- *more esthetical*
- *more comfy*
- *more user-friendly*
- *more simple*
- *more durable*
- *more economic*



www.nucleoss.de

DGZI— globally engaged



Dr Rolf Vollmer

Dear colleagues,

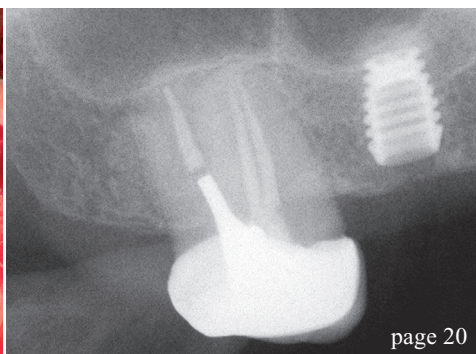
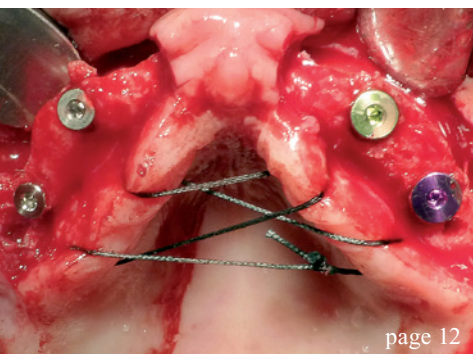
The first half of this year had scheduled numerous international events in the field of implantology in which we as the German Association of Dental Implantology (DGZI e.V.) participated representing our members and readers of this journal. Especially worth mentioning among those events is the annual meeting of the American Academy of Osseointegration (AO) with more than 2,500 participants. Attending the impressive congress with a delegation of DGZI members, we maintained our existing contacts and also made some new ones. The international exchange of expertise in the field of implantology is an essential part of our work as expert association and ensures a high standard of quality in practice and teaching while at the same time providing an important basis for the scientific conception of our annual DGZI congresses. As a result of our personal contacts and conversations, internationally renowned speakers as well as young and ambitious colleagues are encouraged to participate and engage. Referring to the exchange of expertise, Dr Pollack, AO President, said to the participants of this year's AO congress: "The majority of what we take home from meetings like this arises from sharing ideas and problems with our colleagues. Sitting in the auditorium next to someone who is practicing at the other end of the country or even the world, someone who has different perspectives and preconditions and thus applies different procedures, is eye opening and presents a variety of possibilities."

In addition, the 37th International Dental Show (IDS) in Cologne was another major event for all involved in the dental community. On the one hand, there seems to be no other event like the IDS offering such a broad overview of current technologies and trends in the area of implantology. As could be seen in Cologne, the promises that have been made over the last couple of years concerning the digital workflow in guided surgery in implantology are slowly being fulfilled; more and more integrated measures enter the market. On the other hand, the IDS constitutes the best place to meet old and new interlocutors for joint projects. With the help of OT medical, our long-term industrial partner and main sponsor of our annual congresses, the DGZI were able to present a point of contact at this year's IDS. For this we are especially thankful!

One last word regarding our scientific activities: On the occasion of the 47th annual congress on 29 and 30 September 2017 in Berlin, we once again present our DGZI awards. This includes the DGZI Implant Dentistry Award 2017 (5,000 Euro) as well as the DGZI Thesis Award 2017 (2,000 Euro). The closing date for both awards is 31 May 2017. Further details and conditions of participation are available at our website www.dgzi.de. I now wish you a pleasant and informative reading of this issue of **implants international magazine of oral implantology**.

Yours

Dr Rolf Vollmer
First Vice President and Treasurer of the German Association of Dental Implantology



editorial

- 03 **DGZI**—globally engaged
Dr Rolf Vollmer

research

- 06 **Immediate** restoration in the **digital** workflow
José Eduardo Maté Sánchez de Val &
José Luis Calvo Guirado

case report

- 12 **Implant-prosthesis** treatment
in case of **total edentulism**
Prof. Massimo Pasi
- 20 **Sinus elevation** with short implant
Prof. Dr Mauro Marincola, Prof. Dr Rolf Ewers,
Prof. Giorgio Lombardo & Prof. Miguel Simancas
Pallares

industry

- 26 **Augmentation** and **defect filling** in oral surgery
Henriette Lerner
- 32 Vertical bone **augmentation** procedures—
Part II
Prof. Dr Florian G. Draenert, M.D., D.D.S., Ph.D.

special

- 38 How **safe** is your implant?
Dr Dirk U. Duddeck

interview

- 40 Become a **champion!**
Katrin Maiterth

events

- 42 2017 **AO** Annual Meeting Orlando
Dr Rolf Vollmer

news

- 44 **manufacturer news**
- 48 **news**

about the publisher

- 50 imprint



Cover image courtesy of NucleOSS Europe GmbH
www.nucleoss.com

a perfect fit™

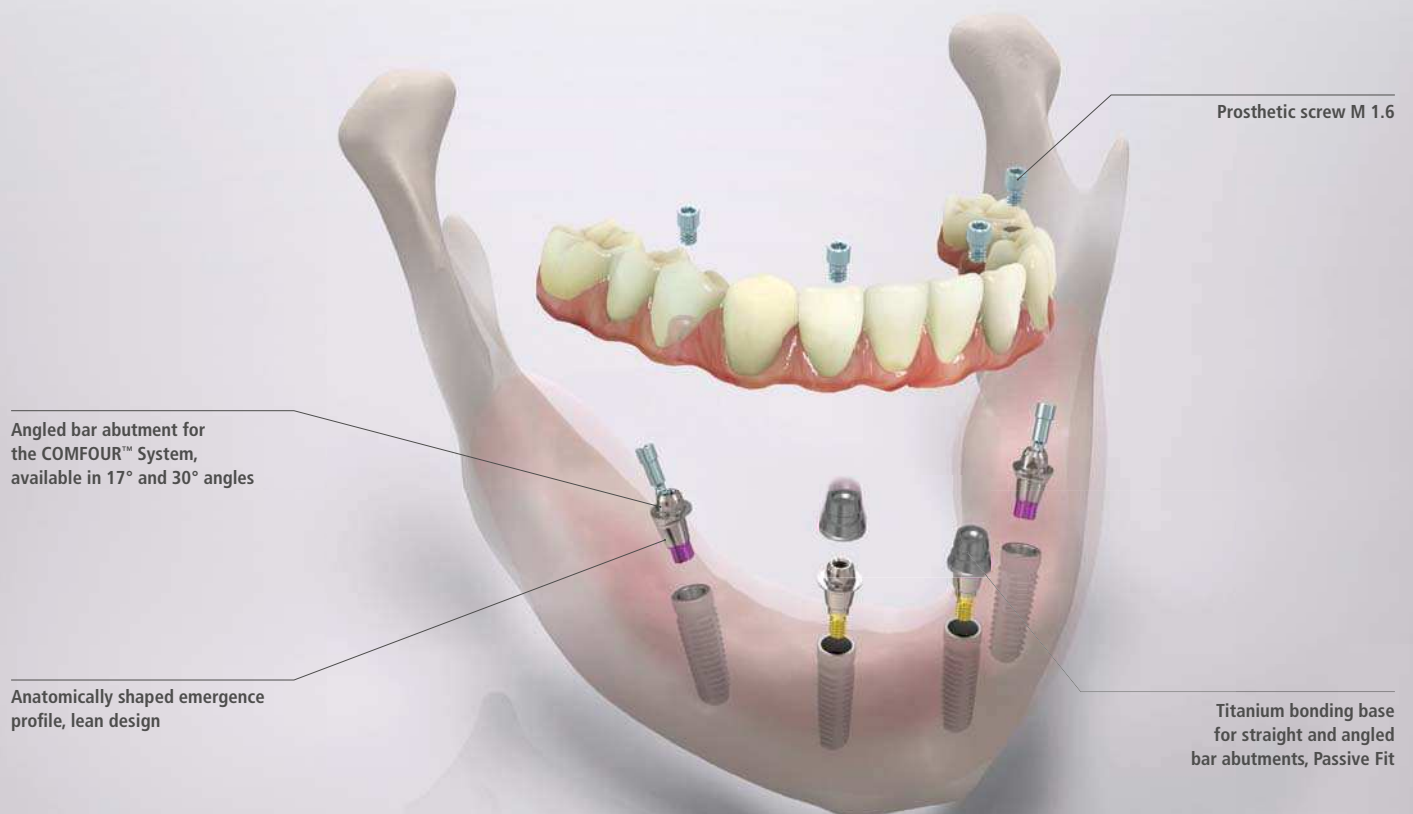camlog

THE NEW COMFORT CLASS.

The COMFOUR™ Abutment System for occlusal screw-retained restorations is an ideal addition to the CAMLOG® and the CONELOG® Implant System. With the COMFOUR™ System, you can offer your edentulous patients the option of an immediate, comfortable and permanent denture on four or six implants – and thus a considerable gain in quality of life. www.camlog.com

CAMLOG®
SYSTEM

CONELOG®
SYSTEM



Aligning tool



Scanning cap



Titanium cap



Flexible handle

COMFOUR™ offers you a range of options to overcome the challenges you face in your implant practice, making them easier while saving time.

Immediate restoration in the digital workflow

Part I

Authors: José Eduardo Maté Sánchez de Val & José Luis Calvo Guirado, Spain

Endosseous implants have consistently achieved high success rates in partially and completely edentulous patients. Clinicians have therefore begun to offer selected patients immediate and early implant placement options. The long-term success of immediately loaded implants has been investigated in animals^{1,2} and humans,³ with encouraging results. However, most of the studies were performed with implants placed in the anterior mandible, where primary implant stability is easily achieved.

In the anterior maxilla, clinicians seeking to load implants immediately must be concerned not only about achieving adequate implant stability, but also about fulfilling patients' desires for aesthetic results that resemble the natural dentition. To achieve this, it is essential to maintain as much of the bone height around the implant neck as possible, controlling the biologic width.⁴

Bone loss around the implant always occurs when an abutment is connected to a dental implant at the crestal level. It has been demonstrated that the gap between the implant and the abutment has a direct effect on bone loss, regardless of whether the two parts are connected at the time of integration of the implant or later.⁵ This phenomenon occurs whether the implant is loaded or not and ap-

pears to be unrelated to the type of implant surface.^{5,6} Hermann et al. demonstrated that crestal bone remodels to a level about 2.0 mm apical to the implant-abutment junction (IAJ),^{5,7,8} while Lazzara and Porter reported crestal bone levels about 1.5 to 2 mm below the IAJ at one year after restoration.⁹ Tarnow et al. documented a horizontal component that results in 1.3 to 1.4 mm of resorption from the IAJ to the bone in a horizontal direction.^{10,11} When the biologic width is in the wake of such osseous changes, the soft-tissue architecture, including the appearance of the papillae, is affected. The interproximal bone influences the interdental papillae by acting as a guidepost for the soft-tissue contours.

In addition to several ideas aimed at limiting crestal bone resorption, the concept of platform switching appears to be promising. Platform switching refers to the use of a smaller-diameter abutment on a larger-diameter implant collar. This type of connection shifts the perimeter of the IAJ inward toward the central axis of the implant.^{12,13} The time limitation in implant treatments is an important bias when it comes to planning and developing rehabilitation therapies. In this sense, the inclusion of new materials that allow for immediate loading in a single session without having to replace prosthetic components facilitate optimal results in terms of gingival attachment and minimize

peri-implant bone loss after prosthetic abutments have been manipulated. Ceramically reinforced PEEK is of great interest as it allows a single attachment to be retained in place throughout the entire treatment and avoids handling-related overload. Its mechanical and physical properties have been tested in animal experiments and in humans, showing the material to be ideal for one-step X protocols.



Fig. 1: Implants and abutments used (left to right). blueSKY implant, SKY esthetic abutment titanium, SKY elegance abutment.

The physical and mechanical properties of the prosthetic components govern the success of the long-term restoration. Resistance to occlusal loads such as masticatory movements and para-function should be adequate to allow denture survival. The modulus of elasticity and bending resistance of the material should be adequate to prevent undesirable fractures or micromovements.¹³

Furthermore, components used require a high degree of biocompatibility to prevent the occurrence of abnormal tissue reactions such as initial peri-implant inflammation and mucositis, which may result in more severe complications such as peri-implantitis.¹⁴ Polyetheretherketone (PEEK) is a polymer from the polyaryletherketone family, a relatively newly developed family of high-temperature thermoplastic polymers having of an aromatic backbone interconnected by ketone and functional ether groups.¹ In medicine, PEEK has been found to be an excellent substitute for titanium in orthopaedic applications^{15,16} and has been used in dental implants, provisional abutments, implantsupported bars, or clamp material in removable dentures.^{17,18} PEEK is biocompatible and

has a natural tooth-coloured appearance, unlike metal reconstructions.

Ceramicly reinforced PEEK materials were developed to improve the mechanical properties and the colour of dental restorations. One of these materials is BioHPP (bredent medical, Senden, Germany). In abutments, the BioHPP is directly injectionmoulded to a titanium base and forms a monolithic hybrid abutment called "elegance" abutment, with a screw seat in titanium for long-term stability plus a resilient body made of ceramicly reinforced PEEK.

To shorten procedures and eliminate intermediate prosthetic steps, digital technologies were developed that allow the intraoral scanning of models and attachments with a high degree of precision and reproducibility. Chairside CAD/CAM systems such as CEREC (Sirona) allow direct scanning of the abutments and the realization of immediate crowns. The ceramicly reinforced hybrid abutments with a PEEK body and titanium base are easily scannable, yielding restorations of high quality with a good prognosis. Problems caused by removing and reinserting different

AD

47TH DGZI INTERNATIONAL ANNUAL CONGRESS

29./30. September 2017
Berlin – Maritim Hotel

ONLINE CONGRESS PROGRAMME



www.dgzi-jahreskongress.de

Fax Reply
+49 341 48474-290

I would like to receive further information on the 47TH DGZI INTERNATIONAL ANNUAL CONGRESS

Title, Surname, Name

E-mail address (for digital programme)

Stamp

IM 2/17

Holbeinstraße 29 · 04229 Leipzig · Tel.: +49 341 48474-308 · event@oemus-media.de

Theme:

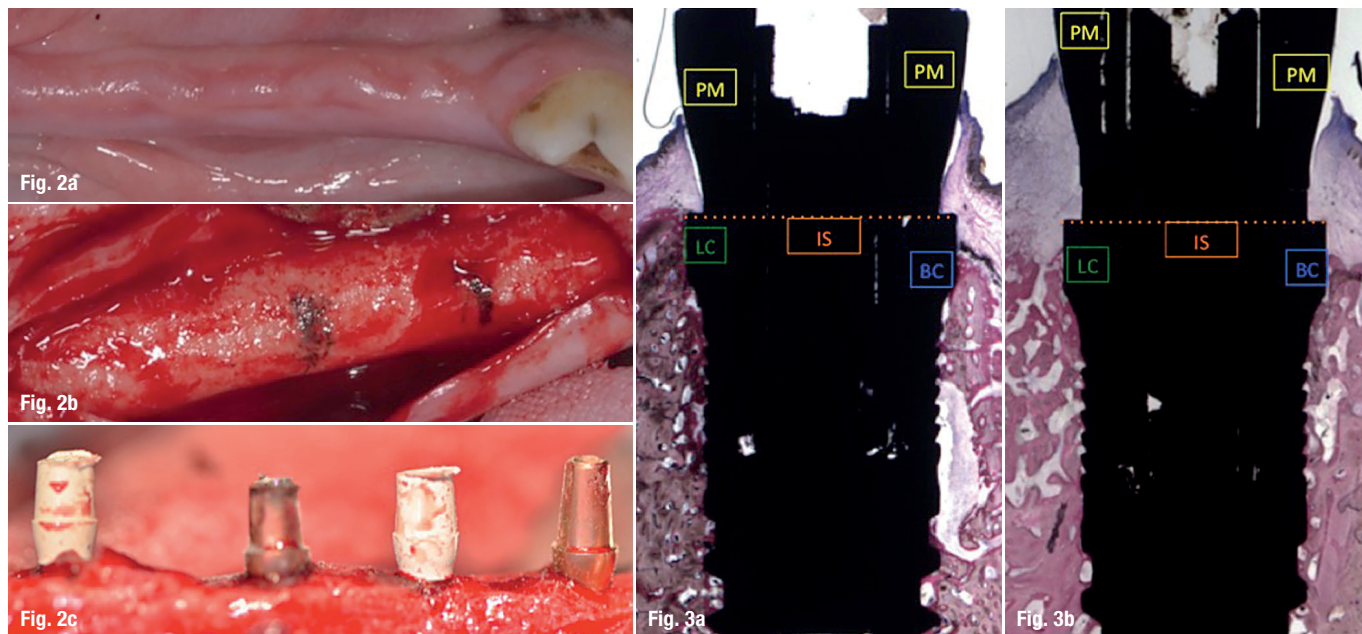
Does biology still play a role?

Organiser/Scientific chair:

Prof. (CAI) Dr. Roland Hille

Organisation:

OEMUS MEDIA AG
Holbeinstraße 29 | 04229 Leipzig
Tel.: +49 341 48474-308 | Fax: +49 341 48474-290
event@oemus-media.de | www.oemus.com



Figs. 2a–c: Animal study protocol with immediate loading.

Figs. 3a & b: Linear measurements (in mm): peri-implant mucosa (PM), buccal bone crest (BC), lingual bone crest (LC), top of the implant shoulder (IS), bone crest (BC), distance from the implant shoulder at buccal bone crest (IS-BC), distance from the implant shoulder at lingual bone crest (IS-LC).

prosthetic components—such as loss of soft tissue or early marginal bone loss—are reduced or eliminated. This article demonstrates the reliability of the single-session protocol using digital methods for scanning and producing crowns complemented with platform switching and evaluates the peri-implant soft-tissue seal.

Material and methods

Animal protocol

An animal experiment was conducted to evaluate an implant placement protocol with immediate loading using PEEK and CEREC and to assess the peri-implant soft tissue. Forty-eight blueSKY implants (bredent medical) were placed in healing bone. Thirty-two SKY elegance abutments (bredent medical) were used in the test group and sixteen titanium abutments in the control group (Fig. 1).

A randomization scheme was generated using the website www.randomization.com. The Ethics Committee for Animal Research of the University of Murcia, Spain, approved the study protocol, which followed the guidelines established by Directive 2010/63/EU on the protection of animals used for scientific purposes. Six American Foxhound dogs approximately one year of age, each weighing approximately 13–15 kg, were used in the study.

Day 0 (first stage)

The animals were pre-anaesthetized and taken to the operating theatre where, at the earliest opportunity, an intravenous catheter was inserted into the cephalic vein and propofol was infused at the rate of 0.4 mg/kg/min as a slow constant-rate infusion. Conventional dental infiltration anaesthesia

was administered at the surgical sites. Premolar and molar extractions (P2, P3, P4, M1) were performed in both mandibular quadrants of each dog.

Day 60 (second stage)

After drilling, the sequence of placement of four implants by hemi-mandible was randomly planned (using randomization as mentioned). The implants were inserted in healed bone at the sites of the mandibular premolars and molars (P2, P3, P4, M1), with an insertion torque of 30 Ncm or more (Figs. 2a–c).

Analysis (eight weeks after implantation)

- Histological and histomorphometric analysis of the bone-to-implant contact area (BIC) with linear measurements in millimetres: peri-implant mucosa (PM), buccal bone crest (BC), lingual bone crest (LC), top of the implant shoulder (IS), bone crest (BC), distance from the implant shoulder at buccal bone crest (IS-BC), distance from the implant shoulder at lingual bone crest (IS-LC) (Figs. 3a & b).
- Primary stability was evaluated by measuring the ISQ by Osstell Mentor at the time of placement.
- The radiological analysis was performed using a standardized protocol.

Human protocol

The research protocol called for recruitment of subjects among patients referred to the Department of General Dentistry, University of Murcia, Spain, during an 18-month period. All those in need of anterior oral rehabilitation that would include single-implant placement were invited to take part in the study, which was overseen by the institutional review board.



SiMPLÉ

SiMPLÉ