

implants

the international C.E. magazine of oral implantology

3²⁰¹³



c.e. article

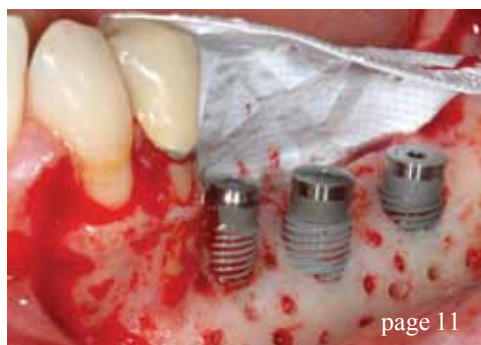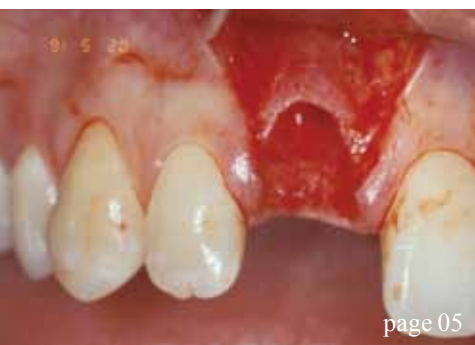Immediate implant placement
and conventional loading of a
maxillary central incisor

events

Technology and biology
converge in the
'Valley of the Sun'

industry

Intra-Lock reveals
BLOSSOM design



| c.e. articles

- 05 Immediate implant placement and conventional loading of a maxillary central incisor
_Jay R. Beagle, DDS, MSD
- 11 Surgical predictability of vertical GBR in the posterior mandible: flap design, management and passivation of soft tissues as principal keys for success
_Ronda Marco, DMD, and Claudio Stacchi, DDS

| events

- 16 Technology and biology converge in the Valley of the Sun
- 18 ICOI to host its World Congress XXX in Istanbul, Turkey
- 22 Registration now open for the 7th International Congress on 3D Dental Imaging

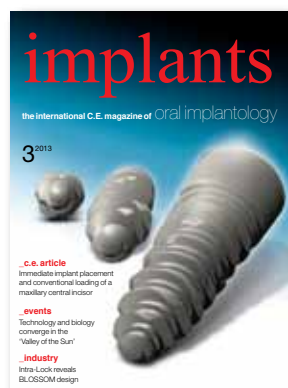| industry

- 24 Reduce treatment time with digital dentistry
_Dean H. Salki, DDS, and Grant Bulls, director of Implant R&D and digital manufacturing


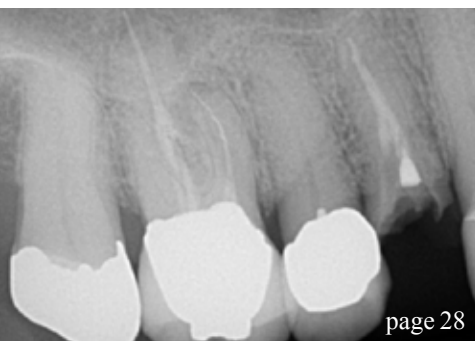
- 28 Investing in cone beam CT ... Can you afford not to?
_Blake Julian, DDS
- 32 Fascinating ergonomics
_W&H staff
- 34 Intra-Lock reveals BLOSSOM design
_ Intra-Lock staff

| about the publisher

- 38 _imprint



| on the cover
Cover image provided
by Intra-Lock






**DENTSPLY Implants is a leading provider
of comprehensive implant solutions that
allow for successful long-term outcomes.**

The comprehensive offering includes the ANKYLOS®, ASTRA TECH Implant System™ and XiVE™ implant lines, digital technologies such as ATLANTIS™ patient-specific abutments, Symbios™ regenerative bone products and professional development programs.

We are dedicated to continuing the tradition of DENTSPLY International, the world leader in dentistry with 110 years of industry experience, by providing high quality and groundbreaking oral healthcare solutions that create value for dental professionals, and allows for predictable and lasting implant treatment outcomes, resulting in enhanced quality of life for patients.

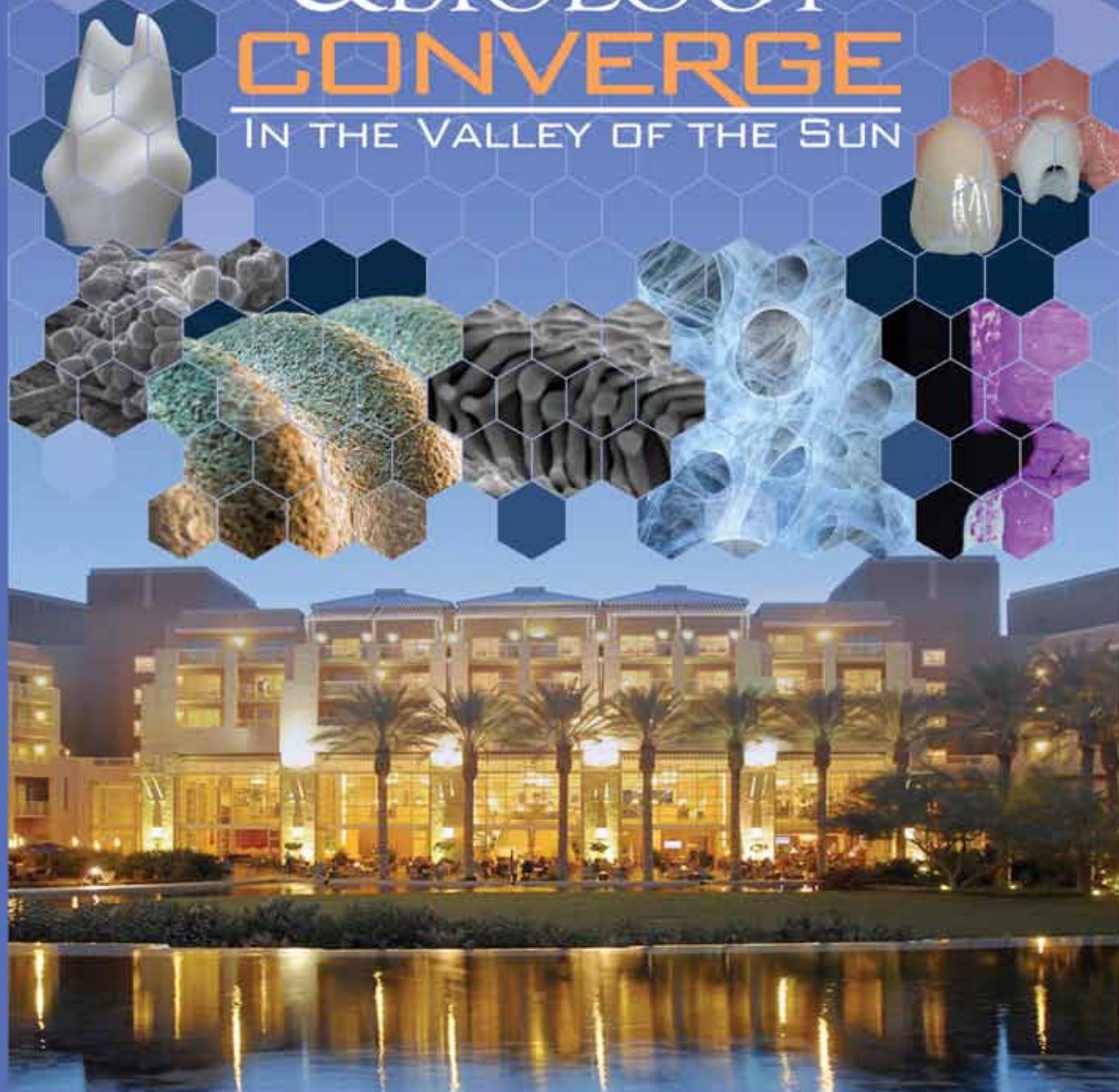
We invite you to join us on our journey to redefine implant dentistry.
For more information, visit www.dentsplyimplants.com.

ANKYLOS® **ASTRA TECH**
IMPLANT SYSTEM **XiVE™**  **symbios** **ATLANTIS™** **Facilitate™** **EXPERTEASE™**

www.dentsplyimplants.com

PHOENIX, ARIZONA
OCTOBER 23-26 **2013**

TECHNOLOGY
& BIOLOGY
CONVERGE
IN THE VALLEY OF THE SUN



AMERICAN ACADEMY OF IMPLANT DENTISTRY
62nd AAID Annual Meeting | aaid.com
Practical Education for the Practicing Implant Dentist

ADA CERP® Continuing Education
Recognition Program

American Academy of Implant Dentistry is an ADA CERP Recognized Provider.
ADA CERP is a service of the American Dental Association to assist dental
professionals in identifying quality providers of continuing dental education.
ADA CERP does not approve or endorse individual courses or instructors, nor
does it imply acceptance of credit hours by providers of continuing education.
American Academy of Implant Dentistry designates this activity for CE continuing
education credit.



Academy of General Dentistry
Approved CDE Program Provider
PACEDENTIST CDE
Approved Provider for CDE activities
by a CDE in clinical practice
of dentistry or related
June 1, 2012 to May 31, 2013
Florida: 124 71 0000

Immediate implant placement and conventional loading of a maxillary central incisor

Author_Jay R. Beagle, DDS, MSD

This 30-year-old caucasian female presented to the office, having been referred for the treatment of tooth #8. The patient's chief concern at the initial visit related to the tooth's pink discoloration.

Upon clinical examination, it was discovered that tooth #8 had a previous history of trauma, and it was surmised that the clinical crown had become noticeably pink in color as a result of internal resorption (Fig. 1). This diagnosis was confirmed radiographically, indicating a large radiolucency involving the central and distal portions of the clinical crown (Fig. 2).

It was determined that restoration of this tooth was not possible, and therefore, extraction was indicated. The presence of a mid-line diastema, which the patient wanted to reproduce, directed the treatment plan for tooth replacement utilizing a dental implant.

Her medical and dental health, including a periodontal and occlusal analysis, identified her as a good candidate for dental implant surgery and restoration.

Although she presented with a high lip line and a thin-gingival phenotype, an immediate placement technique with a conventional restorative loading protocol was recommended to accelerate her rehabilitation.

The clinical and radiological findings, in combination with the patient's treatment expectations, led to an esthetic risk profile summing up to a medium esthetic risk, as per the specifications delineated by Martin et al 2007.

Prior to the initiation of the dental implant surgery, mounted diagnostic study casts were obtained and a surgical guide was fabricated.

The immediate implant surgical procedure for tooth #8 was carried out as described by Beagle 2006 (Figs. 3–7).

Excellent primary stability was obtained using a 12 mm 3.3–4.8 Regular Neck TE Straumann dental implant (Figs. 8, 9).

_c.e. credit part I

This article qualifies for C.E. credit. To take the C.E. quiz, log on to www.dtstudyclub.com. Click on 'C.E. articles' and search for this edition (Implants C.E. Magazine — 3/2013). If you are not registered with the site, you will be asked to do so before taking the quiz. You may also access the quiz by using the QR code below.

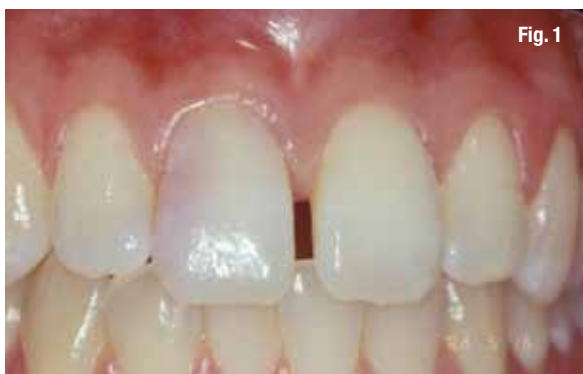

Fig. 1

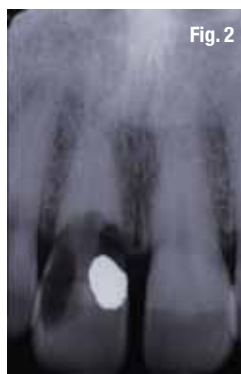

Fig. 2

Fig. 1: Caucasian female, age 30, presents with internal resorption of tooth #8. A highly scalloped, thin type I gingival phenotype is clinically evident. (Photos/Provided by Dr. Jay R. Beagle)

Fig. 2: Periapical radiograph of teeth #8 and #9 illustrating the resorption defect associated with tooth #8.

Fig. 3: Buccal view of initial incision.

Fig. 4: Occlusal view of initial incision.

Fig. 5: Buccal view following preparation with 2.2 mm twist drill.

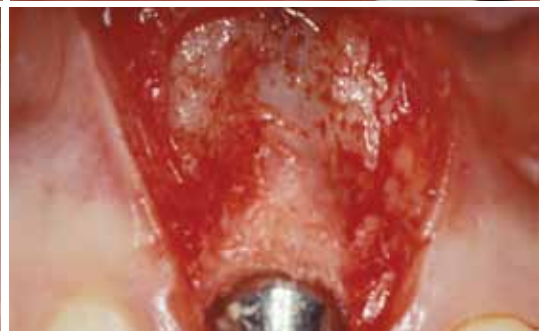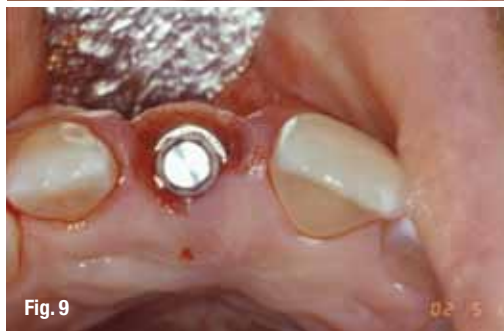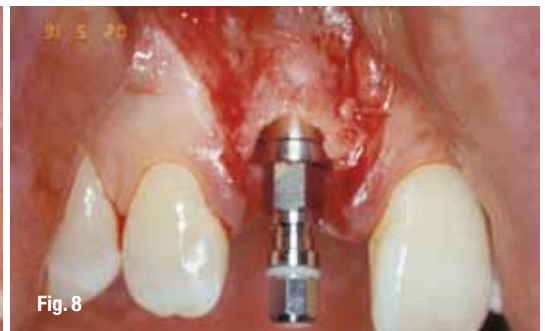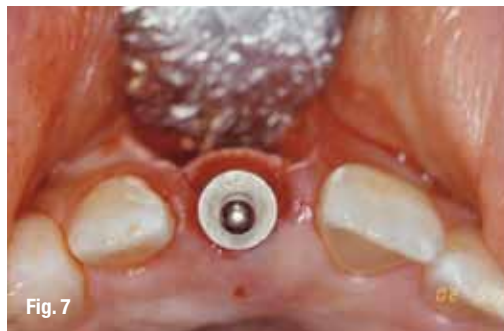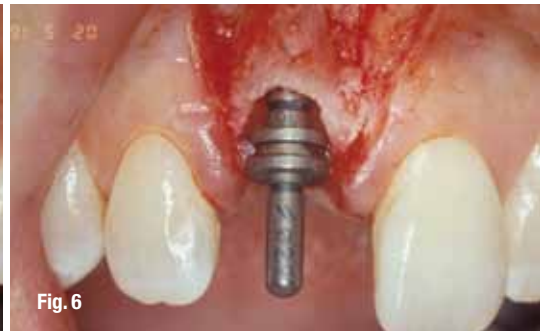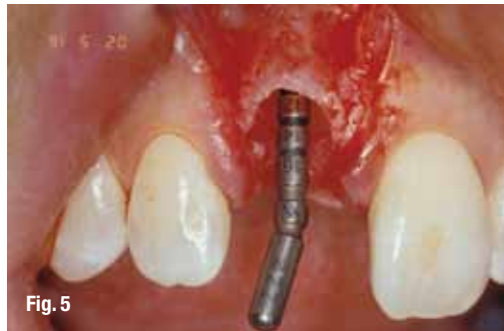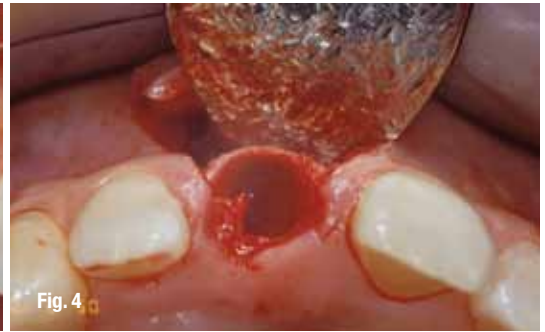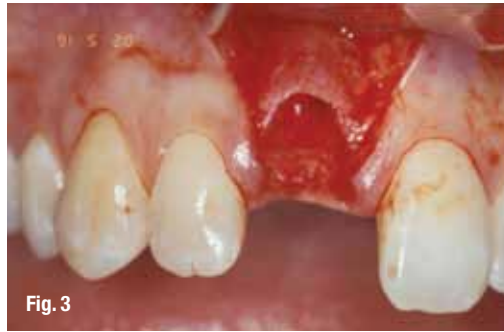Fig. 6: Buccal view following preparation with 2.8 mm twist drill.

Fig. 7: Occlusal view following preparation with 2.8 mm twist drill.

Fig. 8: Placement of a 12 mm 3.3-4.8 TE Straumann dental implant with pre-mount attached indicating the correct mesial-distal relationship, as well as the correct occlusal-cervical relationship.

Fig. 9: Occlusal view of the TE Straumann dental implant with the pre-mount attached indicating the correct buccal-lingual position.

Fig. 10: Buccal view of the placement of a 3.5 mm beveled healing cap.



Grafting of the horizontal defect dimension and thin labial plate was performed using autogenous bone and a resorbable collagen membrane (Figs. 10, 11).

A semi-submerged flap closure was chosen to enhance the final positioning of the peri-implant soft tissues, and a periapical radiograph was taken immediately following surgery (Figs. 12–14).

Ten weeks following implant surgery, a small gingivectomy was performed to gain access to the beveled healing cap (Figs. 15, 16).

A synOcta provisionalization coping was attached to the implant (Figs. 17, 18), and a self-curing acrylic

resin provisional restoration was fabricated and marginated using a synOcta laboratory analog as described by Higginbottom and coworkers 2004 (Figs. 19, 20).

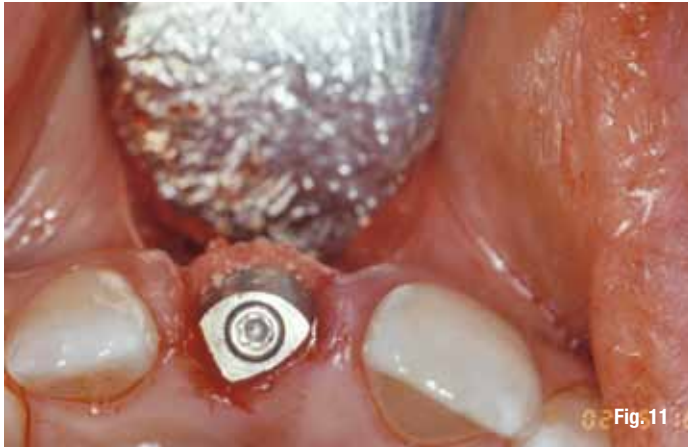

Fig. 11

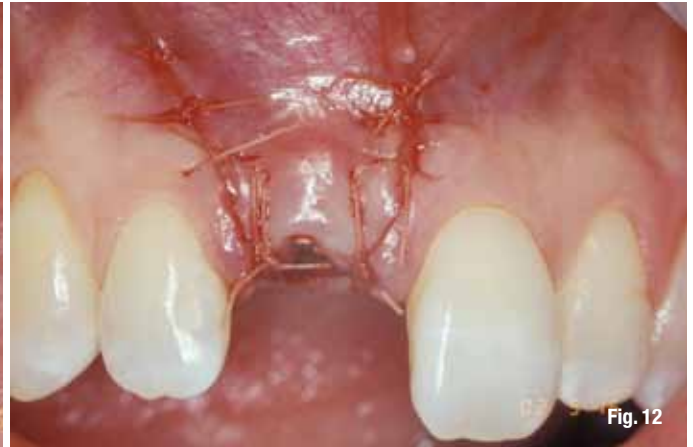

Fig. 12

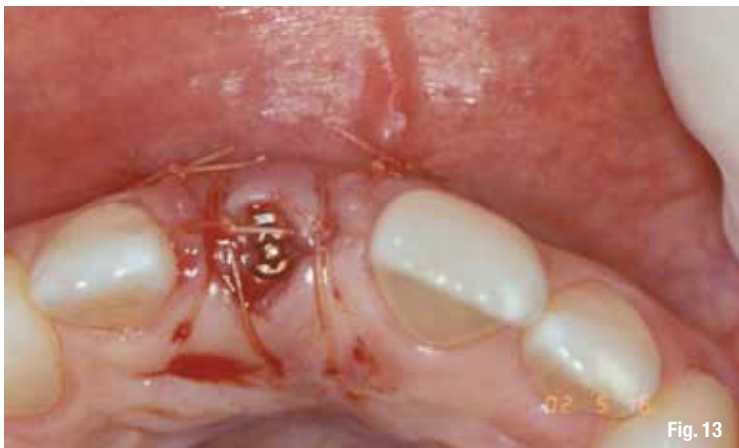

Fig. 13

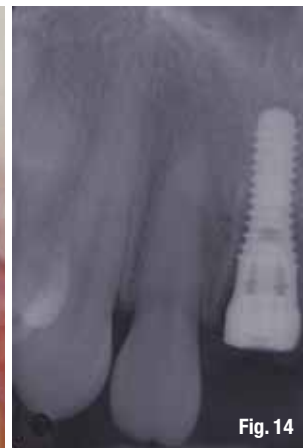

Fig. 14

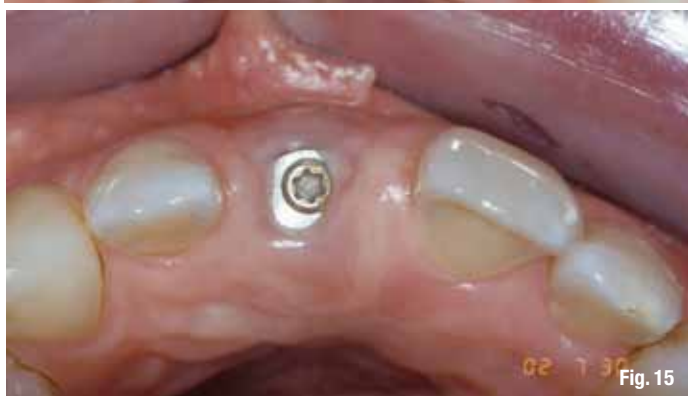

Fig. 15

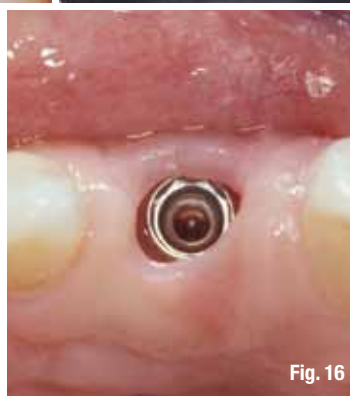

Fig. 16

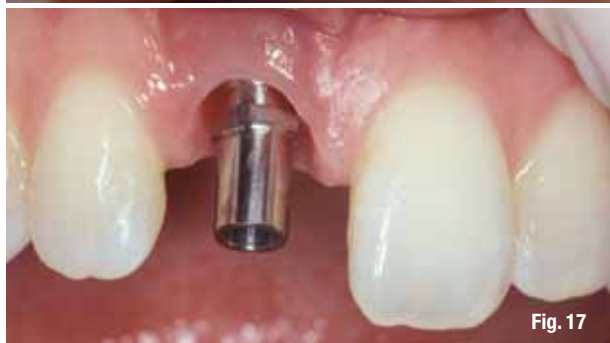

Fig. 17

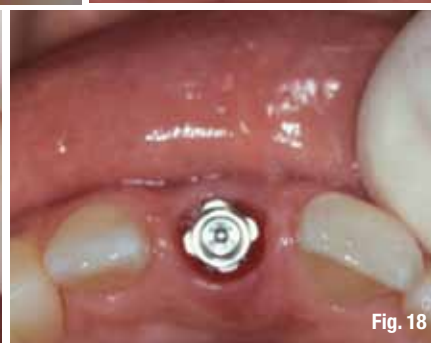

Fig. 18

Fig. 11: Occlusal view illustrating the addition of an autogenous bone graft into the horizontal defect dimension (HDD) along the buccal surface.

Fig. 12: Buccal view of flap closure using 5.0 vicryl suture.

Fig. 13: Occlusal view of flap closure using a semi-submerged closure technique.

Fig. 14: Periapical radiograph taken immediately following surgery.

Fig. 15: Occlusal view of surgical site following ten weeks of healing.

Fig. 16: Removal of healing cap following a minor gingivectomy procedure.

Fig. 17: Placement of a synOcta provisionalization coping.

Fig. 18: Occlusal view of synOcta provisionalization coping.

The peri-implant soft tissues were allowed to mature around the provisional restoration for four weeks prior to final impression (Figs. 21 – 23).

Following connection of the analog to the impres-

sion coping, a master cast was fabricated to reproduce the implant location three-dimensionally. The master cast was then utilized to aid in the creation of a screw-retained cast-metal crown framework using

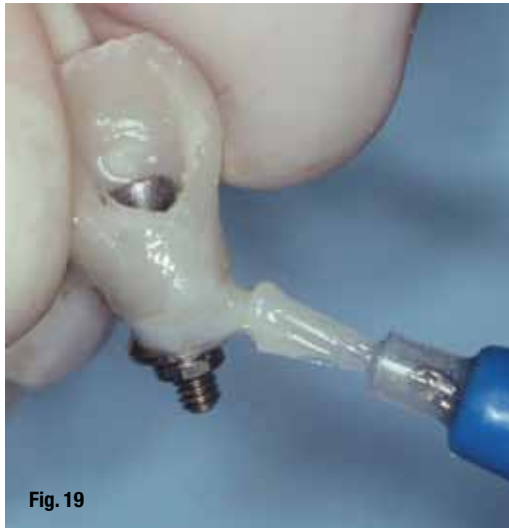

Fig. 19

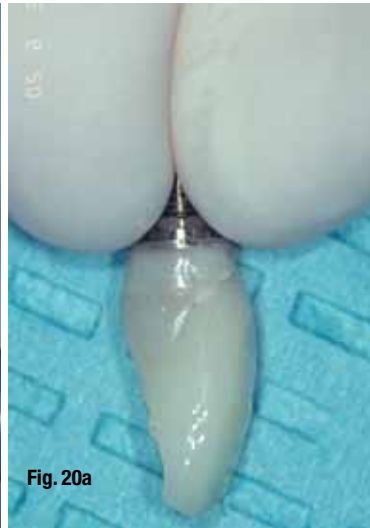

Fig. 20a



Fig. 20b

Fig. 19: Margination of an acrylic screw-retained provisional restoration.

Fig. 20a, b: Emergence profile obtained using an acrylic provisional restoration.

Fig. 21: Placement of the provisional restoration. Note the initial closure of the mid-line diastema, resulting in a crown morphology that is too wide mesial-distally.

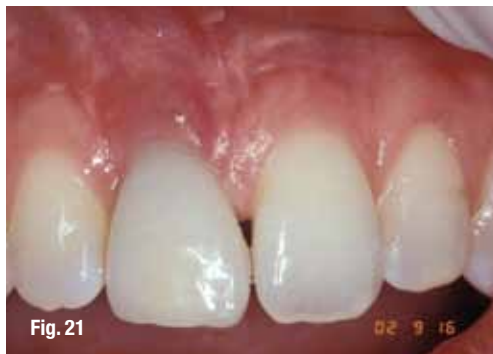

Fig. 21

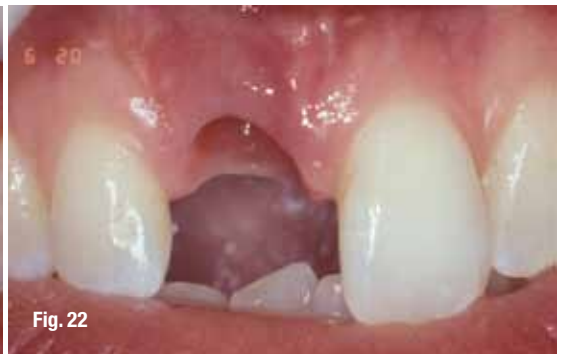

Fig. 22

Fig. 22: Buccal view of soft tissue profile following tissue remodeling using the acrylic provisional restoration.

Fig. 23: Occlusal view of the peri-implant sulcus following tissue remodeling using the acrylic provisional restoration.

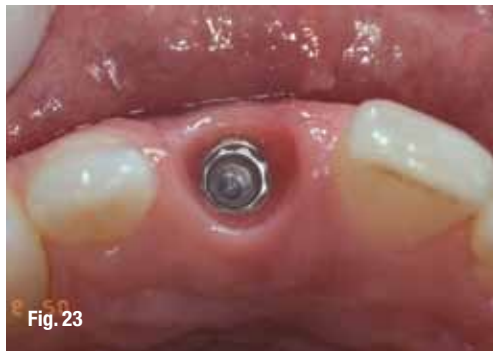

Fig. 23

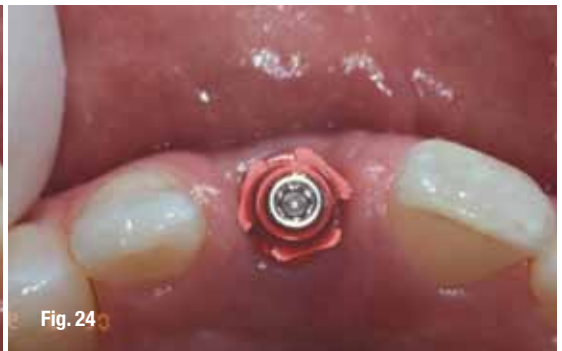

Fig. 24

Fig. 24: Occlusal view of synOcta screw-retained impression coping.

Fig. 25: Final Impression.

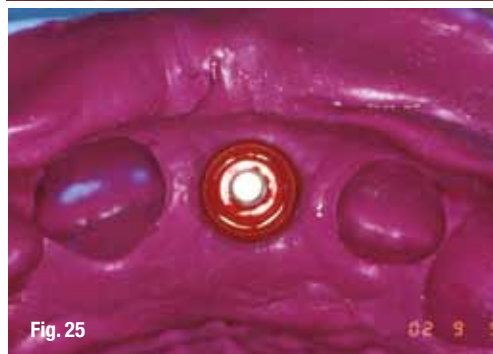


Fig. 25

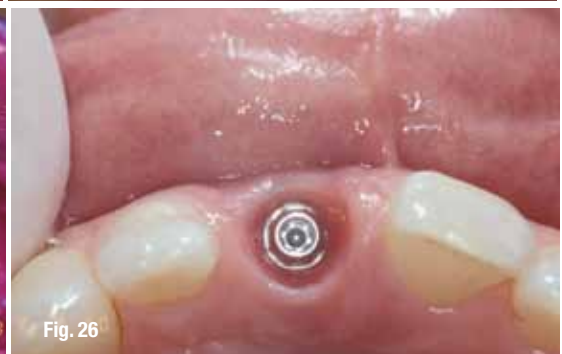

Fig. 26

Fig. 26: Occlusal view of mature peri-implant sulcular tissue with synOcta abutment.

a non-rotational synOcta gold coping. Following the insertion of a 1.5 synOcta abutment (Fig 26), which was hand tightened, the crown framework was attached to the implant with an SCS occlusal screw, and a second definitive impression using a closed tray

technique was made to verify the peri-implant soft tissue profiles (Figs. 27–30).

The ceramic work was completed at the laboratory using this accurate master cast. The 1.5 synOcta abutment was torqued to 35 n/cm² and the final

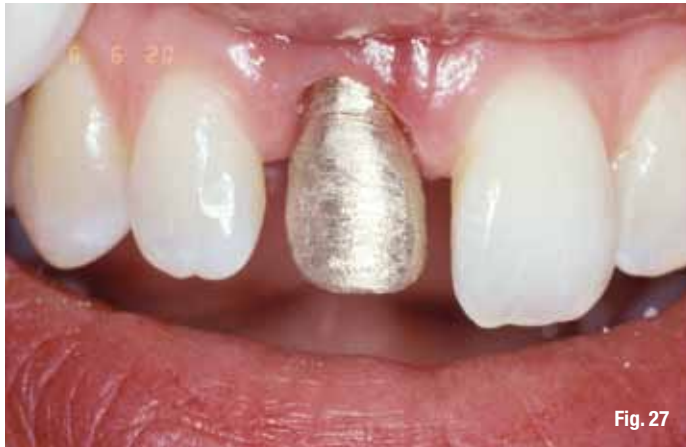

Fig. 27

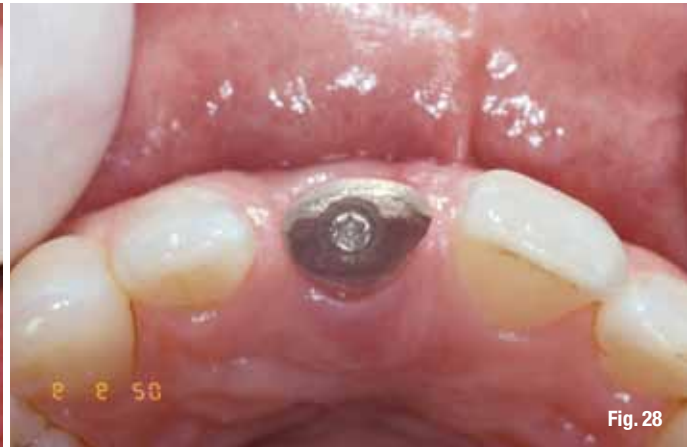

Fig. 28

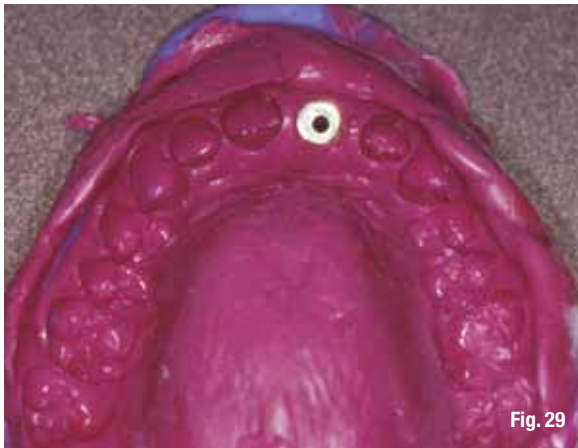

Fig. 29



Fig. 30

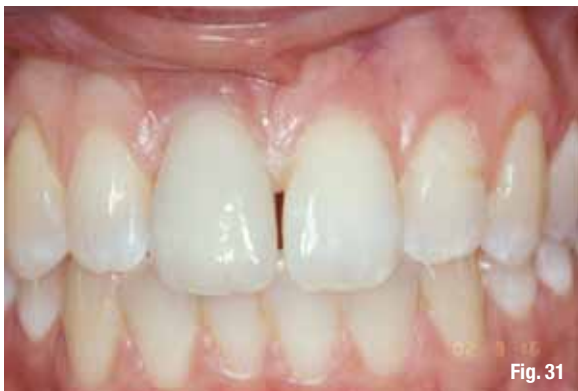

Fig. 31

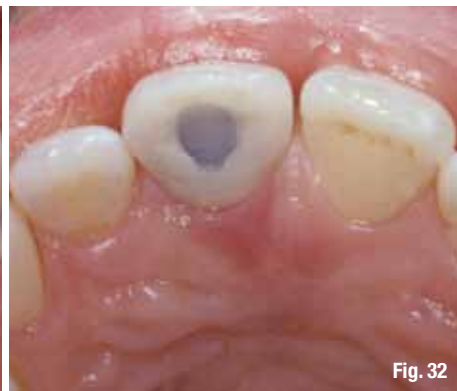

Fig. 32

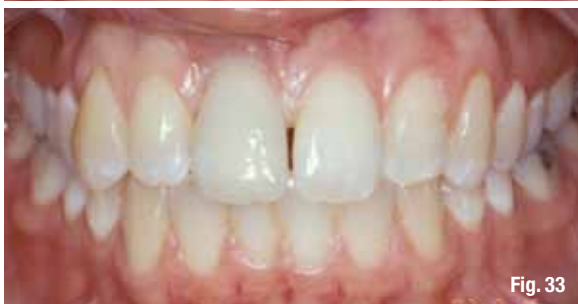

Fig. 33

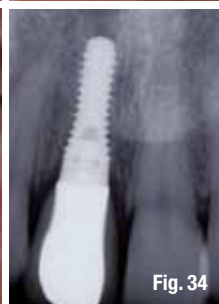

Fig. 34

crown was seated and checked for marginal fit, occlusal and interproximal contacts and emergence profile (Fig. 31).

Final glazing of the ceramics was then performed, and the SCS occlusal screw was tightened

to 15 n/cm². The screw access was obturated with a cotton pledget and restored with a light cured composite (Fig. 32).

A periapical radiograph was obtained to establish a baseline marginal bone level with maintenance

Fig. 27: Buccal view of cast gold framework coping.

Fig. 28: Occlusal view of cast gold framework coping.

Fig. 29: Impression of framework coping to verify soft-tissue profiles.

Fig. 30: Close-up occlusal view of impression of framework coping to verify soft-tissue profiles.

Fig. 31: Buccal view of final restoration delivered four months from initial surgery date.

Fig. 32: Occlusal view of final screw-retained restoration.

Fig. 33: Extended buccal view of final restoration delivered four months from initial surgery date.

Fig. 34: Periapical radiograph of final restoration delivered four months following initial surgery.