

roots

the international C.E. magazine of endodontics

1 2015

_C.E. article

Pulp necrosis in the left upper incisor

_technique

The endo-restorative connection

_interview

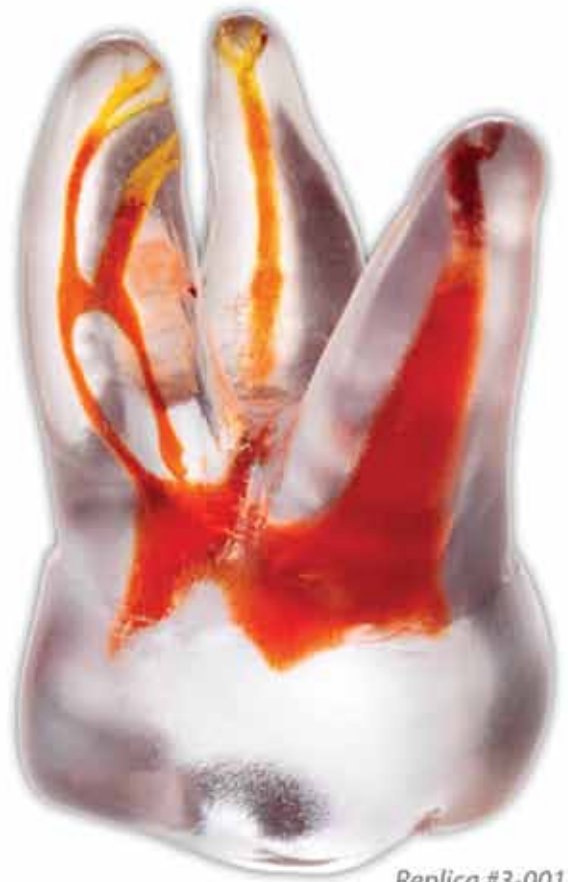Dr. Robert S. Roda:
'A time of unprecedented change'

TrueTooth[®]

Not models. Replicas of actual teeth.

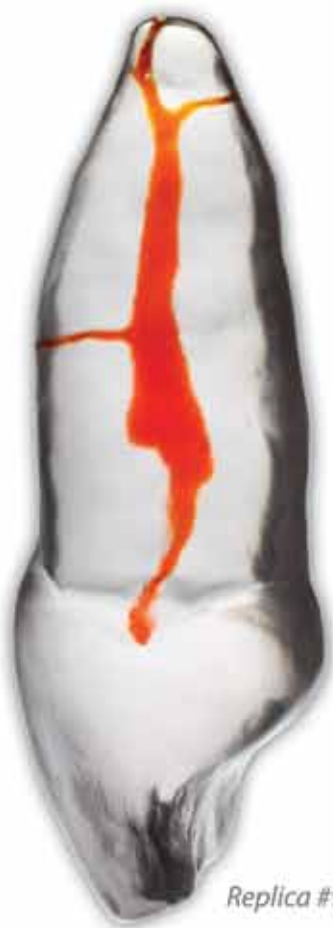"The real value in the TrueTooth Replicas is that our students can appreciate the complexity of the root canal system. We have the benefits of students working on replica teeth that we select, and everyone is working on the same tooth. It levels the playing field and takes away the infection control concerns. We can concentrate our energy on technique instead of tooth selection."

Donald J. Kleier, D.M.D.
Professor and Chair,
Division of Endodontics, School of Dental Medicine, University of Colorado



Replica #3-001

*Now available
in accessed
and shaped
versions!*



Replica #9-001

"No more explaining to students how the anatomy is different than natural teeth. Get real, people."

Ronald R. Lemon, D.M.D.
Coordinator of Predoctoral Endodontic Program and Associate Dean for Advanced Education
School of Dental Medicine, University of Nevada, Las Vegas

"TrueTooth Replicas brought anatomic realism to our preclinical endodontics course!"

Division of Endodontics,
University of Minnesota, School of Dentistry

Almost as Good as the Real Thing

Available exclusively through Dental Education Laboratories
Your Premier Resource for Endodontic Continuing Education

800.528.1590 / 805.899.4529 / www.DELendo.com Patent Pending

Saving teeth is a worthy endeavor



Fred Weinstein, DMD, MRCD(C),
FICD, FACD

Endodontists are heroes. We save teeth – which is worth every effort, if you ask me. But to stay on top of your game, you have to stay up to date on the latest technology and treatment options. In this issue of *roots*, you can find many articles designed to enhance your knowledge.

Dr. Javier Martínez Osorio and Dr. Sebastiana Arroyo Bote offer a case report on a 17-year-old patient who came into their clinic because she noticed a color change of the upper-left central incisor. A pulp necrosis of the 2.1 incisor was diagnosed and treated. Dr. Jason H. Goodchild reports on the materials he finds most useful in restoring endodontically treated teeth. In an interview, Dr. Robert S. Roda, president of the American Association of Endodontists, discusses his background, those who influenced him most in his career, his passion for diagnosing and treating patients and the latest initiatives of the AAE. We also offer a preview of the AAE's upcoming annual meeting, to be held this May in Seattle.

There's even more.

By reading the article by Dr. Osorio and Dr. Bote in this issue of *roots*, and then taking a short online quiz about their article at www.DTStudyClub.com, you will gain one ADA CERP-certified C.E. credit. Keep in mind that because *roots* is a quarterly magazine, you can actually chisel four C.E. credits per year out of your already busy life without any lost revenue and time away from your practice.

To learn more about how you can take advantage of this C.E. opportunity, visit www.DTStudyClub.com. You need only register at the Dental Tribune Study Club website to access these C.E. materials free of charge. You may take the C.E. quiz after registering on the DT Study Club website.

I know that taking time away from your practice to pursue C.E. credits is costly, and that is another reason *roots* is such a valuable publication. I hope you will enjoy this issue and that you will take advantage of the C.E. opportunity.

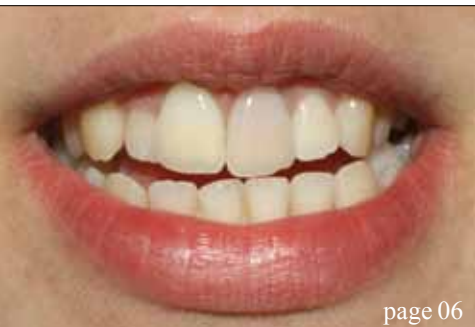For those of you attending the upcoming AAE meeting this spring in Seattle, be sure to say hello to me in person. I'll also be at the Midwinter Meeting in Chicago and at CDA Presents the Art and Science of Dentistry in Anaheim, Calif.

As always, I welcome your comments and feedback.

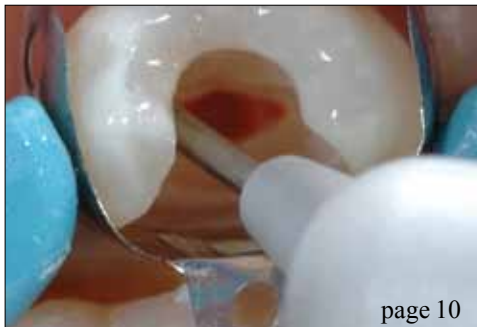Sincerely,

A handwritten signature in cursive script that reads "Fred".

Fred Weinstein, DMD, MRCD(C), FICD, FACD
Editor in Chief



page 06



page 10



page 14

| **C.E. article**

- 06 **Pulp necrosis** in the upper left incisor as a consequence of neurovascular pedicle compression
_Dr. Javier Martínez Osorio and Dr. Sebastiana Arroyo Bote

| **technique**

- 10 The **endo-restorative** connection: The right material for the right situation
_Jason H. Goodchild, DMD

| **interview**

- 14 Dr. Robert S. Roda: 'A time of **unprecedented change** in our profession'
_Fred Michmershuizen, Managing Editor

| **meetings**

- 18 Endodontists from around the world to meet in Seattle, May 6-9, for **AAE15**

| **industry**

- 20 Wykle Research offers **Calasept Endo** line
- 22 Planmeca's **endodontic imaging** mode

| **industry education**

- 24 There is a **better way** (and LVI can show you how to get there)
_Mark Duncan, DDS, FAGD, LVIF, DICOI, FICCMO

| **about the publisher**

- 25 _submissions
- 26 _imprint




| **on the cover**

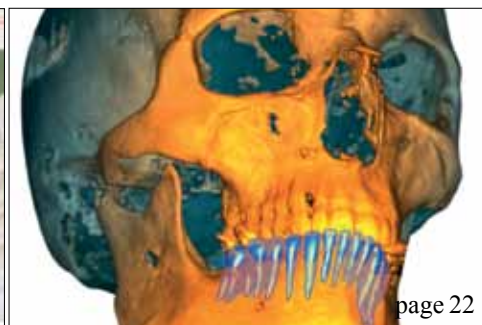
Photograph provided by Dr. Craig Barrington.



page 18



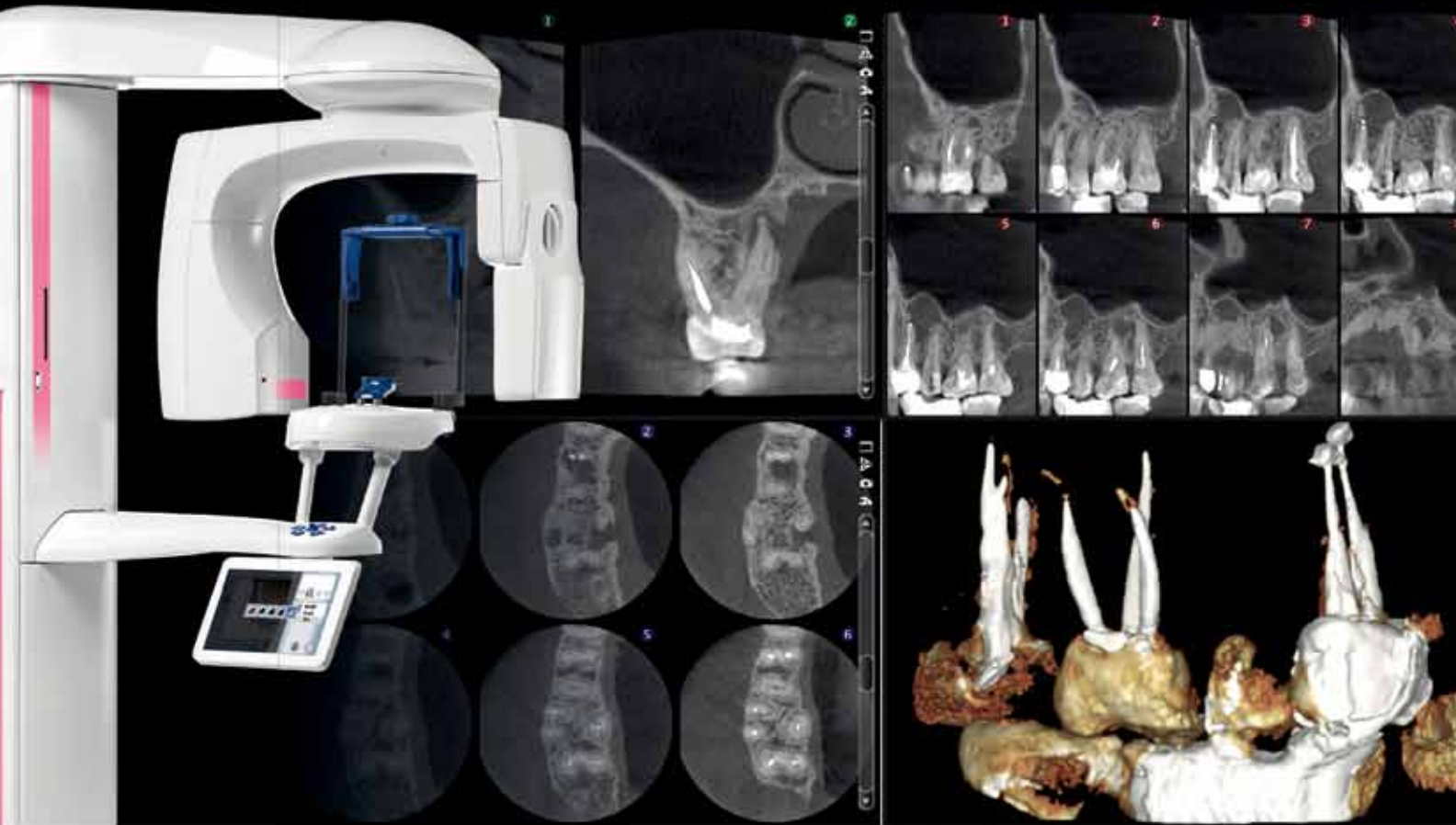
page 20



page 22

Planmeca ProMax® 3D

Endodontic imaging mode – a new era in precision

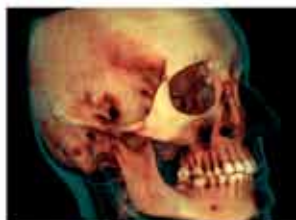

Perfect visualisation of the finest details

- Extremely high resolution with 75 µm voxel size
- Noise-free images with intelligent **Planmeca AINO™** filter
- Artefact-free images with efficient **Planmeca ARA™** algorithm



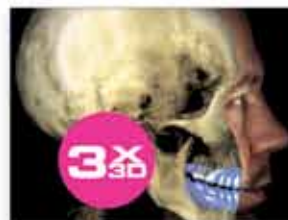Other unique features in Planmeca ProMax® 3D family units:



Ultra low dose imaging

CBCT imaging with an even lower patient dose than panoramic imaging.

Adult female, FOV Ø200 x 170 mm
Effective dose 14.7 µSv
Planmeca ProMax® 3D Mid



Create your virtual patient

A world first:
One imaging unit,
three types of 3D data.
All in one software.

CBCT + 3D model scan + 3D face photo

PLANMECA



Pulp necrosis in the left upper incisor as a consequence of neurovascular pedicle compression

Authors_Dr. Javier Martínez Osorio and Dr. Sebastiana Arroyo Bote

_c.e. credit

This article qualifies for C.E. credit. To take the C.E. quiz, log on to www.dntstudyclub.com. Click on 'C.E. articles' and search for this edition (Roots C.E. Magazine — 1/2015). If you are not registered with the site, you will be asked to do so before taking the quiz. You may also access the quiz by using the QR code below.



_Abstract

We report a case of a 17-year-old patient who came into the clinic because she noticed a color change of the upper-left central incisor (2.1) of 48 hours' duration. During clinical inspection, the 2.1 incisor presented a darker color than the rest of the teeth. After performing a complete exploration and obtaining no response to vitality tests, a pulp necrosis of the 2.1 incisor was diagnosed.

Differential diagnosis begins with the completion of the medical record. The patient had received orthodontic treatment, and she had been operated to extract a supernumerary tooth in the anterior region of the upper maxilla. The patient does not remember having suffered injuries or trauma in the incisal region. An oral orthopantomography is requested, in which a high-density area is observed at periapical level in the 2.1 area.

A three-dimensional CAT (computed axial tom-

ography) is requested, which shows the presence of a supernumerary in the periapical 2.1 region, located in palatine and upward oriented. Necrosis by compression of the neurovascular pedicle of 2.1 due to the eruption-follicle growth of the supernumerary is diagnosed. Pulpectomy and surgical removal of the supernumerary are performed. During surgical removal of the supernumerary, the 2.1 neurovascular pedicle is located edematized-congestive and cause of the 2.1 pulp necrosis.

_Clinical case

A 17-year-old patient who had undergone orthodontic treatment four years before came into the clinic because she noticed a color change in her upper right central incisor lasting a few hours. The patient noted a pink color (Fig. 1) with a slight pain that ceased with anti-inflammatory (AINE). In an initial visit to her general dentist, vitality tests were

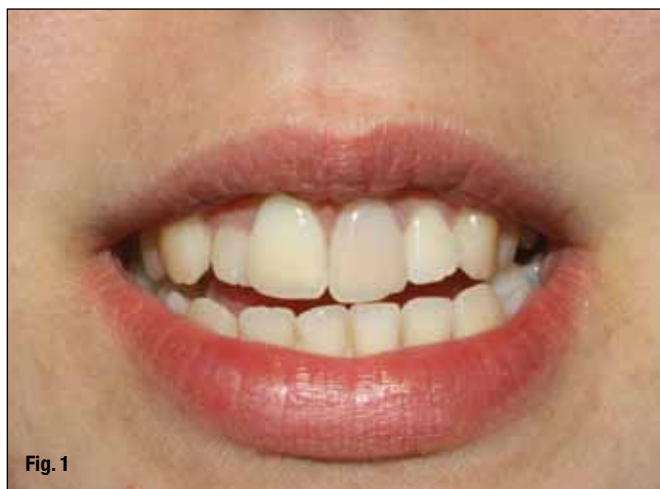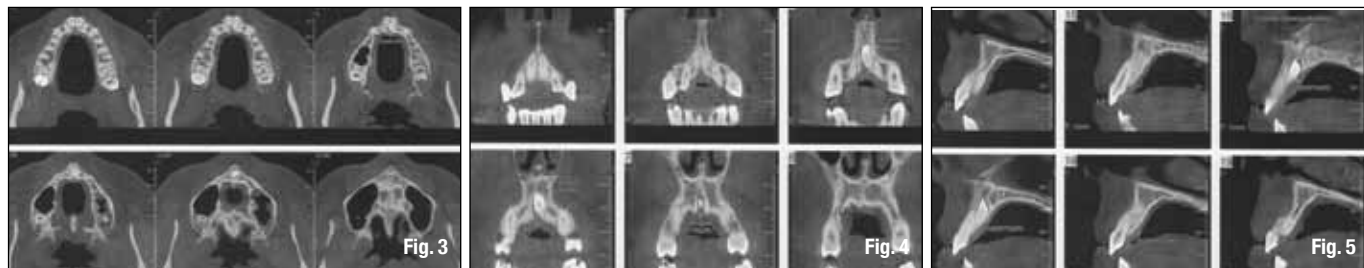


Fig. 1

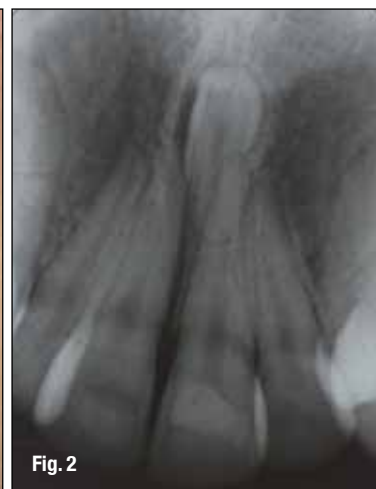

Fig. 2

(Photos/Provided by
Dr. Javier Martínez Osorio and
Dr. Sebastiana Arroyo Bote)



performed, detecting a slight response. After that, the patient was referred to a specialist.

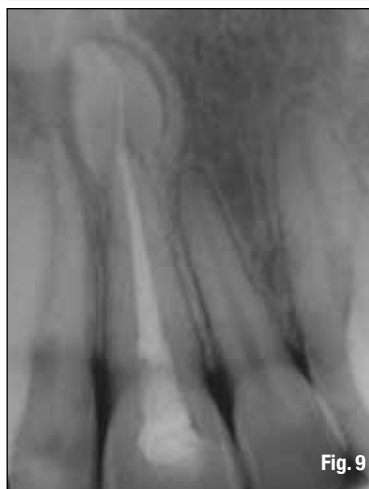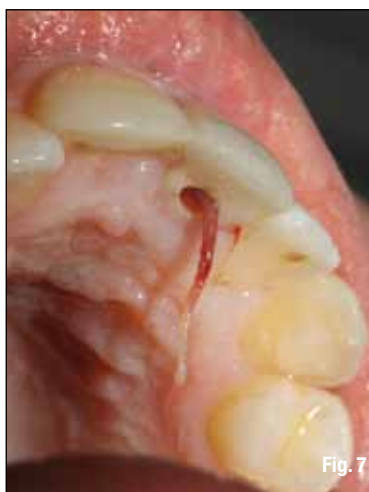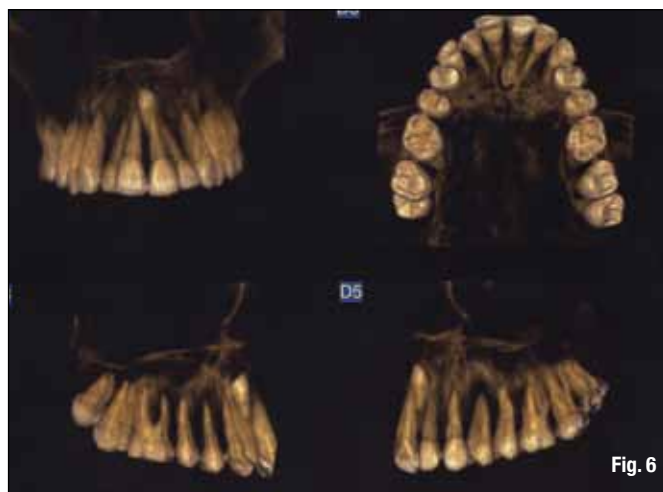When she visited the endodontist, the tooth had changed color and had darkened over to a gray-brown color. In addition to that, the tooth did not respond to pulp vitality tests anymore. During the visit, the endodontist performed periapical radiographs of the area (Fig. 2). The existence of a supernumerary at the apical level of the incisive growing toward the floor of the nasal cavity was confirmed. The endodontist requested a cone-beam computed tomography (CBCT), to study the position and assess the possibility of surgical extraction.

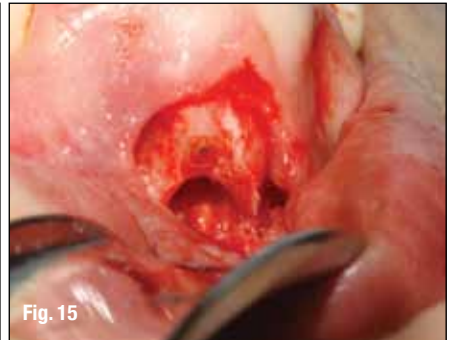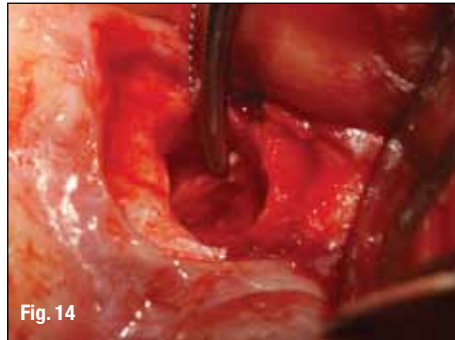
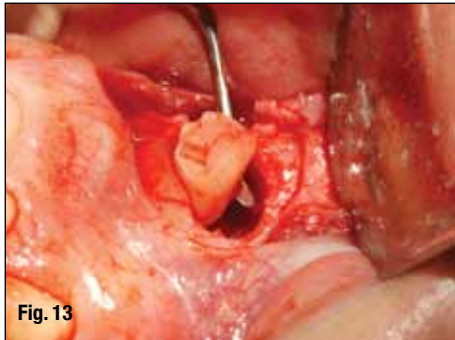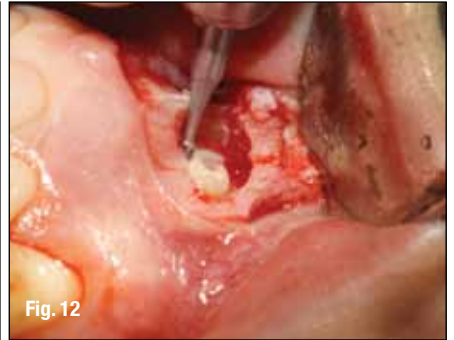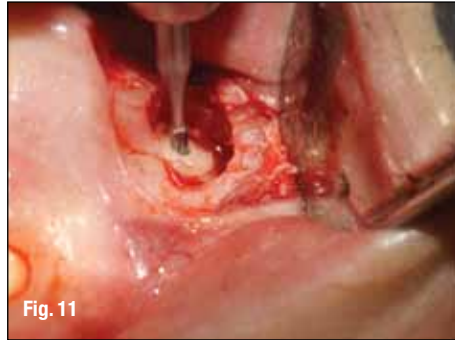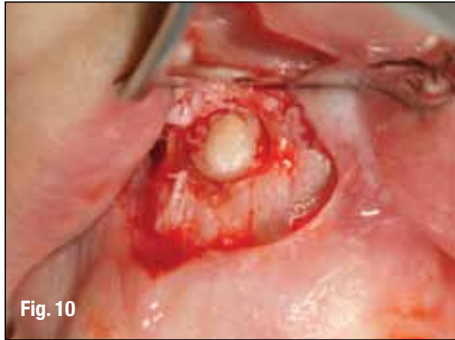CBCT images show the position of the supernumerary relative to the roots of neighboring teeth, confirming growth toward the apical region of 2.1, i.e. 180 degrees relative to the orientation, it should have

to erupt within the dental arch. 3-D reconstruction shows this phenomenon very didactically (Figs. 3–6).

Endodontic treatment of 2.1 was performed, removing the congested pulp and observing some bleeding during the course of it. The length of the shutter-percha obturation was deliberately longer than usually in order to facilitate surgery (Figs. 7–9).

Surgical treatment was planned based on a semilunar flap on the periapical region of 2.1 and a minimum root resection without bezel, using a 0.23 round bur, with a straight handpiece, of about 2 mm approx, exposing the supernumerary's crown. The supernumerary's crown was sectioned by the middle third coronary level, incisal portion was removed (Fig. 11). A hole was made in what would be the middle and cervical third of supernumerary, to force up (Fig. 12) and make the extraction through the oste-





otomy practiced for apicoectomy, thereby achieving a complete extraction (Fig. 13) with minimal trauma to the bone and roots of the incisors.

The edematous pedicle that was compressed by the follicle eruption of the supernumerary, and caused a lack of blood supply to the pulp left central incisor, can be observed in the image, pressed by a hemostat (Fig. 14).

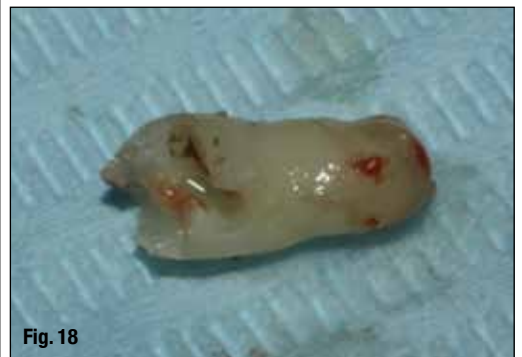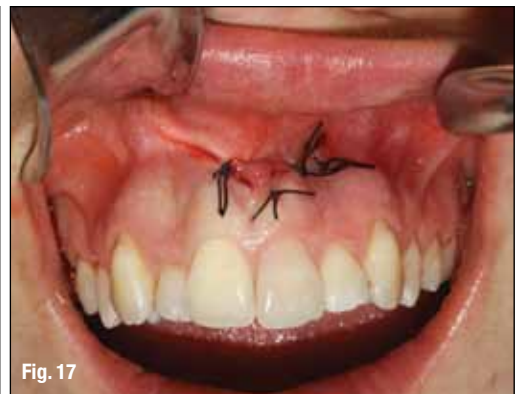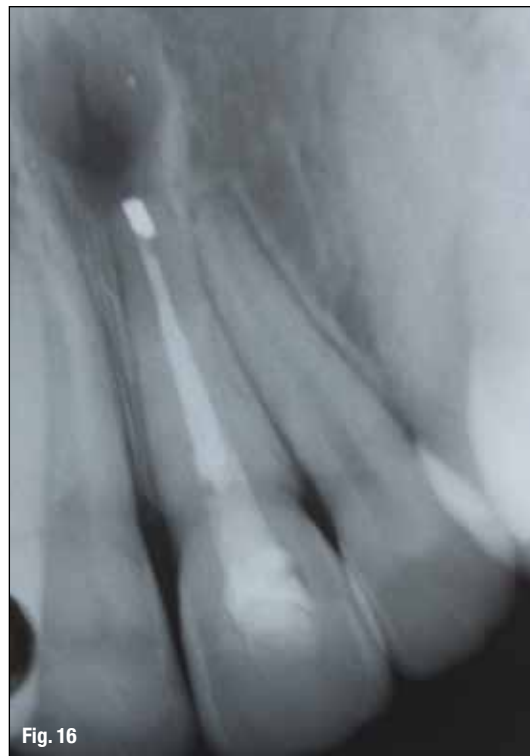Afterward, a preparation a retro was performed using a Satelec Ultrasonic system and a proper insert. Conduit was sealed a retro with SuperEBA, thereby

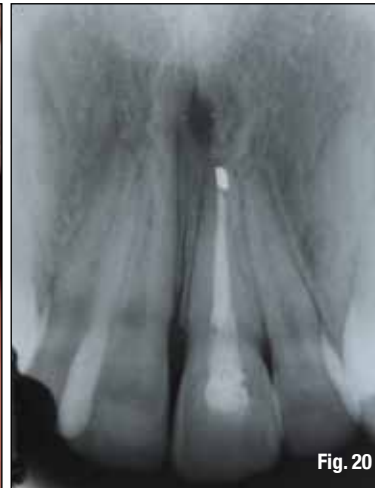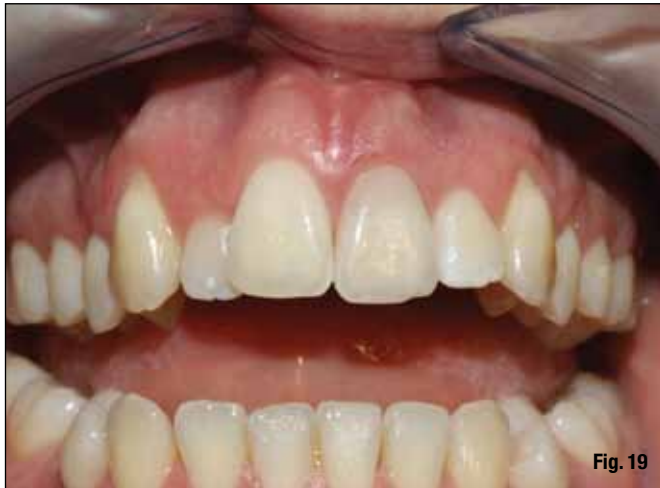achieving sealing of the conduit at apical level (Figs. 15, 16). The flap was closed with three silk sutures (Fig. 17), which were removed after seven days.

Supernumerary tooth after extraction can be observed in the picture (Fig. 18).

Two months after the intervention, an internal bleaching treatment was performed to improve the color of the incisor.

In the last two pictures, we can observe the clinical appearance (Fig. 19) and the radiographic progression (Fig. 20) after three years of evolution.





_Discussion

Diagnostic and anatomical data provided by CBCT studies, which has been widely used in endodontic diagnostics including fractures and fissures or in implant studies, is not commonly used in surgical planning yet. The relevant and detailed information that this imaging technique provides, especially about the position of supernumerary tooth, is further proof that it should be present in the protocol of the case during the surgical planning.

The second point of discussion is the pathway used to approach the supernumerary. We could have used a palatal pathway, but the CBCT study revealed that the vestibular pathway was less risky, provided greater visibility and better respected the important anatomical structures, such as neighboring teeth, without injuring them by accident or increasing the risk of causing an iatrogenic injury.

Another important point to be observed is the pathophysiological mechanism that resulted in pulp necrosis. We suspected an apical or periapical resorption of 2.1 because of the expansive growth of the erupting follicle and secondary osteolysis, which cannot be excluded. To eliminate the greatest amount of cells involved in the resorptive-destructive process, an apicoectomy was performed. Nevertheless, pulp congestion suggests that the most probable pathophysiological mechanism involved was venous stasis of the venous pack that enters the incisor, just before apex.

Last point of discussion is when these supernumerary teeth should be removed. If possible, the best moment for removal is before showing any pathology signs, always individualizing each patient, performing a clinical and radiographic follow-up of the case in order to choose the right time is necessary.

_Conclusion

The presence of supernumerary teeth in the permanent dentition has a frequency of between 0.1

and 3.8 percent, one of the possible complications being necrosis of adjacent teeth, so we must take into account the possibility of supernumerary teeth existence during diagnosis, especially in patients with pulp necrosis without previous traumatic dental pathology.

_about the authors

roots

Javier Martínez Osorio graduated in medicine in 1981 from Barcelona University. He specialized in dentistry in 1983 and plastic surgery in 1987. He is a member of the Spanish Society of Implantology, Endodontic, Conservative Odontology and Maxillofacial Surgery. He is associate professor of conservative dentistry and endodontic, faculty of odontology at Barcelona University since 1996. He maintains a private practice in implants and endodontic surgery in Barcelona, Spain. He is an author of publications and lectures around the world on current concepts in endodontic surgery and implantology. He is president of the Catalonia Society of Odontology. He may be contacted at 16486jmo@comb.cat.



Sebastiana Arroyo Bote graduated in medicine in 1983 from Barcelona University. She specialized in dentistry in 1985. She is a member of the Spanish Society of Endodontology and Conservative Dentistry. She is associate professor of conservative dentistry and endodontology, Barcelona University, since 1992. She maintains a private practice in conservative dentistry and endodontic treatment in Barcelona, Spain. She is an author of publications and lectures on current concepts in endodontology and esthetic conservative dentistry. She may be contacted at 20506sab@comb.cat.

