

roots

the international C.E. magazine of endodontics

2²⁰¹⁴

_C.E. article

Endodontic irrigants
and irrigant delivery
systems

_education

Control the anatomy;
control procedural training

_industry education

LVI Core I three-day course
is designed for doctors and
their teams to learn together



CALASEPT® Endo-line

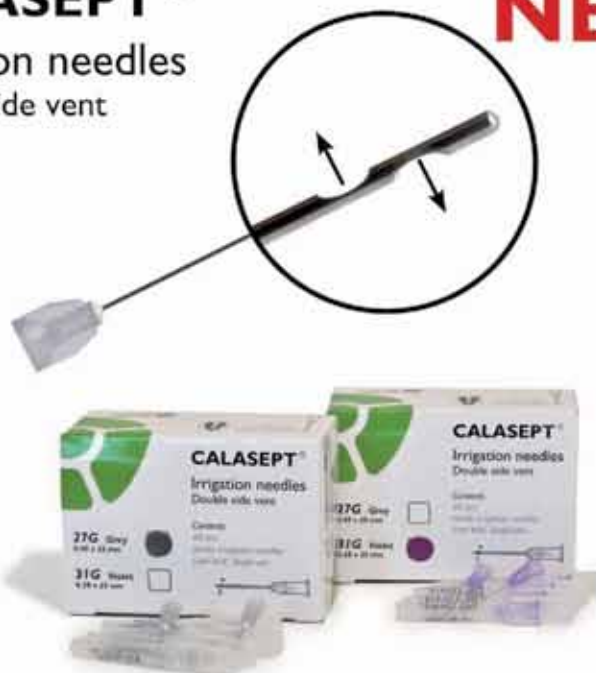CALASEPT®

Irrigation needles
Double side vent

NEW

CALASEPT Irrigation Needles

- * Double side vented
- * With luer lock hub
- * Bendable
- * High quality stainless steel
- * Sterile and disposable
- * Easy for cleaning out the canals
- * Container packed



CALASEPT® Plus
Calcium Hydroxide

NEW

CALASEPT PLUS

- * More than 41% calcium hydroxide
- * Optimal calcium release
- * Strong bactericidal effect pH 12.4
- * Flexi-needle for precise and deep application



**Call Wykle Research for a Free sample
of our Calasept products 800-859-6641**

Distributed by:

Made by:



**WYKLE
RESEARCH, INC.**
2222 College Parkway
Carson City, NV 89706
Tel. 800-859-6641
Fax. 866-329-9955
www.wyklesearch.com

New ways to learn



Fred Weinstein, DMD, MRCD(C),
FICD, FACD

When it comes to dentistry in general, and the specialty of endodontics in particular, there is always a lot to learn. That's why dental meetings like the AAE Annual Session are so important. The dental literature is valuable as well — especially a C.E. magazine like the one you are holding now (more on that in a moment).

In this issue of *roots*, you can find articles on new ways to learn. Namely, there are new 3-D training replicas, available from Dr. L. Stephen Buchanan and his team at Dental Education Laboratories. (These new tooth models, I'm told, are a delight to work with.) There's an article about a three-day course available at the Las Vegas Institute for Advanced Dental Studies. This issue also contains a report by Dr. Gary Glassman on endodontic irrigation. He reveals the results of research on various irrigation systems and their efficacy.

By reading the article by Dr. Glassman, then taking a short online quiz about his article at www.DTStudyClub.com, you will gain one ADA CERP-certified C.E. credit. Keep in mind that because *roots* is a quarterly magazine, you can actually chisel four C.E. credits per year out of your already busy life without the lost revenue and time away from your practice.

To learn more about how you can take advantage of this C.E. opportunity, visit www.DTStudyClub.com. You need only register at the Dental Tribune Study Club website to access these C.E. materials free of charge. You may take the C.E. quiz after registering on the DT Study Club website.

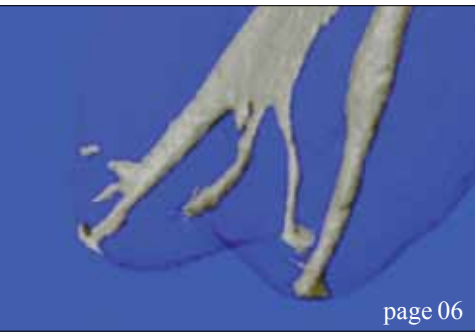
I know that taking time away from your practice to pursue C.E. credits is costly in terms of lost revenue and time, and that is another reason *roots* is such a valuable publication. I hope you will enjoy this issue and that you will take advantage of the C.E. opportunity.

For those of you attending the AAE Annual Session this spring in Washington, D.C., be sure to say hello in person. I'll also be at the spring CDA Presents the Art and Science of Dentistry meeting in Anaheim, Calif.

As always, I welcome your comments and feedback.

Sincerely,

Fred Weinstein, DMD, MRCD(C), FICD, FACD
Editor in Chief



| C.E. article

- 06 **Endodontic irrigants** and irrigant delivery systems
_Gary Glassman, DDS, FRCD(C)

| education

- 14 **Control the anatomy; control procedural training**
_L Stephen Buchanan, DDS, FICD, FACD

| industry education

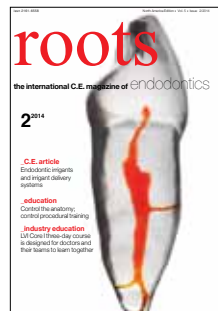- 19 **LVI Core I** three-day course is designed for doctors and their teams to learn together
_Mark Duncan, DDS, FAGD, LVIF, DICOI, FICCMO

| industry

- 20 **Sonendo**: Root canals clean at the speed of sound
21 Introducing **Grey MTA Plus** — ‘Reshaping’ root canal practices everywhere

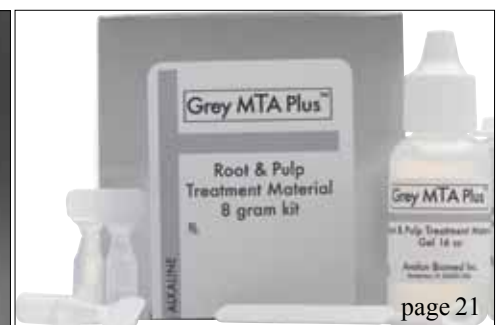
| about the publisher

- 22 _imprint



| on the cover

The image is of a TrueTooth™ training replica. Designed by Dr. L. Stephen Buchanan and re-created by a 3-D printer, these are authentic replicas of the internal and external anatomy of CT-scanned extracted teeth, with bleach-dissolvable material in the root canal passageways. TrueTooth training replicas are available exclusively from www.DELEndo.com and are patent pending. (Image/ Provided by L. Stephen Buchanan, DDS, FICD, FACD)



VISTA DENTAL. Experience the **ULTRA**sonic difference.

INTRODUCING

ENDO|ULTRA™

SUPERIOR ACTIVATION*
(compared to sonic devices)

ULTRA EFFECTIVE.

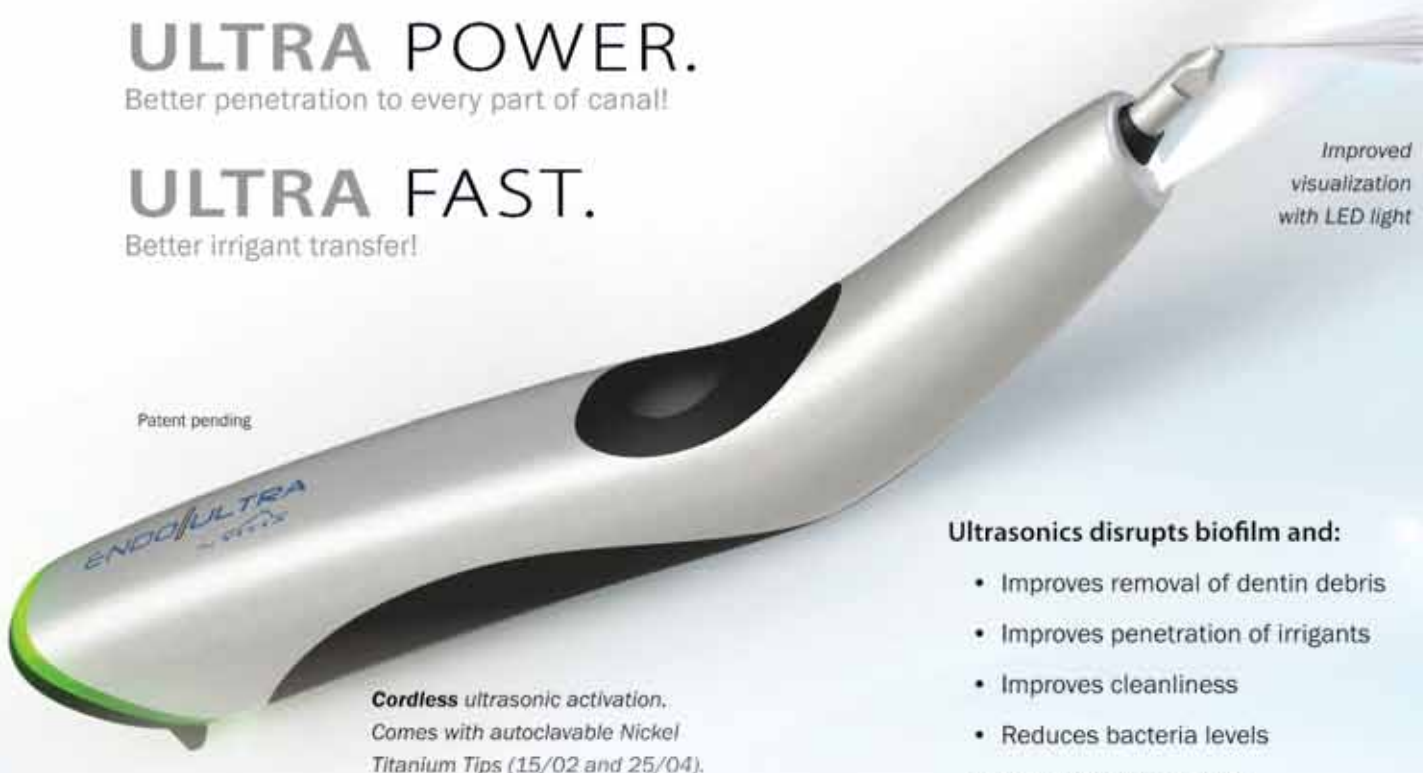Better cleansing ability than sonic streaming!*

ULTRA POWER.

Better penetration to every part of canal!

ULTRA FAST.

Better irrigant transfer!



Patent pending

Improved
visualization
with LED light

Cordless ultrasonic activation.
Comes with autoclavable Nickel
Titanium Tips (15/02 and 25/04).

Ultrasonics disrupts biofilm and:

- Improves removal of dentin debris
- Improves penetration of irrigants
- Improves cleanliness
- Reduces bacteria levels
- Improves accessibility
- Improves root sealing

See why scientific evidence supports **ULTRA**sonic technology



Vist us at AAE – Booth 622

Or call for our INTRODUCTORY OFFER



Vista Dental Products www.vista-dental.com call toll free 1.877.418.4782

*Sources: Med Oral Pathol Oral Clin Buccal; 2012 May 1;17(3):e512-6. Review of ultrasonic irrigation in endodontics: increasing action of irrigating solutions. Mozo S(1), Uena C, Forner L.
Int Endod J. 2007 Jun;40(6):415-26. Epub 2007 Apr 17. Passive ultrasonic irrigation of the root canal: a review of the literature. van der Sluis LW(1), Verschuyl M, Wu MK, Wesselink PR.
Eur J Dent. 2008 Jul;2(3):198-203. Effect of passive ultrasonic irrigation on apical extrusion of irrigating solution. Tasdemir T(1), Er K, Celik D, Yildirim T.

Endodontic irrigants and irrigant delivery systems

Author_Gary Glassman, DDS, FRCD(C)

_c.e. credit

This article qualifies for C.E. credit. To take the C.E. quiz, log on to www.dtstudyclub.com. Click on 'C.E. articles' and search for this edition (Roots C.E. Magazine — 2/2014). If you are not registered with the site, you will be asked to do so before taking the quiz. You may also access the quiz by using the QR code below.



_Endodontic treatment is a predictable procedure with high success rates. Success depends on a number of factors, including appropriate instrumentation, successful irrigation and decontamination of the root-canal space to the apices and in areas such as isthmuses. These steps must be followed by complete obturation of the root canals, and placement of a coronal seal, prior to restorative treatment.

Several irrigants and irrigant delivery systems are available, all of which behave differently and have relative advantages and disadvantages. Common root-canal irrigants include sodium hypochlorite (NaOCl), chlorhexidine gluconate, alcohol, hydrogen peroxide and ethylenediamine-tetraacetic acid (EDTA). In selecting an irrigant and

technique, consideration must be given to their efficacy and safety.

With the introduction of modern techniques, success rates of up to 98 percent are being achieved.¹ The ultimate goal of endodontic treatment per se is the prevention or treatment of apical periodontitis, such that there is complete healing and an absence of infection,² while the overall long-term goal is the placement of a definitive, clinically successful restoration and preservation of the tooth. For these to be achieved, appropriate instrumentation, irrigation, decontamination and root-canal obturation must occur, as well as attainment of a coronal seal.

There is evidence that apical periodontitis is a biofilm-induced disease.³ A biofilm is an aggregate

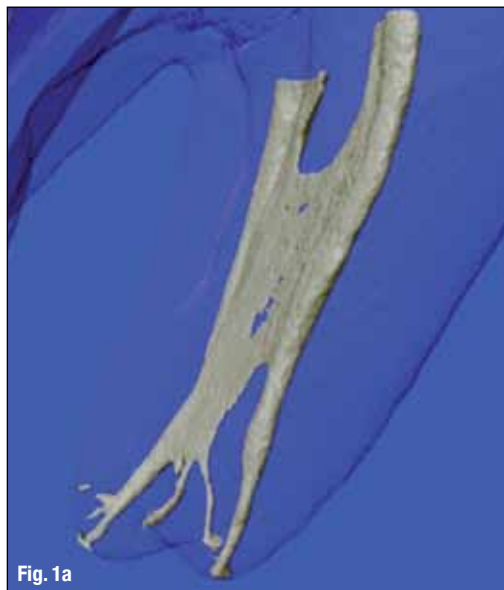

Fig. 1a

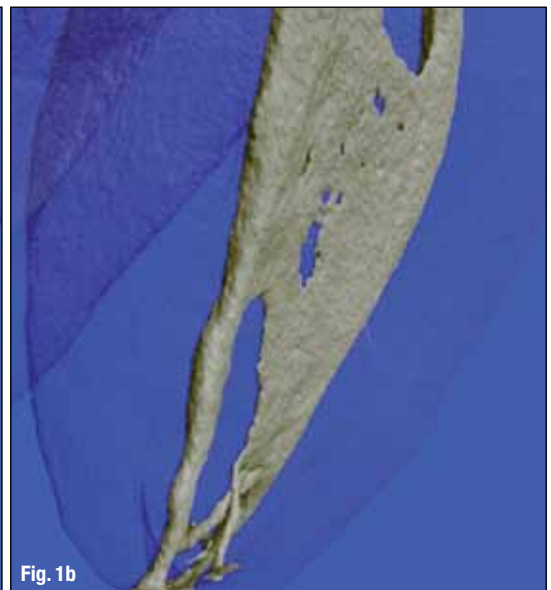

Fig. 1b

Figs. 1a,b_Root-canal complex.
(Images/Dr Ronald Ordinala Zapata,
Brazil, [www.facebook.com/
TheInternalAnatomy
OfTheHumanTeeth](http://www.facebook.com/TheInternalAnatomyOfTheHumanTeeth))

of microorganisms in which cells adhere to each other and/or to a surface. These adherent cells are frequently embedded within a self-produced matrix of extracellular polymeric substance. The presence of microorganisms embedded in a biofilm and growing in the root-canal system is a key factor for the development of periapical lesions.⁴⁻⁷ Additionally, the root-canal system has a complex anatomy that consists of arborisations, isthmuses and cul-de-sacs that harbor organic tissue and bacterial contaminants (Figs. 1a,b).⁸

The challenge for successful endodontic treatment has always been the removal of vital and necrotic remnants of pulp tissue, debris generated during instrumentation, the dentin smear layer, microorganisms, and micro-toxins from the root-canal system.⁹

Even with the use of rotary instrumentation, the nickel-titanium instruments currently available only act on the central body of the root canal, resulting in a reliance on irrigation to clean beyond what may be achieved by these instruments.¹⁰ In addition, *Enterococcus faecalis* and *Actinomyces* prevention or treatment of apical periodontitis such as *Actinomyces israelii*— which are both implicated in endodontic infections and in endodontic failure — penetrate deep into dentinal tubules, making their removal through mechanical instrumentation impossible.^{11,12} Finally, *E. faecalis* commonly expresses multidrug resistance,¹³⁻¹⁵ complicating treatment.

Therefore, a suitable irrigant and irrigant delivery system are essential for efficient irrigation and the success of endodontic treatment.¹⁶ Root-canal irrigants must not only be effective for dissolution of the organic of the dental pulp, but also effectively eliminate bacterial contamination and remove the smear layer — the organic and inorganic layer that is created on the wall of the root canal during instrumentation. The ability to deliver irrigants to the root-canal terminus in a safe manner without causing harm to the patient is as important as the efficacy of those irrigants.

Over the years, many irrigating agents have been tried in order to achieve tissue dissolution and bacterial decontamination. The desired attributes of a root-canal irrigant include the ability to dissolve necrotic and pulpal tissue, bacterial decontamination and a broad antimicrobial spectrum, the ability to enter deep into the dentinal tubules, biocompatibility and lack of toxicity, the ability to dissolve inorganic material and remove the smear layer, ease of use, and moderate cost.

As mentioned above, root-canal irrigants currently in use include hydrogen peroxide, NaOCl, EDTA, alcohol and chlorhexidine gluconate. Chlorhexidine gluconate offers a wide antimicrobial spectrum, the main bacteria associated with en-

dodontic infections (*E. faecalis* and *A. israelii*) are sensitive to it, and it is biocompatible, with no tissue toxicity to the periapical or surrounding tissue.¹⁷ Chlorhexidine gluconate, however, lacks the ability to dissolve necrotic tissue, which limits its usefulness. Hydrogen peroxide as a canal irrigant helps to remove debris by the physical act of irrigation, as well as through effervescing of the solution. However, while an effective anti-bacterial irrigant, hydrogen peroxide does not dissolve necrotic intra-canal tissue and exhibits toxicity to the surrounding tissue.

Cases of tissue damage and facial nerve damage have been reported following use of hydrogen peroxide as a root-canal irrigant.¹⁸ Alcohol-based canal irrigants have antimicrobial activity too, but they do not dissolve necrotic tissue.

The irrigant that satisfies most of the requirements for a root-canal irrigant is NaOCl.^{19,20} It has the unique ability to dissolve necrotic tissue and the organic components of the smear layer.^{19,21,22} It also kills sessile endodontic pathogens organized in a biofilm.^{23,24} There is no other root-canal irrigant that can meet all these requirements, even with the use of methods such as lowering the pH,²⁵⁻²⁷ increasing the temperature²⁸⁻³² or adding surfactants to increase the wetting efficacy of the irrigant.^{33,34} However, although NaOCl appears to be the most desirable single endodontic irrigant, it cannot dissolve inorganic dentine particles and thus cannot prevent the formation of a smear layer during instrumentation.³⁵

Calcifications hindering mechanical preparation are frequently encountered in the root-canal system, further complicating treatment. Demineralizing agents such as EDTA have therefore been recommended as adjuvants in root-canal therapy.^{20,36} Thus, in contemporary endodontic practice, dual irrigants such as NaOCl with EDTA are often used as initial and final rinses to circumvent the shortcomings of a single irrigant.³⁷⁻³⁹ These irrigants must be brought into direct contact with the entire canal-wall surfaces for effective action,^{20,37,40} particularly in the apical portions of small root canals.⁹

The combination of NaOCl and EDTA has been used worldwide for antisepsis of root-canal systems. The concentration of NaOCl used for root-canal irrigation ranges from 2.5 to 6 percent, depending on the country and local regulations; it has been shown, however, that tissue hydrolyzation is greater at the higher end of this range, as demonstrated in a study by Hand et al. comparing 2.5 and 5.25 percent NaOCl.

The higher concentration may also favor superior microbial outcomes.⁴¹ NaOCl has a broad antimicrobial spectrum,²⁰ including but not limited to *E. faecalis*. NaOCl is superior among irrigating agents

that dissolve organic matter. EDTA is a chelating agent that aids in smear layer removal and increases dentine permeability,^{42,43} which will allow further irrigation with NaOCl to penetrate deep into the dentinal tubules.⁴⁴

General safety precautions

Regardless of which irrigant and irrigation system is employed, and particularly if an irrigant with tissue toxicity is used, there are several general precautions that must be followed. A rubber dam must be used and a good seal obtained to ensure that no irrigant can spill from the pulp chamber into the oral cavity. If deep caries or a fracture is present adjacent to the rubber dam on the tooth being isolated, a temporary sealing material must be used prior to performing the procedure to ensure a good rubber dam seal. It is also important to protect the patient's eyes with safety glasses and protect clothing from irrigant splatter or spill.

It is very important to note that while NaOCl has unique properties that satisfy most requirements for a root-canal irrigant, it also exhibits tissue toxicity that can result in damage to the adjacent tissue, including nerve damage should NaOCl incidents occur during canal irrigation. Furthermore, Salzgeber reported in the 1970s that apical extrusion of an endodontic irrigant routinely occurred in vivo.⁴⁵ This highlights the importance of using devices and techniques that minimize or prevent this. NaOCl incidents are discussed later in this article.

Irrigant delivery systems

Root-canal irrigation systems can be divided into two categories: manual agitation techniques and machine-assisted agitation techniques.⁹ Manual irrigation includes positive-pressure irrigation, which is commonly performed with a syringe and a sidevented needle. Machine-assisted irrigation techniques include sonics and ultrasonics, as well as newer systems such as the EndoVac (SybronEndo), which delivers apical negative-pressure irrigation,⁴⁶ the plastic rotary F File (Plastic Endo),^{47,48} the Vibringe (Vibringe),⁴⁹ the Rinsendo (Air Techniques),⁹ and the EndoActivator (DENTSPLY Tulsa Dental Specialties).⁹

Two important factors that should be considered during the process of irrigation are whether the irrigation system can deliver the irrigant to the whole extent of the root-canal system, particularly to the apical third, and whether the irrigant is capable of debriding areas that could not be reached with mechanical instrumentation, such as lateral canals and isthmuses. When evaluating irrigation of the apical

third, the phenomenon of apical vapor lock should be considered.^{50–52}

Apical vapor lock

Because roots are surrounded by the periodontium, and unless the root-canal foramen is open, the root canal behaves like a closed-ended channel. This produces an apical vapor lock that resists displacement during instrumentation and final irrigation, thus preventing the flow of irrigant into the apical region and adequate debridement of the root-canal system.^{53,54}

Apical vapor lock also results in gas entrapment at the apical third.⁹ During irrigation, NaOCl reacts with organic tissue in the root-canal system, and the resulting hydrolysis liberates abundant quantities of ammonia and carbon dioxide.⁵⁵ This gaseous mixture is trapped in the apical region and quickly forms a column of gas into which further fluid penetration is impossible. Extension of instruments into this vapor lock does not reduce or remove the gas bubble,⁵⁶ just as it does not enable adequate flow of irrigant.

The phenomenon of apical vapor lock has been confirmed in studies in which roots were embedded in a polyvinylsiloxane impression material to restrict fluid flow through the apical foramen, simulating a closed-ended channel. The result in these studies was incomplete debridement of the apical part of the canal walls with the use of a positive-pressure syringe delivery technique.^{57–60}

Micro-CT scanning and histological tests conducted by Tay et al. have also confirmed the presence of apical vapor lock.⁶⁰ In fact, studies conducted without ensuring a closed-ended channel cannot be regarded as conclusive on the efficacy of irrigants and the irrigant system.^{61–63} The apical vapor lock may also explain why in a number of studies investigators were unable to demonstrate a clean apical third in sealed root canals.^{59, 64–66}

In a paper published in 1983 based on research, Chow determined that traditional positive-pressure irrigation had virtually no effect apical to the orifice of the irrigation needle in a closed root-canal system.⁶⁷ Fluid exchange and debris displacement were minimal. Equally important to his primary findings, Chow set forth an infallible paradigm for endodontic irrigation: "For the solution to be mechanically effective in removing all the particles, it has to: (a) reach the apex; (b) create a current (force); and (c) carry the particles away."⁶⁷ The apical vapor lock and consideration for the patient's safety have always prevented the thorough cleaning of the apical 3 mm. It is critically important to determine which irrigation system will effectively irrigate the apical third, as well as isthmuses and lateral canals,¹⁶ and in a safe manner that prevents the extrusion of irrigant.

Manual agitation techniques

By far the most common and conventional set of irrigation techniques, manual irrigation involves dispensing of an irrigant into a canal through needles/cannulae of variable gauges, either passively or with agitation by moving the needle up and down the canal space without binding it on the canal walls. This allows good control of needle depth and the volume of irrigant that is flushed through the canal.^{9,63} However, the closer the needle tip is positioned to the apical tissue, the greater the chance of apical extrusion of the irrigant.^{67, 68} This must be avoided; were NaOCl to extrude past the apex, a catastrophic accident could occur.⁶⁹

Manual–dynamic irrigation

Manual–dynamic irrigation involves gently moving a well-fitting gutta-percha master cone up and down in short 2- to 3-mm strokes within an instrumented canal, thereby producing a hydrodynamic effect and significant irrigant exchange.⁷⁰ Recent studies have shown that this irrigation technique is significantly more effective than automated–dynamic irrigation and static irrigation.^{9,71,72}

Machine–assisted agitation systems

Sonic irrigation

Sonic activation has been shown to be an effective method for disinfecting root canals, operating at frequencies of 1–6k Hz.^{73,74} There are several sonic irrigation devices on the market. The Vibringe allows delivery and sonic activation of the irrigating solution in one step. It employs a two-piece syringe with a rechargeable battery. The irrigant is sonically activated, as is the needle that attaches to the syringe. The EndoActivator is a more recently introduced sonically driven canal irrigation system.^{9,75} It consists of a portable handpiece and three types of disposable polymer tips of different sizes. The EndoActivator has been reported to effectively clean debris from lateral canals, remove the smear layer and dislodge clumps of biofilm within the curved canals of molar teeth.⁹

Ultrasonics

Ultrasonic energy produces higher frequencies than sonic energy but low amplitudes, oscillating at frequencies of 25–30 kHz.^{9,76} Two types of ultrasonic irrigation are available. The first type is simultaneous ultrasonic instrumentation and irrigation, and the second type is referred to as passive ultrasonic irrigation operating without simultaneous irrigation (PUI).

The literature indicates that it is more advanta-

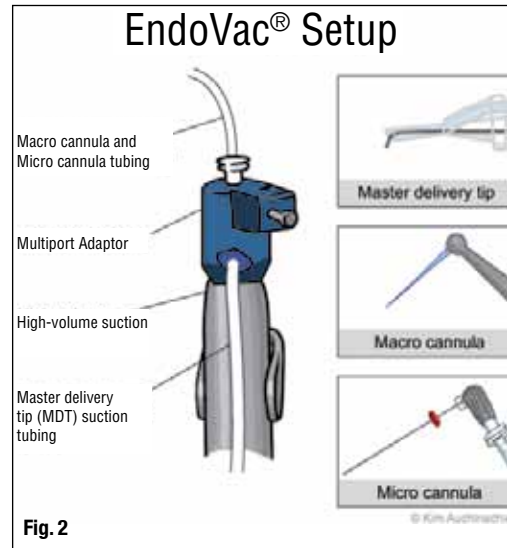


Fig. 2 EndoVac setup. (Images/ Provided by Gary Glassman, DDS, FRCD(C))

geous to apply ultrasonics after completion of canal preparation rather than as an alternative to conventional instrumentation.^{9,20,77} PUI irrigation allows energy to be transmitted from an oscillating file or smooth wire to the irrigant in the root canal by means of ultrasonic waves.⁹ There is consensus that PUI is more effective than syringe needle irrigation at removing pulpal tissue remnants and dentine debris.^{78–80} This may be due to the much higher velocity and volume of irrigant flow that are created in the canal during ultrasonic irrigation.^{9,81} PUI has been shown to remove the smear layer; there is a large body of evidence with different concentrations of NaOCl.^{9,80–84} In addition, numerous investigations have demonstrated that the use of PUI after hand or rotary instrumentation results in a significant reduction in the number of bacteria,^{9,85–87} or achieves significantly better results than syringe needle irrigation.^{9,84,88,89}

Studies have demonstrated that effective delivery of irrigants to the apical third can be enhanced by using ultrasonic and sonic devices that demonstrate acoustic micro-streaming and cavitation.^{79,81,90,91} Acoustic micro-streaming is defined as the movement of fluids along cell membranes, which occurs as a result of the ultrasound energy creating mechanical pressure changes within the tissue. Cavitation is defined as the formation and collapse of gas and vapor-filled bubbles or cavities in a fluid.

The Apical Vapor Lock theory, proven in vitro by Tay, has been clinically demonstrated⁹² to also include the middle third by Vera: "The mixture of gases is originally trapped in the apical third, but then it might grow quickly by the nucleation of the smaller bubbles, forming a gas column that might not only impede penetration of the irrigant into the apical third but also push it coronally after it has been delivered into the canal." However, more recently Munoz⁹³ demonstrated that both passive ultrasonic irrigation