

# CAD/CAM

international magazine of digital dentistry



## **interview**

Digital workflow in dentistry—  
What's in it for you

## **case report**

Predictable guided implant placement  
for full-mouth reconstruction

## **cone beam supplement**

Experts advocate using low-dose  
CBCT imaging protocols

# STRAUMANN® CARES® DIGITAL SOLUTIONS

Straumann® CARES® Digital Solutions > Intraoral Scanner

## Straumann® Virtuo Vivo™ Capture each note.



SCANNING IN  
REAL COLOR.

SMALL  
AND LIGHT  
HANDPIECE.

REMOVABLE  
& AUTO-  
CLAVABLE  
SLEEVES.



Contact your local Straumann representative  
now or visit [www.straumann.com](http://www.straumann.com).

A0019/en/A/00 03/19

Dr Scott D. Ganz

Editor-in-Chief



## IDS 2019—Amazing!

**Every two years**, the global dental industry convenes the largest trade show and dental business summit in Cologne in Germany for the International Dental Show (IDS). Despite many of the economic, financial and cultural issues presently facing the world, IDS 2019 (the 38<sup>th</sup> edition) marched on to record attendance and participation by clinicians, educators, auxiliaries, manufacturers, distributors and publishers, while showcasing a vast variety of products and equipment.

Koelnmesse was the centre of the dental universe for tens of thousands of participants during a full week in March, often with a crush of people trying to pass through the crowded aisles to get a glimpse of new products and technology, or watch hands-on demonstrations or brief presentations delivered by clinicians, laboratory technicians, dental hygienists and industry partners representing 2,000 exhibitors from 58 countries.

As usual, seeing everything that one might wish to see in the multiple halls was impossible. One thing was abundantly clear: there was a major emphasis on innovation and digital solutions focusing on the expanding world of CAD/CAM, 3D printing, design software from various vendors, CBCT and 3D imaging, aesthetic dentistry, smile design and the ever-expanding dental implant uni-

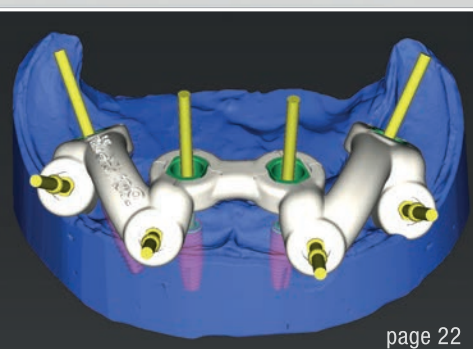
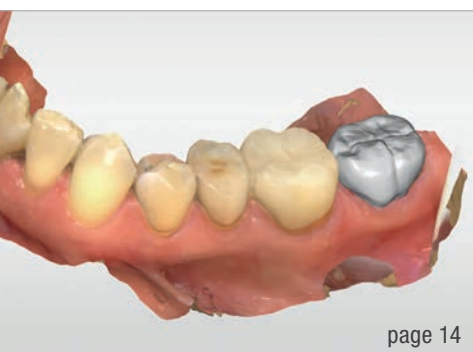verse. The number of dental implant manufacturers and systems on display was almost beyond imagination!

As in previous years, Dental Tribune International (DTI) was present at IDS 2019 with an expansive and elegant lounge conceived for meeting colleagues and industry partners over coffee or a quick meal away from the din of surrounding exhibit halls. The publisher's array of print and online publications truly illustrates the incredible scope and impact of DTI around the globe. For those who are ardent readers of **CAD/CAM**, we appreciate your patronage. This is one of a myriad of publications and news channels DTI offers, making the company's portfolio an invaluable resource for all dental professionals.


For those who did not get to experience IDS 2019, keep checking the pages of DTI offerings in print or online to learn more about the innovations presented during the event. For those who want to experience IDS first-hand, the next meeting will be in March 2021—put that on your calendar and book your hotel rooms now!

Dr Scott D. Ganz  
Editor-in-Chief





Cover image courtesy of  
Chesky/Shutterstock.com



## editorial

- IDS 2019—**Amazing!** 03  
Dr Scott D. Ganz

## study

- Comparison of** guided and non-guided **implant placement accuracy:**  
***In vitro*** study with 3D printing (Part 2) 06  
Marta Czajkowska, Dr Łukasz Zadrozny, Zbigniew Bartosik & Dr Leopold Wagner

## interview

- Digital workflow** in dentistry—What's in it **for you** 12  
Interview with Dr Simon Kold

## user report

- Scan perfectly **with CEREC Primescan** and gain time for  
what is **really important:** your patients 14  
Results by Dr Bernhild-Elke Starnitz

## case report

- Zirconia implants and **digital workflow:** A case report 18  
Drs Saurabh Gupta & Sammy Nounbissi  
Straumann Pro Arch concept with **fully guided implant**  
and abutment **placement** 22  
Dr Nikolay Makarov  
Predictable **guided implant** placement for **full-mouth** reconstruction 28  
Dr Ara Nazarian

## cone beam supplement

- Experts advocate using **low-dose CBCT imaging** protocols 32  
Use of **3D technology** in the **diagnosis** and treatment of endodontic disease 34  
Dr Fabio Gorni  
Dynamic Navigation: **Closing the gap** between planning and execution 40

## practice management

- Why reviews** have grown in **importance** 42  
Chris Barrow

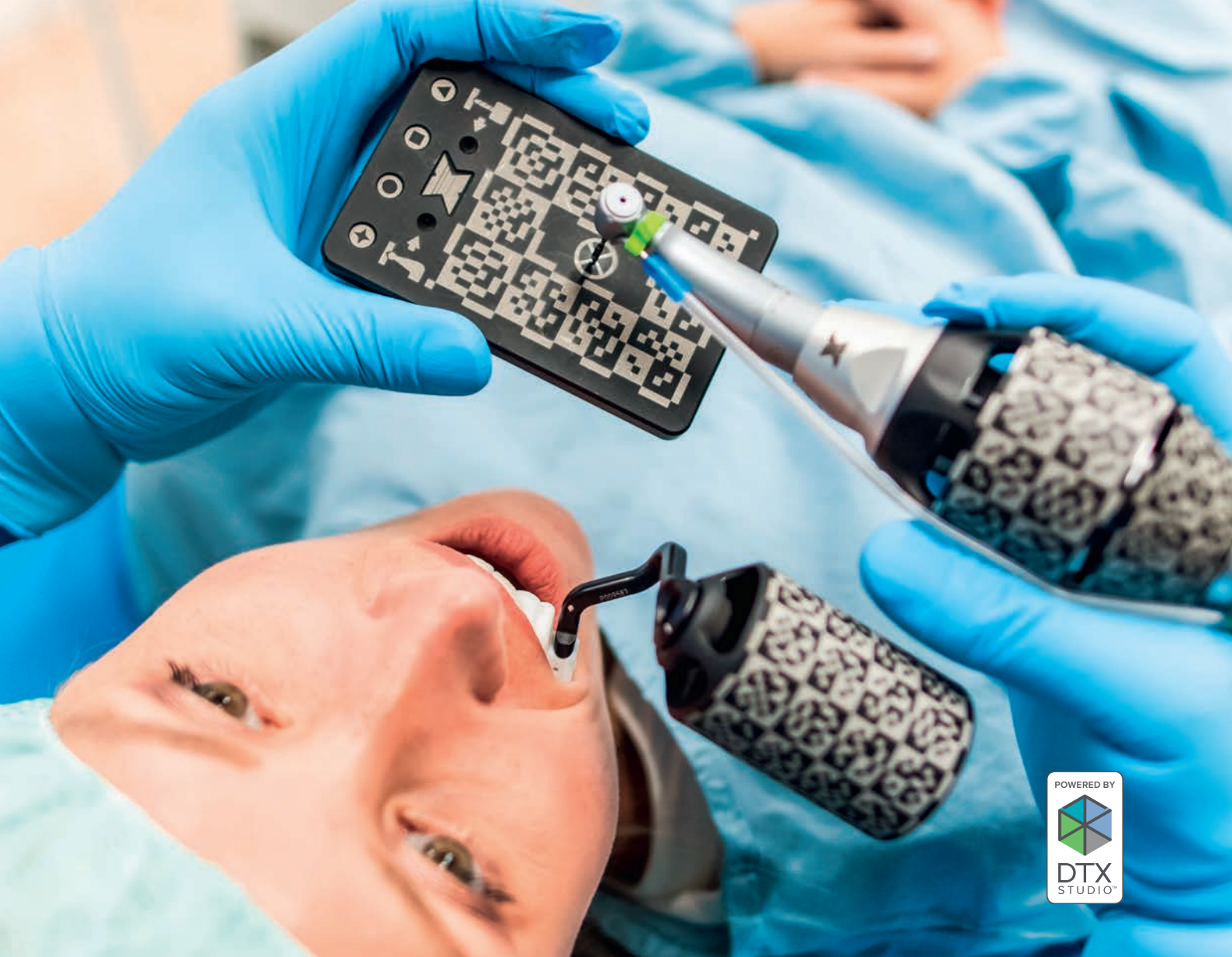## manufacturer news

## meetings

- IDS 2019: Leading global trade fair of the dental industry **reaffirms its position** 50  
Nobel Biocare is set to **reshape implantology** with new implant solution  
at upcoming Madrid symposium 54  
International events 56

## about the publisher

- submission guidelines 57  
international imprint 58



# Same-day 3D navigated surgery

- Perform free-hand surgery with real-time 3D guidance for your drills and implants with X-Guide
- Adapt your implant plan anytime during surgery
- Facilitate more same-day diagnostic and treatment sessions with DTX Studio suite

GMT 61123 GB 1903 © Nobel Biocare Services AG, 2019. All rights reserved. Distributed by: Nobel Biocare. X-Guide is either registered trademark or trademark of X-Nav Technologies, LLC in the United States and/or other countries. Nobel Biocare, the Nobel Biocare logotype and all other trademarks are, if nothing else is stated or is evident from the context in a certain case, trademarks of Nobel Biocare. Please refer to [nobelbiocare.com/trademarks](https://nobelbiocare.com/trademarks) for more information. Product images are not necessarily to scale. Disclaimer: Some products may not be regulatory cleared/released for sale in all markets. Please contact the local Nobel Biocare sales office for current product assortment and availability. For prescription use only. Caution: Federal (United States) law restricts this device to sale by or on the order of a licensed dentist. See Instructions For Use for full prescribing information, including indications, contraindications, warnings and precautions.



# Comparison of guided and non-guided implant placement accuracy

## *In vitro* study with 3D printing (Part 2)

Marta Czajkowska, Dr Łukasz Zadrożny, Zbigniew Bartosik & Dr Leopold Wagner, Poland

### Introduction

Proper 3D implant positioning is a crucial factor for predictable implant and prosthodontic treatment. Guided osteotomy preparation and placing implants through a guide may contribute to more precise implant placement in accordance with the prosthodontic plan. In the first part of the article (published in **CAD/CAM** 1/2019), we described the use of 3D imaging in implant treatment planning. This study aims at the comparison of two methods in terms of repeatability and compliance with the treatment plan.

### Aim of the second part of the study

The aim of the second part of the study is to present the methods of comparison of effects for both types of procedures and the initial results.

### Material

The guide was sterilised and clinically used during the procedure repeated under the *in vitro* conditions on half of the selective laser sintered mandibular models

(material: polyamide 12; 3D printer: TPM Elite P3200 SLS system; print: Solveere). The procedure was performed freehand for the other half of the models. The mandibular models, created on the basis of 3D imaging, reflected the clinical spatial conditions.

The comparative material consisted of scans of the bone bearing the implants (TSIII with standard mounts, Osstem Implant) and scans of the model of the treatment plan with inserts. The bone scans were performed with the use of the laboratory scanner ceramill map 400+ (Amann Girrbach) and saved in STL open files. The files are maps of triangles describing the surface of the 3D model. Each triangle vertex has coordinates. The denser the net of triangles, the smaller the area of the real model covered by each triangle. According to the manufacturer, the scanner accuracy is 10 µm. The compared material consisted of two STL files of the scans of models in which the implantation procedure was performed with the use of the guide, an STL file of the scan of the model after implantation performed freehand and an STL file of the virtual plan of the procedure. The file of the virtual plan was a reference point for the calculation of deviations in the groups with and without the use of the guide.



The implantation procedure was planned in DDS-Pro software ([www.dds-pro.com.pl](http://www.dds-pro.com.pl)) on the basis of the CBCT scan and the optical scan of the cast model and of the model with the wax-up of the future prosthesis. In this manner, the image of the bone and mucosa surface and the localisation and the shape of the future prosthesis were obtained.


In the next step, based on the implant location plan, a digital model with inserts located in the sites of the future implants was created. Each virtual insert was located exactly in the site of the virtual implant platform and was in the shape of a cylinder with a diameter of 3.0 mm and height of 8.5 mm.

## Methodology

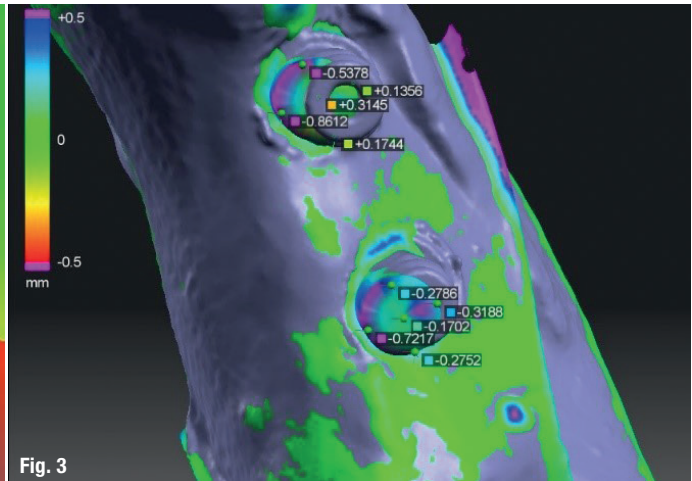
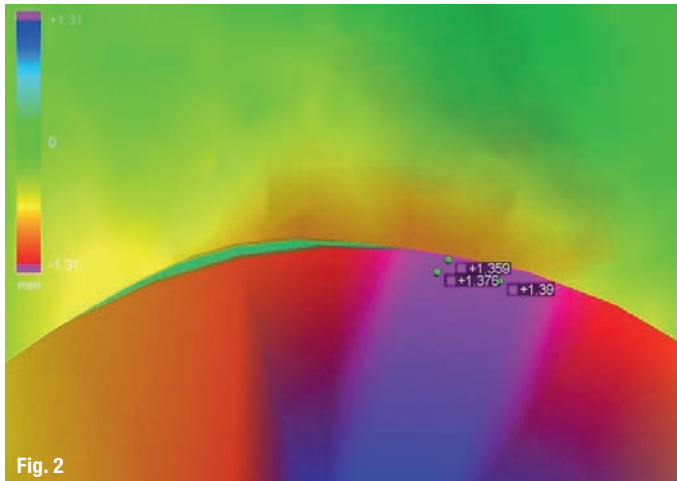
In order to compare the samples from both groups—bone scans with implants placed freehand and with the use of guides—HP 3D Scan Version 5 software (HP) was used. Data was recorded using two methods: based on the maps of deviations and on the measuring points. For each scan, 30 maps were created, based on tolerance levels of 0.01 to 3.01 mm in 0.1 mm increments (Fig. 1).

Next, for each implant, a tolerance level was chosen for which there were no areas on the map showing variations exceeding this level. In this way, the levels not exceeded by the deviation of the implant and insert locations were established for each implant individually. The next stage of the study was finding the areas with deviations exceeding this level on the tolerance level lower by 0.1 mm (one tolerance level) than the level established for each implant. These areas were marked in pink. By choosing a number of points located close to each other and choosing a point with the highest value in these areas, the points with the highest value of deviations were marked (Fig. 2).

In the second method, the measuring points were established on the reference model. The following points were marked on the upper surface of each insert (Fig. 3): central, mesial, distal, labial and lingual. Next, for each implant, the deviation of its location relative to these points was checked. Test models were changed successively, maintaining formerly set measuring points to avoid marking them again. The location of measurement points did not change relative to the insert, but depending on the test model, the deviation value assigned to these points did.



**Fig. 1:** Example of deviation maps set for FH01. The pink colour indicates areas where the deviations exceeded the tolerance level established for the particular map; the remaining colours indicate areas within the accepted range.

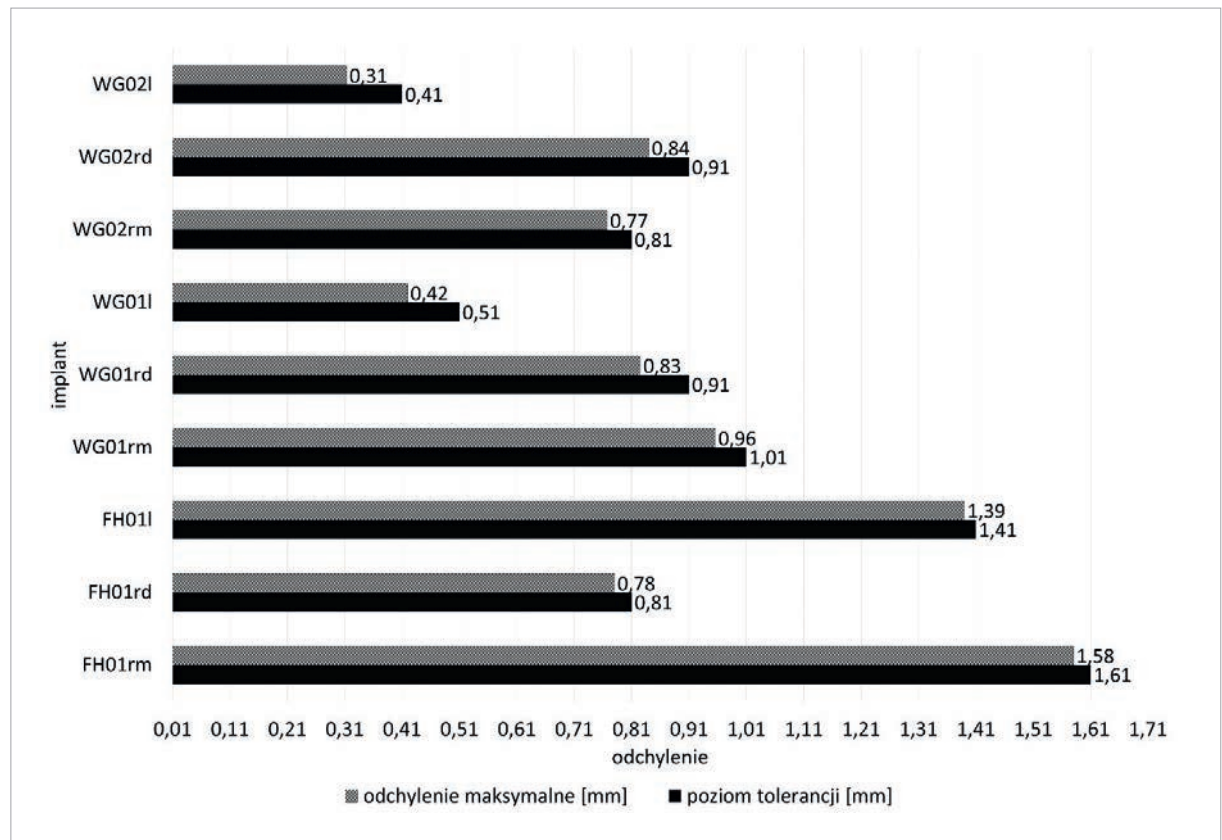


**Fig. 2:** An example of the area where the established tolerance level for implant FH01I was exceeded, with some point deviations marked. **Fig. 3:** The placement of measuring points on implants WG01rm and WG01rd. The grey test model with implants was superimposed upon the reference model and deviation levels marked.

This allowed us to maintain repeatability of measurements while testing other models.

Preliminary results of the comparison are shown in the figures. The smallest deviations were visible on implant WG02I, and the largest deviations were on implant FH01rm (Fig. 4). In order to compare the groups, a larger

number of samples should be studied, but after the comparison of three initial models, we could see a great difference between implants placed with and without the help of guides. There was also a noticeable, differentiation in the degree of deviations in both groups of implants. In the case of implants placed with the help of guides and freehand, there were cases of small and large deviations.



**Fig. 4:** Deviation levels for particular implants set with maximum point deviations. Implant naming: WG/FH, sample number, l/r, m/d (FH = freehand; WG = with guide; I = left; r = right; m = mesial; d = distal).



It should be noted that the differences between the levels where there were no longer any deviations and the maximum deviations were more similar for the procedures performed without the use of guides. This indicates that the treatment plan is followed more precisely when the guides are used.

Like in the first method, in order to compare both types of treatment, more samples should be compared. On the basis of the first three results, we observed that the greatest deviations appeared in the group of implants placed freehand (Fig. 5). In this group, larger differences between deviations at individual measuring points were noticeable. This demonstrates that the axes of the implant and the insert were inclined at a greater angle to each other and the upper surface of the implant was not parallel to the upper surface of the insert. This is especially evident for implants FH01rd and WG02l, which, despite having a similar mean deviation value, have a different degree of differentiation of deviations in the points (Figs. 6 & 7).

## Discussion

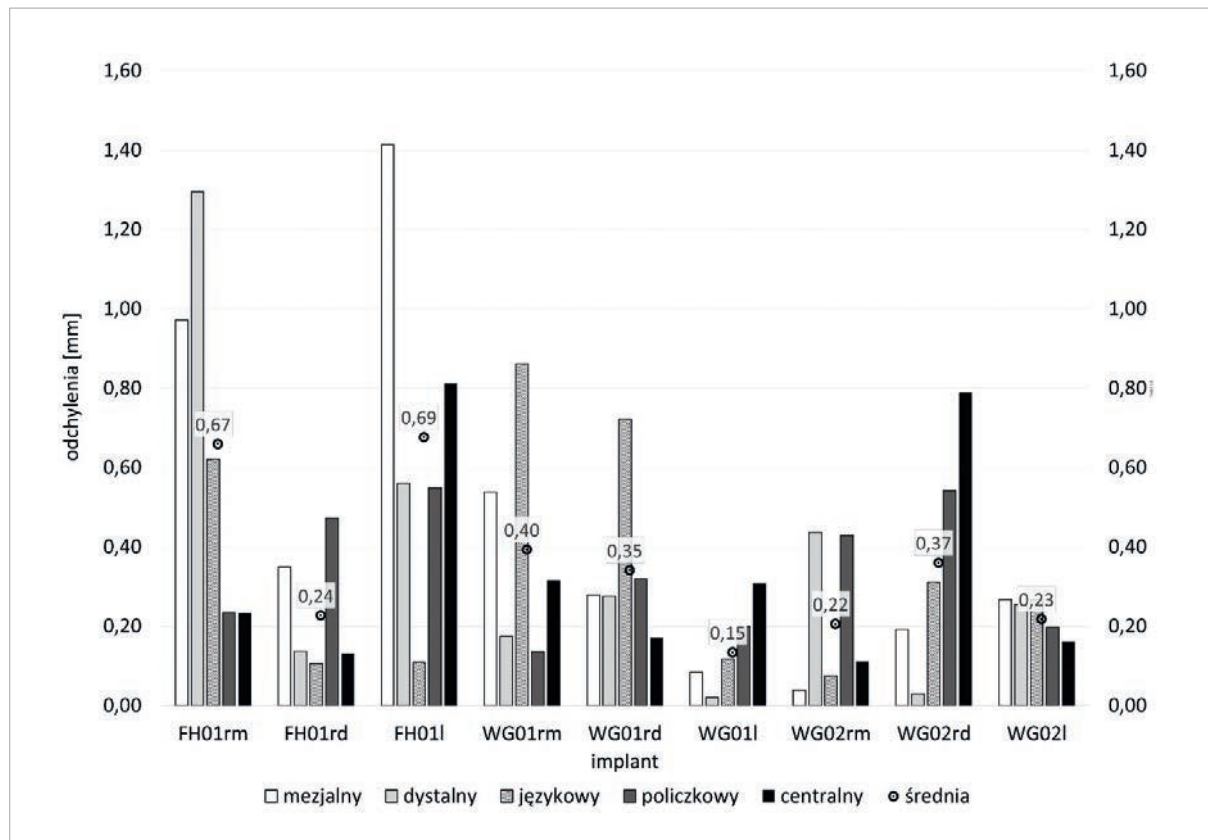
Many factors affecting the success of implant surgery and its compliance with the treatment plan are reported in the literature. The most important of these are the type

of procedure, operator's experience and clinical conditions.

As digital technologies gain in significance, digital spatial imaging is increasingly used, as it allows consideration of not only the bone conditions but also the function and aesthetics of the future prosthetic restoration during the treatment planning. The use of CT or CBCT imaging enables reduction of the risk of damage of such structures as nerves, roots of adjacent teeth and the sinus wall. The implant procedure performed with the use of guides is assessed in systematic reviews as a technique which is less invasive and reduces the risk of postoperative complications.

Despite the limitations of this study, arising from the choice of an *in vitro* method aiming to achieve the highest repeatability of conditions in both groups, the preliminary results of the study are supported by the data obtained in the study conducted under clinical conditions.

Vermeulen shows that procedures performed with the use of implant guides give results more consistent with the treatment plan, even when compared with freehand procedures performed by top-class experienced surgeons. In the mentioned study, particularly important differences were seen in the deviation of implant placement



**Fig.5:** Absolute deviation values for implants in the areas of fixed measuring points on the inserts. Implant naming: WG/FH, sample number, l/r, m/d (FH = freehand; WG = with guide; l = left; r = right; m = mesial; d = distal).